

Welcome to

The 2nd Contemporary Morphology Course
Congenital Heart Disease in Your Hands

December 6-7, 2019

TORONTO

A night photograph of the Toronto skyline. In the foreground, the word "TORONTO" is displayed in large, illuminated letters. Each letter is a different color: 'T' is blue, 'O' is yellow, 'R' is white, 'O' is green, 'N' is blue, 'T' is red, and 'O' is yellow. The letters are reflected in a pool of water in front of them. In the background, several tall buildings are lit up, and a red neon arrow points upwards. A bench is visible in the lower-left foreground.

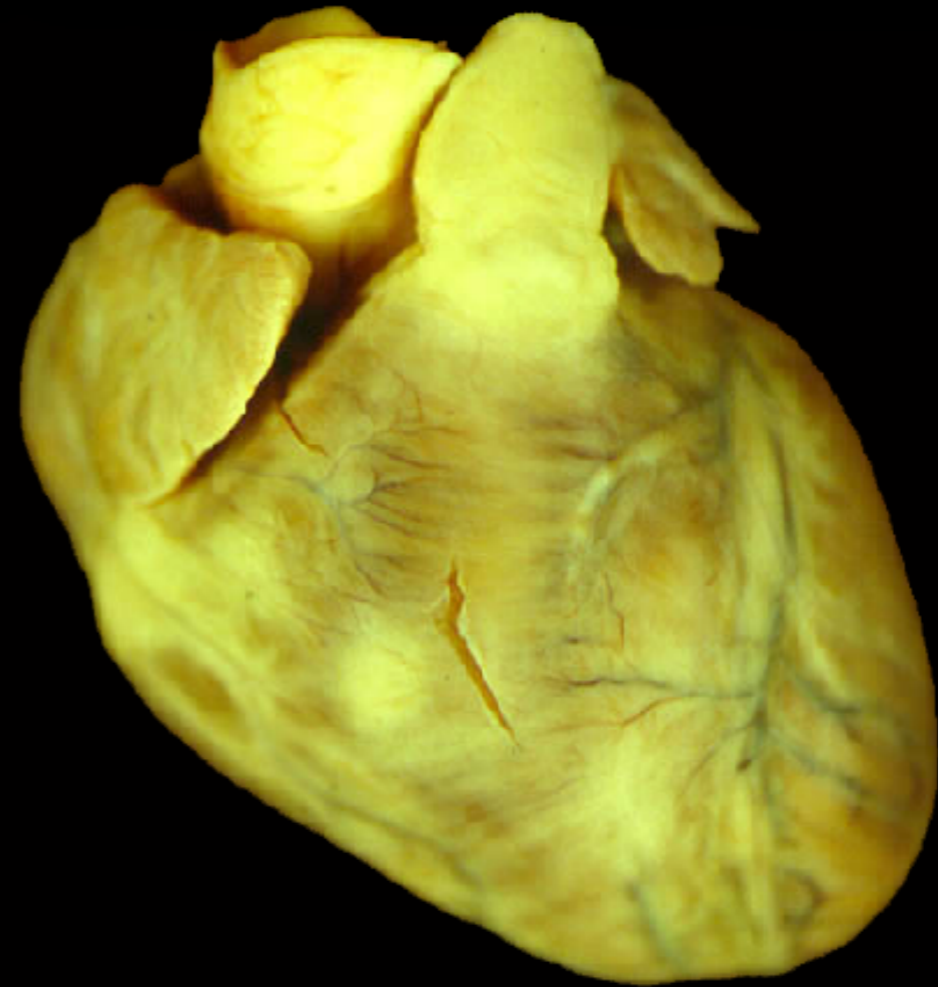
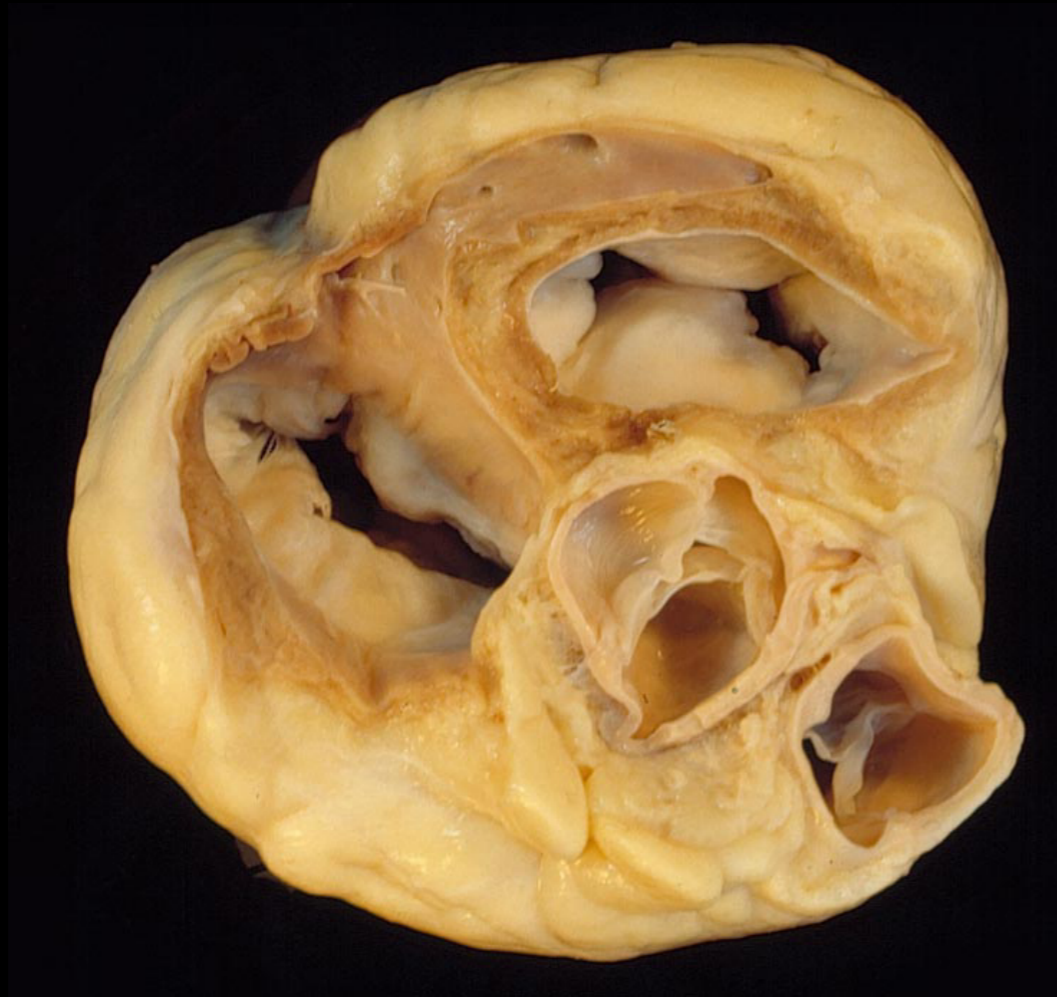The 2nd Contemporary Morphology Course
Congenital Heart Disease in Your Hands
December 6-7, 2019

BASE OF THE VENTRICLES

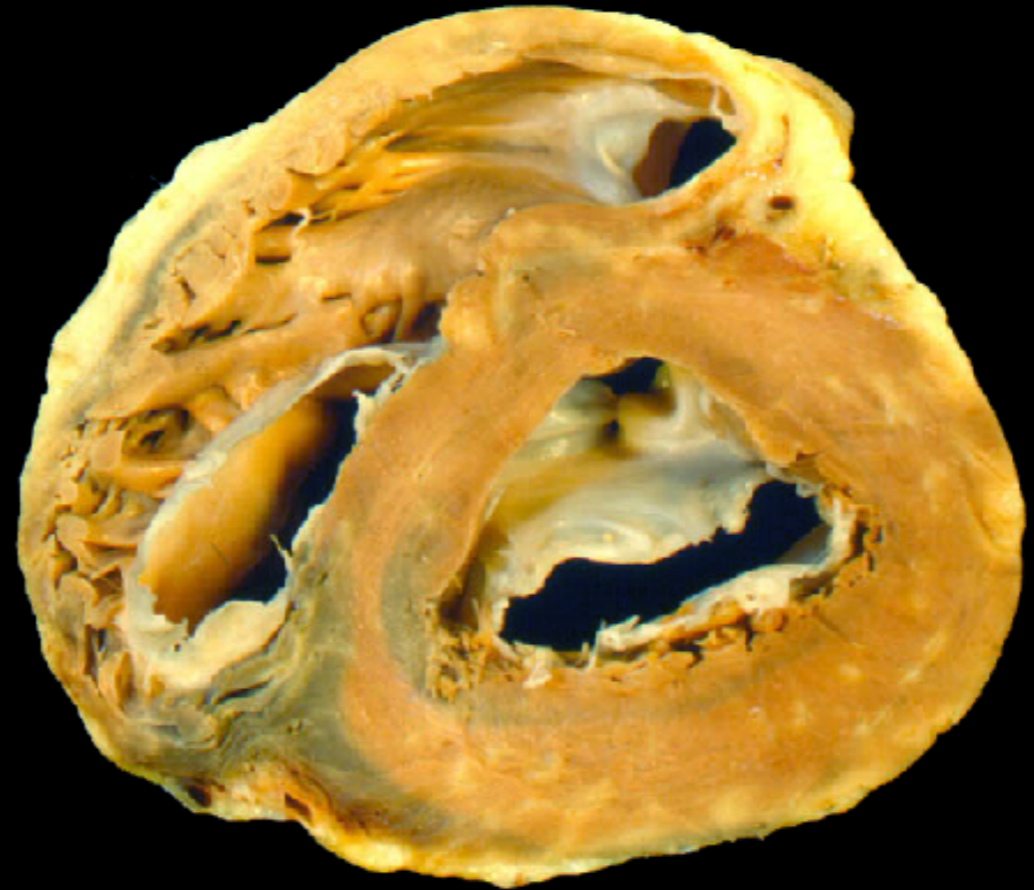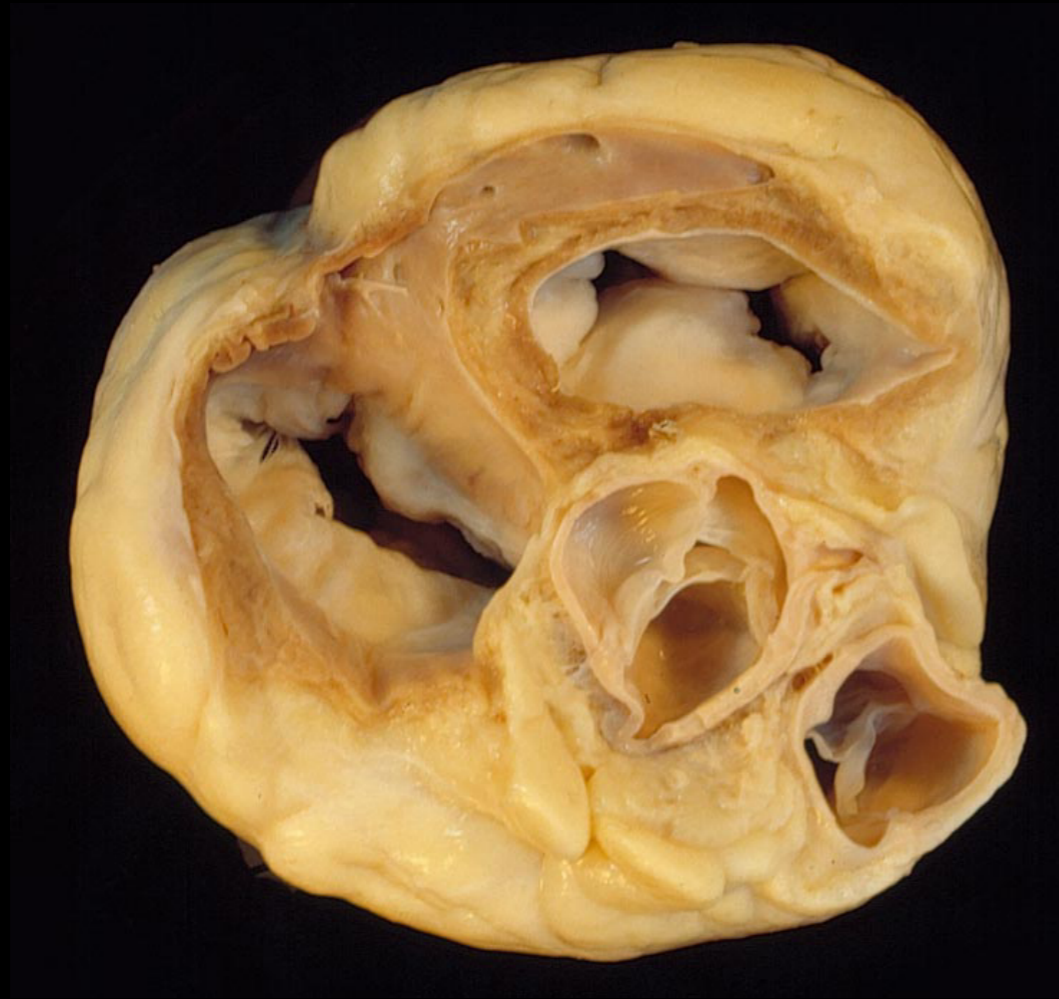A KEY PLANE FOR UNDERSTANDING OF
NORMAL AND MALFORMED HEARTS

Shi-Joon Yoo, MD
Department of Diagnostic Imaging and
Division of Cardiology, Department of Paediatrics
Hospital for Sick Children
University of Toronto
Canada

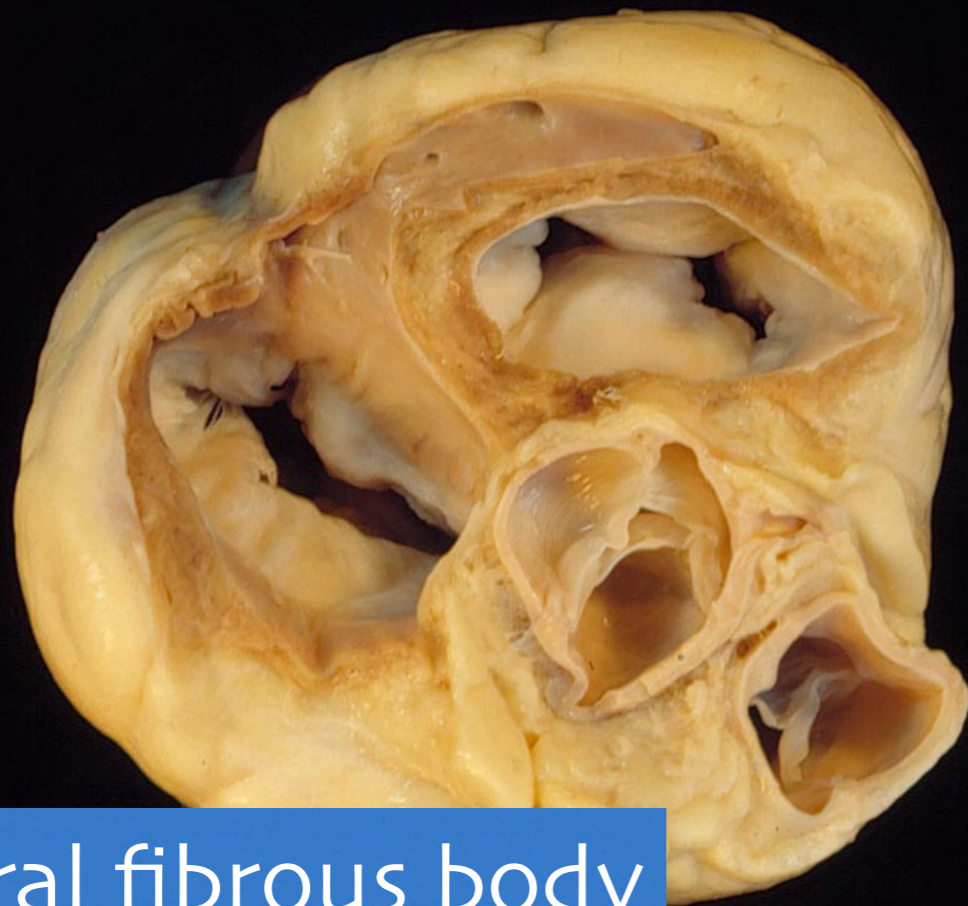
BASE OF THE VENTRICLES



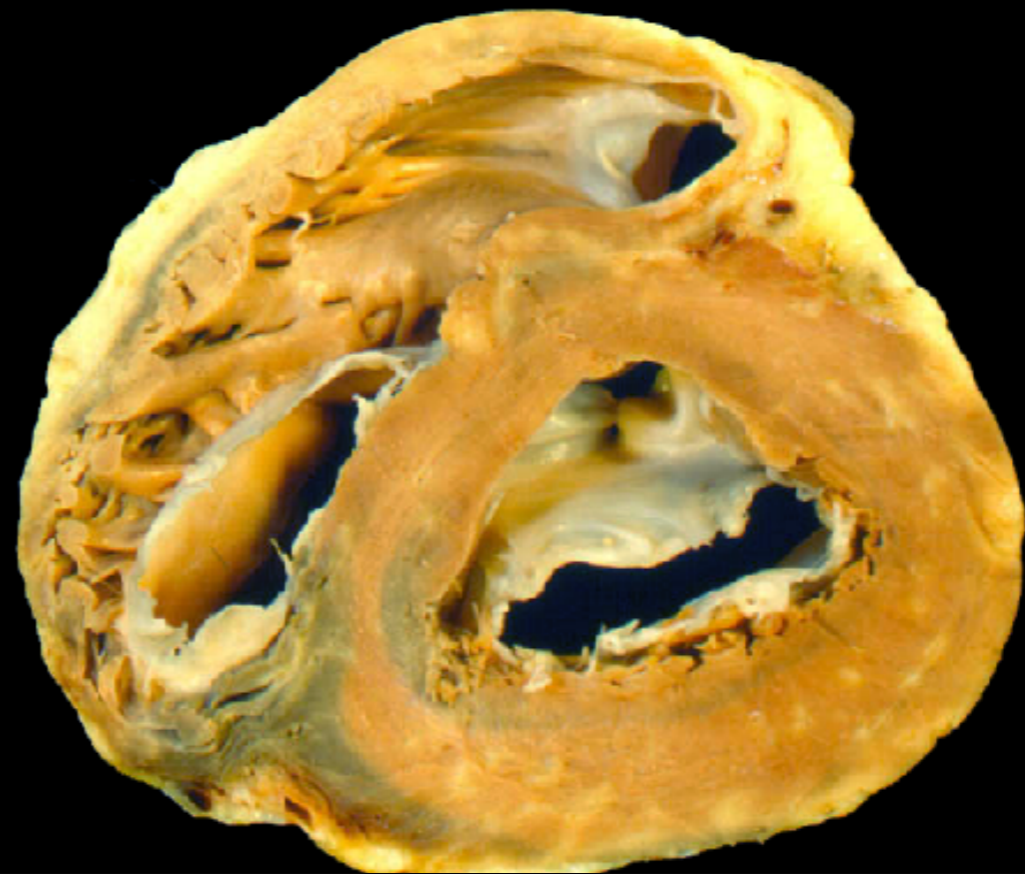OUTLINE



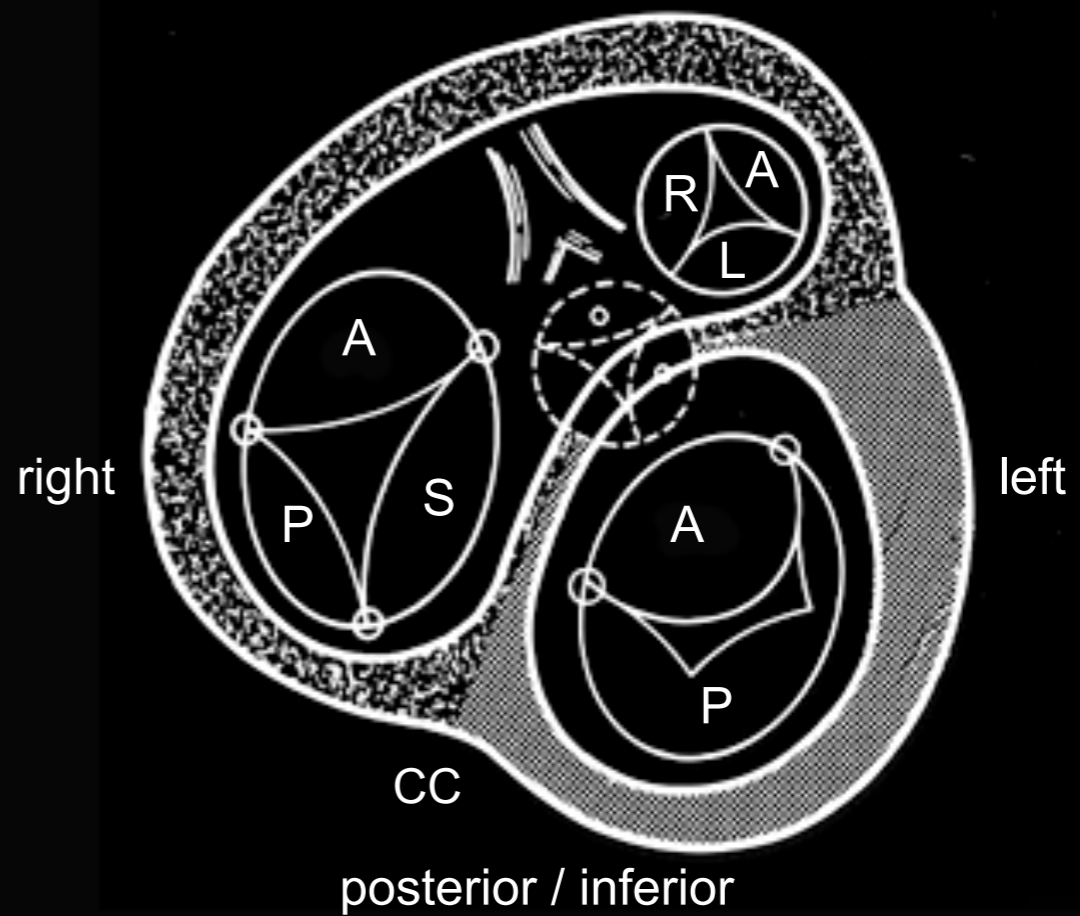
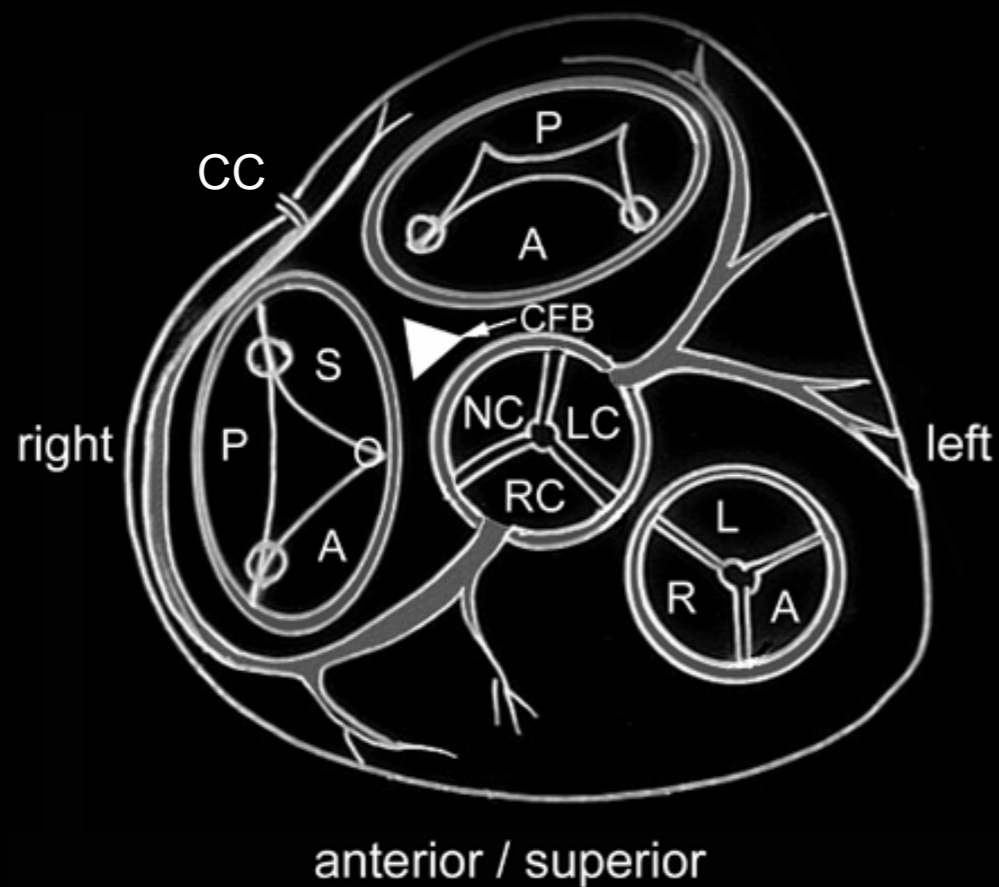
- Normal anatomy
- VSD's: as simple holes vs malalignment type VSDs
- TGA's and DORV's
- Straddling AV valves and double inlet ventricles



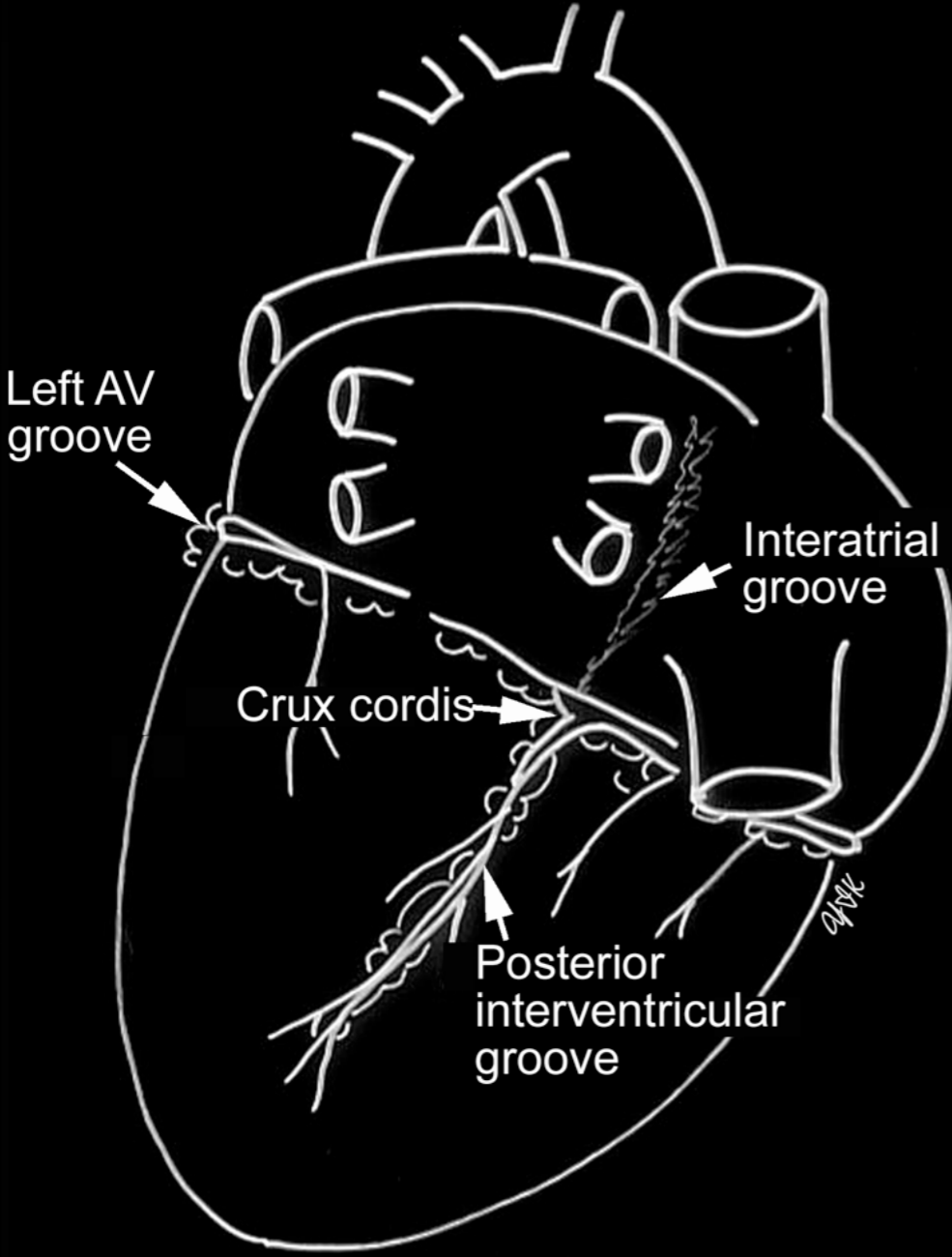
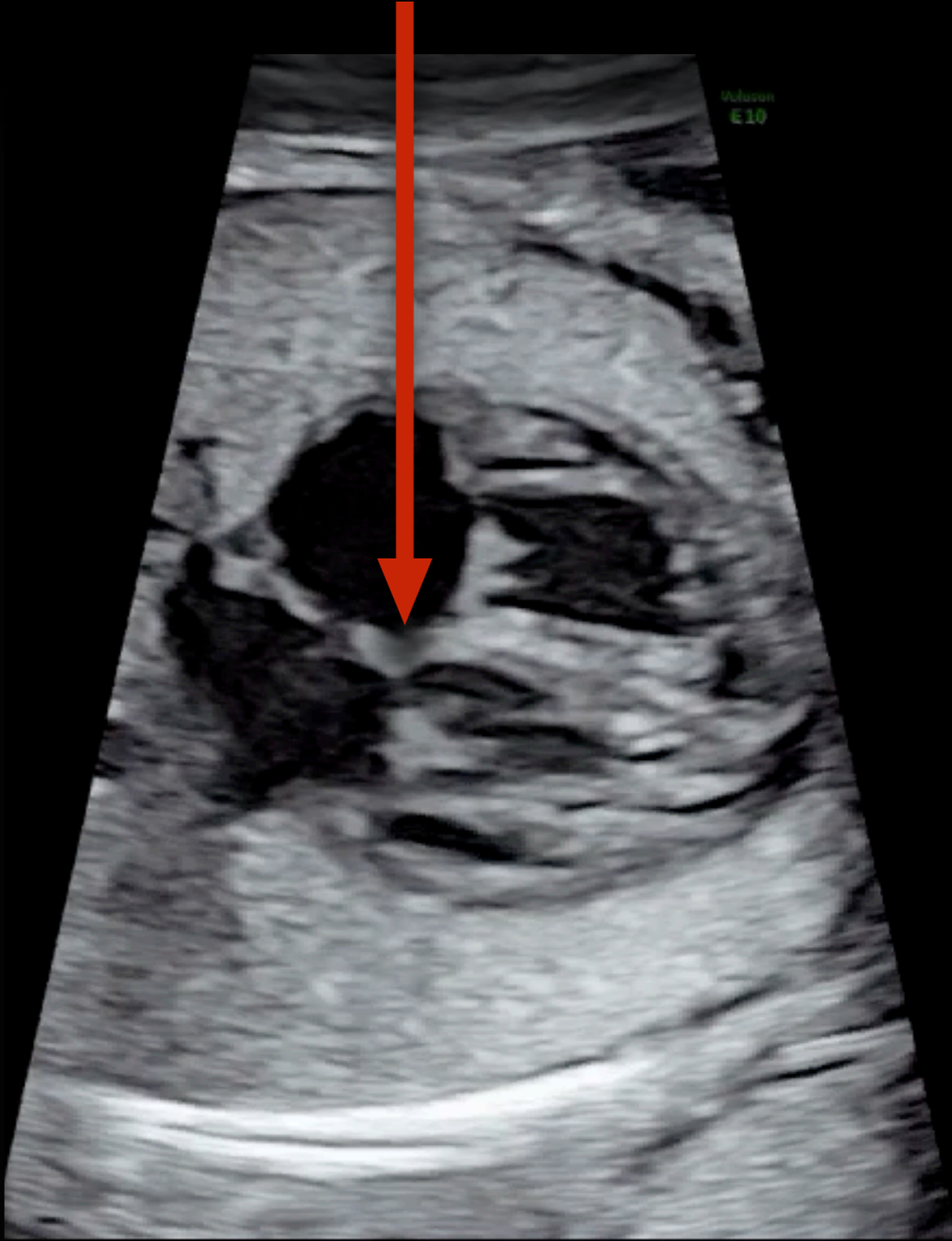
Central fibrous body
Crux cordis



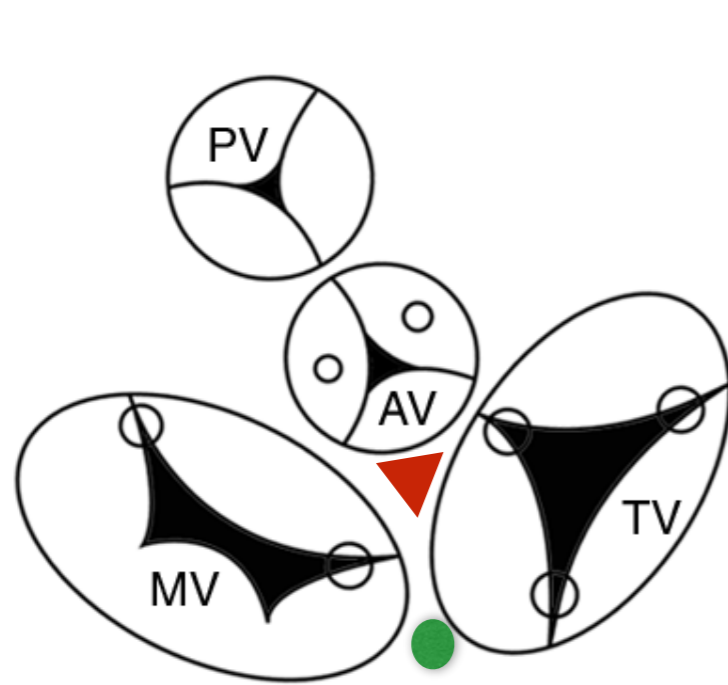
anterior / superior



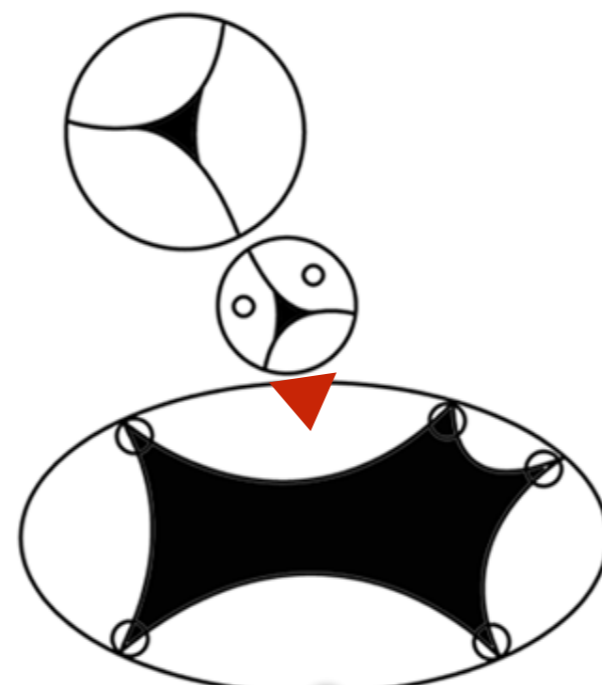
Not this



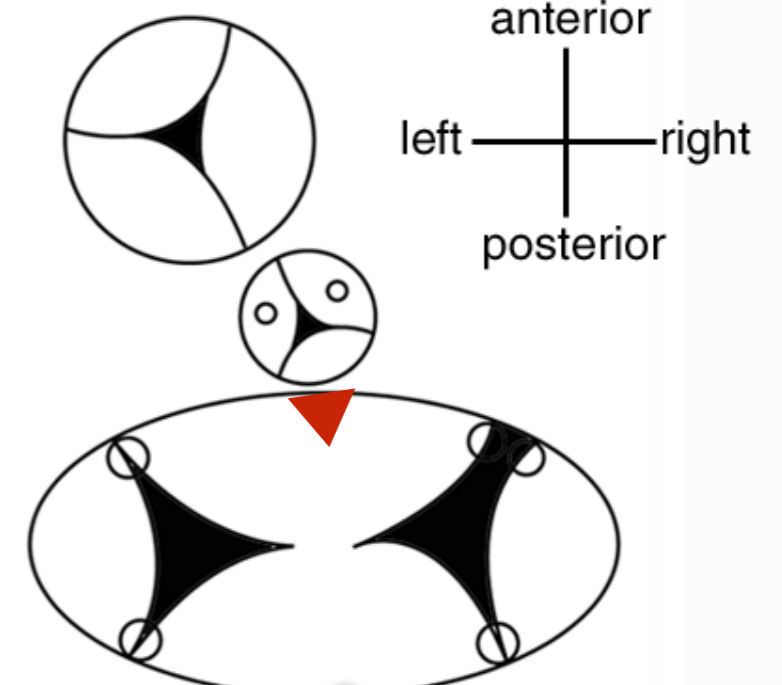
Wedged versus Unwedged or Unsprung position of the aortic valve



Normal

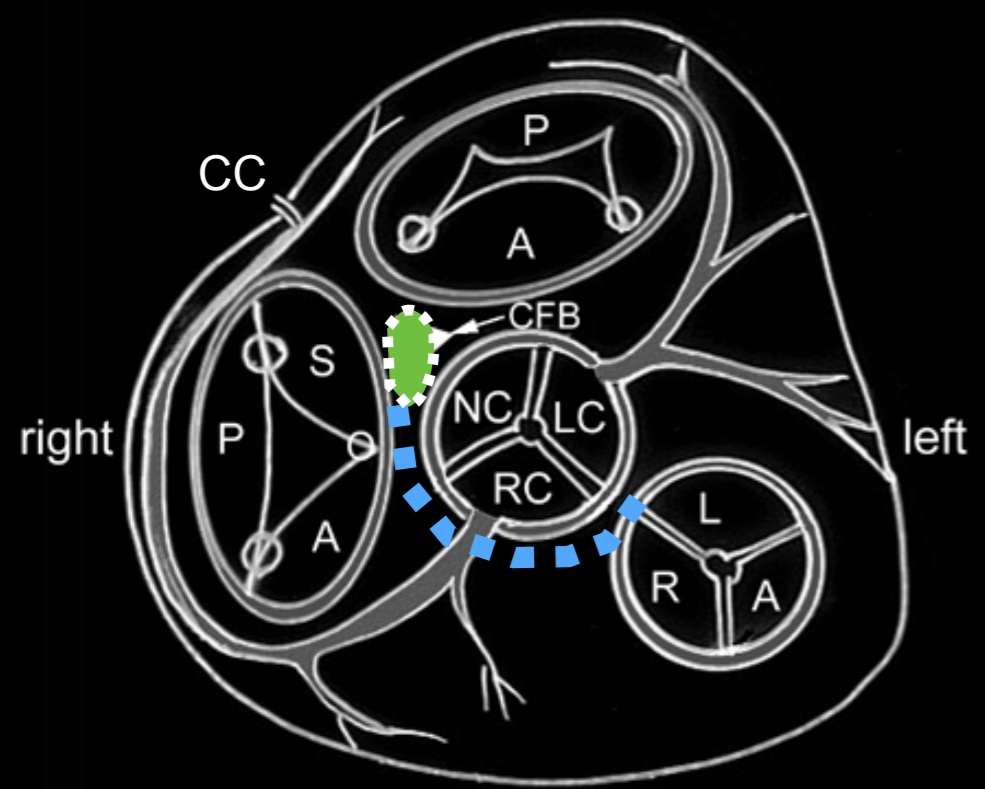


AVSD with a common AV valve orifice



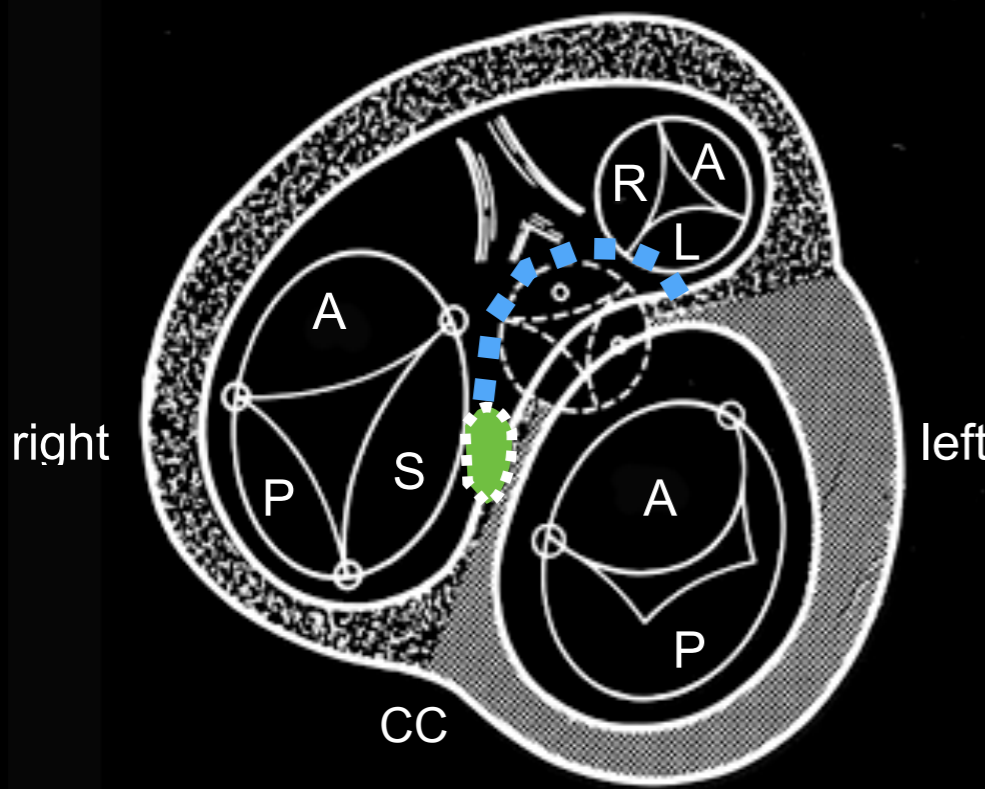
AVSD with partitioned AV valve orifice

posterior / inferior

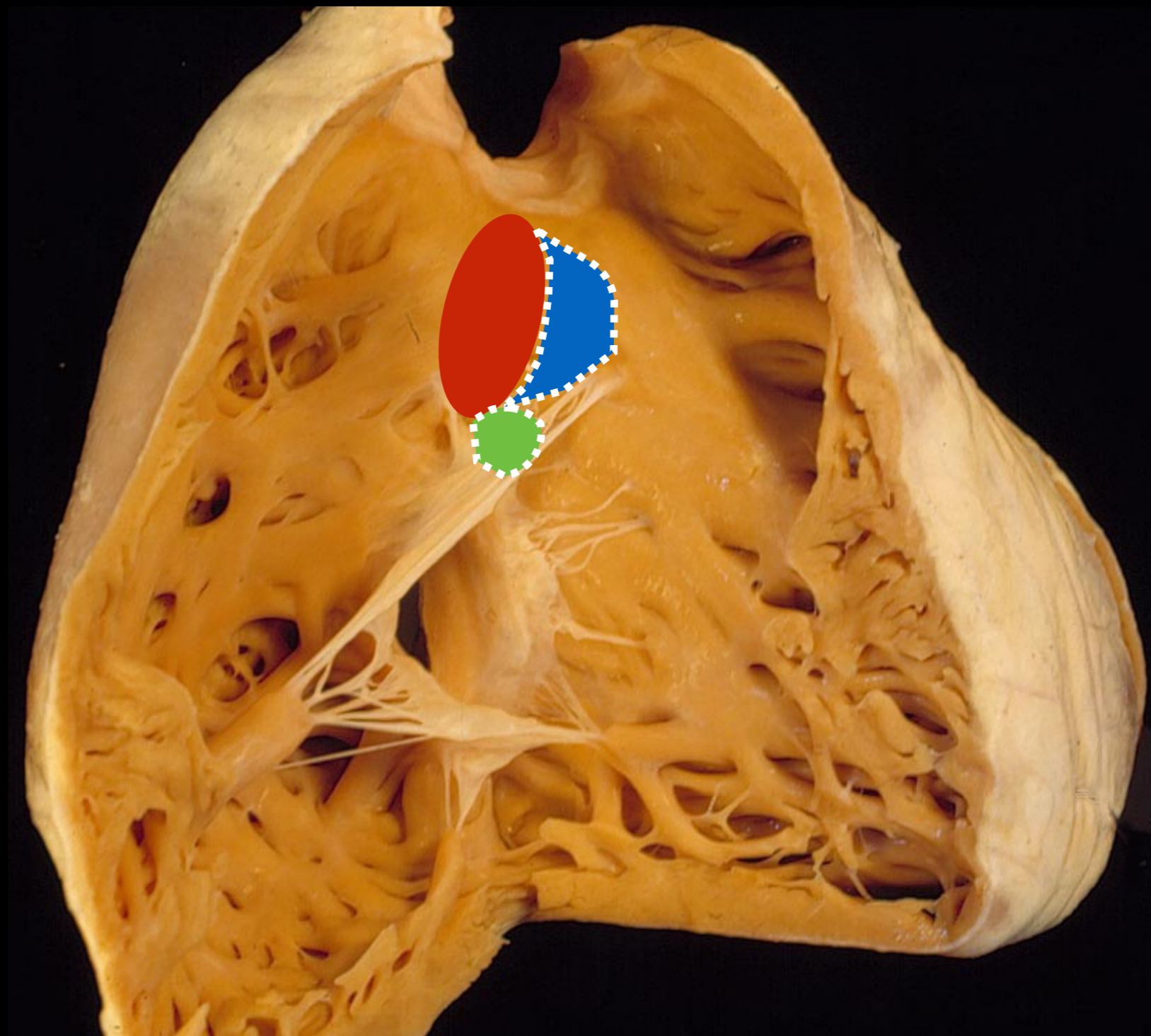


anterior / superior

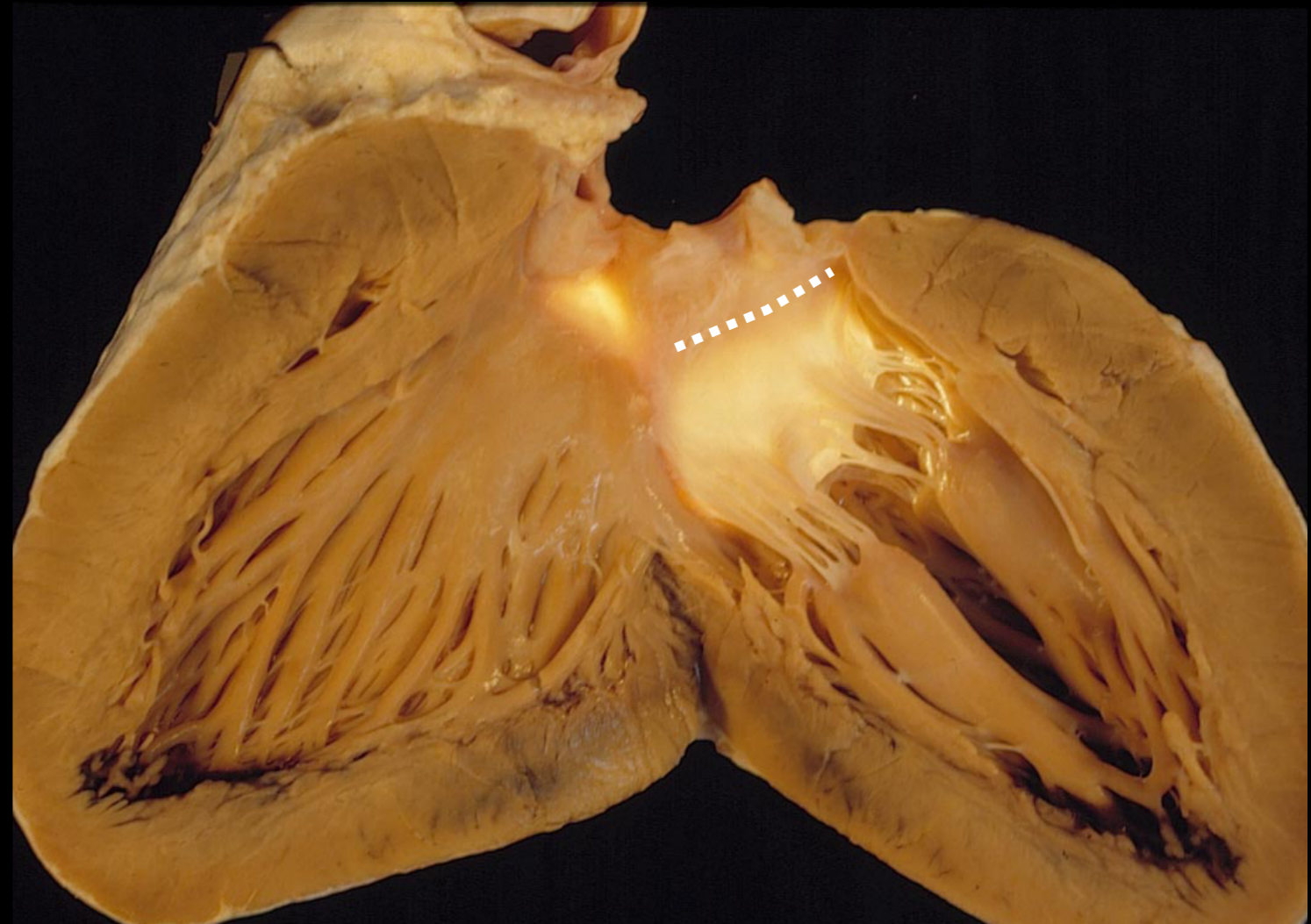
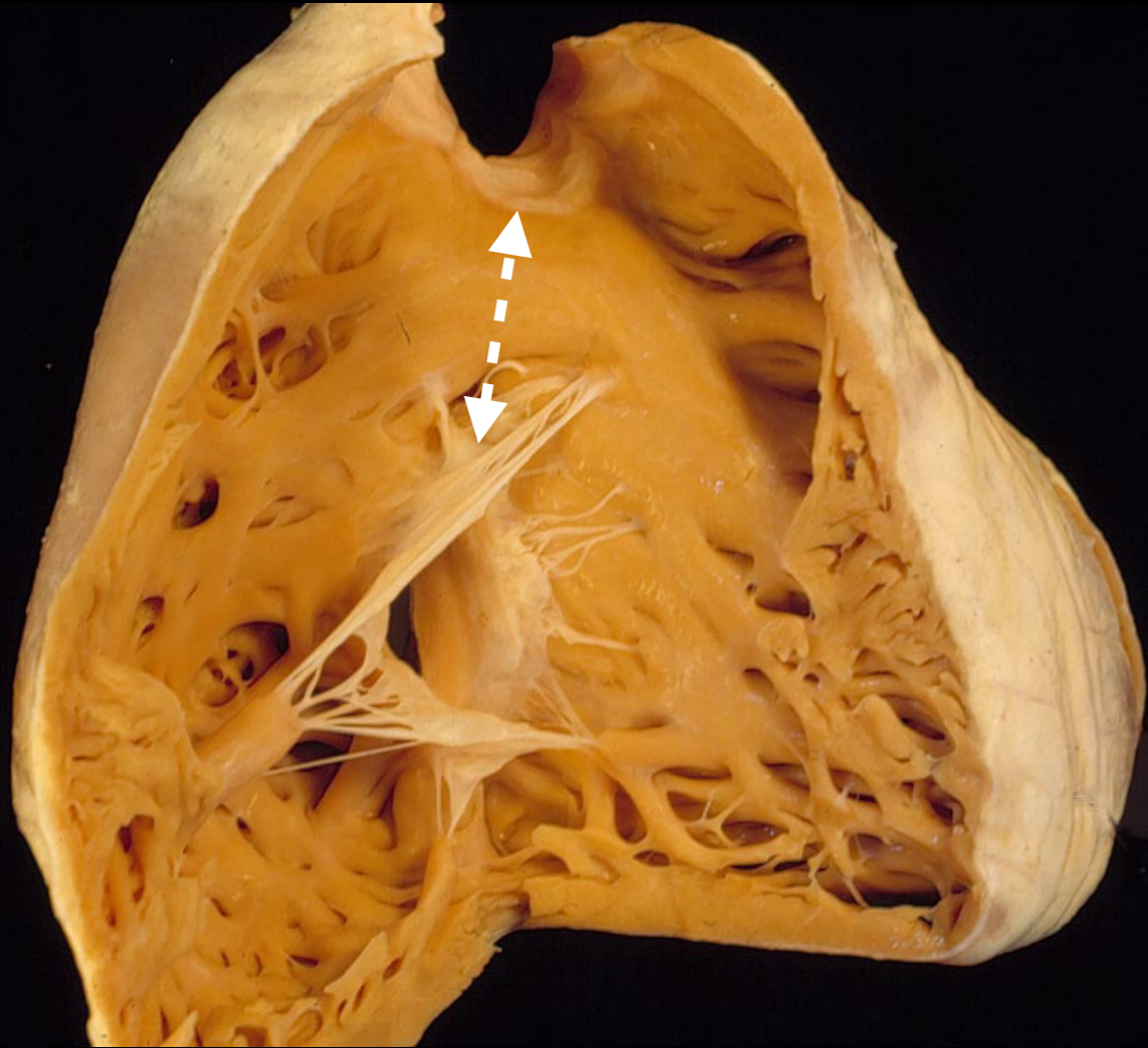
anterior / superior



posterior / inferior

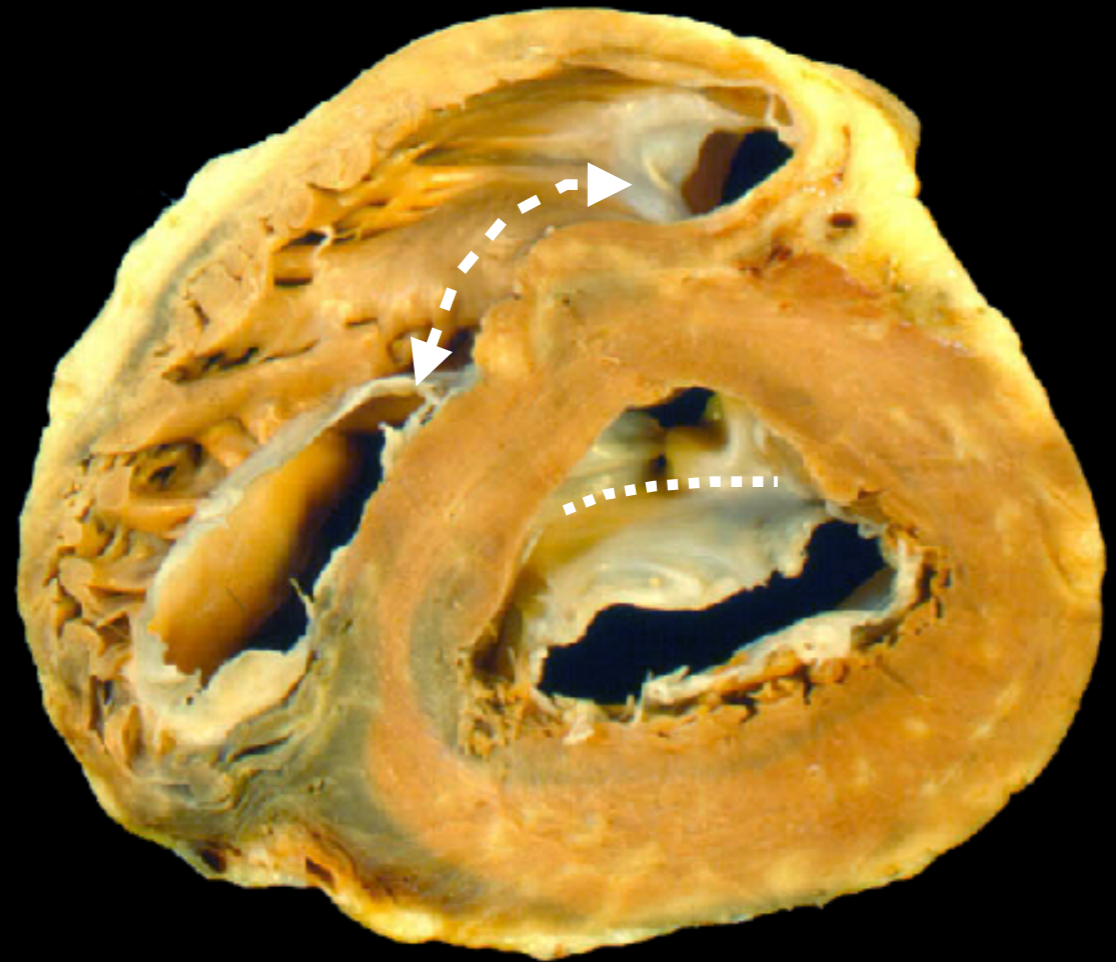
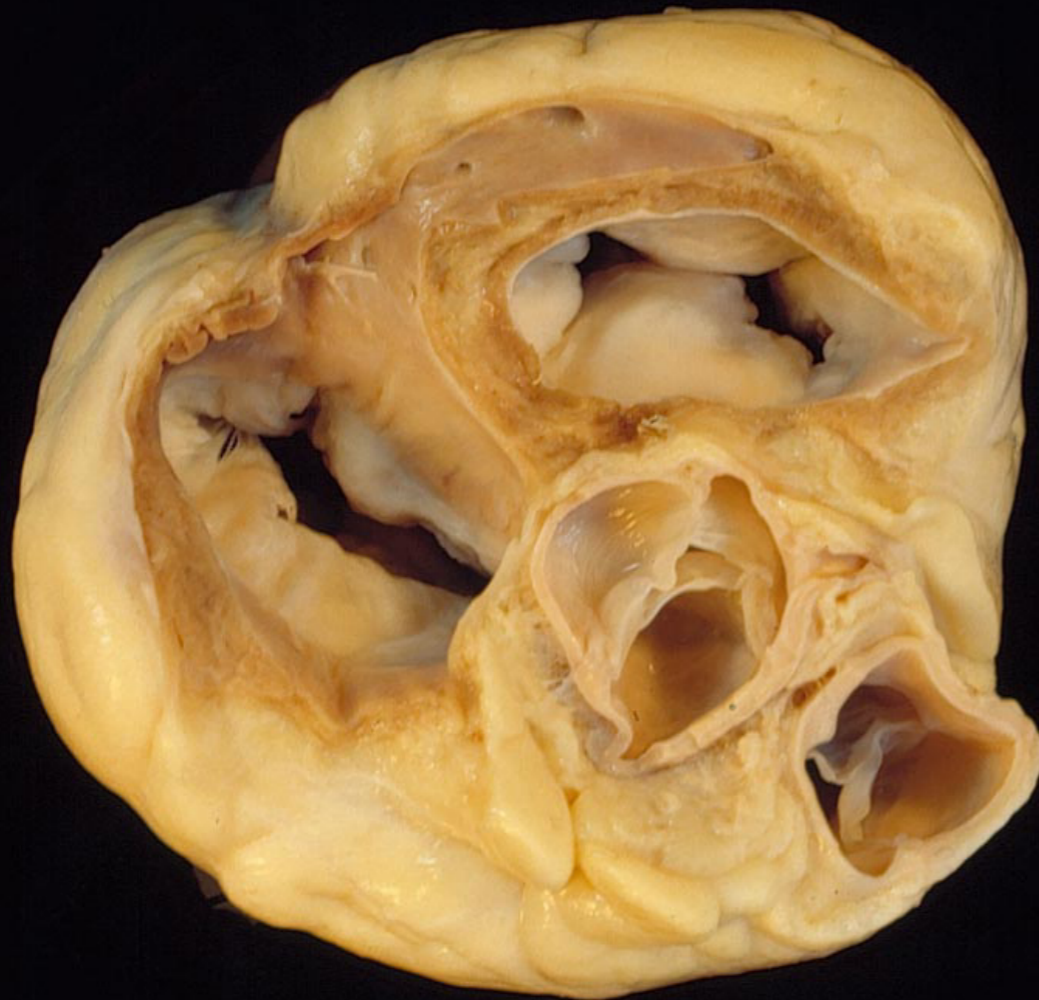

INFUNDIBULUM: What is it?



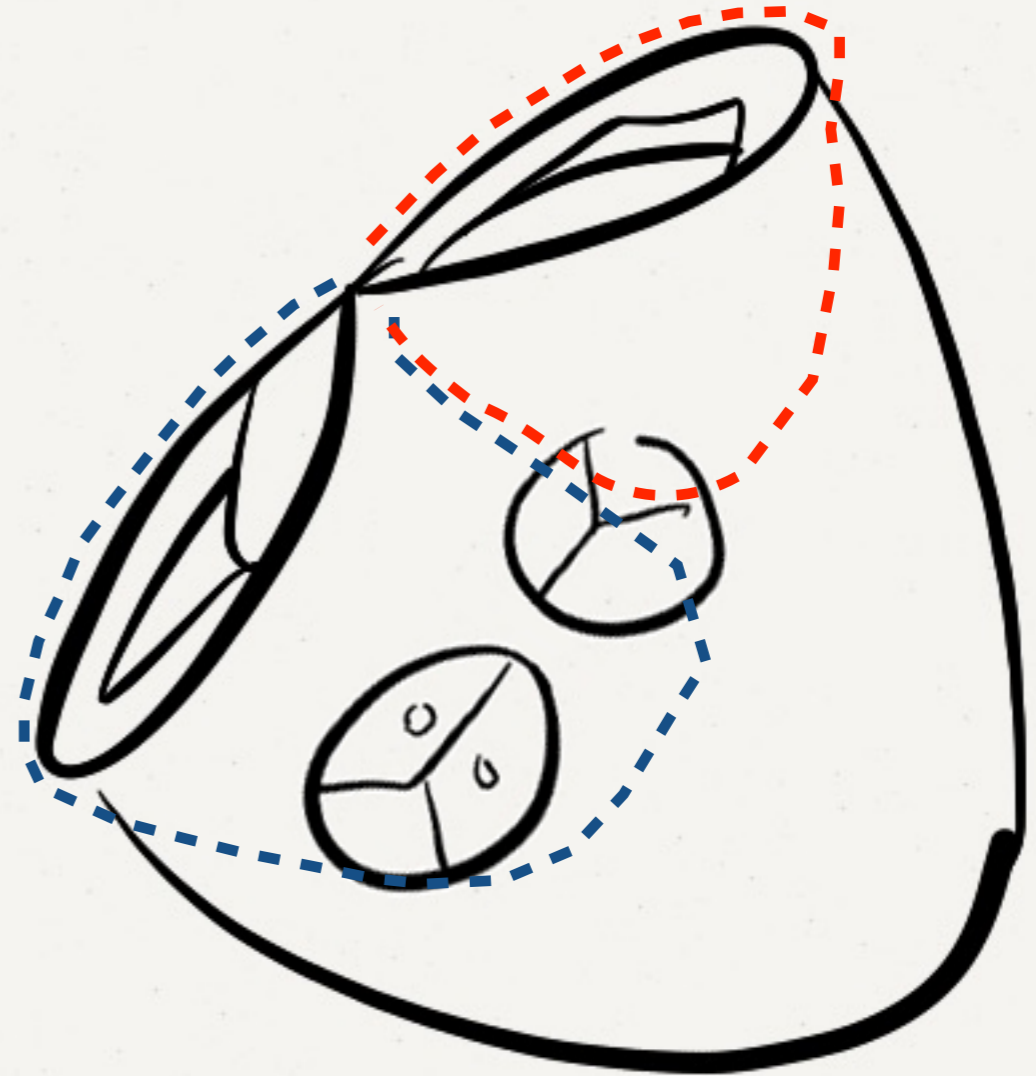
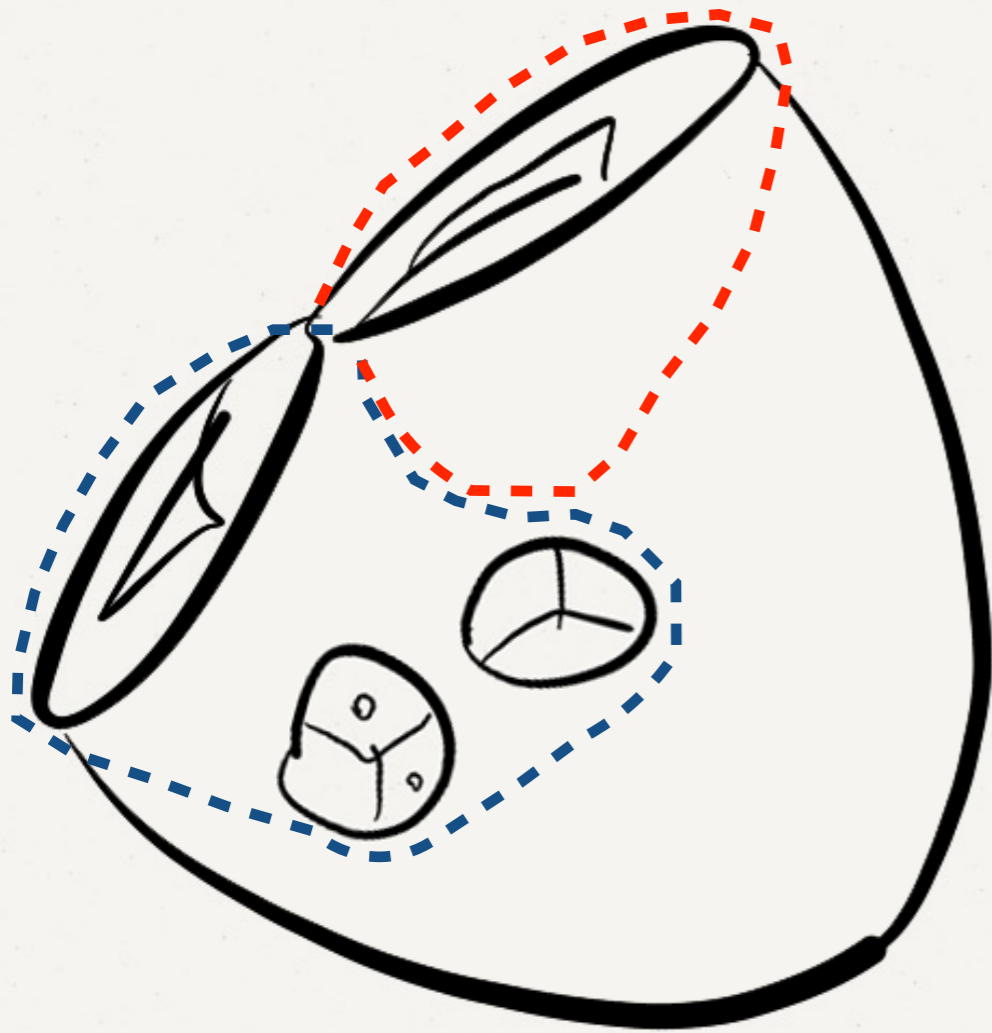
- Crista supraventricularis: Presence vs Absence
- Ventriculoinfundibular fold (VIF): Presence or Absence
- Discontinuity vs Continuity between AV and VA valves
- Infundibulum: Presence vs Absence

INFUNDIBULUM: What is it?



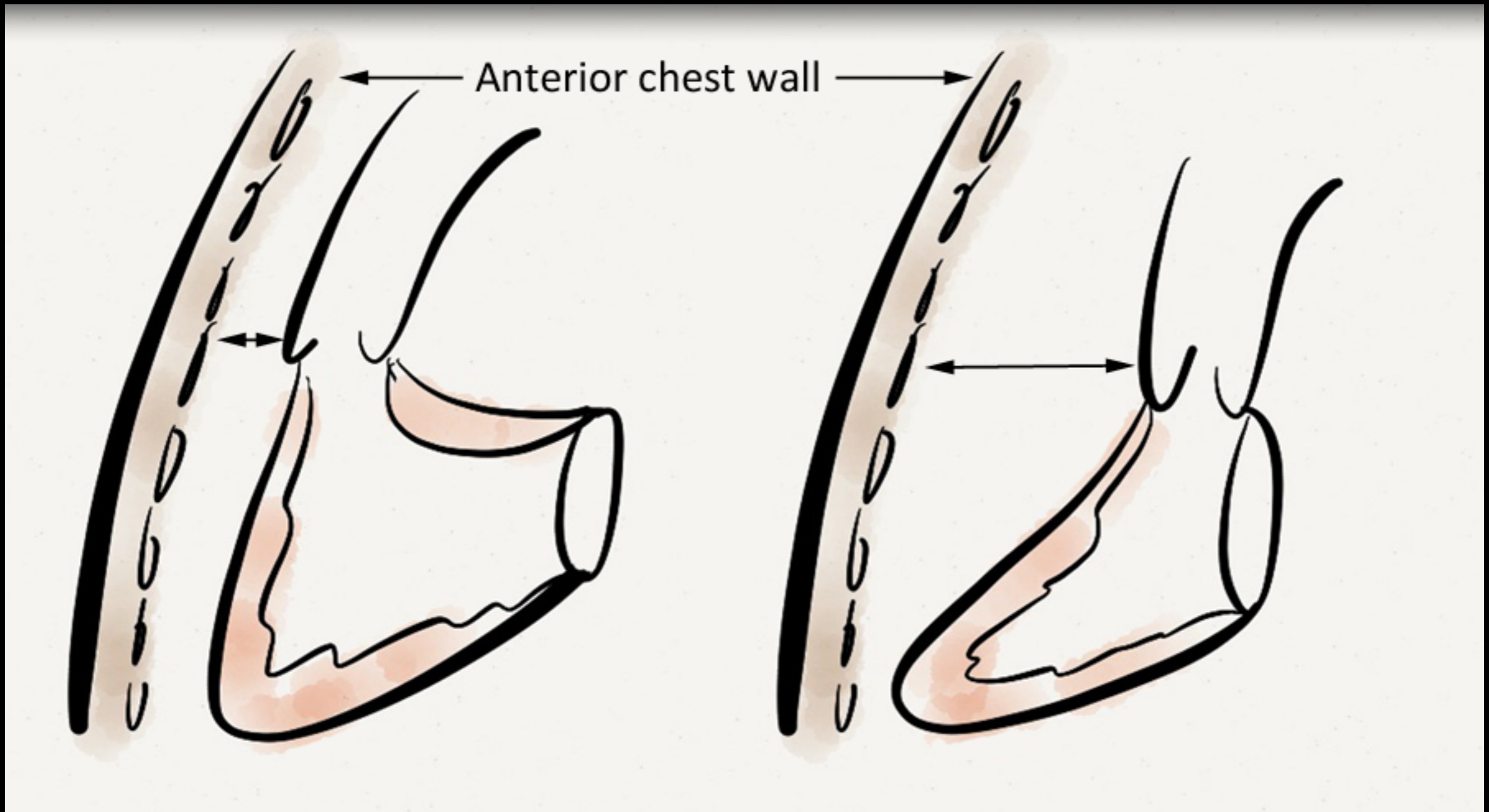
- Crista supraventricularis: Presence vs Absence
- Ventriculoinfundibular fold (VIF): Presence or Absence
- Discontinuity vs Continuity between AV and VA valves
- Infundibulum: Presence vs Absence

Having an infundibulum:

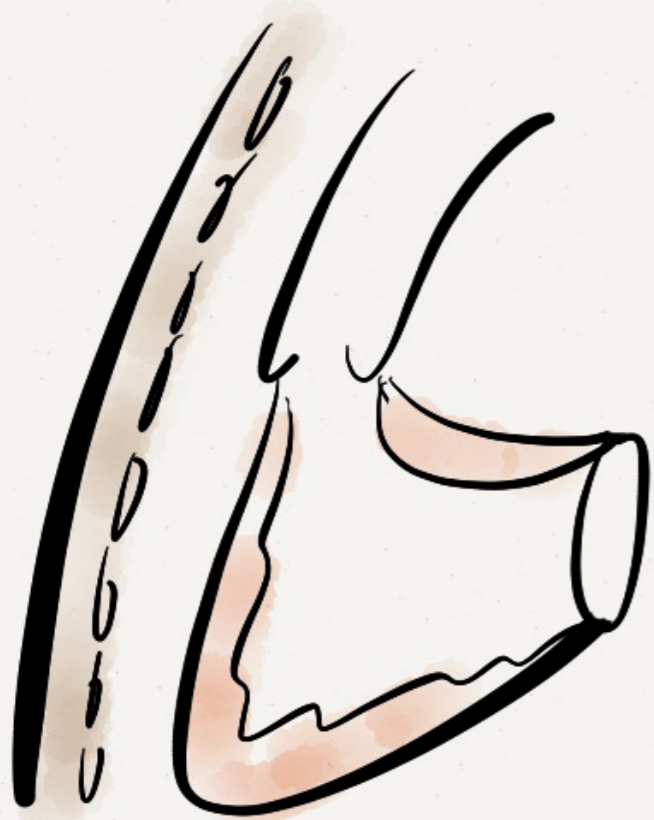

- Forward and upward displacement of the arterial trunk supported by the infundibulum so that it is related / connected to the anteriorly located ventricular chamber

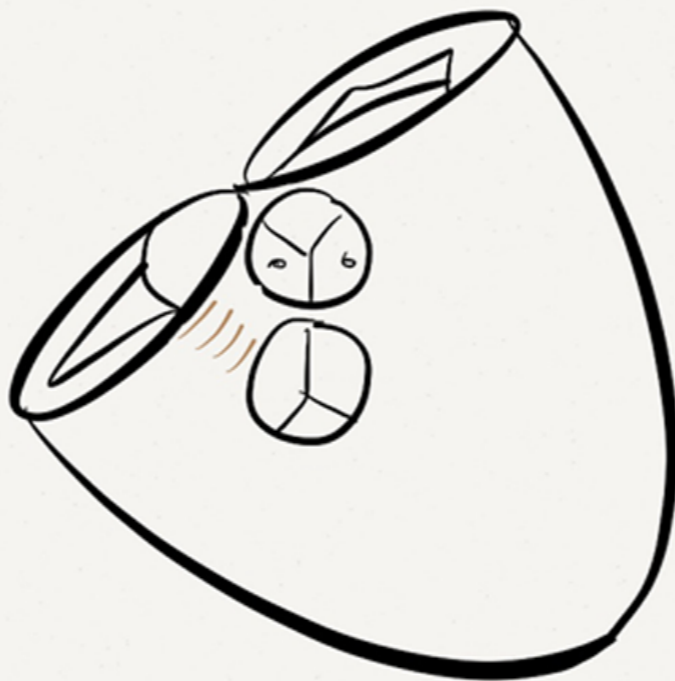
Having an infundibulum:



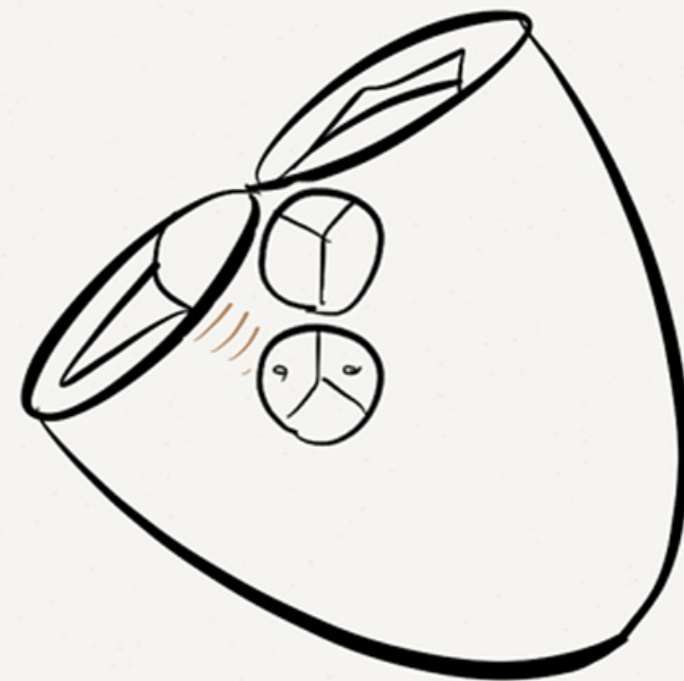
- Forward and upward displacement of the arterial trunk supported by the infundibulum so that it is related / connected to the anteriorly located ventricular chamber



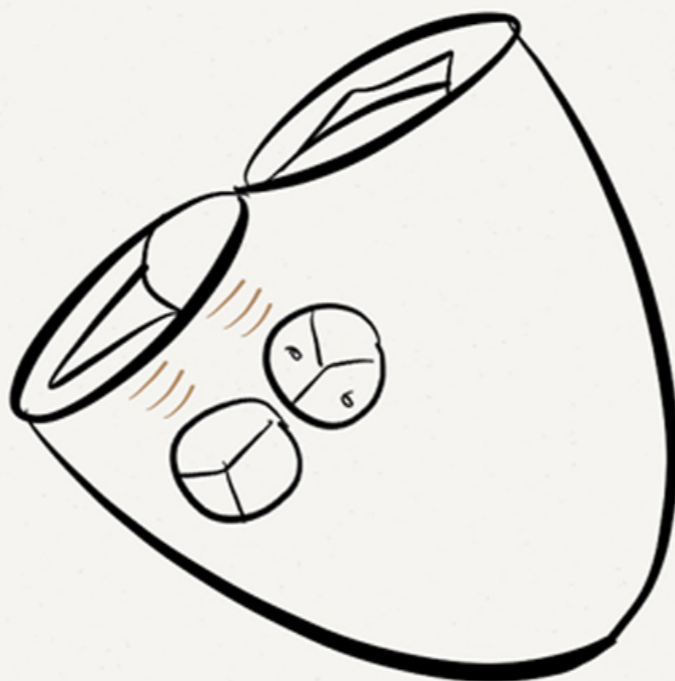
Subpulmonary
infundibulum



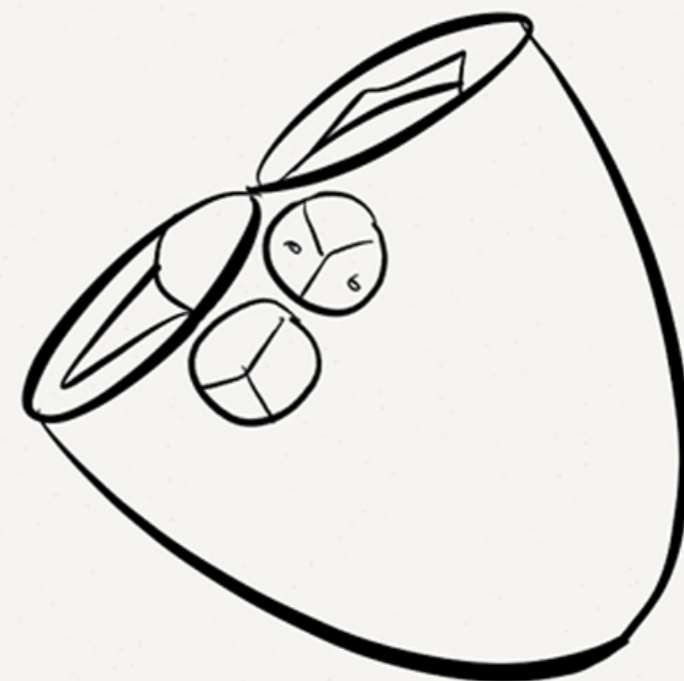
Subaortic
infundibulum

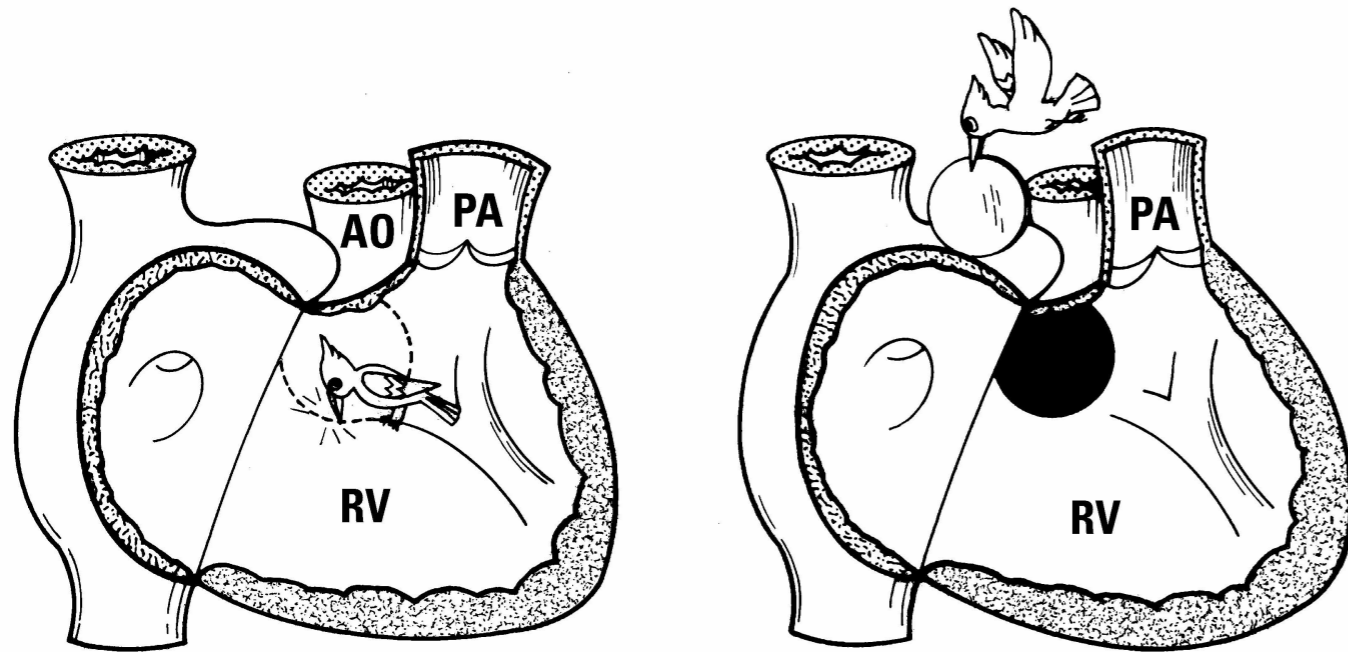


Bilateral
infundibulum

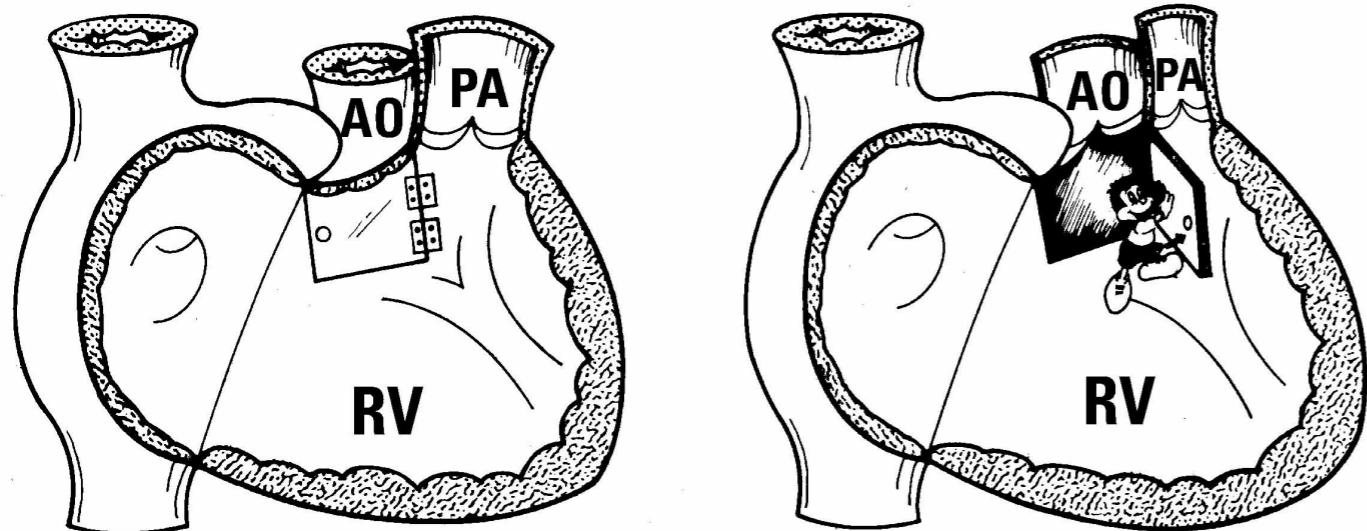


Bilaterally deficient
infundibulum





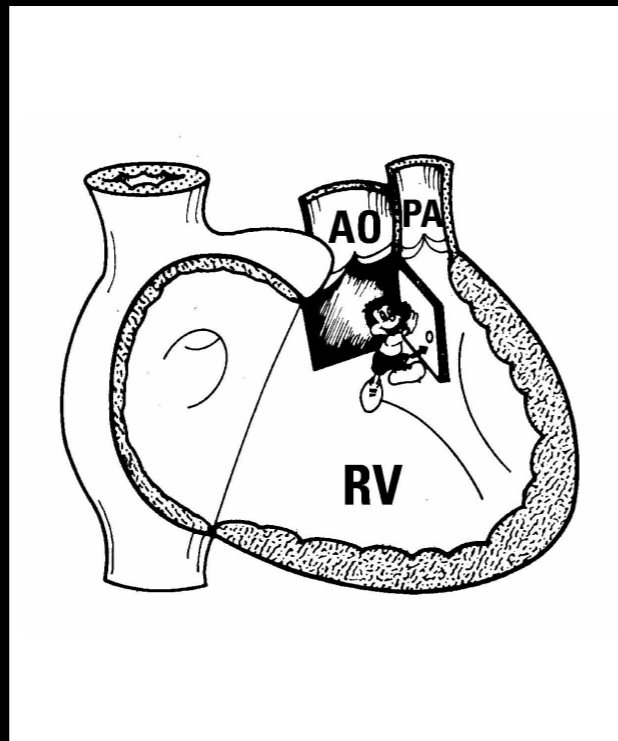
VSD AS A SIMPLE HOLE



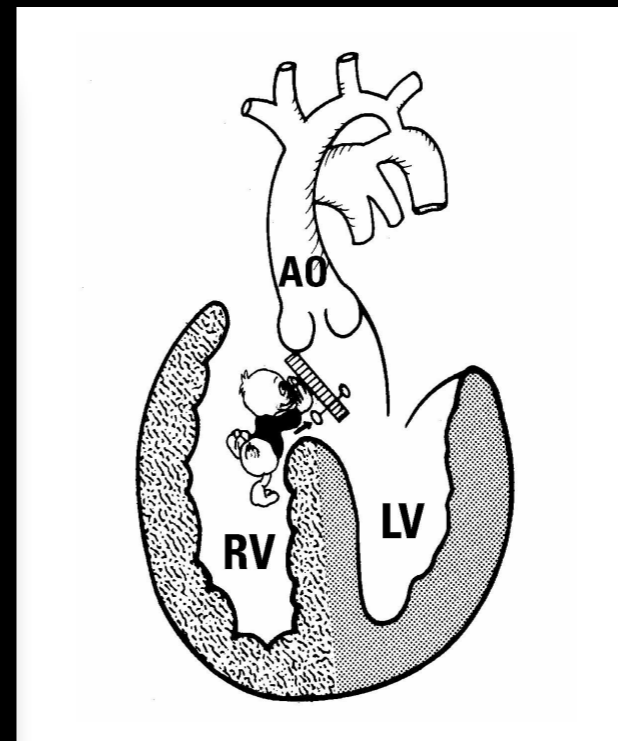
MALALIGNMENT TYPE VSD

MALALIGNMENT TYPE VSD'S

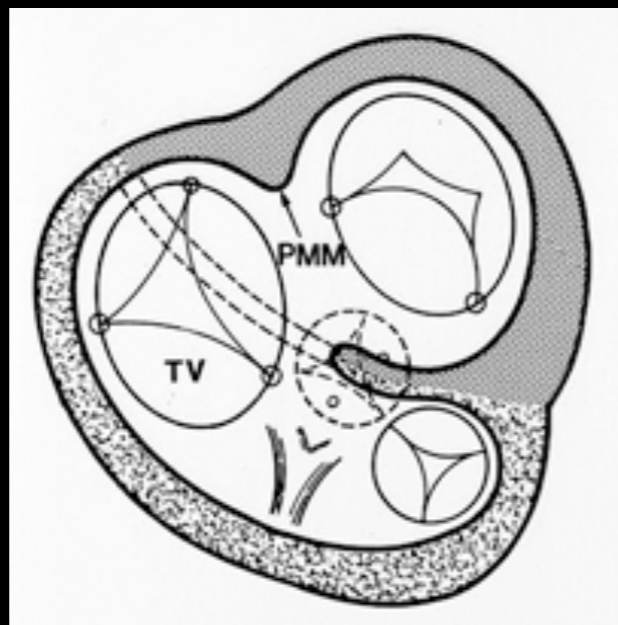
Tetralogy of Fallot



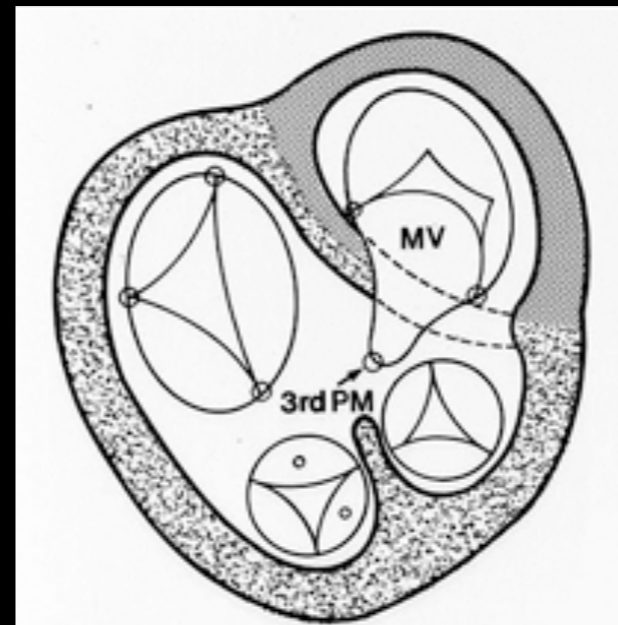
Aortic arch interruption or coarctation



Tricuspid valve straddling & overriding



Mitral valve straddling & overriding



SEPTAL MALALIGNMENT

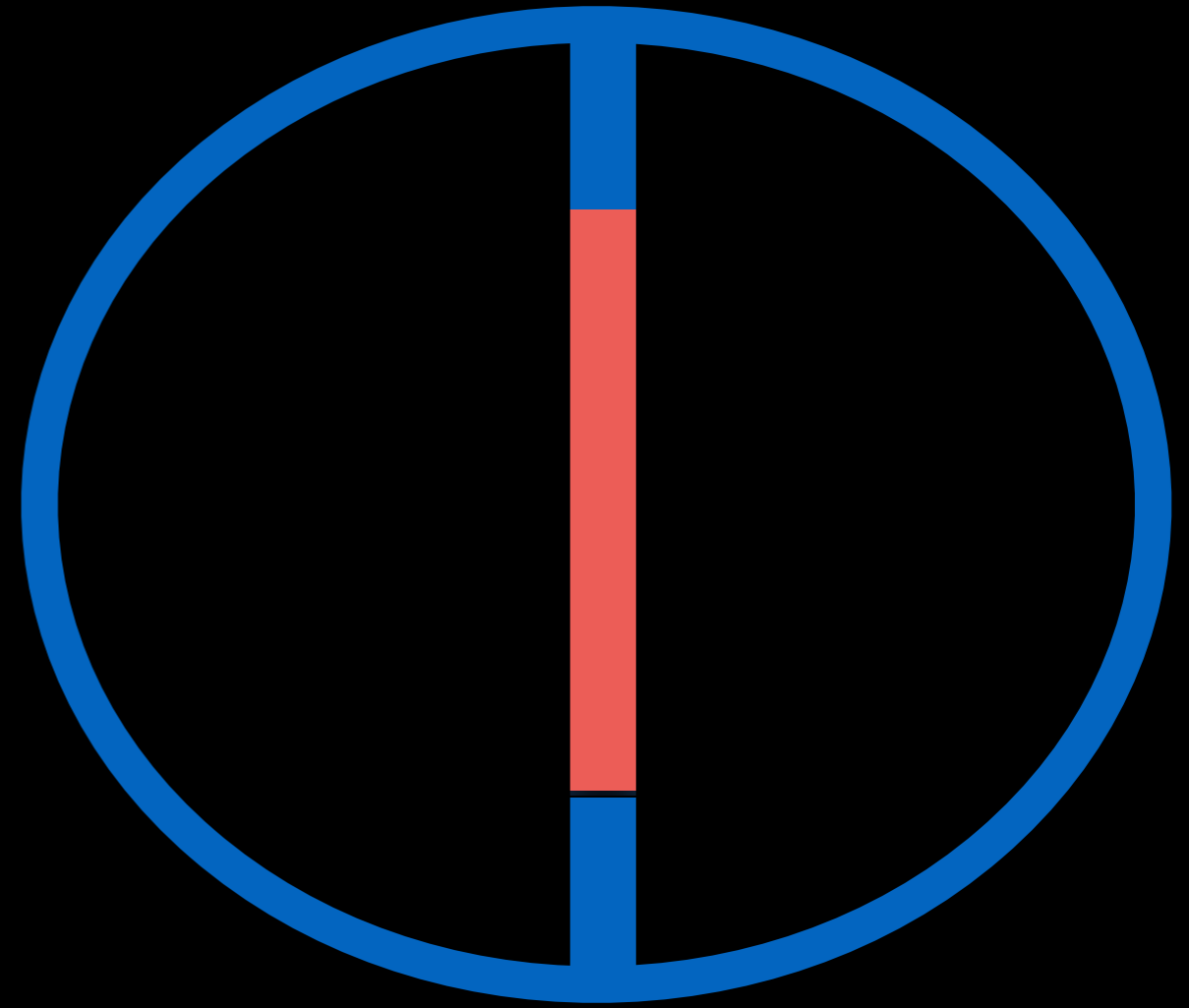
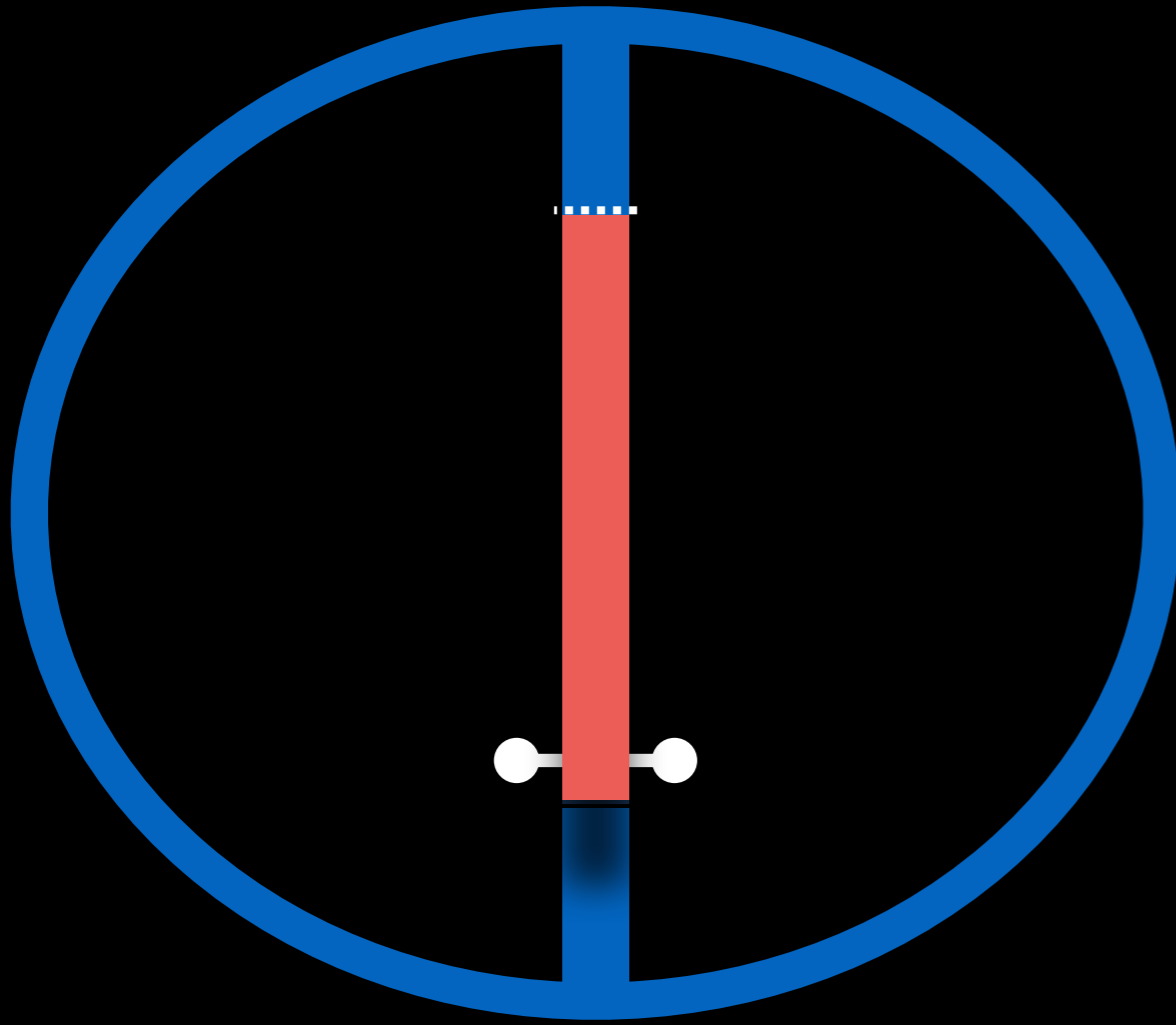
-Essential features to define-

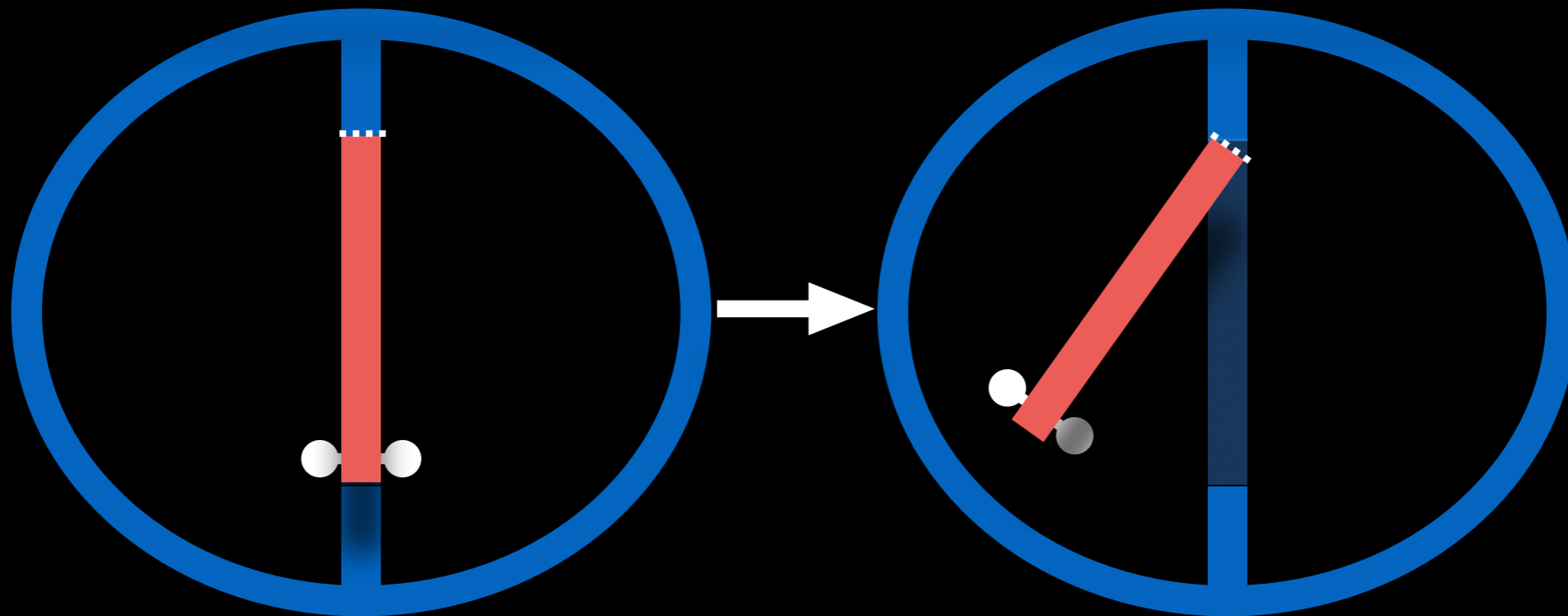
- Malaligned part of the septum
- Mechanisms of malalignment
- Reference structure: In relation to what?
- Direction of malalignment
- Extent of malalignment

MECHANISMS OF MALALIGNMENT

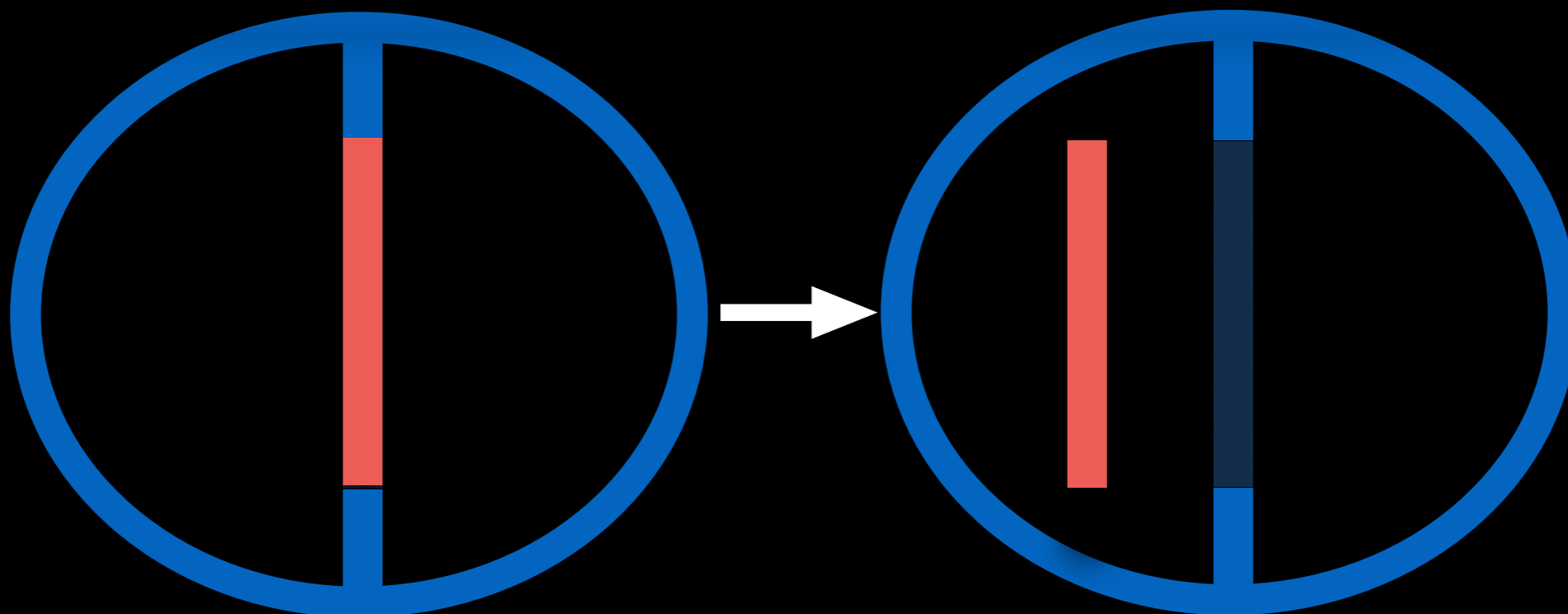
Flap door mechanism

En bloc displacement





Flap-door mechanism

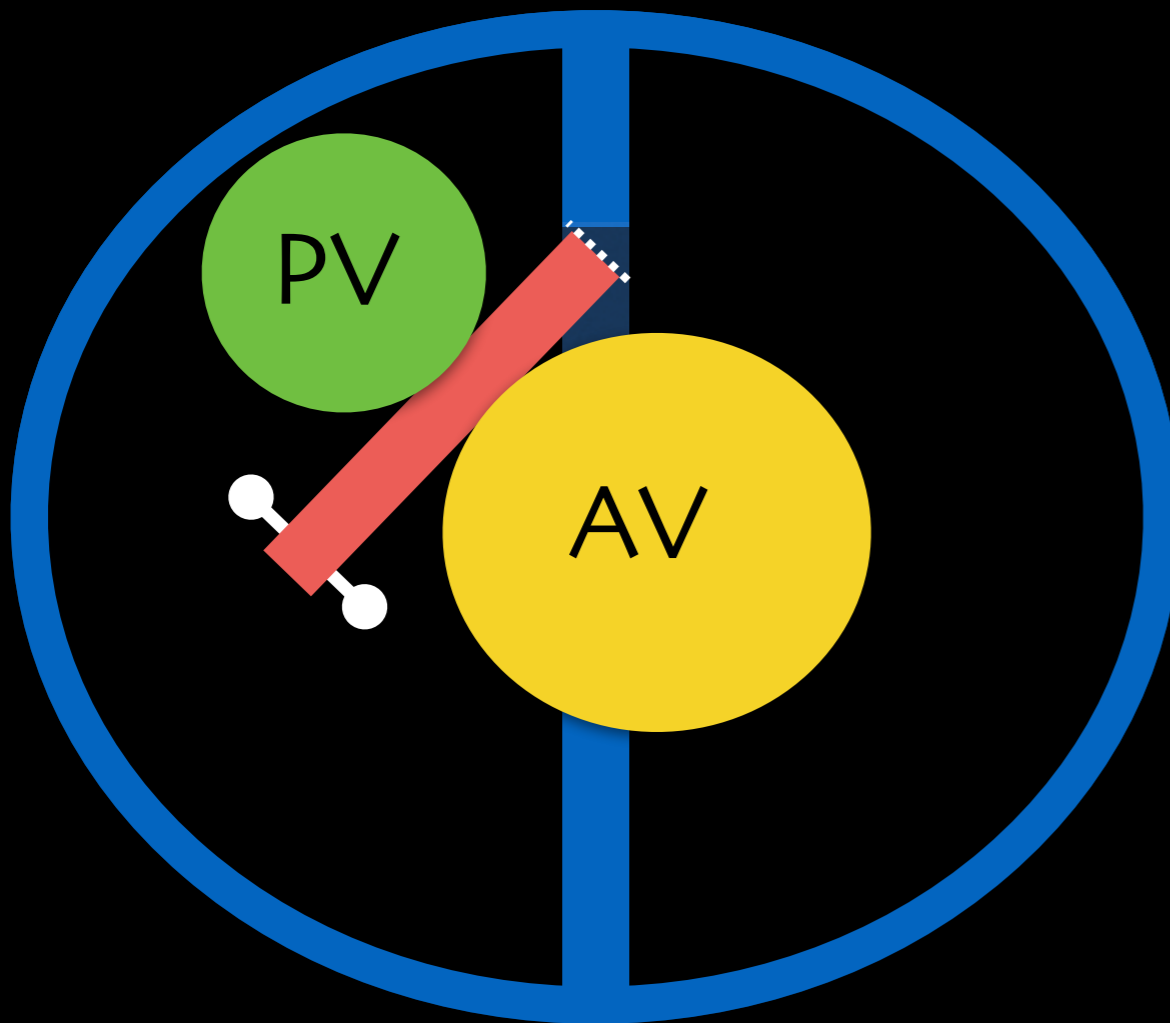


En bloc displacement

MECHANISMS OF MALALIGNMENT

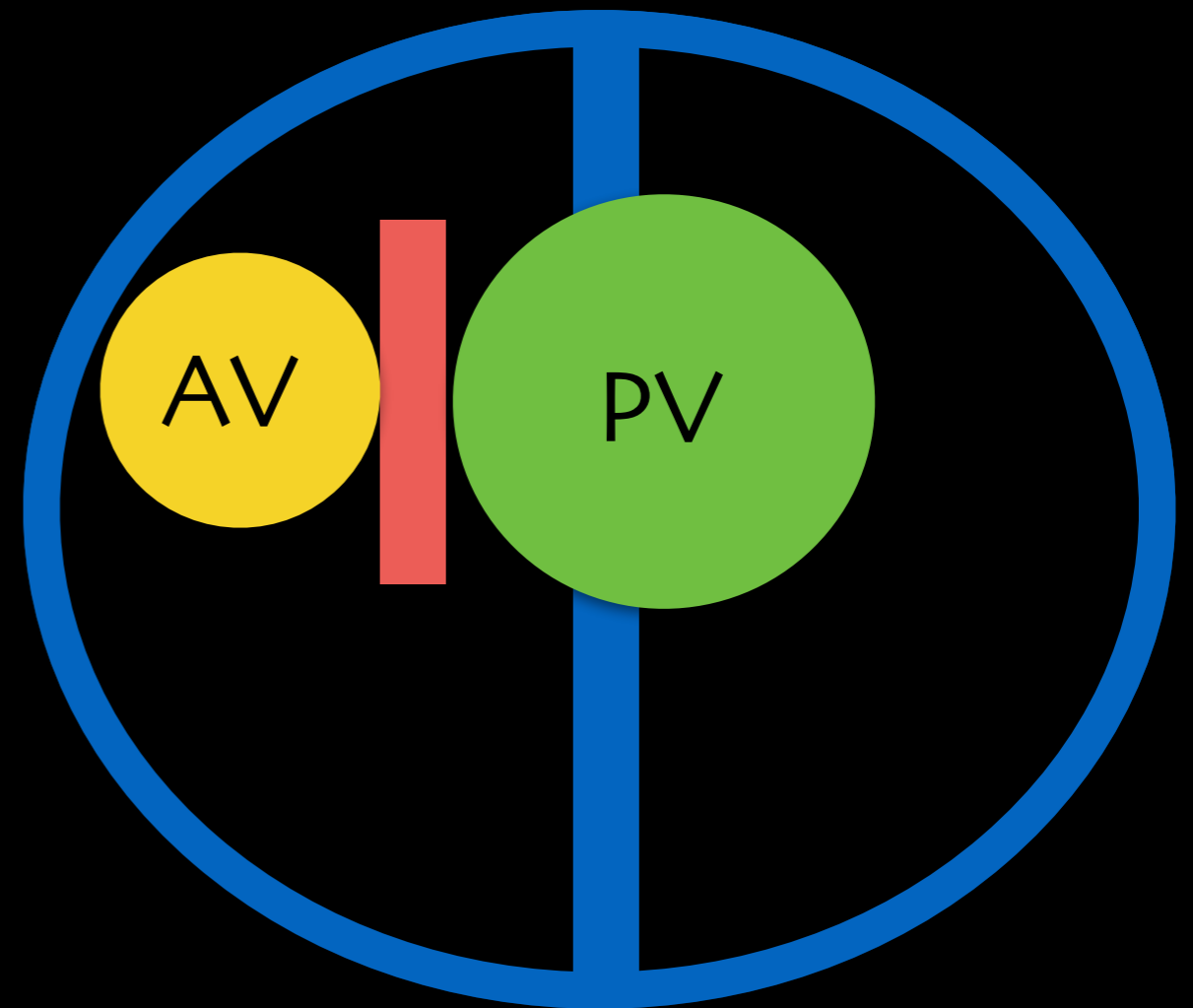
OUTLET SEPTAL MALALIGNMENT

Flap door mechanism



Examples: TOF, DORVs

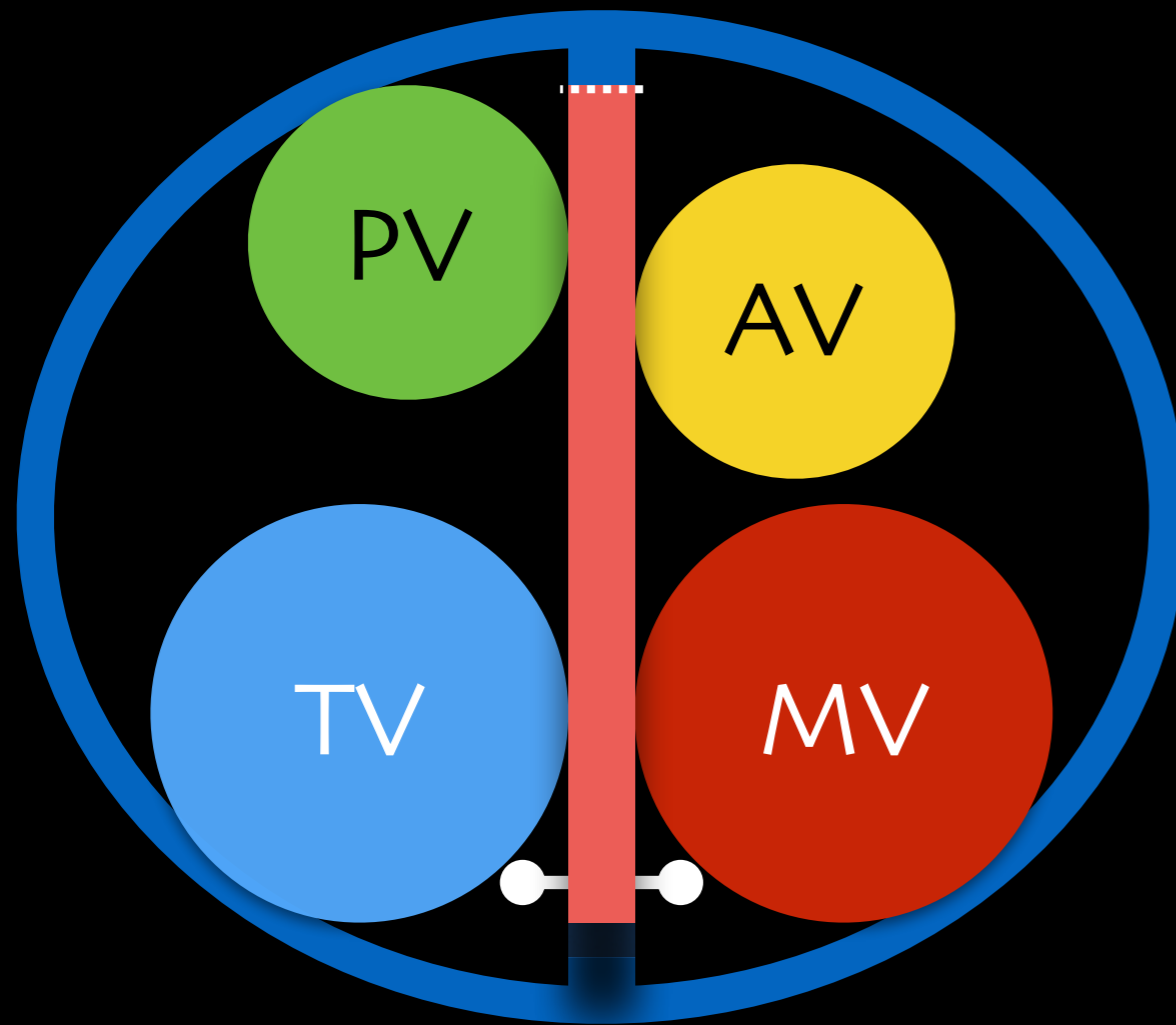
En bloc displacement



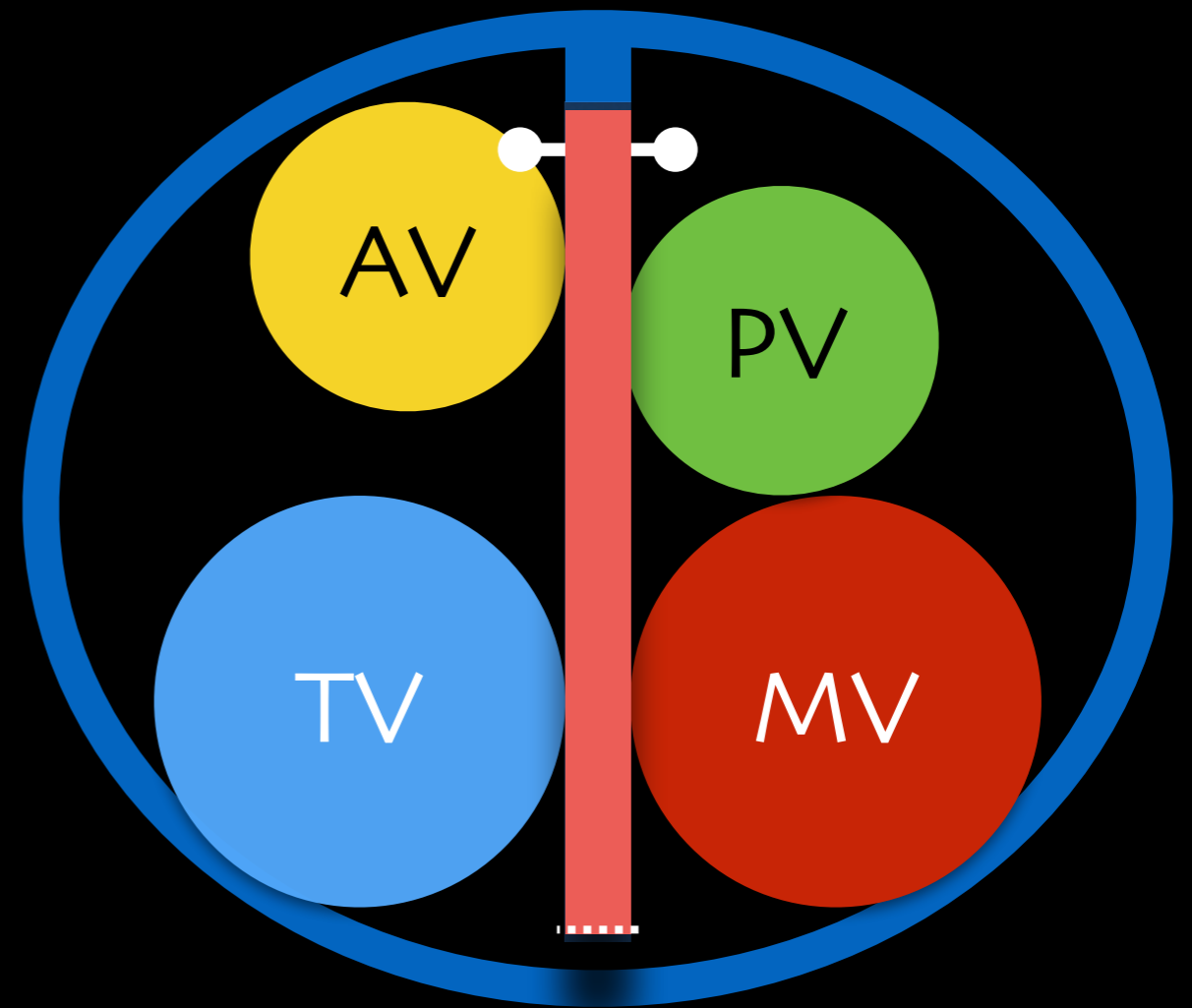
DORV
(Some of Taussig-Bing's)

MECHANISMS OF MALALIGNMENT

Straddling / Overriding AV Valves
Flap door mechanism



Pulmonary stenosis



DORV

SEPTAL MALALIGNMENT

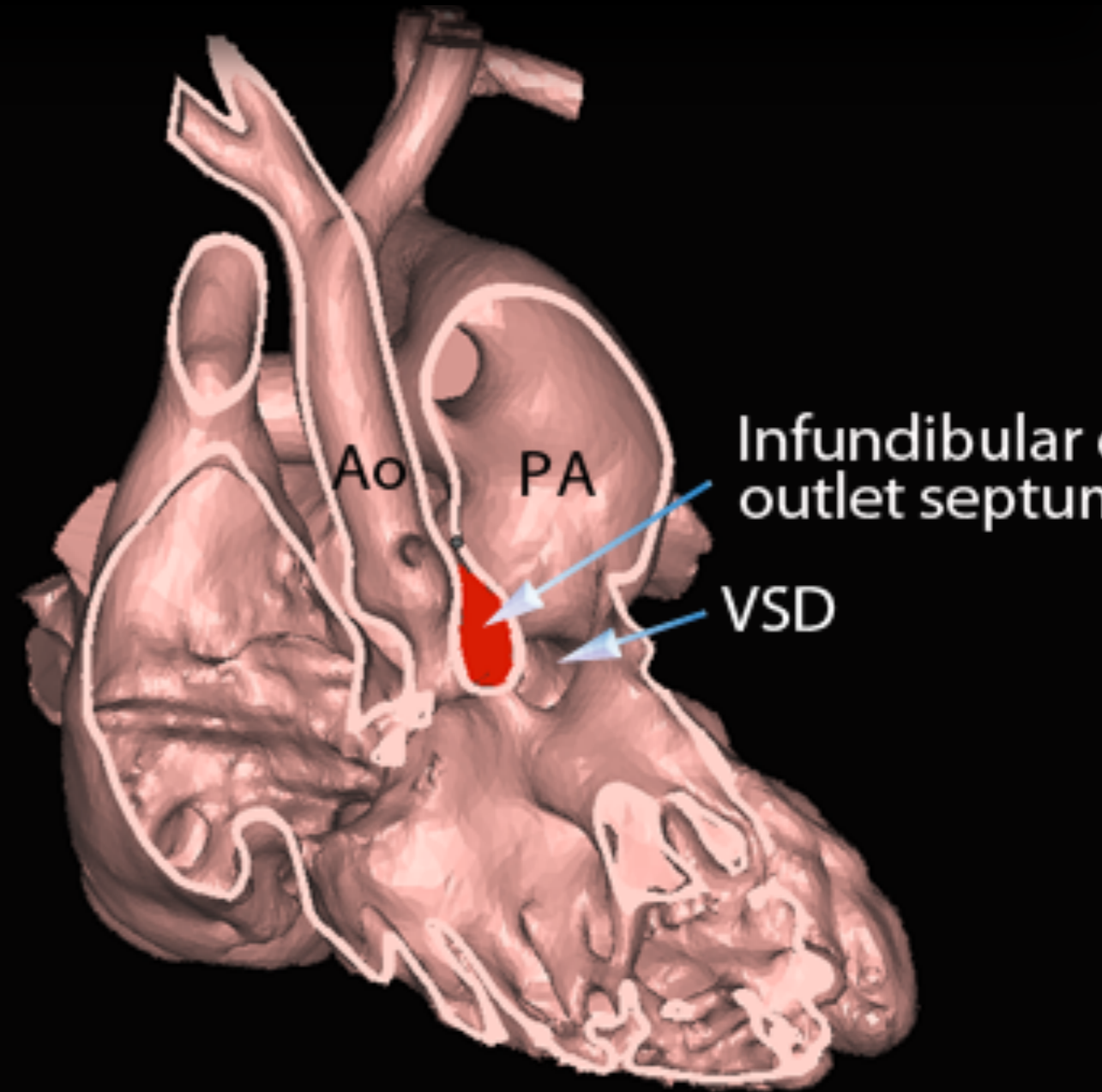
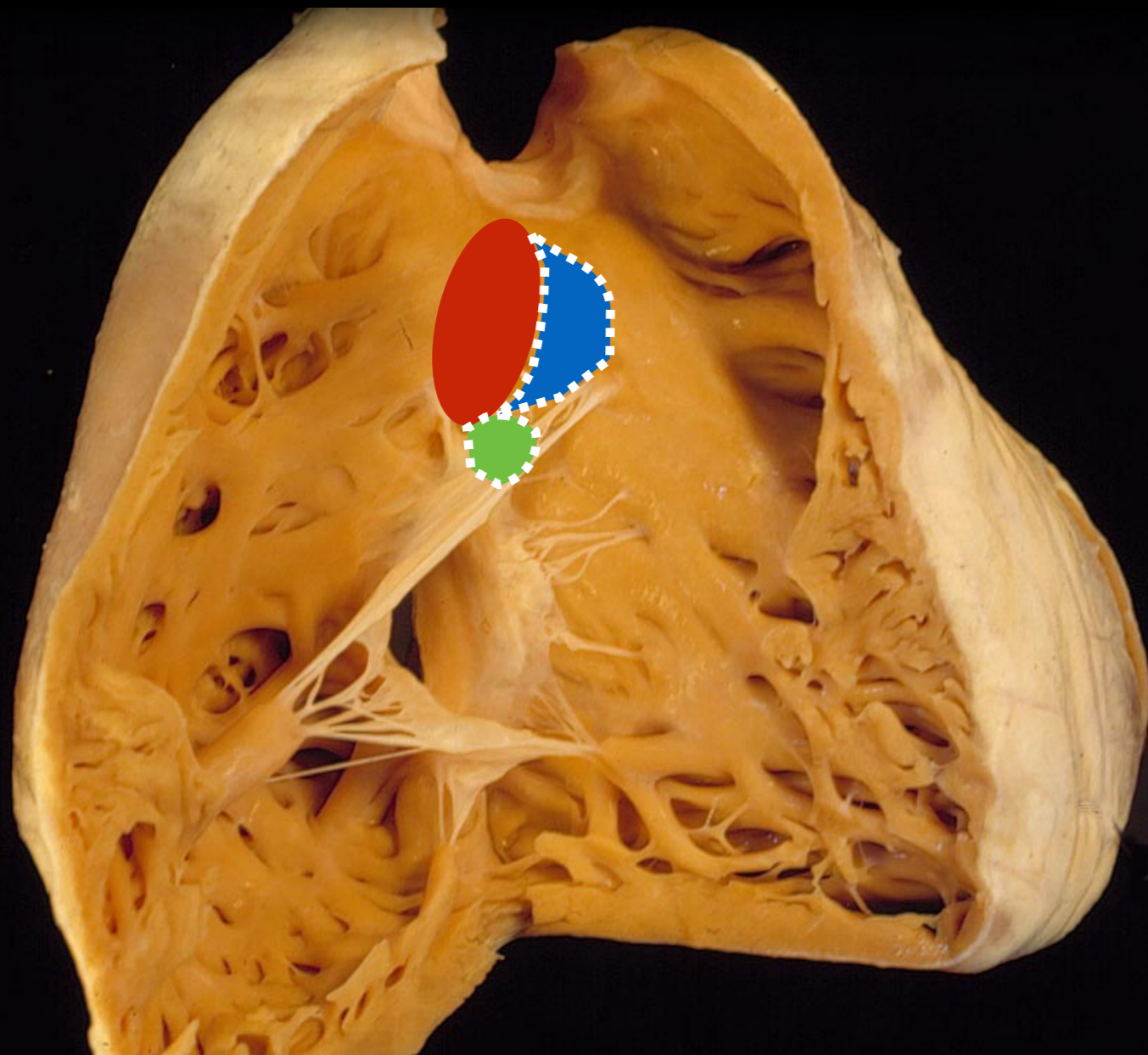
-Essential features to define-

- Malaligned part of the septum
- Mechanisms of malalignment
- Reference structure: In relation to what?
- Direction of malalignment
- Extent of malalignment

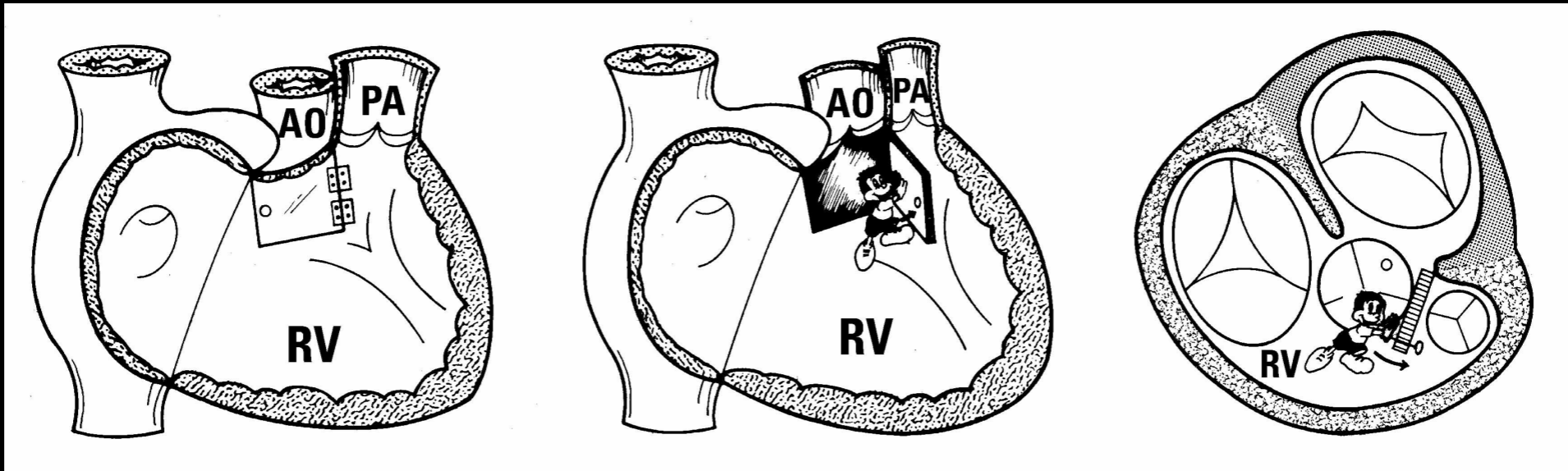
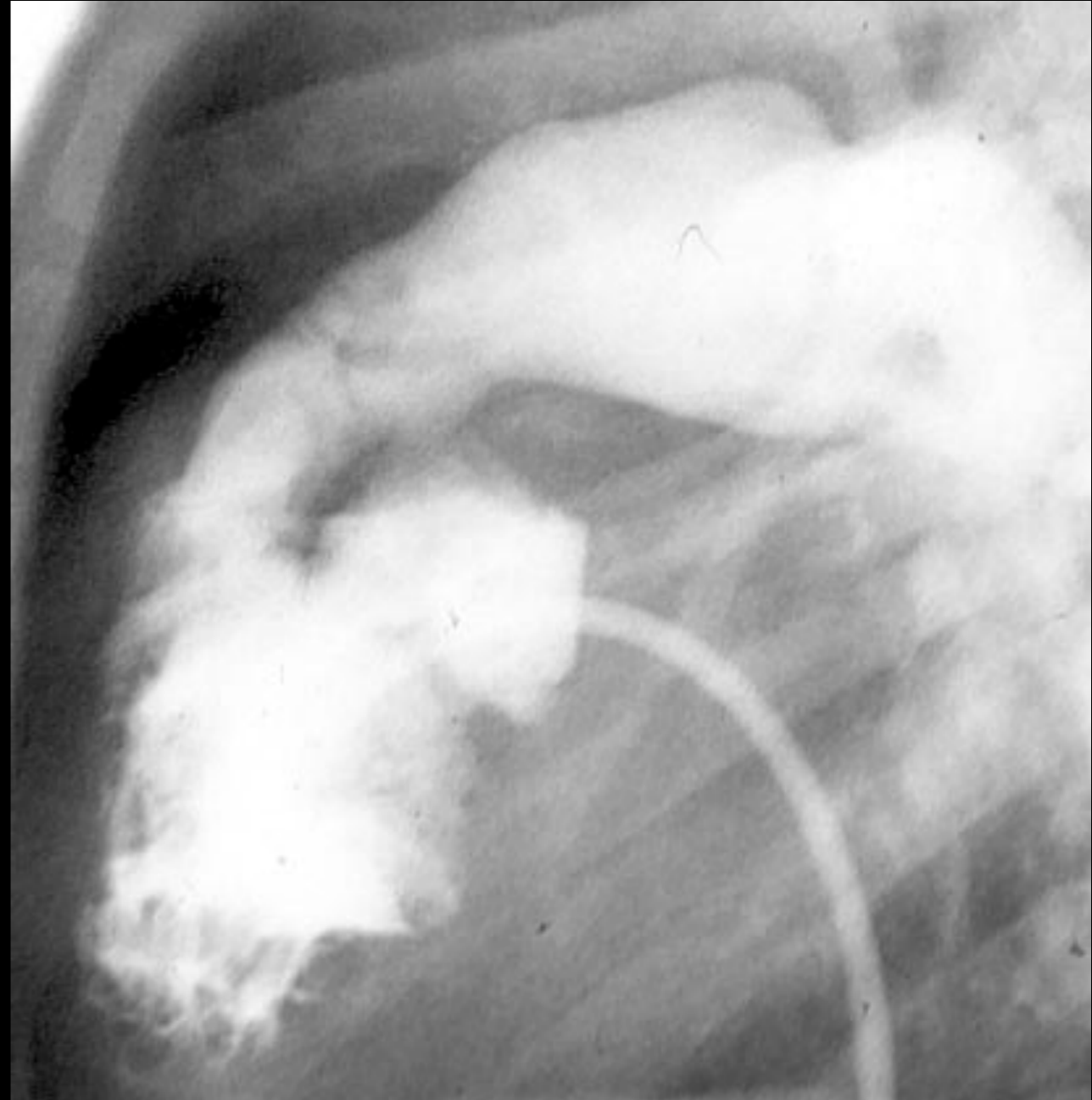
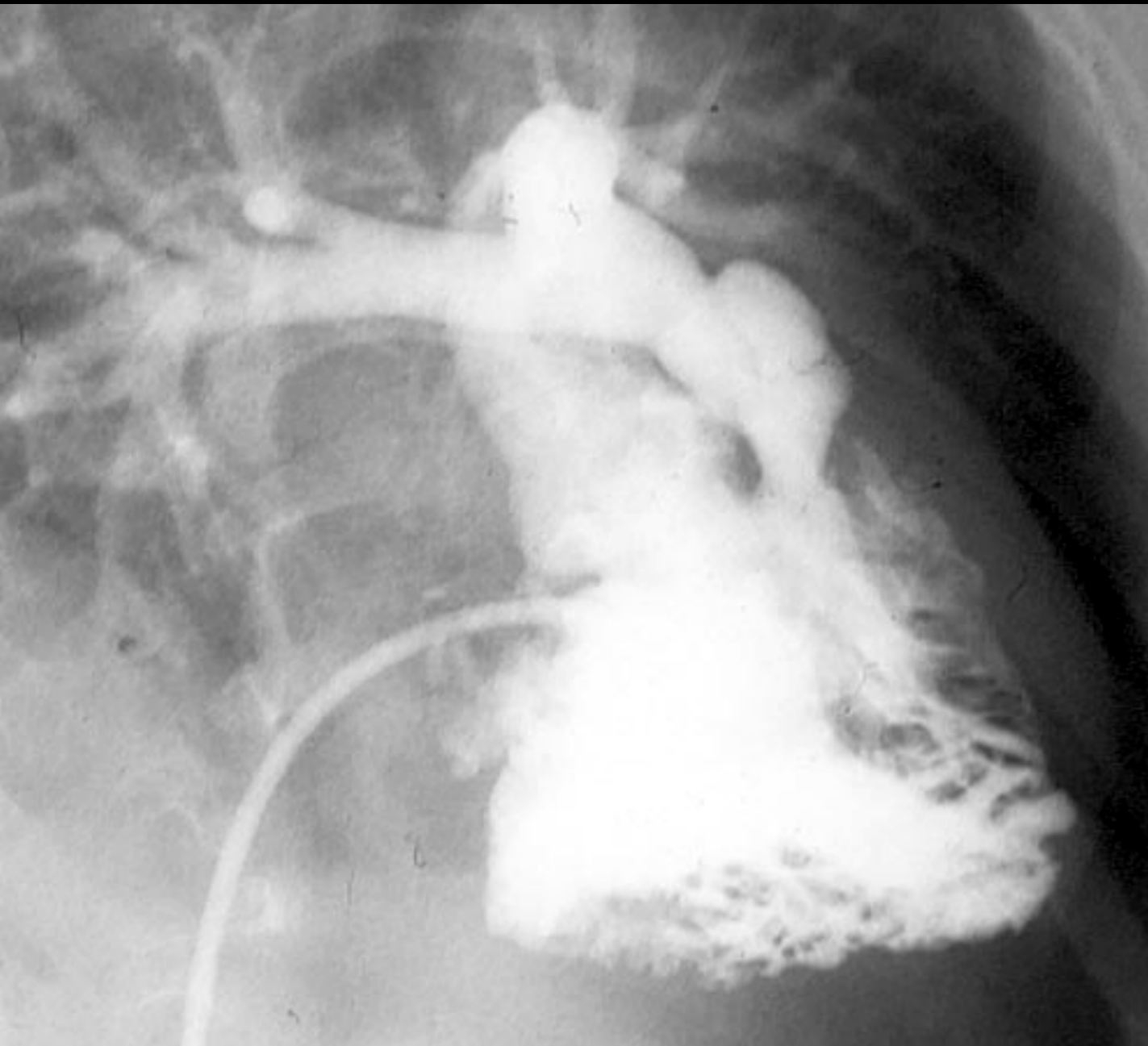
OUTLET SEPTAL MALALIGNMENT

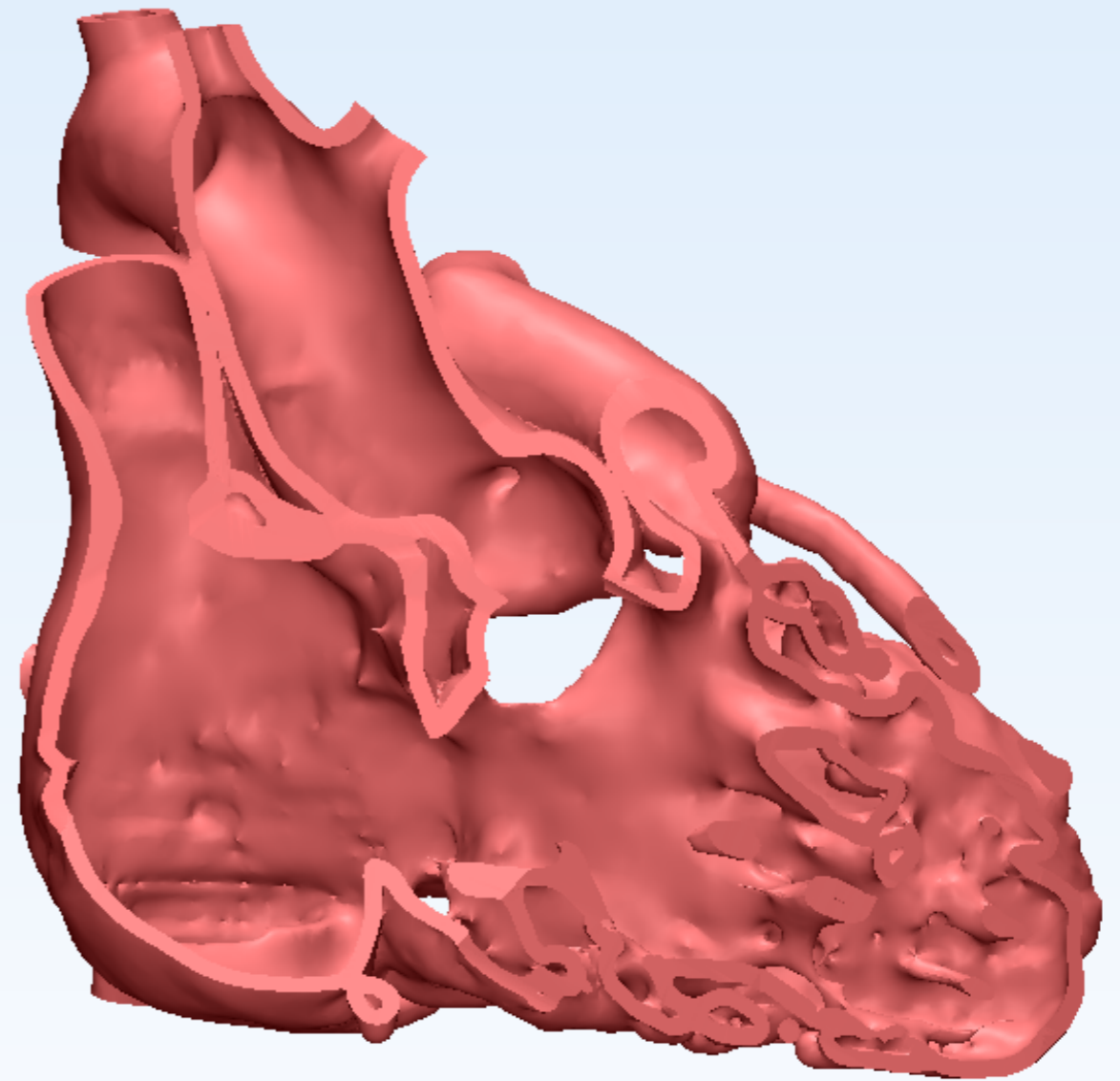
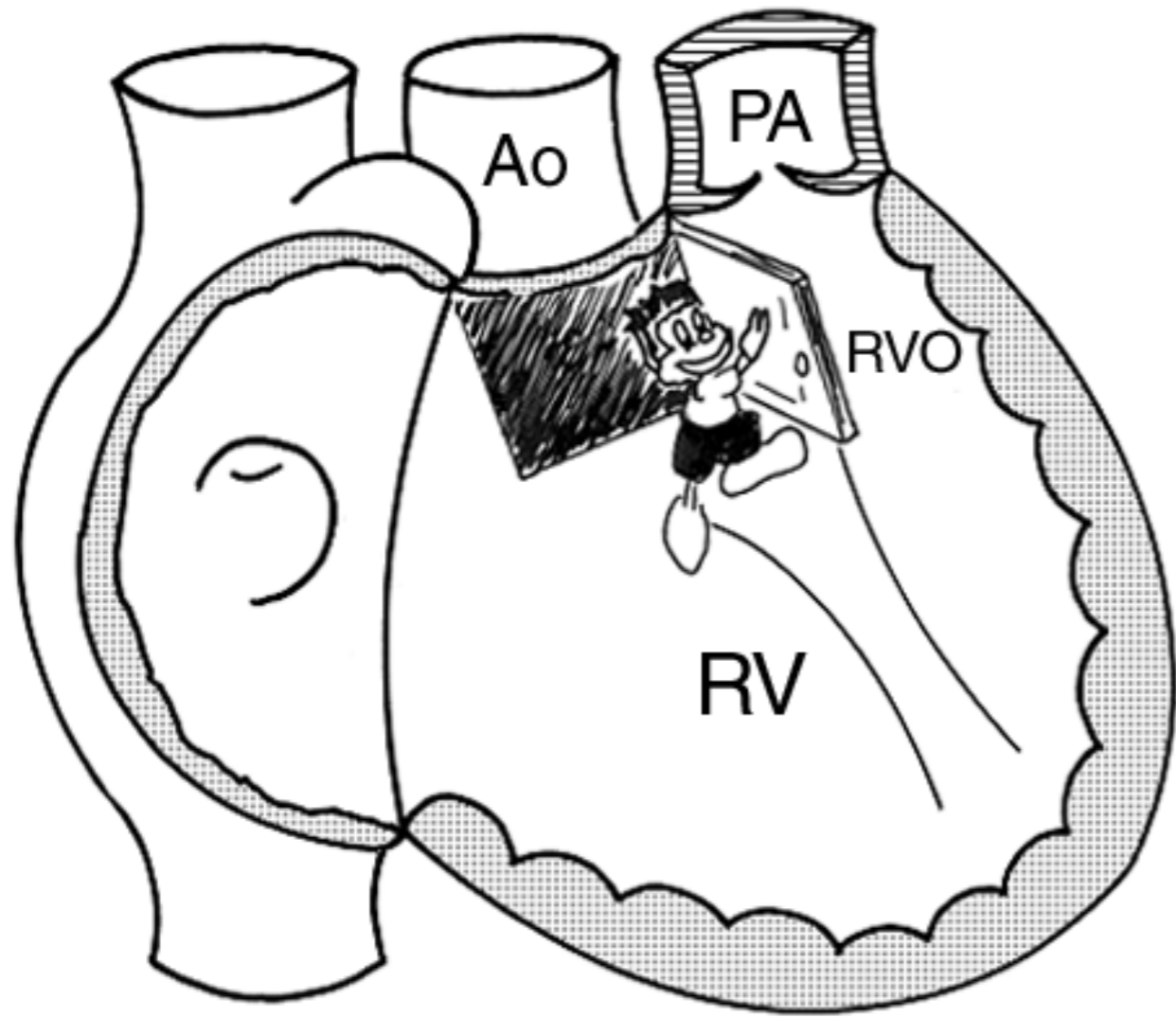
- TOF
- DORV
- DOLV
- COA type VSD

OUTLET SEPTUM

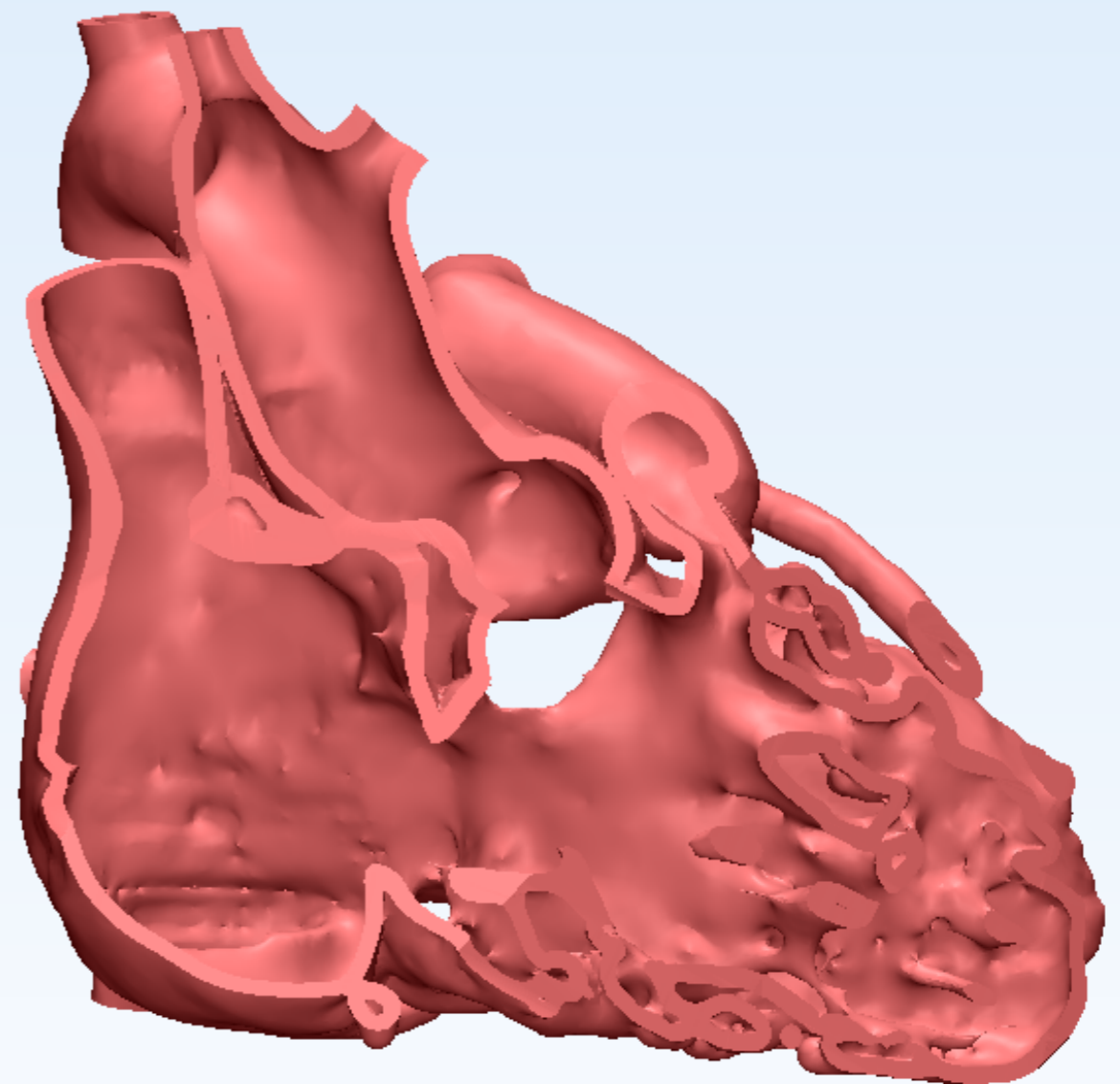
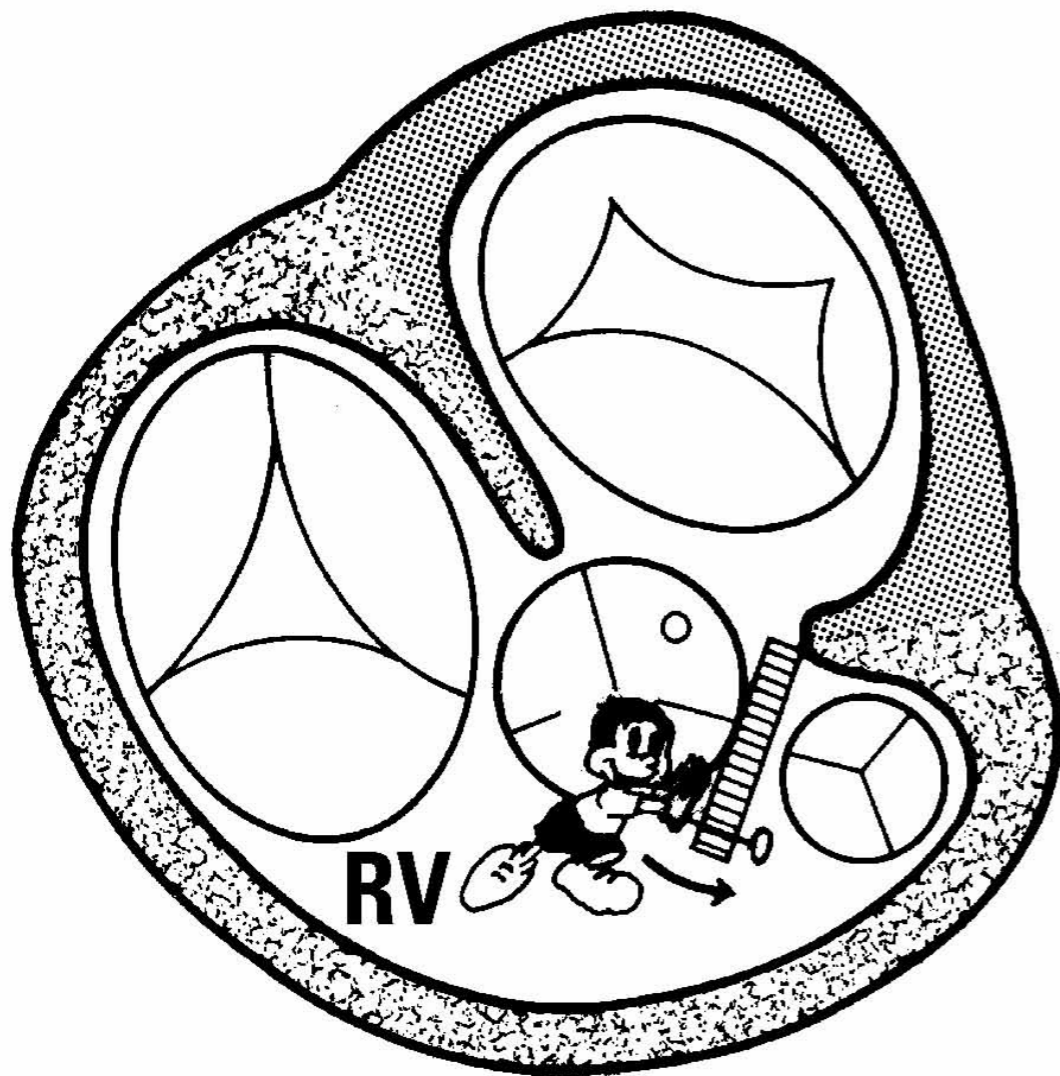


- Divides the right and left ventricular outflow tracts.
- Divides the subpulmonary and subaortic outflow tracts.





Leftward, anterior and superior deviation of the outlet septum relative to the rest of the septum.



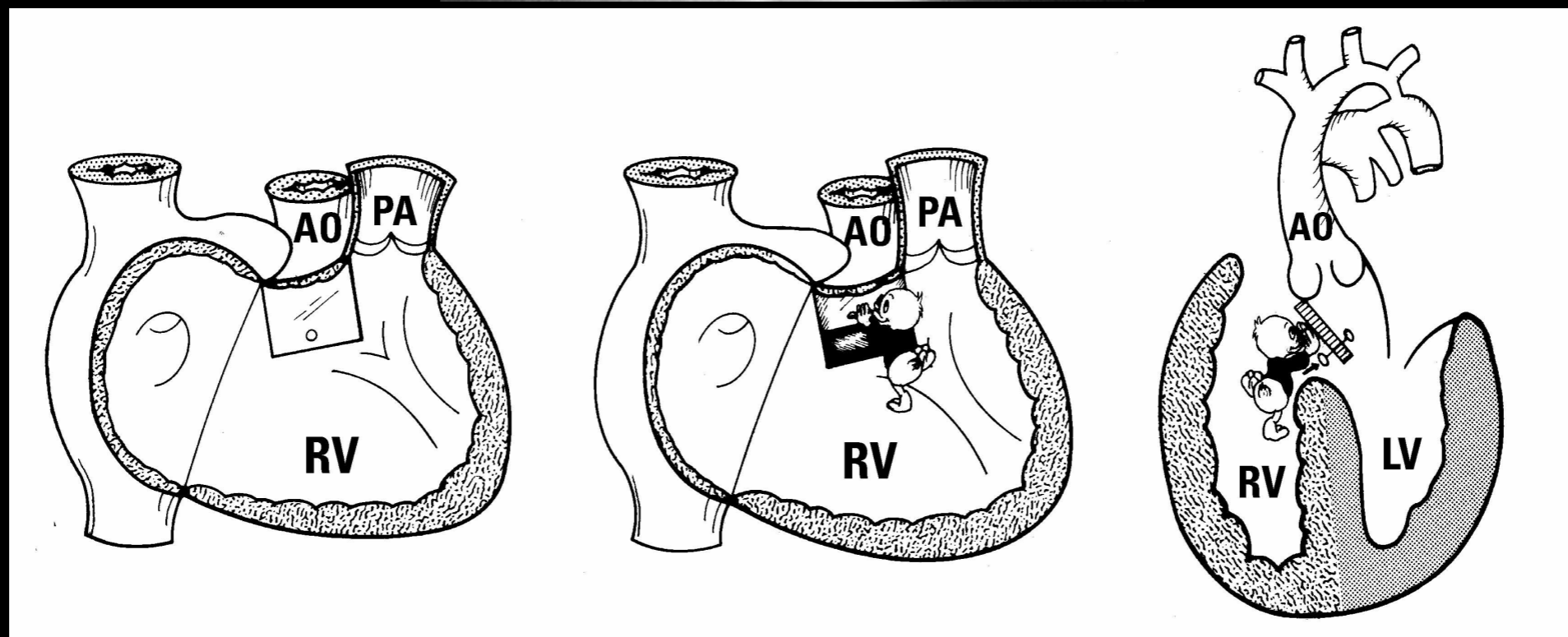
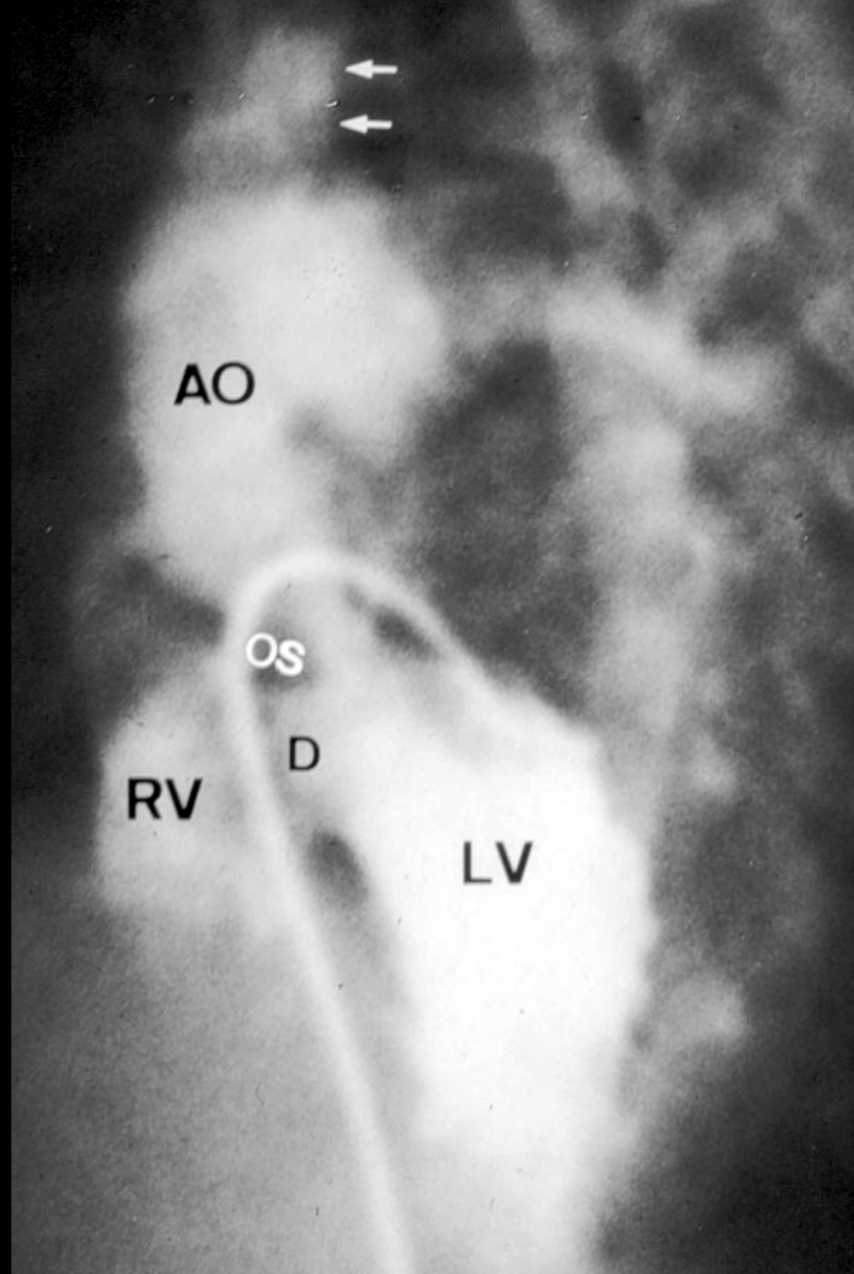
Malaligned part: Outlet septum

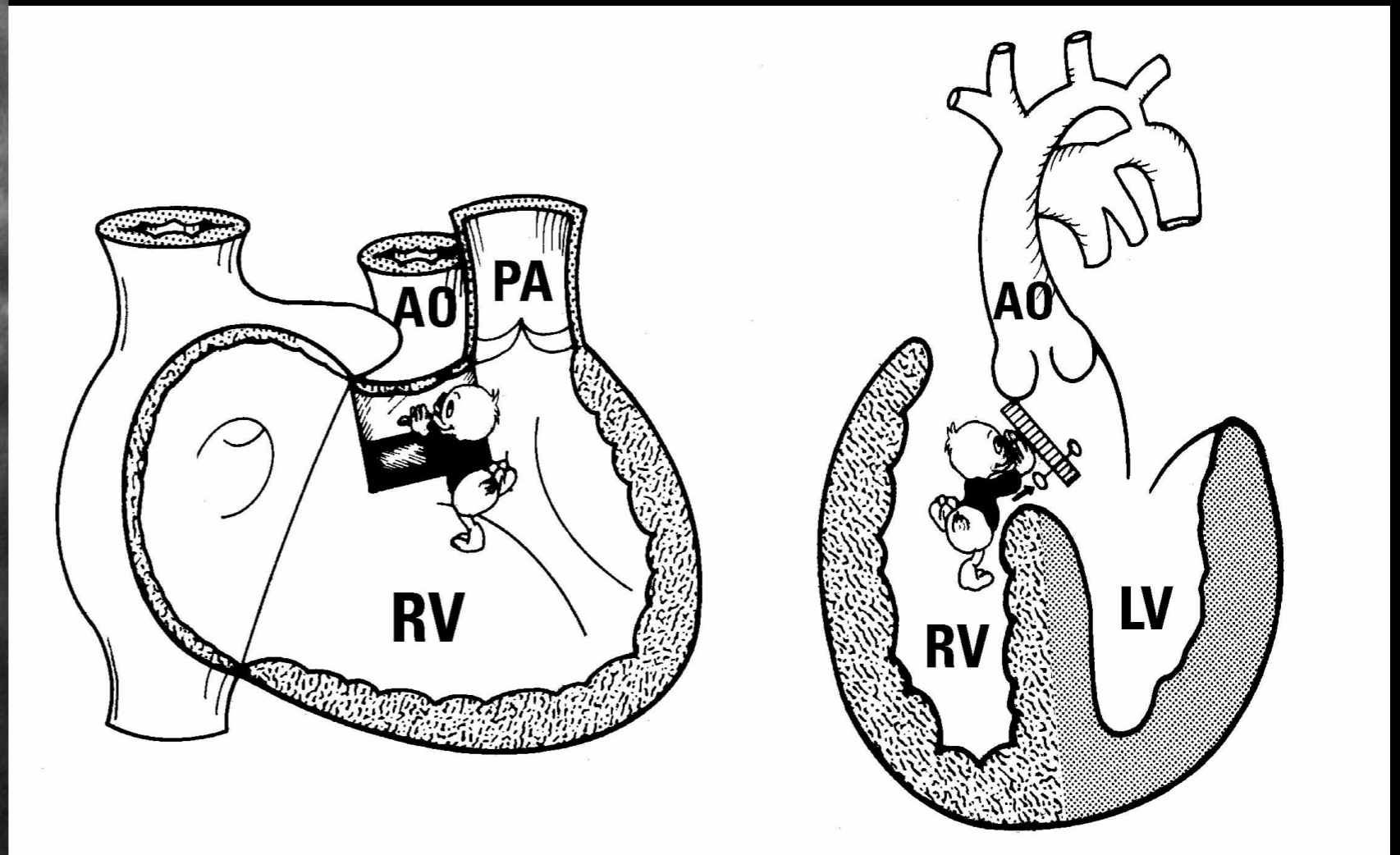
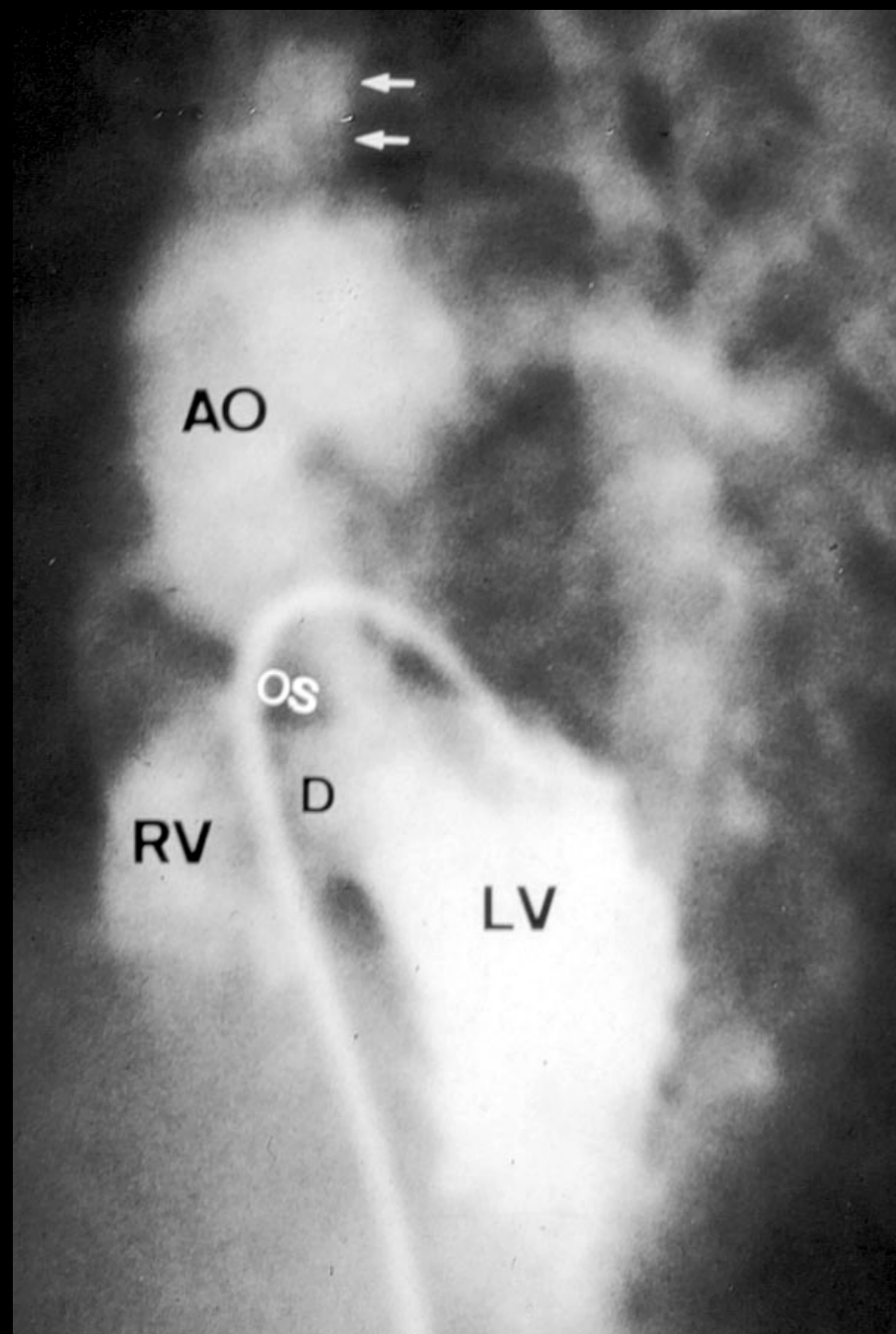
Mechanism: Flap door with hinge on the left

Reference structure: Rest of the ventricular septum

Direction: Leftward, anterior and superior

Extent: 80% aortic overriding and moderate to severe sub-pulmonary stenosis





Malaligned part: Outlet septum

Mechanism: Flap door hinge on the top

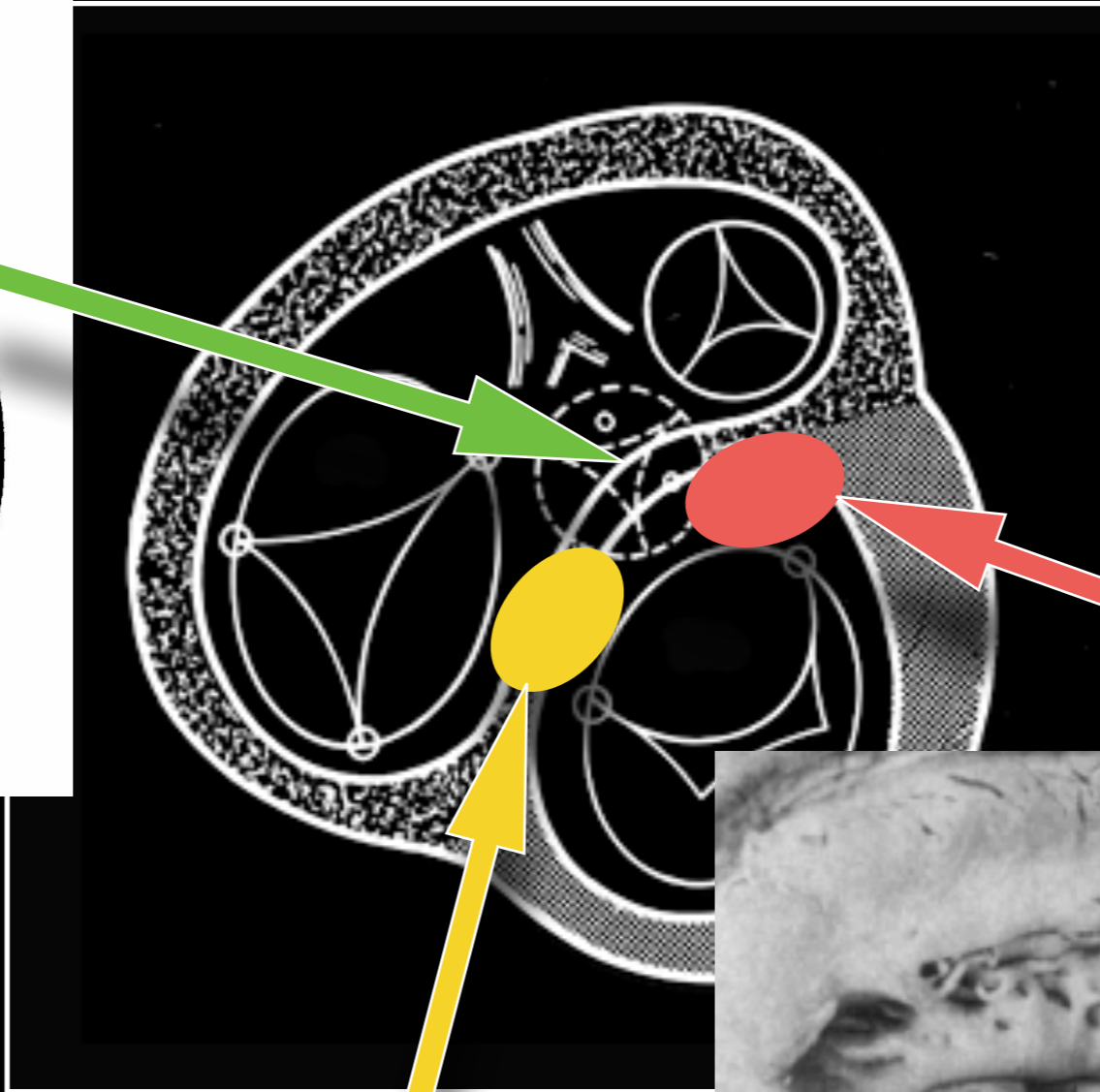
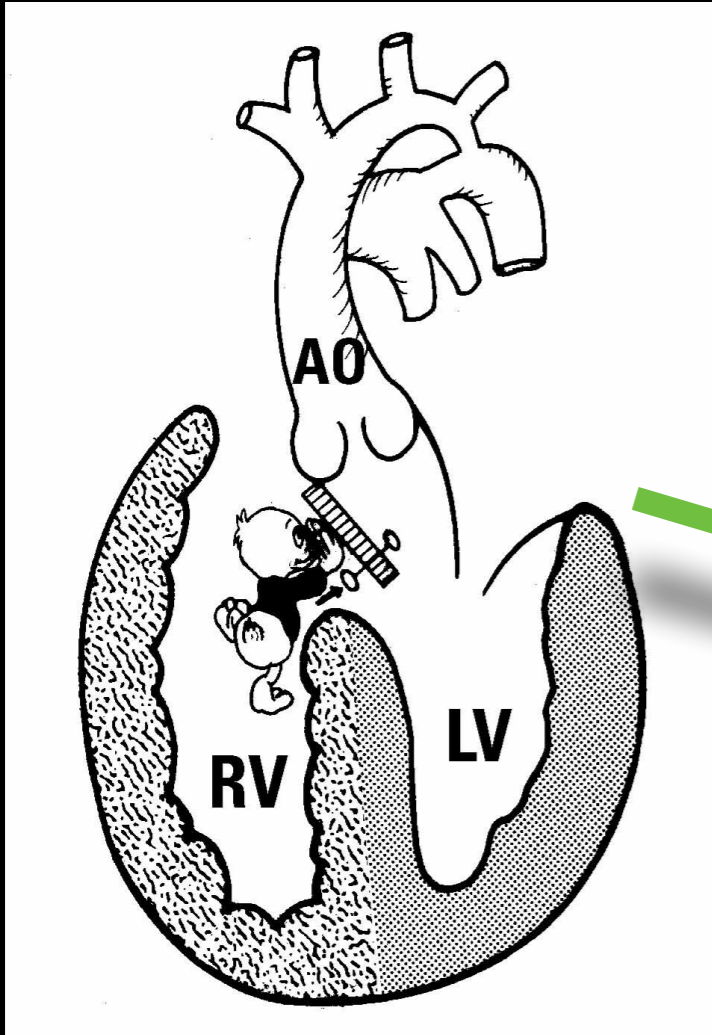
Reference structure: Rest of the ventricular septum

Direction: Posterior and superior

Extent: Moderate LVOTO

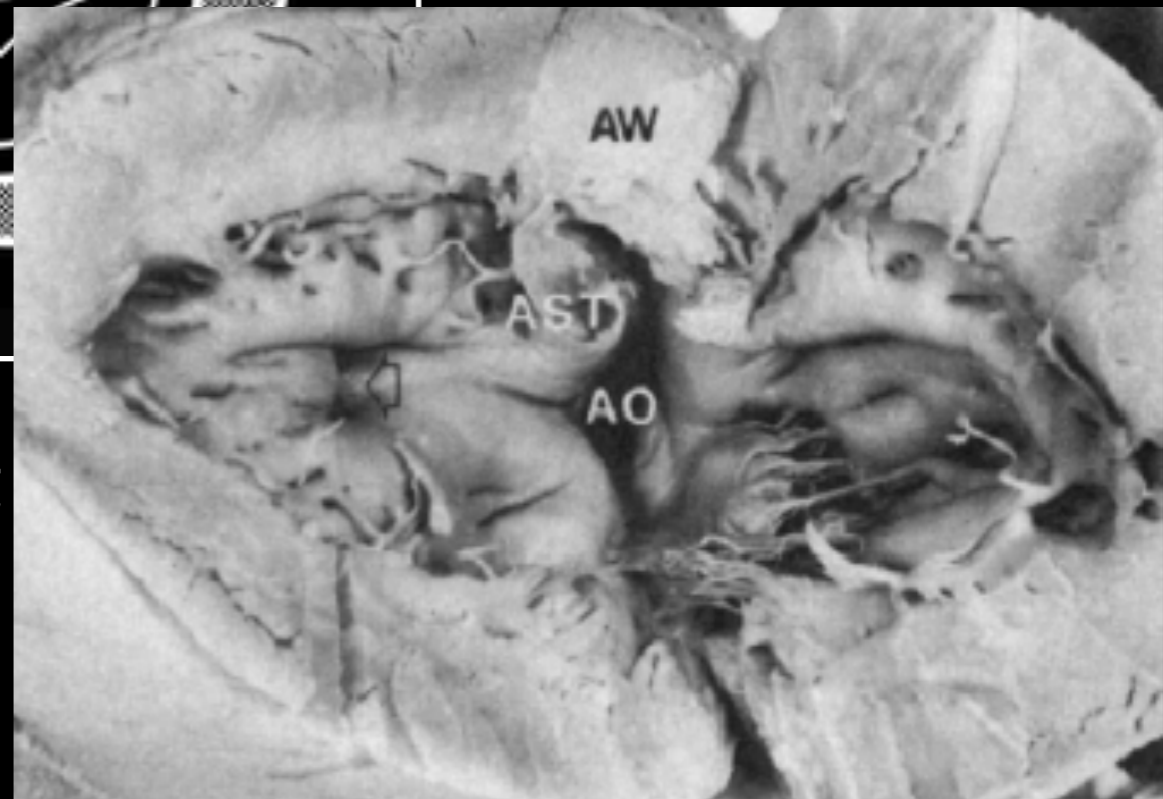
Malaligned outlet septum

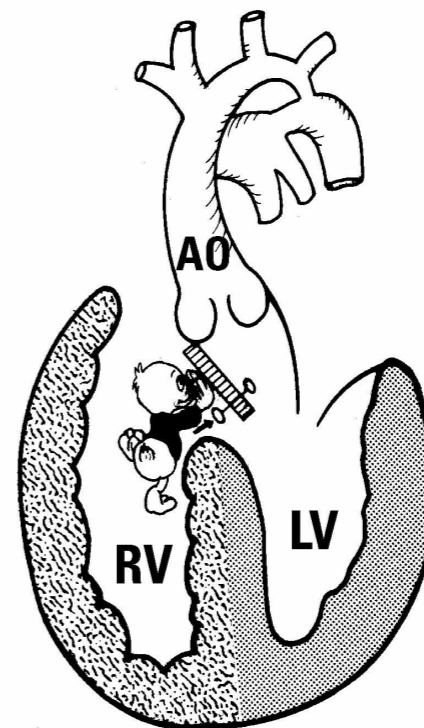
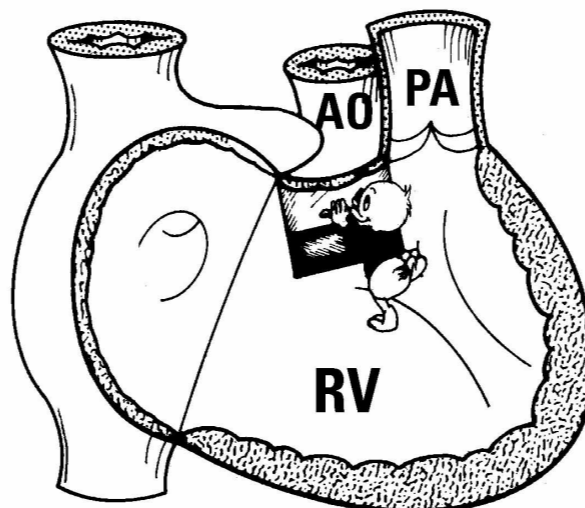
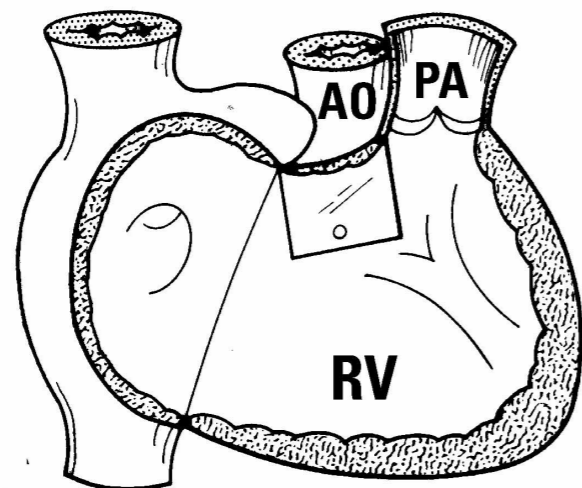
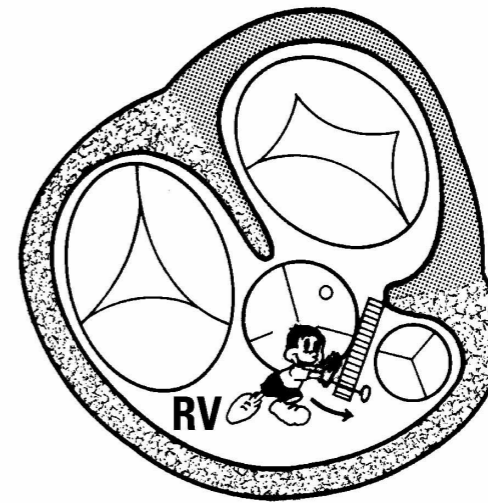
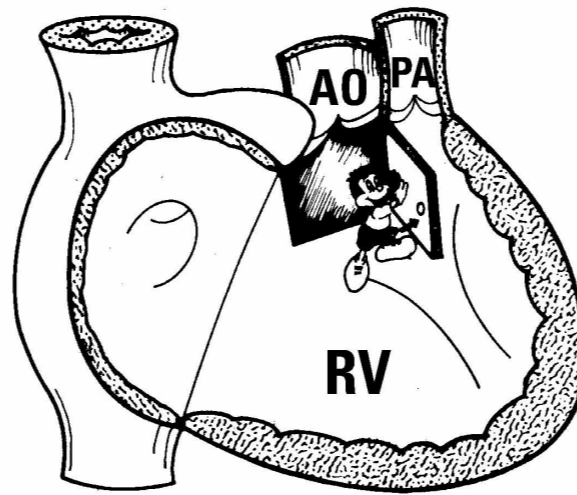
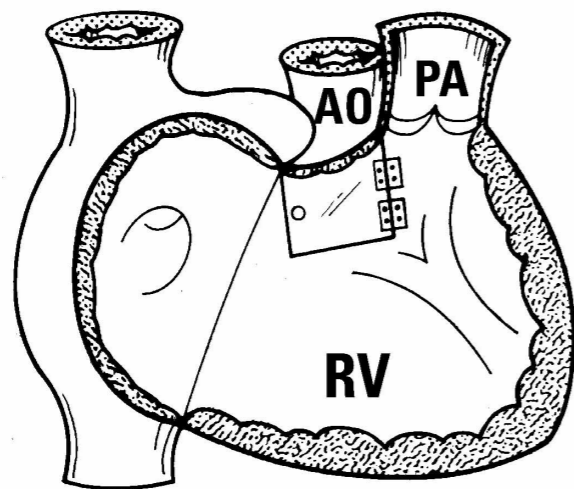
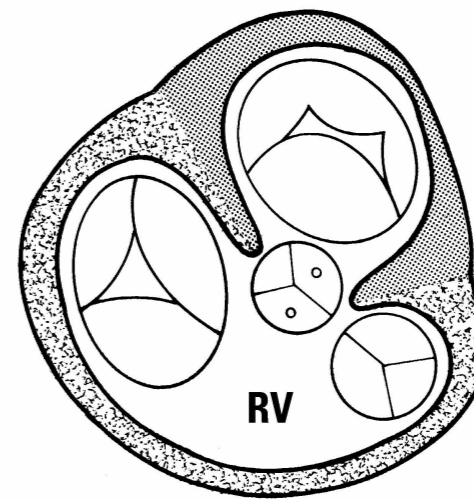
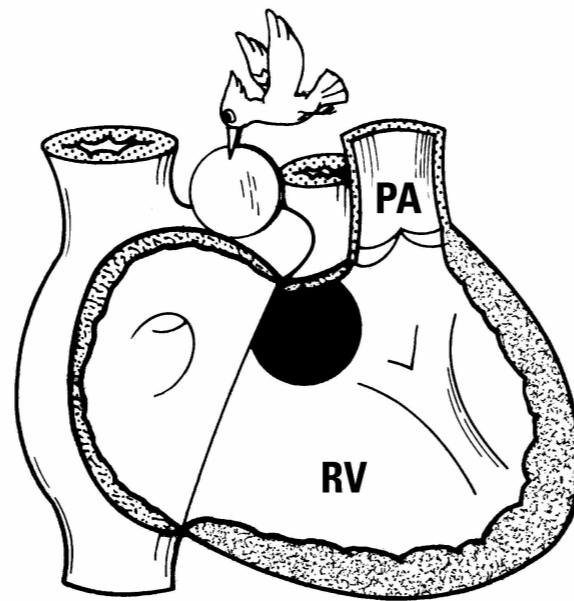
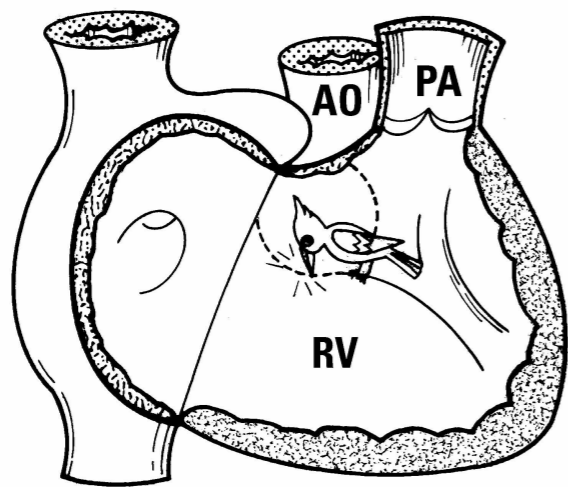
LVOTO



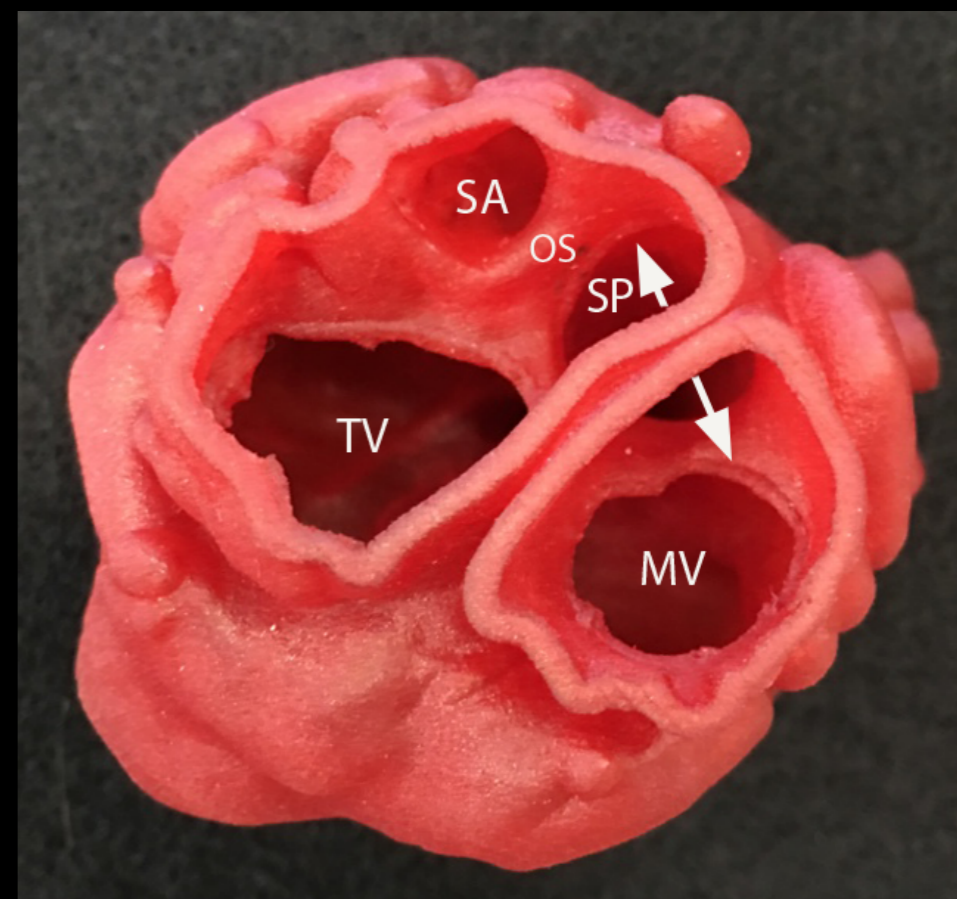
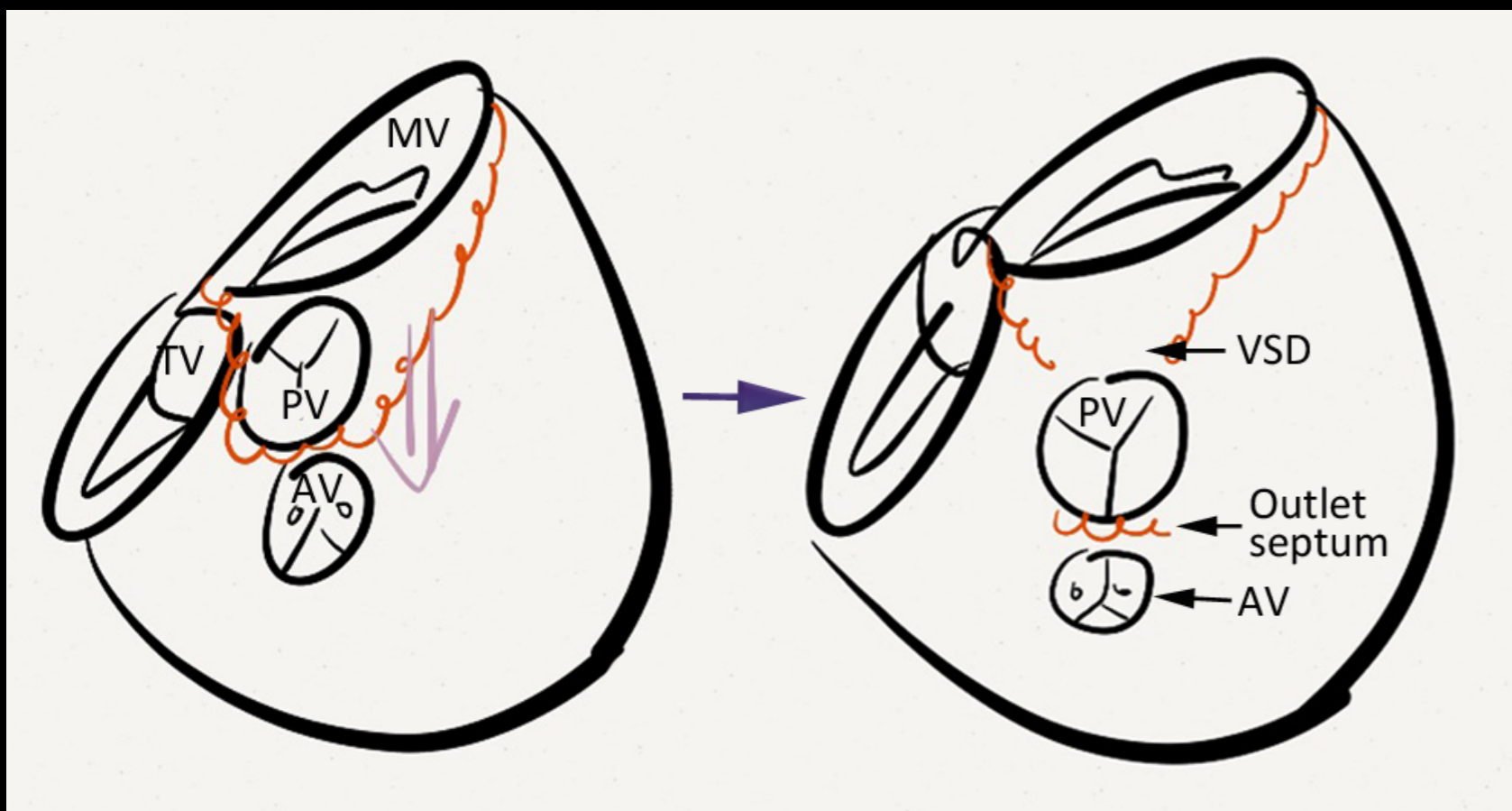
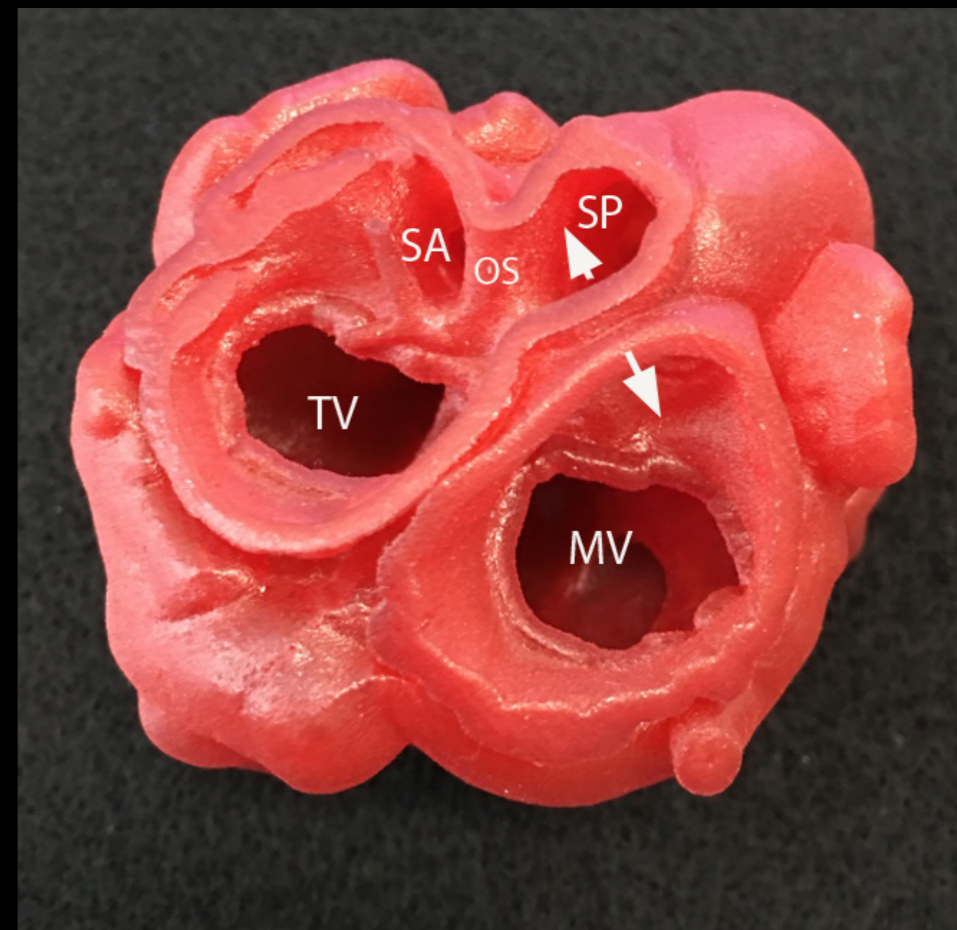
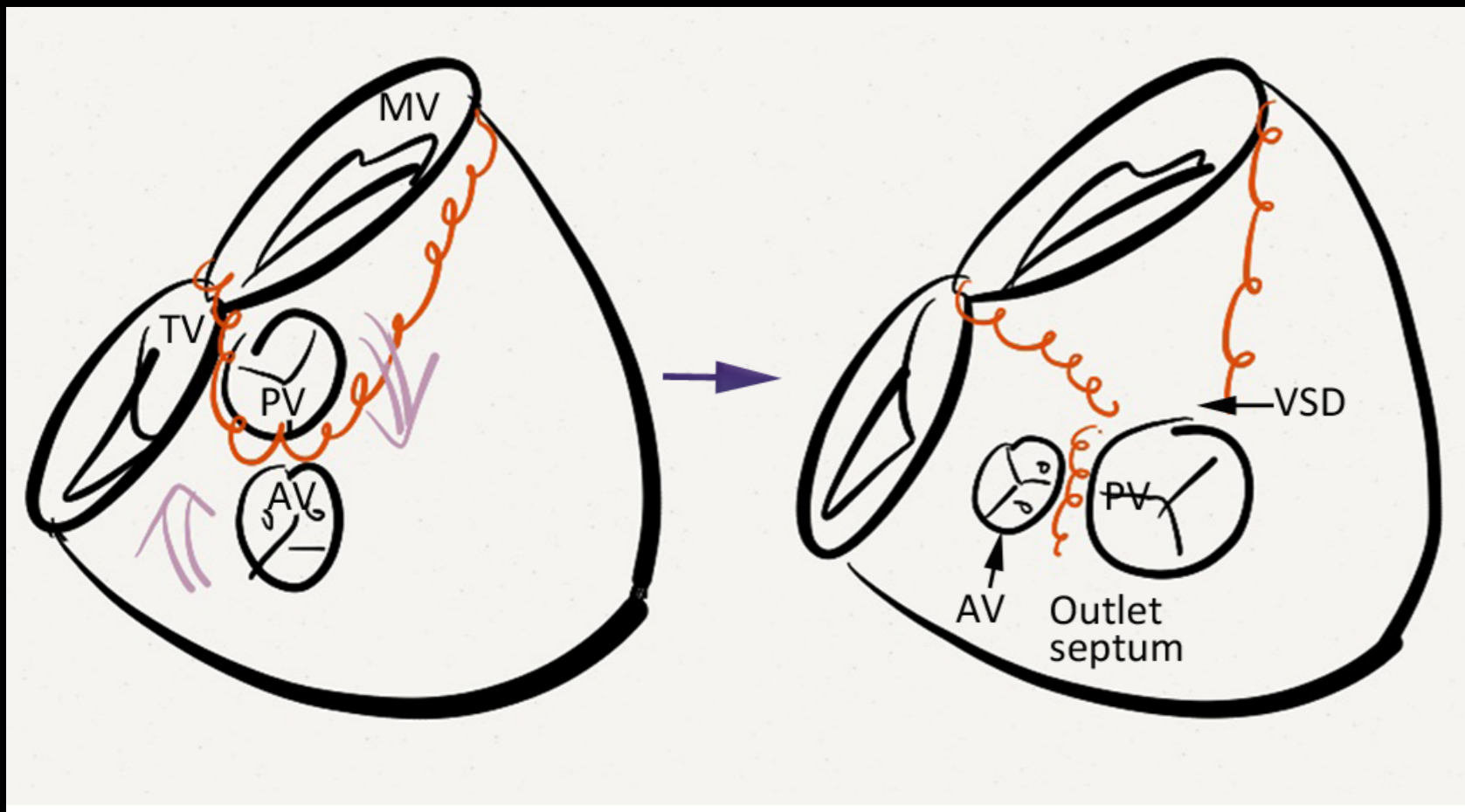
Anterolateral muscle bundle

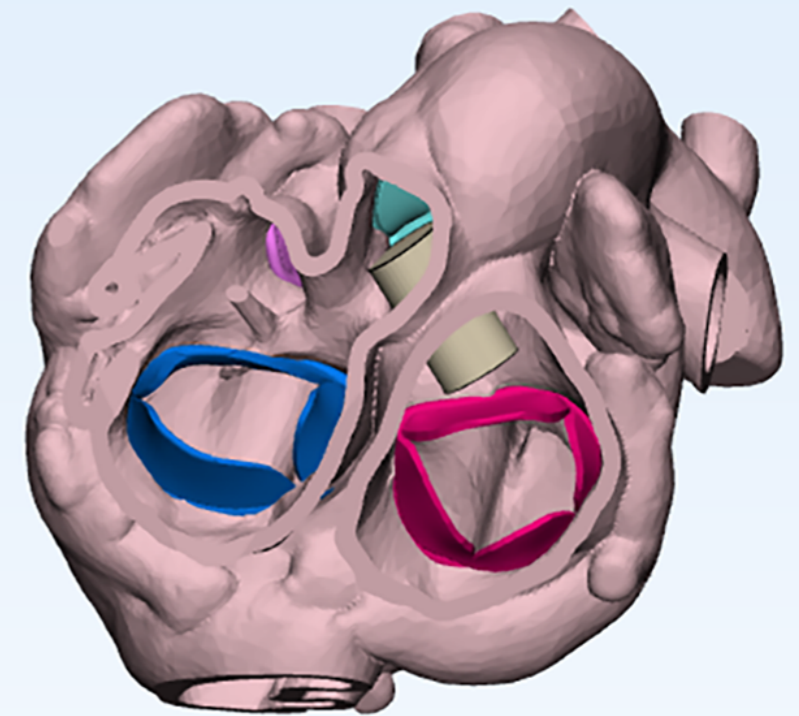
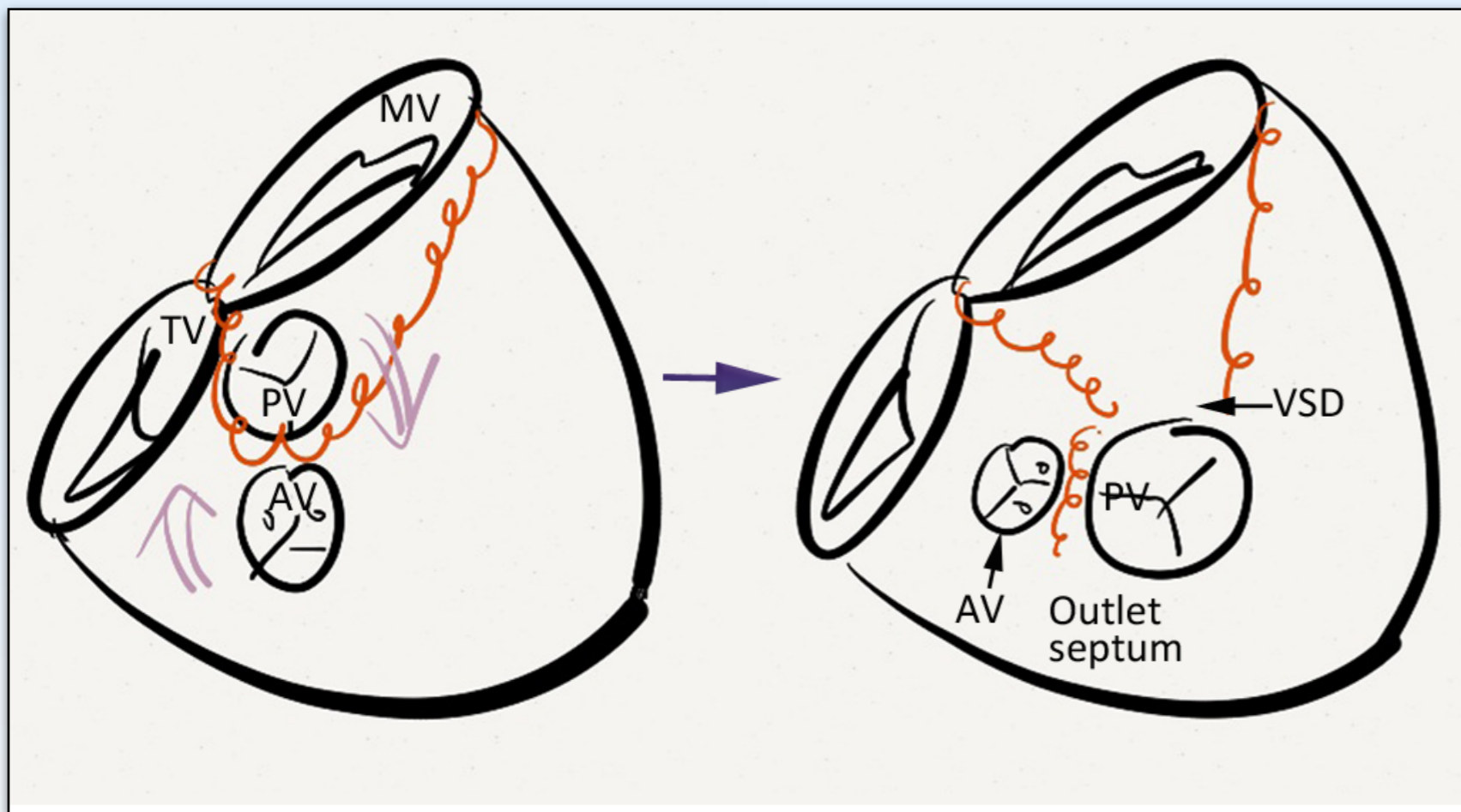
Anteroseptal twist





DORV with a Subpulmonary VSD
So-called Taussig-Bing Anomaly





TGA

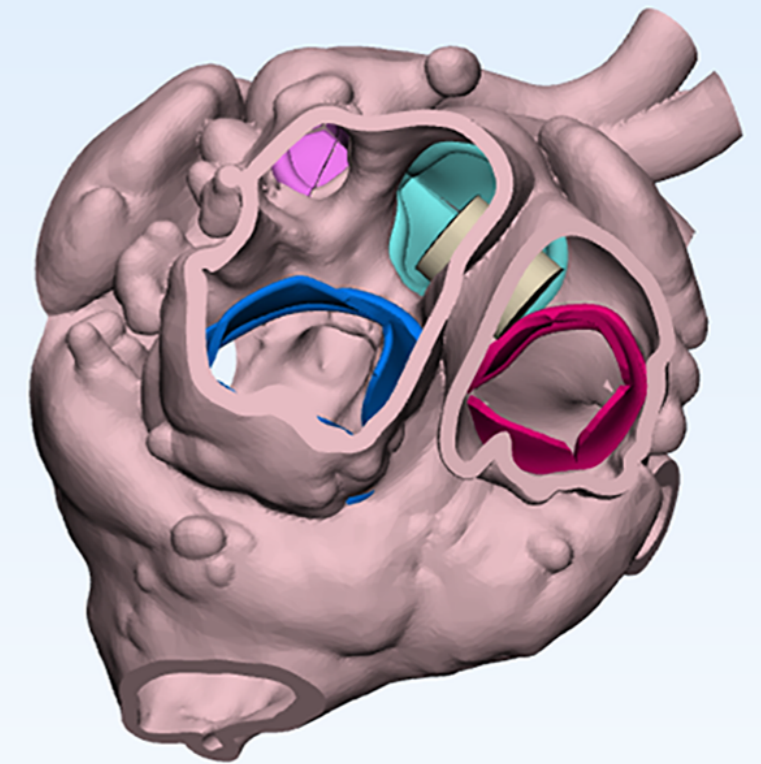
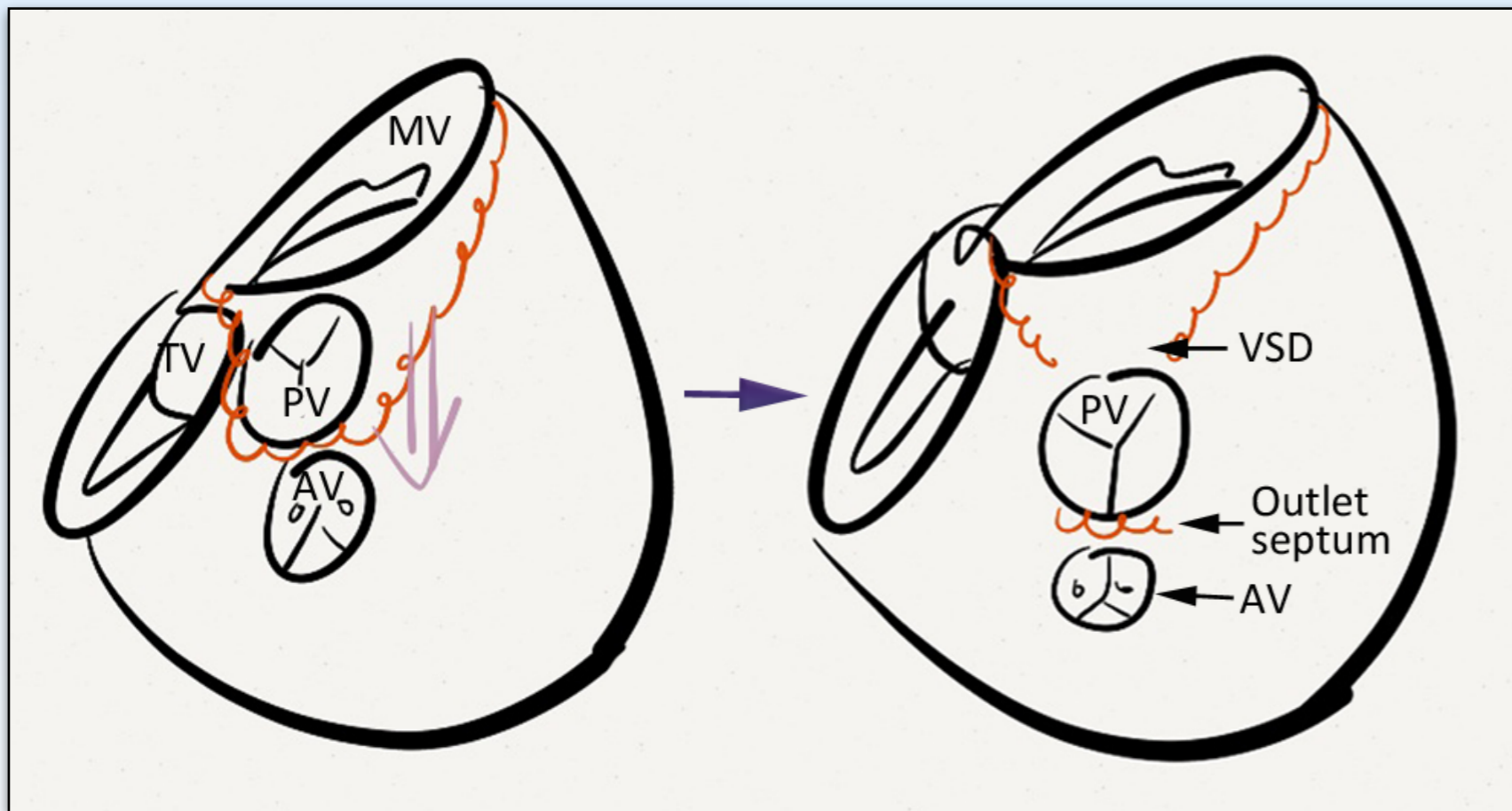
Malaligned part: Outlet septum

Mechanism: Flap door with hinge on the right

Reference structure: Rest of the ventricular septum

Direction: Rightward and forward

Extent: 80% overriding of pulmonary valve and moderate subaortic stenosis



TGA

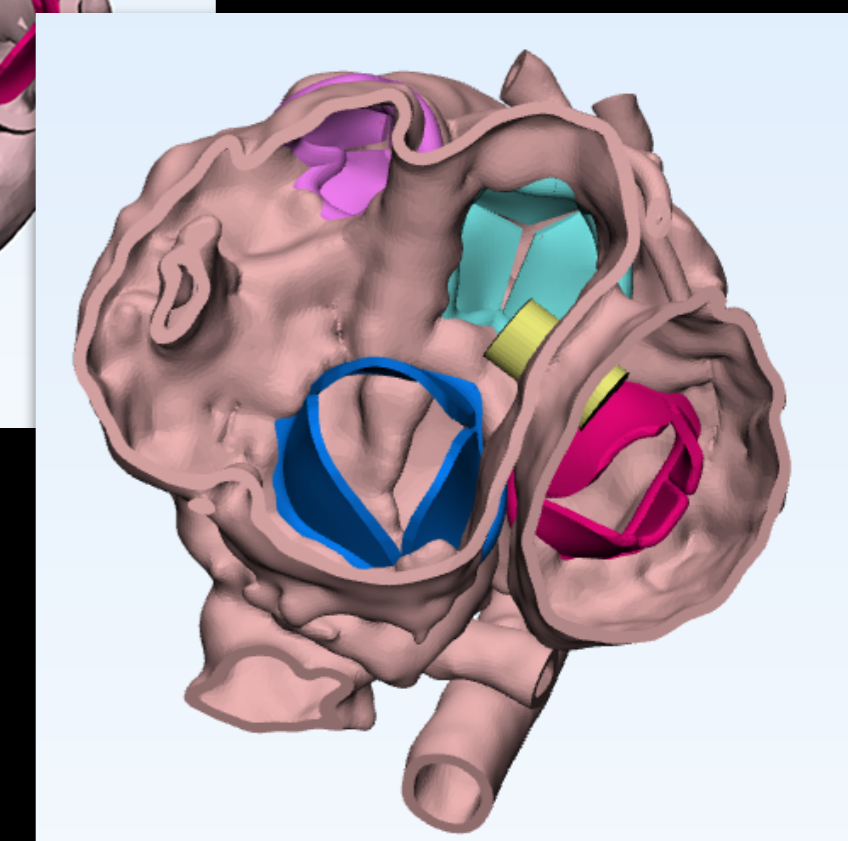
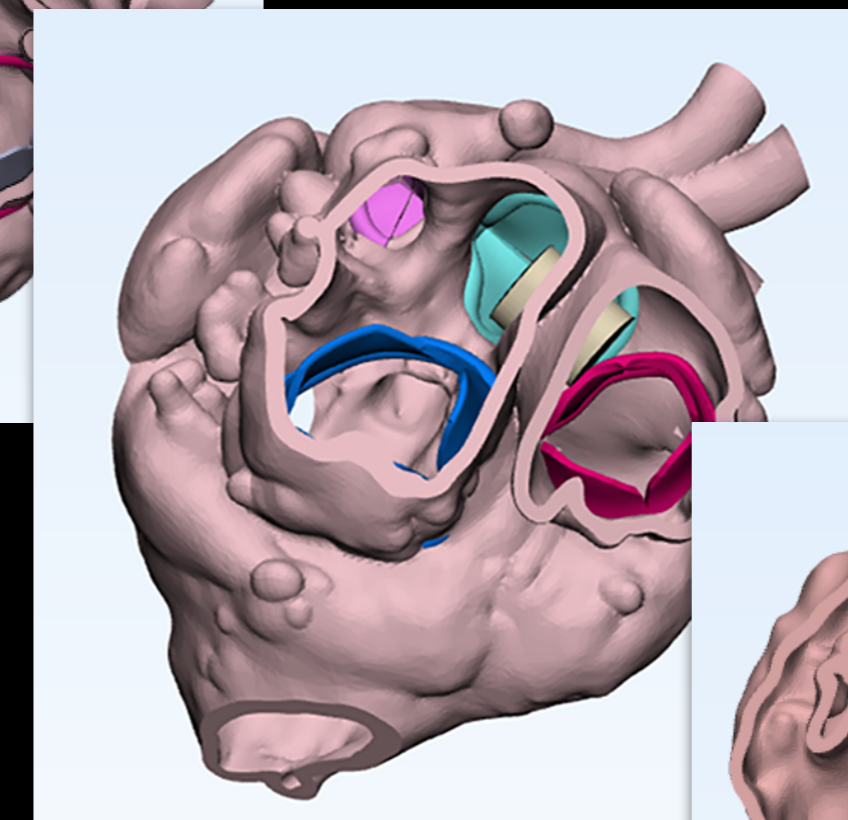
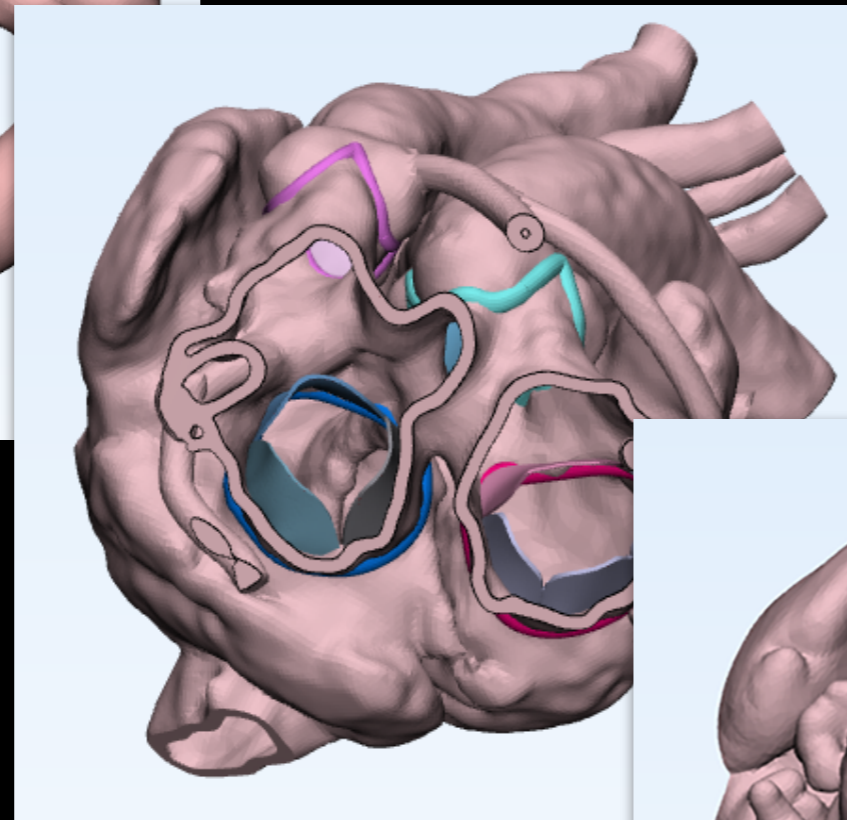
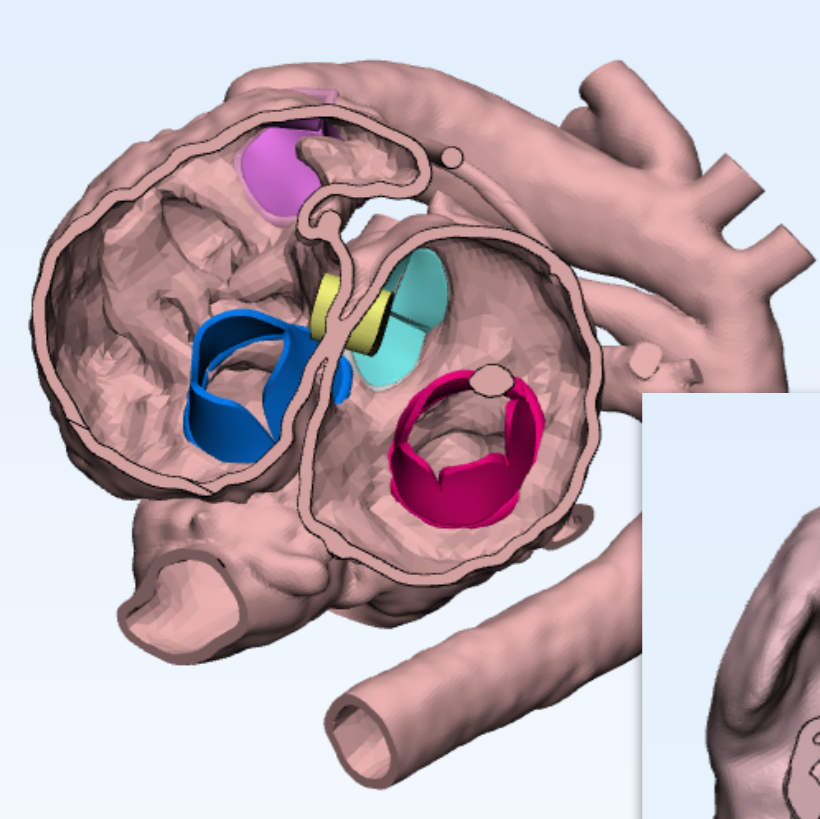
Malaligned part: Outlet septum

Mechanism: En bloc displacement

Reference structure: Rest of the ventricular septum

Direction: Forward

Extent: 80% overriding of pulmonary valve and mild subaortic stenosis

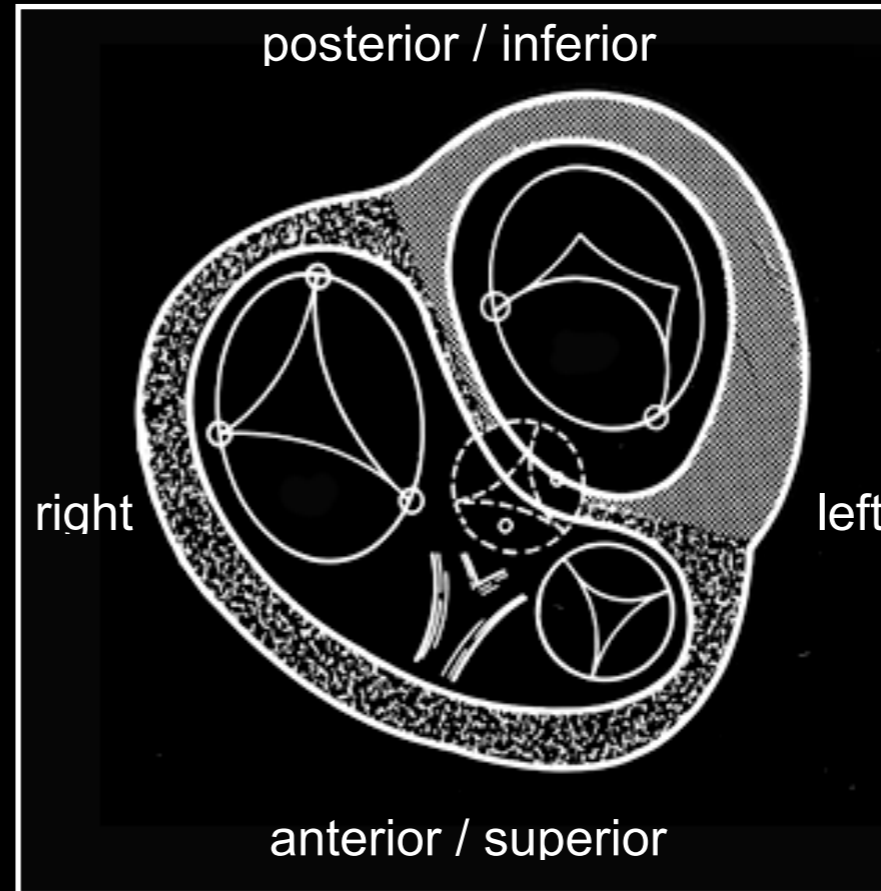


SEPTAL MALALIGNMENT

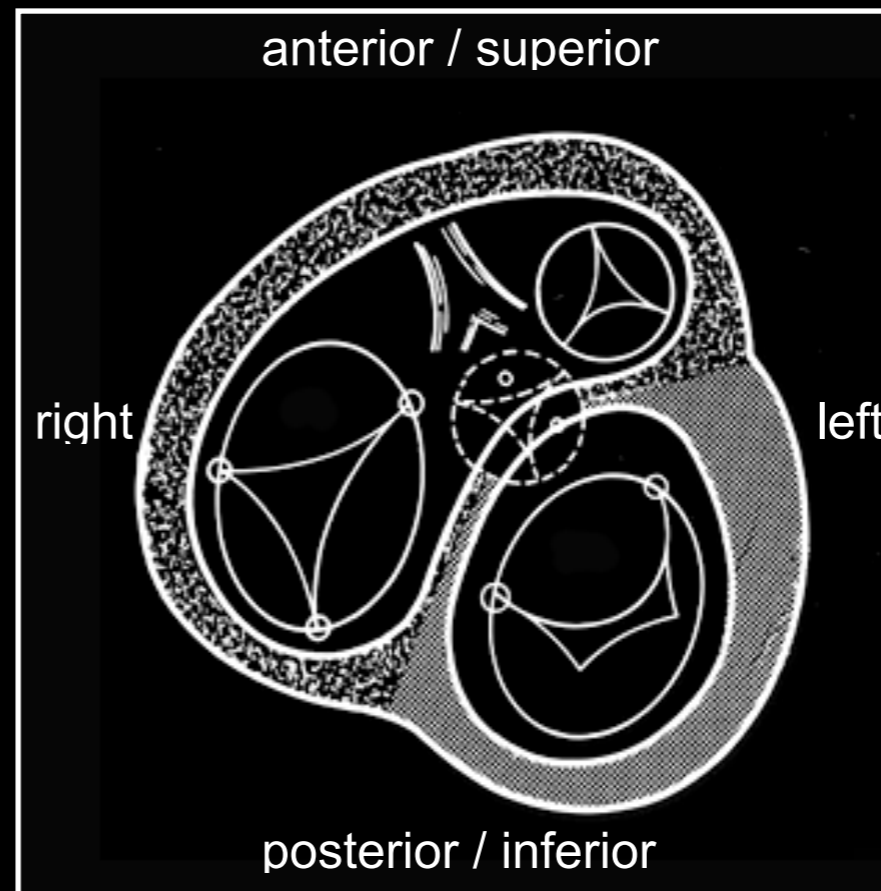
-Essential features to define-

- Malaligned part of the septum
- Mechanisms of malalignment
- Reference structure: In relation to what?
- Direction of malalignment
- Extent of malalignment

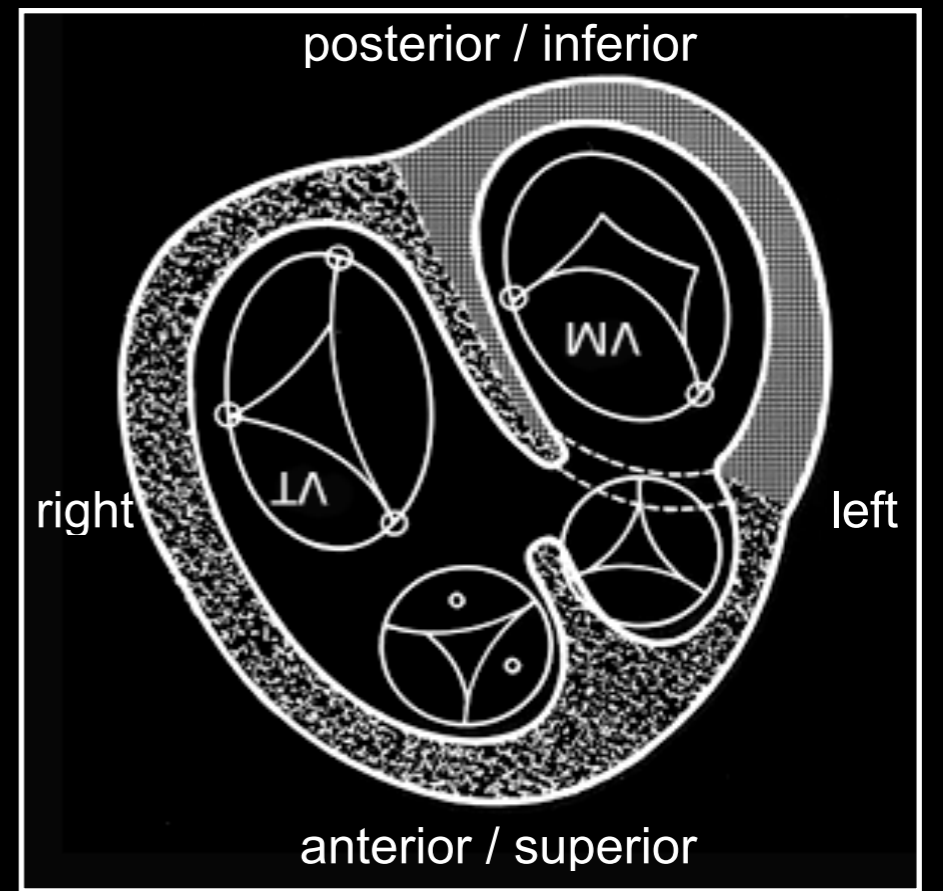
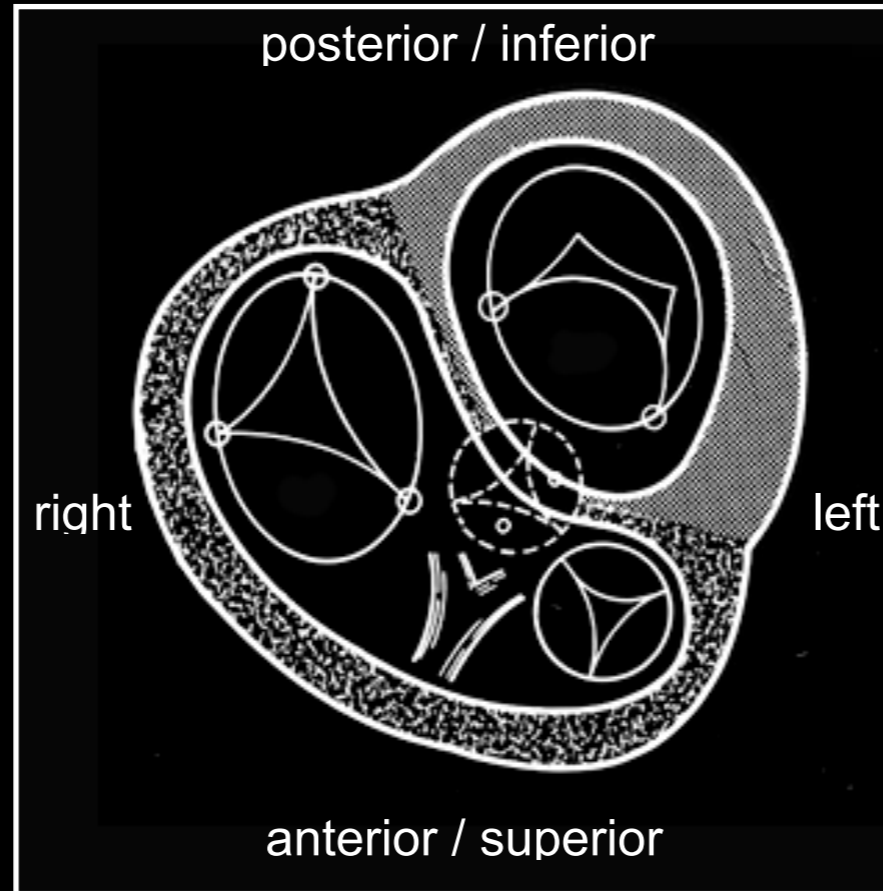
From above



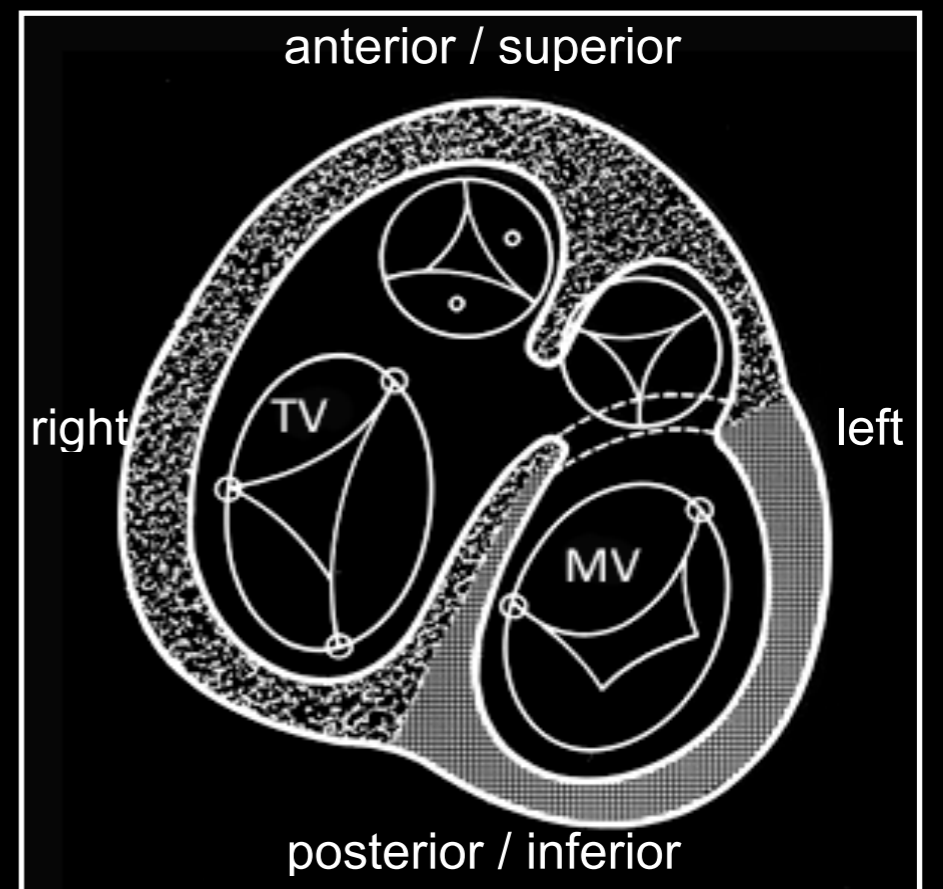
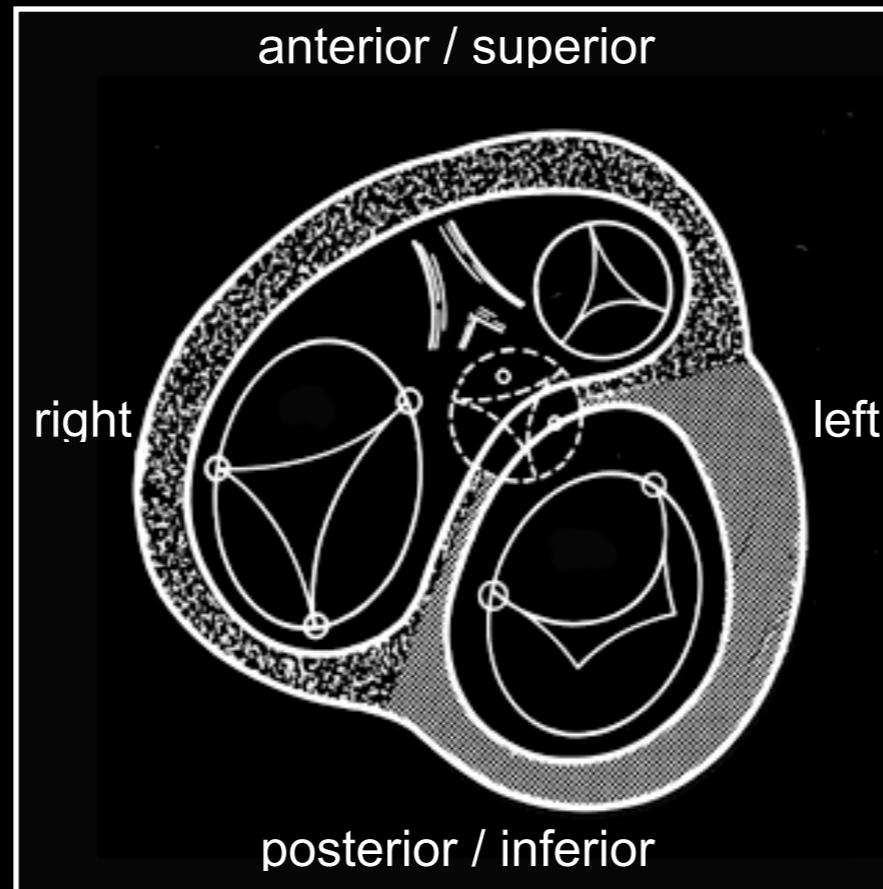
From below



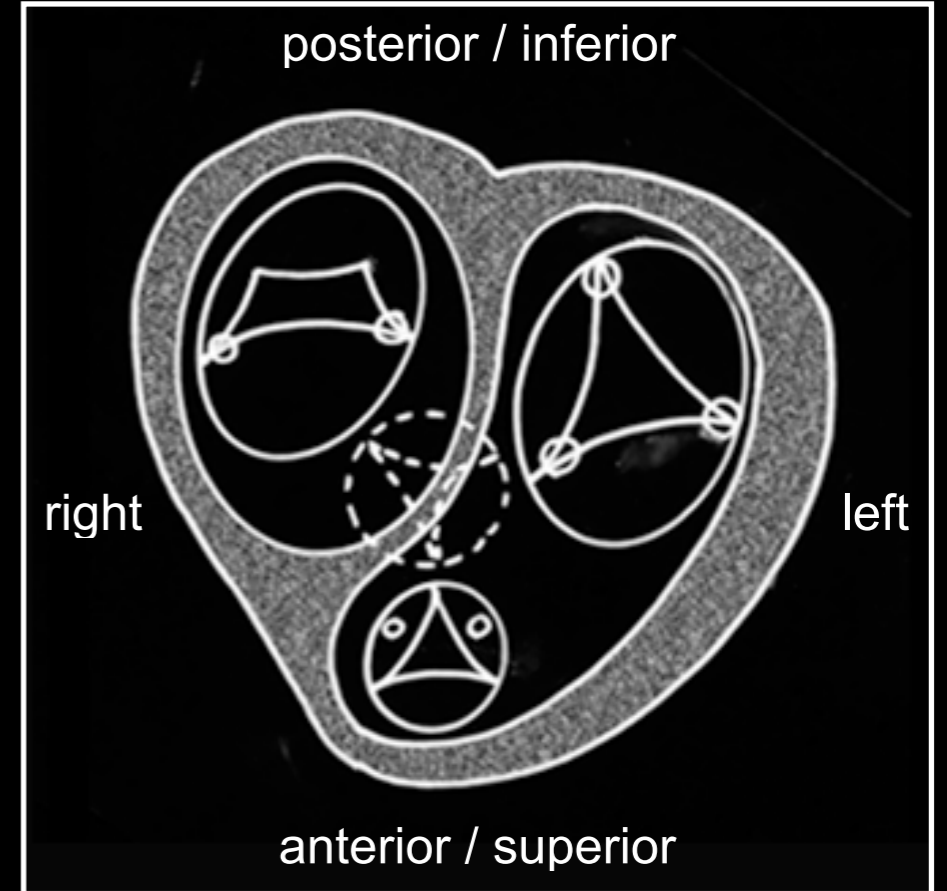
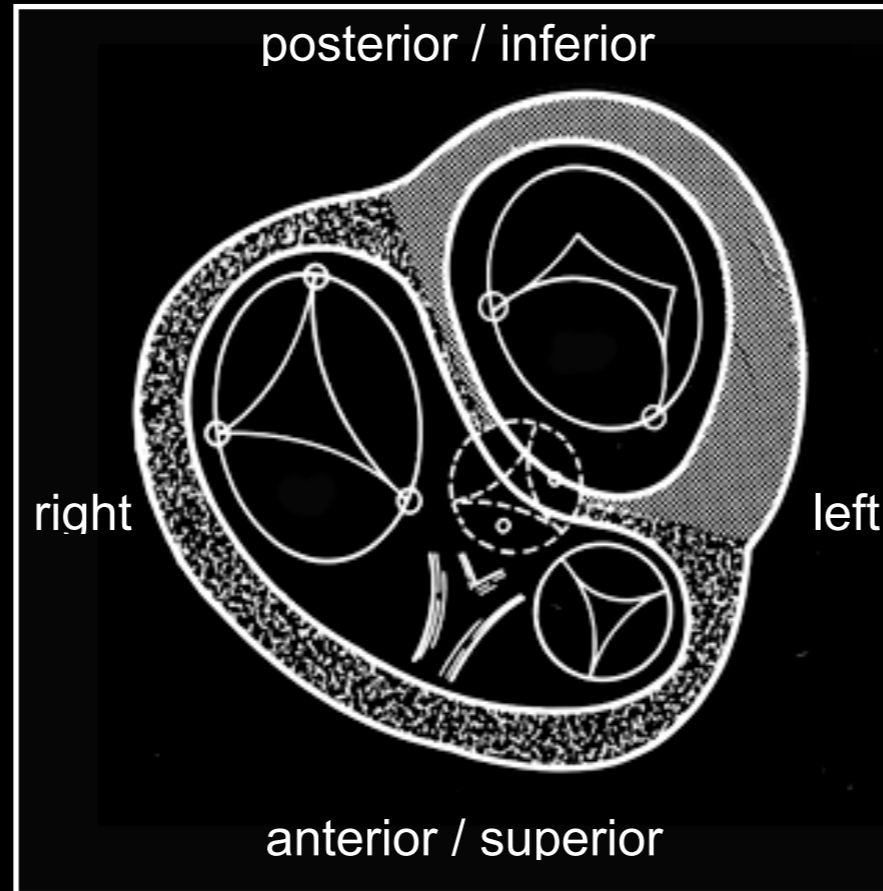
From above



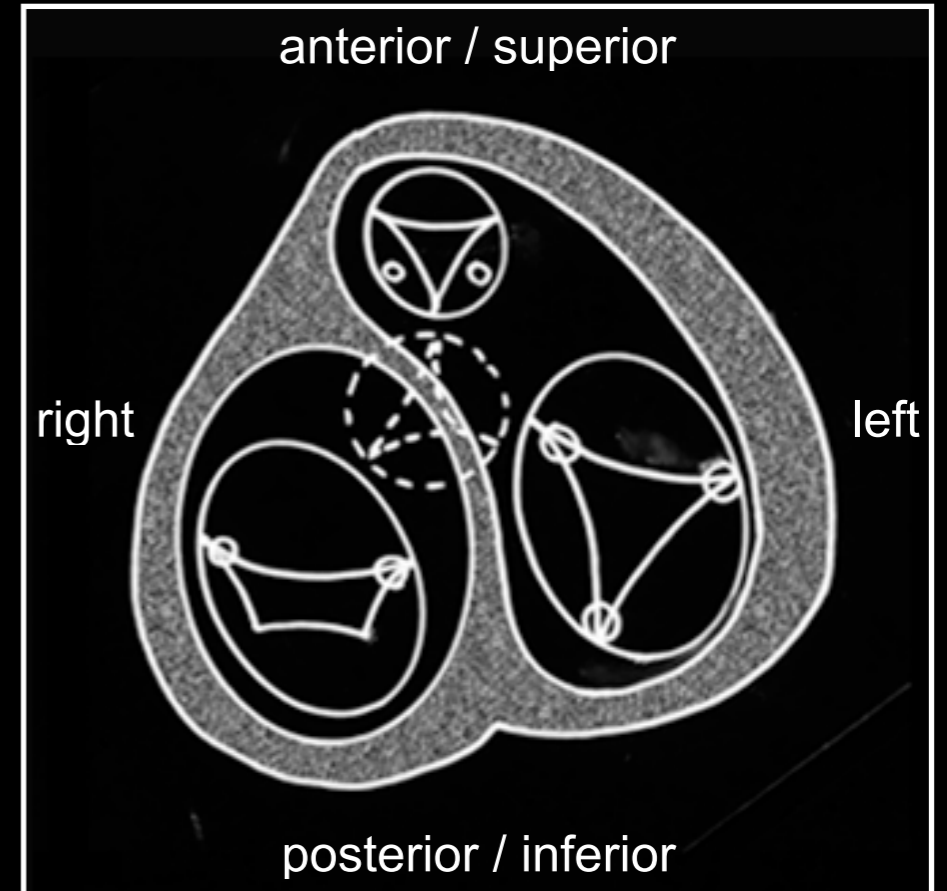
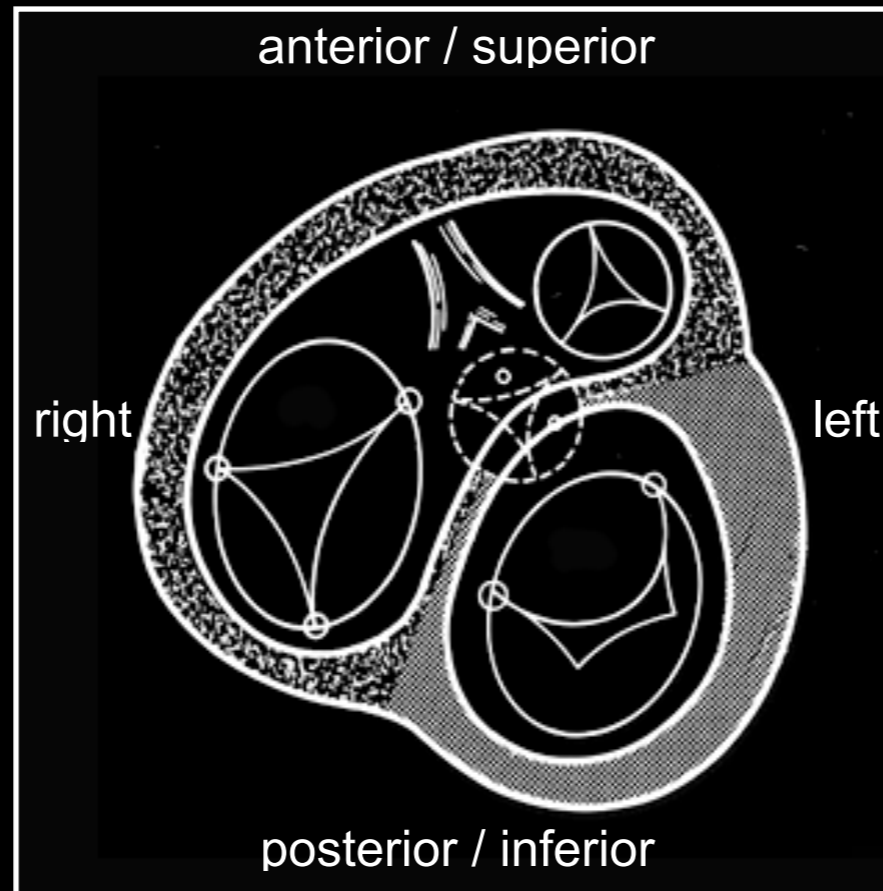
From below



From above



From below





TORONTO

Thank you!