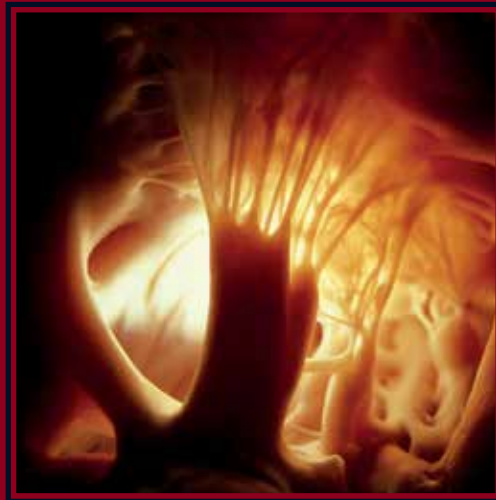



Society for Cardiothoracic Surgery in Great Britain and Ireland

# Perspectives in Cardiothoracic Surgery

## The SCTS Ionescu University Volume II



Series Editor  
Paul Modi

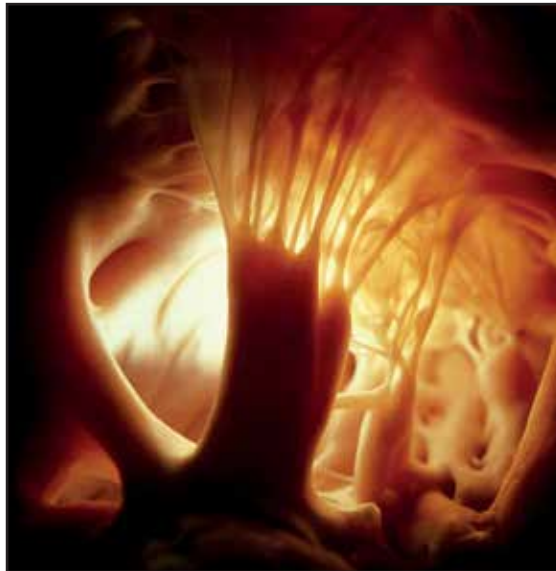Invited Editor  
Marian Ion Ionescu



Society for Cardiothoracic Surgery in Great Britain and Ireland

# Perspectives in Cardiothoracic Surgery

The SCTS Ionescu University  
Volume II



Series Editor  
Paul Modi

Invited Editor  
Marian Ion Ionescu

## Perspectives in Cardiothoracic Surgery: The SCTS-Ionescu University, Volume II

Copyright © 2017 Society for Cardiothoracic Surgery in Gt Britain and Ireland

ISBN 978-0-9957260-0-0

First published in Great Britain in 2016 by Society for Cardiothoracic Surgery in Great Britain and Ireland, SCTS 5th Floor, Royal College of Surgeons of England, 35-43 Lincoln's Inn Fields, London WC2A 3PE.

Tel: 0207 869 6893

Fax: 0207 869 6890

Email: [sctsadmin@scts.org](mailto:sctsadmin@scts.org)

Web: [www.scst.org](http://www.scst.org)

All rights reserved. No part of this book may be reproduced or transmitted in any form or by any means, electronic or mechanical, including photocopying, recording or by any information storage and retrieval system, without written permission from the author, except for the inclusion of brief quotations in a review.

Cover photo by Lennart Nilsson

Designed, typeset and printed by CPL Associates, London, UK.

# Perspectives in Cardiothoracic Surgery

The SCTS Ionescu University  
Volume II

*Series Editor* Paul Modi

*Invited Editor* Marian Ion Ionescu

**Section I: Cardiac Surgery – Diseases of the Aorta**

*Guest Editor* Mark Field, Liverpool, UK.

*Deborah Harrington, Liverpool, UK.*

**Section II: Thoracic Surgery - Minimally Invasive  
Lung Surgery**

*Guest Editor* Michael Shackcloth, Liverpool, UK.

*Steven Woolley, Liverpool, UK.*



Society for Cardiothoracic Surgery  
in Great Britain and Ireland





---

# Preface

---

*“A fonte puro pura deuit aqua”*

It is a privilege for us to introduce the second volume of Perspectives in Cardiothoracic Surgery. As Invited Editor, Mr Marian Ionescu noted in his post scriptum to Volume 1 that cardiothoracic surgery is in a period of intense scientific activity. The evidence from the SCTS Ionescu University 2016 is that this activity continues. There were twelve streams to the University in 2016 and, in Volume 2 of Perspectives in Cardiothoracic Surgery, we have concentrated on two areas; surgery of the thoracic aorta and minimally invasive lung resection. The chapters on these topics certainly show how intense this activity is and how it benefits our patients.

We are of course grateful to our international faculty who lectured at the University and have written the chapters for this book. The coordination of this has been undertaken by our Guest Editors Deborah Harrington, Mark Field, Michael Shackcloth and Steven Woolley, and we are pleased to be able to recognise their important contribution.

Especial thanks go to Series Editor Paul Modi who has undertaken the real hard work in transforming Mr Marian Ionescu’s vision and support into the, now two, publications that are Perspectives in Cardiothoracic Surgery.

The 2016 SCTS Ionescu University was attended by 457 delegates. Whilst a much wider audience can view the presentations on-line at [www.scts.org](http://www.scts.org), we find that there is something about holding a book and reading the printed word that improves the experience. On behalf of the contributors to the book and the team that have produced it, I hope that you find this too.

*Graham Cooper*

President 2016-18

*Richard Page*

President Elect 2018-20



# Contents

Preface	5
Contributors	8
<b>Section 1 – Cardiac Surgery: Diseases of the Aorta</b>	
<b>1 Hybrid Aortic Arch Replacement – Contemporary Practice and Outcomes</b>	11
George J. Arnaoutakis, Joseph E Bavaria	
<b>2 Aortic Valve-Preserving Surgery</b>	23
Omar Nawaytou, Gebrine El Khoury	
<b>3 Thoraco-Abdominal Aortic Aneurysm Repair – Tips from Belgium</b>	39
Marianna Buonocore, Marc Schepens	
<b>4 Management of the Infected Aortic Root</b>	51
Mustafa Zakkar, Alan J Bryan	
<b>5 Surgical Options in Acute Type B Dissection</b>	63
Mohamad Bashir, Amer Harky, Aung Oo	
<b>6 Team Building and Subspecialisation in Aortic Surgery</b>	75
John Pepper	
<b>7 Blood Conservation and Transfusion in Aortic Surgery</b>	87
Seema Agarwal	
<b>8 Distal aortic repair in Type A aortic Dissection</b>	99
Nishith Patel, Pedro Catarino	
<b>Section 2 – Thoracic Surgery: Minimally Invasive Lung Resection</b>	
<b>9 Video-Assisted Thoracoscopic Surgery versus Open Lobectomy</b>	113
Doug Mathisen	
<b>10 Avoiding and Treating Complications in VATS Lobectomy</b>	125
Ariel W. Knight, Shanda H. Blackmon	
<b>11 Complex Minimally Invasive Pulmonary Resections</b>	141
René Horsleben Petersen	
<b>12 Microlobectomy</b>	147
Joel Dunning, Muhammad Izanee Mydin, Mohammed Elsaegh, Marco Nardini, Shanda Blackmon, Rene Peterson, Henrik Hansen, Bryan Helsel, Malcolm Will, William S Walker	
<b>13 Video-Assisted Thoracoscopic Surgical Tracheal and Carinal Resection</b>	155
Keng Ang, GuiLing Peng, JingPei Li, JianXing He	
<b>14 Training in VATS Lobectomy</b>	163
Alberto Sandri, Michele Salati, Alessandro Brunelli	
<b>15 Robotic-Assisted Lobectomy: The Newcastle Experience</b>	171
Sasha Stamenkovic, Dharmendra Agrawal, Robert Slight	
<b>Postscriptum</b>	181



# Contributors

## **Seema Agarwal FRCA**

Consultant Anaesthetist,  
Liverpool Heart and Chest Hospital,  
Liverpool, UK.

## **D Agrawal MBBS MCh EBCTS**

Locum Consultant Thoracic Surgeon,  
Freeman Hospital,  
Newcastle-upon-Tyne, UK.

## **Keng Ang PhD FRCS(CTh)**

Consultant Thoracic Surgeon,  
Glenfield Hospital,  
University Hospitals of Leicester,  
Leicester, UK.

## **George J. Arnaoutakis MD**

Attending Cardiac Surgeon,  
Division of Thoracic and  
Cardiovascular Surgery,  
University of Florida,  
Gainesville, FL, USA.

## **Mohamad Bashir MD PhD MRCS**

Clinical Fellow in Cardiothoracic Surgery,  
Barts Heart Centre,  
London, UK.

## **Joseph E Bavaria MD**

Attending Cardiac Surgeon,  
Division of Cardiovascular Surgery,  
University of Pennsylvania,  
Philadelphia, PA, USA.

## **Shanda H Blackmon MD MPH FACS**

Associate Professor of Surgery,  
Department of Surgery,  
Division of General Thoracic Surgery,  
Mayo Clinic,  
Rochester, MN, USA.

## **Alessandro Brunelli MD**

Consultant Thoracic Surgeon,  
Honorary Clinical Associate Professor  
University of Leeds,  
Secretary General, European Society  
of Thoracic Surgeons,  
St. James's University Hospital,  
Leeds, UK.

## **Alan J Bryan DM FRCS(CTh)**

Consultant Cardiac Surgeon,  
Bristol Heart Institute,  
University Hospitals Bristol  
NHS Foundation Trust,  
Bristol, UK.

## **Marianna Buonocore MD**

Department of Cardiac Surgery,  
AZ Sint Jan,  
Bruges, Belgium.

## **Pedro Catarino MD**

Consultant Cardiac Surgeon,  
Papworth Hospital,  
Cambridge, UK.

## **Joel Dunning FRCS PhD**

Consultant Thoracic Surgeon,  
James Cook University Hospital  
Middlesbrough, UK.

## **Gebrine El Khoury MD**

Professor of Cardiac Surgery,  
Cliniques Universitaires St Luc,  
Brussels, Belgium.

## **Mohamed Elsaegh MD FRCS(CTh)**

Clinical Fellow in Cardiothoracic Surgery,  
James Cook University Hospital,  
Middlesbrough, UK.

**Mark Field FRCS(CTh) DPhil**

Consultant Cardiac and Aortic Surgeon,  
Liverpool Heart and Chest Hospital,  
Liverpool, UK.

**Henrik Hansen MD**

Consultant Thoracic Surgeon,  
University Hospital of Copenhagen,  
Copenhagen, Denmark.

**Amer Harky MB ChB MRCS**

Senior House Officer in  
Cardiothoracic Surgery,  
Barts Heart Centre,  
London, UK.

**Deborah Harrington MD FRCS(CTh)**

Consultant Cardiac and Aortic Surgeon,  
Liverpool Heart and Chest Hospital,  
Liverpool, UK.

**JianXing He MD PhD FACS FRCS**

Professor of Thoracic Surgery,  
The First Affiliated Hospital of  
Guangzhou Medical University,  
State Key Laboratory of  
Respiratory Diseases,  
National Clinical Research Center  
for Respiratory Disease,  
Guangzhou, China.

**Bryan S Helsel MD FACS**

Staff Cardiothoracic Surgeon,  
San Antonio Military Medical Center,  
Cardiothoracic Surgery Service,  
San Antonio, TX, USA.

**Ariel Knight MD**

Resident in Thoracic Surgery,  
Division of General Thoracic Surgery,  
Mayo Clinic,  
Rochester, MN, USA.

**JingPei Li MD**

Resident in Thoracic Surgery,  
The First Affiliated Hospital of  
Guangzhou Medical University,  
State Key Laboratory of  
Respiratory Diseases,  
National Clinical Research Center  
for Respiratory Disease,  
Guangzhou, China.

**Douglas J. Mathisen MD**

Chief, Thoracic Surgery,  
Massachusetts General Hospital,  
Boston, MA, USA.

**Muhammad Izanee Mydin MB ChB MRCS(Ed)**

Registrar in Cardiothoracic Surgery,  
James Cook University Hospital,  
Middlesbrough, UK.

**Marco Nardini MD**

Clinical Fellow in Cardiothoracic Surgery,  
James Cook University Hospital,  
Middlesbrough, UK.

**Omar Nawaytou MD FRCS (C-Th)**

Fellow in Aortic Surgery,  
Liverpool Heart and Chest Hospital,  
Liverpool, UK.

**Aung Y Oo MD FRCS(CTh)**

Professor of Aortic Surgery,  
Associate Medical Director for Surgery,  
Liverpool Heart and Chest Hospital,  
Liverpool, UK.

**Nishith Patel BSc (Hons) PhD MRCS FRCS (C-Th)**

NIHR Aortic Fellow,  
Papworth Hospital,  
Cambridge, UK.

**GuiLing Peng MD**

Resident in Thoracic Surgery,  
The First Affiliated Hospital of  
Guangzhou Medical University,  
State Key Laboratory of  
Respiratory Diseases,  
National Clinical Research Center for  
Respiratory Disease,  
Guangzhou, China.

**John Pepper MA MChir FRCS FESC**

Lead Clinician for the Aortic Unit at Royal  
Brompton and Harefield,  
NIHR Cardiovascular Biological  
Research Unit,  
Royal Brompton Hospital,  
London, UK.

**René Horsleben Petersen MD**

Chief Thoracic Surgeon,  
University Hospital of Copenhagen,  
Copenhagen, Denmark.

**Michele Salati MD**

Consultant Thoracic Surgeon,  
Ospedali Riuniti Ancona,  
Ancona, Italy.

**Alberto Sandri MD**

Consultant Thoracic Surgeon,  
European Institute of Oncology,  
Milano, Italy.

**Marc Schepens MD PhD**

Chief of Department of  
Cardiothoracic Surgery,  
AZ Sint Jan,  
Bruges, Belgium.

**Michael Shackcloth MD FRCS(CTh)**

Consultant Thoracic Surgeon,  
Liverpool Heart and Chest Hospital,  
Liverpool, UK.

**R D Slight PhD FRCSEd (CTh)**

Specialist Registrar,  
Freeman Hospital,  
Newcastle-upon-Tyne, UK.

**Sasha A Stamenkovic MBChB FRCS (CTh)**

Consultant Thoracic Surgeon,  
Freeman Hospital,  
Newcastle Upon Tyne, UK.

**William Walker FRCS**

Consultant Thoracic Surgeon,  
Department of Cardiothoracic Surgery,  
Edinburgh Royal Infirmary,  
Edinburgh, UK.

**Malcolm Will MD**

Consultant Thoracic Surgeon,  
Department of Cardiothoracic Surgery,  
Edinburgh Royal Infirmary,  
Edinburgh, UK.

**Steven Woolley MD FRCS(CTh)**

Consultant Thoracic Surgeon,  
Liverpool Heart and Chest Hospital,  
Liverpool, UK.

**Mustafa Zakkar PhD FRCS(CTh)**

Clinical Lecturer in Cardiac Surgery,  
Academic Department of Cardiac Surgery,  
Bristol Heart Institute,  
University Hospitals Bristol NHS  
Foundation Trust,  
Bristol, UK.



# Section 1

## Cardiac Surgery – Diseases of the Aorta

Deborah Harrington

Mark Field

---

*“Abundans cautela non nocet”*



## Chapter 1

# Hybrid Aortic Arch Replacement: Contemporary Practice and Outcomes

*George J Arnaoutakis and Joseph E Bavaria*

---

*“Clavam extorquere Herculi”*

## Introduction

Replacement of the entire aortic arch for extensive arch pathology is technically challenging and harbours significant intraoperative and perioperative risk, including stroke, recurrent laryngeal nerve injury and respiratory complications, and severe bleeding. While open surgical repair of the total aortic arch remains the gold standard operation, this approach requires complex circulatory management and adjunctive brain protection maneuvers<sup>1</sup>. These reconstructions require periods of circulatory arrest, with the attendant end organ ischemia. In those patients with extensive medical co-morbidities, these open aortic arch reconstructions are associated with significant, often prohibitive, morbidity and mortality<sup>2</sup>.

Endovascular technology was initially applied to the thoracic aorta in the context of uncomplicated descending thoracic aneurysms. Results for thoracic endovascular aortic repair (TEVAR) in this clinical setting have demonstrated acceptable morbidity and mortality<sup>3</sup>. Hybrid approaches employing both open surgery and stent graft placement in the aortic arch have emerged from the increasing experience with endovascular technology<sup>4-12</sup>. The complex pathology and anatomy in the aortic arch mandates precise management and surgical modification of landing zones (LZ) to accommodate endovascular placement.

Careful patient selection is critical when choosing between traditional open and hybrid endovascular approaches for complex aortic disease. The hybrid solution is most attractive in those patients with numerous co-morbidities or surgical anatomy that puts them at very high risk for traditional open repair. The combination of open surgical and endovascular techniques in the hybrid arch repair paradigm has two main principles: 1) to minimize physiologic insults through shortening cardiopulmonary bypass and operative times, and potentially eliminating periods of circulatory arrest; and (2) to create suitable proximal and distal landing zones for TEVAR. In many instances, this approach necessitates reimplantation or bypass of the aortic arch vessels, with TEVAR implantation proximally in zone 0 (ascending aorta – innominate origin). This proximal landing zone is either suitable as native aorta, or must be replaced with Dacron graft to construct an appropriate proximal landing zone.

## Preoperative Evaluation

Aortic arch aneurysm repair should be performed if maximal aneurysm diameter exceeds 6cm, aneurysm growth rate is >1cm/year, in the symptomatic patient, or if there is abnormal aneurysm morphology<sup>13</sup>. A thorough preoperative workup should be performed, which includes a high-quality CT angiogram of the chest, abdomen, and pelvis, along with 3D reconstruction of the entire aorta and bilateral iliac system. The aortic arch anatomy delineated by CT scan will dictate the required hybrid operative technique. Measurements should be obtained to allow precise operative preparation, with emphasis on adequate iliofemoral access for safe TEVAR deployment, if a retrograde deployment will be performed. Antegrade TEVAR deployment can be performed concomitant with the debranching procedure, which is a particularly attractive option in patients with diseased iliofemoral vessels.

The presence of arch anomalies warrants careful attention, specifically the origin of the brachiocephalic vessels and dominance of vertebral arteries. The presence of a dominant left vertebral artery mandates left subclavian artery revascularization if coverage will be performed with the thoracic endograft during TEVAR. The 3D-CT reconstruction also enables accurate measurement of targeted landing zones both proximally and distally.

A 2cm landing zone of normal aorta both proximally and distally is preferable to achieve an appropriate seal and minimize the risk of a Type I endoleak.

Coronary angiogram and carotid duplex studies are performed when indicated. A prior history of transient ischemic attacks (TIA) or stroke warrants further neurologic workup to risk stratify and best prepare the patient before arch surgery.

## Surgical Technique

Hybrid Arch procedures should be performed in hybrid operating suites equipped with advanced fixed imaging systems. From a monitoring standpoint, bilateral radial arterial line placement is preferable. This permits continuous hemodynamic monitoring during sequential clamping of the left subclavian or innominate artery during debranching procedures. Near infrared spectroscopy (NIRS) and electroencephalogram (EEG) are routine monitoring adjuncts in all patients undergoing arch procedures. In elective procedures, motor evoked potentials (MEPs) are also used. Transesophageal echocardiography (TEE) is used when necessary. During distal arch reconstruction with TEVAR, a lumbar drain is placed in patients at high risk for spinal cord ischemia, specifically with a long distal thoracic landing zone or history of prior abdominal aortic surgery. In patients undergoing proximal arch surgery, a lumbar drain is not routine.

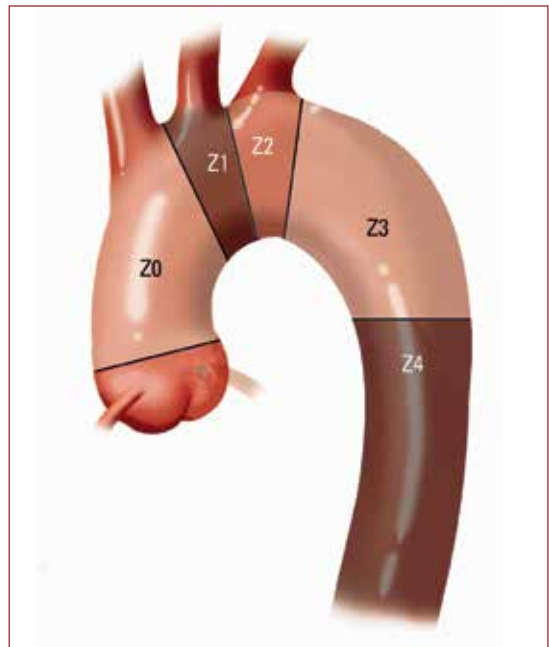
A classification of aortic arch landing zones has been developed which guides circulatory management strategies and standardizes hybrid arch procedures (Figure 1).

The hybrid arch concept relies on extension of the proximal LZ to zone 0, requiring great vessel debranching to maintain brain perfusion. Aortic arch anatomy and proximal and distal LZ affect which hybrid operation is most appropriate.

### Type I Hybrid Arch Repair

The Type I repair is typically employed in patients with aneurysmal disease that is confined solely to the aortic arch. There is suitable native aorta for proximal LZ in Z0 and distal LZ in Z3/Z4. This anatomic situation permits great vessel debranching followed by concomitant antegrade TEVAR or delayed retrograde TEVAR.

The primary benefit of this approach is the avoidance of cardiopulmonary bypass (CPB), cardiac arrest and circulatory arrest.



*Figure 1: Classification of landing zones for TEVAR. Zone 0 includes the ascending aorta up to the innominate artery. Zone 1 includes the aorta from the innominate artery to the left carotid artery. Zone 2 includes the aorta from the left carotid to the left subclavian artery. Zone 3 includes the proximal descending aorta distal to the left subclavian artery and Zone 4 includes the mid descending aorta. Reprinted with permission from Seminars in Cardiothoracic and Vascular Anesthesia.*



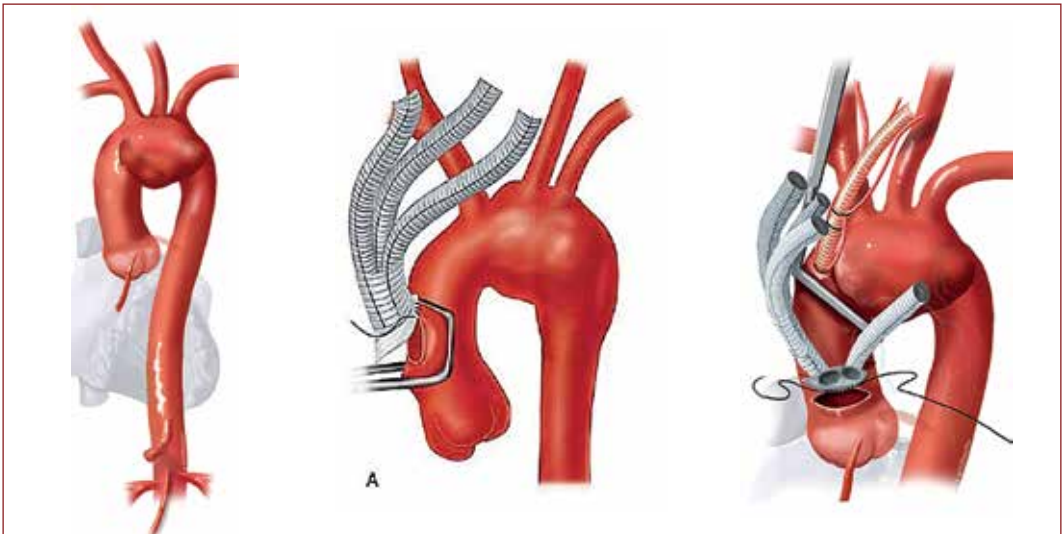
The approach is via a median sternotomy. All three brachiocephalic vessels are encircled with a vessel snare and sequentially sewn to a branched graft after the proximal aortic anastomosis has been completed using a partial occlusion clamp (Figure 2A and B).

An alternative technique employs transposition of the left subclavian artery to the left carotid, which can in turn be transposed to the innominate artery. In the setting of an extremely large aortic aneurysm, access to the left subclavian artery can pose a challenge. Therefore, some surgeons prefer to revascularise the left subclavian artery with a carotid subclavian bypass using an additional supraclavicular incision; or alternatively cover the left subclavian artery with the stent graft, particularly in the setting of a non-dominant left vertebral artery.

The proximal end of the trifurcated graft is sewn to the aorta before sequentially anastomosing the brachiocephalic vessels. This can be performed without CPB if the ascending aorta has suitable length to accommodate a side-biting clamp. It is imperative to ensure 2cm of proximal LZ for optimal seal when deciding upon the site of the proximal portion of the surgical graft. In the setting of a relatively short ascending aorta, CPB and aortic occlusion may be required to construct the proximal portion of the surgical graft.

The brachiocephalic vessels should be debranched sequentially with restoration of cerebral perfusion after each completed anastomosis. Any observed changes in EEG and NIRS when temporarily occluding each head vessel should be carefully investigated and alternative maneuvers should be used to optimize cerebral perfusion.

The endograft can be deployed to exclude the aortic aneurysm after the proximal landing zone has been created. This can be accomplished in an antegrade fashion using a limb of the surgical graft. Antegrade deployment of the stent graft permits precise deployment as there is less transmitted torque via a shorter delivery system. Moreover, manipulation of wires and catheters through the aortic arch may be facilitated by the sternotomy, permitting the surgeon access to the aorta. Retrograde transfemoral delivery is an optional approach, but there remains the risk of peripheral vascular complications when using a



*Figure 2: A. Type I hybrid repair of the aortic arch. The arch vessels are sequentially revascularised following the proximal surgical anastomosis.*

retrograde approach. Type I repairs are most suitable in patients where the proximal aorta is not aneurysmal and less than 4cm in diameter. In patients with ascending aortic enlargement >3.7cm, in our experience there is increased risk for retrograde type A dissection after stent deployment<sup>12</sup>.

### Type II Hybrid Arch Repair

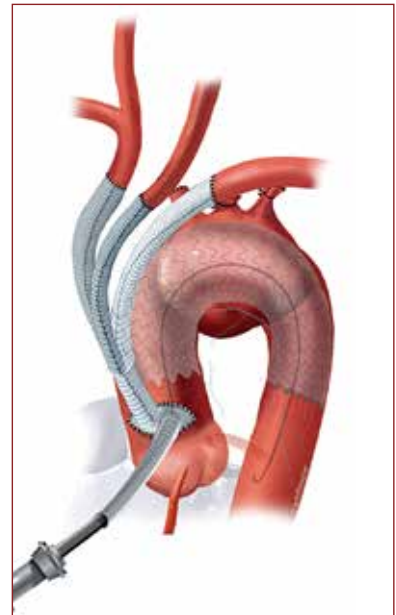
The type II arch hybrid repair is generally performed when there is suitable Z3/Z4 distal LZ, but without a satisfactory proximal Z0 LZ. Type II hybrid repairs require circulatory arrest to accomplish the proximal LZ reconstruction. The open procedure entails creation of a Z0 LZ by proximal aorta reconstruction as well as great vessel debranching (Figure 3). The proximal extension of the operation may involve the aortic root complex requiring aortic valve repair/replacement or aortic root procedures.

All patients are placed on cardiopulmonary bypass with arterial cannulation using the ascending aorta or axillary artery. Axillary cannulation may facilitate the performance of antegrade cerebral perfusion during circulatory arrest. Alternatively, direct ostial cannulation of the great vessels with 13F or 15F balloon-tipped perfusion cannulae can be used to perform antegrade cerebral perfusion during circulatory arrest. The right atrium is the site for venous drainage, and where retrograde cerebral perfusion will be performed, the superior vena cava is separately cannulated and encircled with a heavy tape for snaring. We also routinely use retrograde cardioplegia and perform left ventricular venting via the right superior pulmonary vein

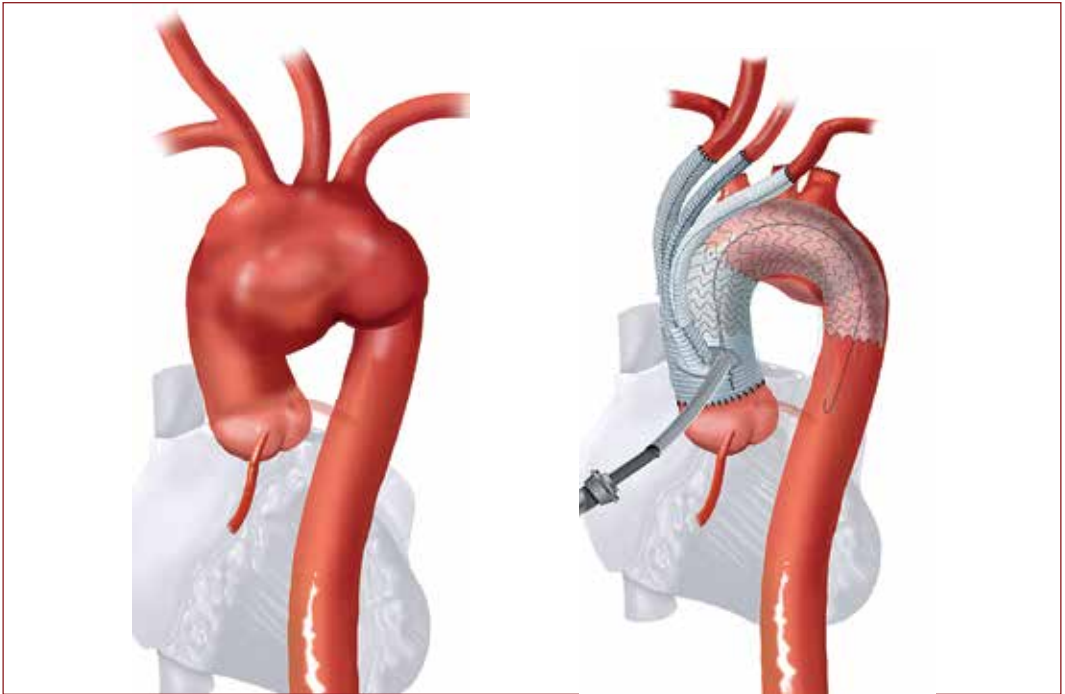
After achieving myocardial arrest with aortic cross-clamping and a combination of antegrade and retrograde cardioplegia, attention is directed to the proximal aorta. Any intervention to the aortic root or aortic valve is addressed at this point, while the patient is being cooled on cardiopulmonary bypass. If antegrade cerebral perfusion will be performed, we elect to use moderate hypothermia between 24-28°C. For retrograde cerebral perfusion, we typically anticipate a circulatory arrest period of less than 20 minutes and use deep hypothermia between 18-20°C.

The dissection of the great vessels and aortic arch may commence prior to initiating CPB and is completed during the period of cooling. If no aortic root procedures are indicated, the proximal anastomosis is completed during the cooling phase. A 4-limb branched graft with a main body component for ascending aortic replacement is sutured just above the sinotubular junction (Figure 4).

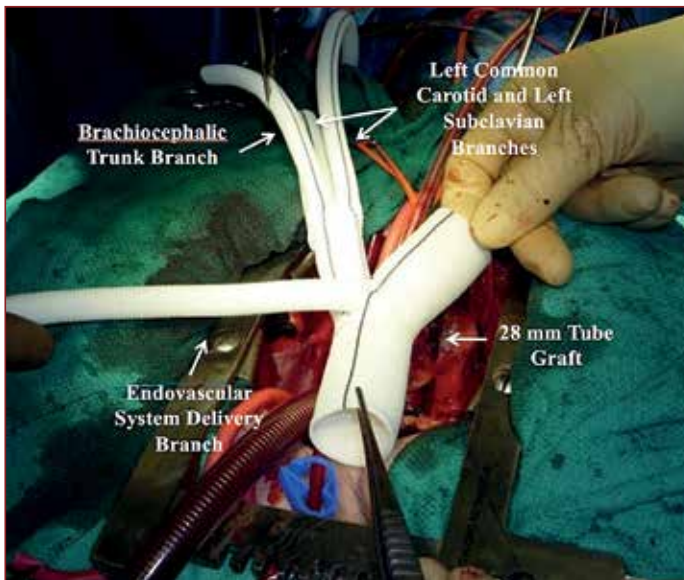
When tailoring the main body graft for ascending aorta replacement, it is important to consider the future LZ location and position the branched graft portion just above the sinotubular junction and positioned anterolaterally. This is key to optimize the proximal LZ and allows the branched grafts to remain on the side of the replaced aorta, and not in direct contact with the sternum.



*Figure 2: B. This is followed by deployment of a stent-graft either in an antegrade or retrograde technique. Reprinted with permission from Seminars in Cardiothoracic and Vascular Anesthesia.*



*Figure 3: A type II repair where the arch vessels are revascularised along with the replacement of the ascending aorta to create a landing zone 0 for the TEVAR. This figure demonstrates antegrade deployment of TEVAR. Reprinted with permission from Seminars in Cardiothoracic and Vascular Anesthesia.*



*Figure 4: Example of a branched graft that can be used in the setting of a hybrid arch repair. Reprinted with permission from Seminars in Cardiothoracic and Vascular Anesthesia*

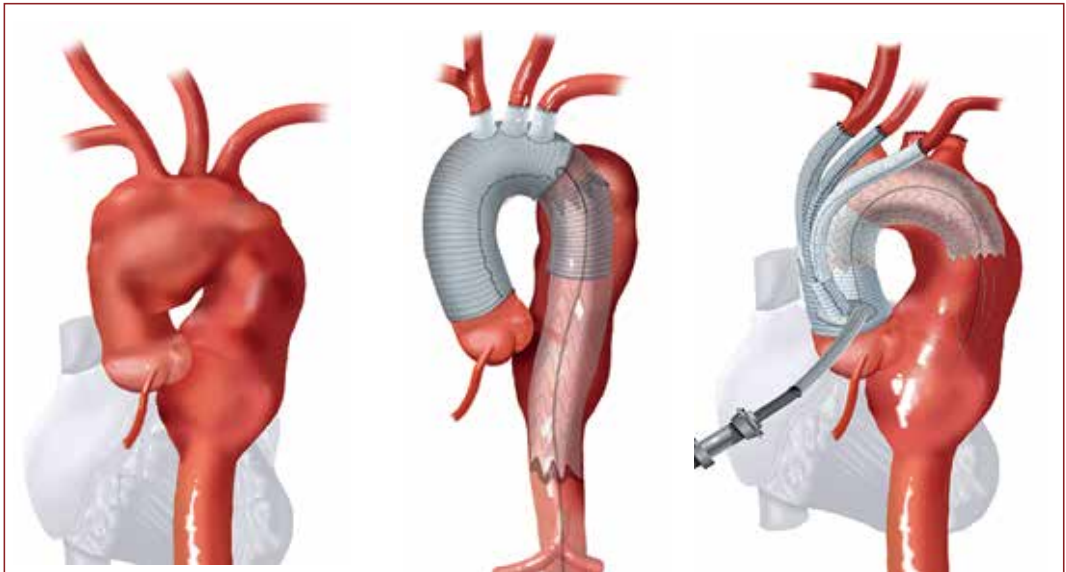
After the period of cooling is complete, preparations are made for circulatory arrest. The patient is placed in Trendelenburg, and it is imperative to maintain clear and direct communication with the anesthesiology and perfusion team members. The distal anastomosis is performed as a transverse hemiarch, and does not have to be overly extensive, as the endograft will exclude this portion. The fourth limb of the graft can be cannulated for resuming cardiopulmonary bypass. Each great vessel is individually anastomosed to the respective limb of the branched graft, with the left subclavian artery first, then

left common carotid artery, and finally the innominate artery. Sizing is critical during this portion, as inappropriate sizing can lead to kinking of the graft branch and possible flow limitation or thrombosis. During great vessel reimplantation, the patient is rewarmed in anticipation of termination of cardiopulmonary bypass. In instances where the subclavian artery anastomosis is anticipated to be difficult, this can also be done during the period of circulatory arrest. Alternatively, if the anatomy is extremely unfavorable, a two-branch arch reconstruction can be performed debranching the innominate artery and left common carotid only. Delayed carotid-subclavian bypass can be performed with coiling of the left subclavian artery at the time of TEVAR.

When concomitant antegrade TEVAR delivery will be performed, the fourth limb of the branched graft can be used to deploy the device. It is important that this limb be at least 10mm, to accommodate the graft sheath. Positioning of the endograft should be confirmed with fluoroscopy. An alternative approach is to perform the TEVAR procedure later using a retrograde femoral artery approach. A radiopaque marker should be placed at the time of arch reconstruction to demarcate the proximal takeoff of the 4-limb branch graft to facilitate TEVAR positioning. Metallic clips can be placed, and we also leave a radiopaque pacing wire encircled around the main body of the tube graft just distal to the takeoff of the 4-limb branch to delineate the most proximal extent of TEVAR deployment. Completion angiography to confirm adequate seal is routine.

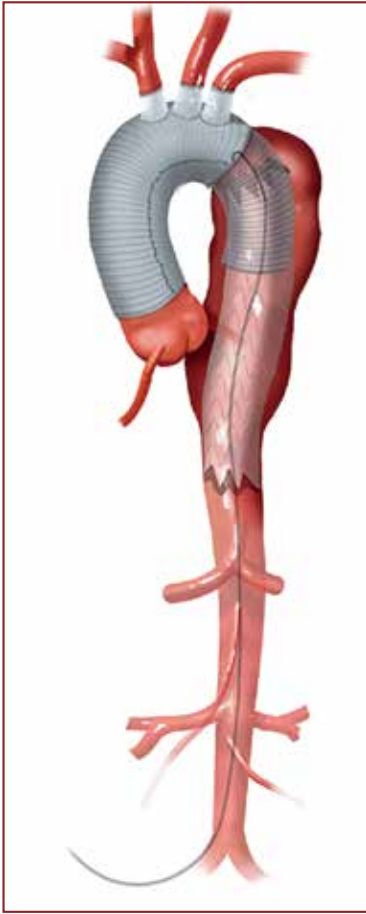### Type III Hybrid Arch Repair

A Type III repair is a 2-stage strategy consisting of a first-stage proximal reconstruction using either a conventional open arch elephant trunk technique or the “stented” elephant trunk technique (Figure 5). This procedure is not a classic debranching procedure, and is utilized in patients with aneurysm of ascending, arch, and descending aorta, or mega-aorta



*Figure 5: A. Type III repair where the first stage includes replacement of the ascending aorta and arch vessels with an open or stented elephant trunk.*





*Figure 5: B. The second stage includes a TEVAR to exclude the distal thoracic aortic aneurysm. Reprinted with permission from Seminars in Cardiothoracic and Vascular Anesthesia.*

mean arterial pressure goal to 90-100mm Hg to augment spinal cord perfusion. These blood pressure targets are especially critical in patients with coverage of the aorta below T6, and in patients with prior abdominal aortic repair. Intrathecal pressures with lumbar drains are carefully monitored and should be maintained between 10-12mm Hg to promote appropriate spinal cord perfusion. Achieving this target pressure usually requires drainage of cerebrospinal fluid in the intraoperative and postoperative period. Vasopressors should be used as needed to achieve these blood pressure goals. Once neurologic function is confirmed to be preserved, the lumbar drained can be capped and subsequently removed 24 hours later.

syndrome. In contrast to type I and II repairs, both the proximal landing zones in the ascending aorta as well as the distal landing zones in the descending thoracic aorta are aneurysmal and unsatisfactory for endovascular repair in type III repairs. Suitable proximal landing zone 0 can be reconstructed like type II hybrid repairs. However, distal aneurysmal extension into the descending thoracic aorta requires endograft exclusion of the entire descending thoracic aorta.

A completion endovascular repair with endograft deployment at the level of the celiac artery is often required. Given the extensive involvement of the descending thoracic aorta and the requirement for multiple endografts, a 2-stage retrograde approach from the iliofemoral vasculature may be more feasible and advantageous.

There are significant benefits to the type III hybrid arch repair. In contrast to the conventional open single-stage repair, performance of the distal anastomosis via a morbid open surgical incision is avoided. The second stage (TEVAR) portion of this hybrid repair is minimally invasive, and therefore the time interval to second stage may be decreased. For many patients, the completion endovascular procedure stage can be performed within a relatively short period, potentially during the index hospitalization. The type III hybrid repair offers these patients a less morbid second stage, and is associated with a shorter interval to their second-stage completion procedure.

## Postoperative Care

The primary goals in the postoperative management of patients who have undergone arch reconstruction include spinal cord protection and adequate end organ perfusion. Spinal cord perfusion is preserved by achieving mean arterial pressure of at least 80-90mm Hg in all patients. In those patients who have undergone particularly extensive coverage of the descending thoracic aorta, we increase the

## Results

Because aortic arch aneurysm is a relatively rare condition and the hybrid technique is an evolving procedure, long-term data are lacking. Several institutions have reported their results of the hybrid approach to the aortic arch, and have documented acceptable peri-procedural and short-term outcomes. From 2005-2013 we reported on 104 patients who underwent a hybrid arch repair<sup>14</sup>. Forty-seven patients were operated on for degenerative aneurysmal disease. In the aneurysm cohort, the in-hospital mortality and stroke rate were each 8% (n=3). The paraplegia rate was 5.5% (n=2). Freedom from all-cause mortality was 48% at 5 years.

A meta-analysis examined procedural outcomes in 46 hybrid arch repair studies<sup>15</sup>. The studies were classified according to patients who underwent aortic arch debranching and those who underwent frozen elephant trunk procedures. The pooled estimate for in-hospital mortality was 11.9% for the debranching group and 9.5% for the elephant trunk group. Cerebrovascular events were identified in 7% of patients, and irreversible spinal cord ischemia occurred in 3.6% in the debranching group and 5% in the elephant trunk group. Renal failure requiring dialysis occurred in approximately 4.5% of the patients.

## Conclusion

Further data from prospective trials comparing conventional and hybrid aortic arch approaches are needed to define those who stand to benefit most from the hybrid technique. With further progress in technology, complete endovascular replacement of the entire thoracic aorta and the arch will likely be possible, thus affording patients at high risk for conventional arch surgery the opportunity to undergo a hybrid reconstruction.

Disclosures: J.E. Bavaria receives research grants from Edwards Lifesciences Corporation, Medtronic Inc, COOK Medical, Boston Scientific, W.L. Gore & Associates and St Jude Medical.

## References

1. Thomas M, Li Z, Cook DJ, et al. Contemporary results of open aortic arch surgery. *J Thorac Cardiovasc Surg* 2012;144(4):838-844.
2. Settepani F, Cappai A, Basciu A, et al. Outcome of open total arch replacement in the modern era. *J Vasc Surg* 2016;63(2):537-545.
3. Makaroun MS, Dillavou ED, Kee ST, et al. Endovascular treatment of thoracic aortic aneurysms: Results of the phase ii multicenter trial of the gore tag thoracic endoprosthesis. *J Vasc Surg* 2005;41(1):1-9.
4. Szeto WY, Bavaria JE, Bowen FW, et al. The hybrid total arch repair: Brachiocephalic bypass and concomitant endovascular aortic arch stent graft placement. *J Card Surg* 2007;22(2):97-102; discussion 103-104.
5. Szeto WY, Bavaria JE. Hybrid repair of aortic arch aneurysms: Combined open arch reconstruction and endovascular repair. *Semin Thorac Cardiovasc Surg* 2009;21(4):347-354.
6. Bavaria J, Milewski RK, Baker J, et al. Classic hybrid evolving approach to distal arch aneurysms: Toward the zone zero solution. *J Thorac Cardiovasc Surg* 2010;140(6 Suppl):S77-80; discussion S86-91.
7. Lee CW, Beaver TM, Klodell CT Jr., et al. Arch debranching versus elephant trunk procedures for hybrid repair of thoracic aortic pathologies. *Ann Thorac Surg* 2011;91(2):465-471.

8. Preventza O, Aftab M, Coselli JS. Hybrid techniques for complex aortic arch surgery. *Tex Heart Inst J* 2013;40(5):568-571.
9. Preventza O, Bakaeen FG, Cervera RD, et al. Deployment of proximal thoracic endograft in zone 0 of the ascending aorta: Treatment options and early outcomes for aortic arch aneurysms in a high-risk population. *Eur J Cardiothorac Surg* 2013;44(3):446-452; discussion 452-443.
10. Patel HJ, Dake MD, Bavaria JE, et al. Branched endovascular therapy of the distal aortic arch: Preliminary results of the feasibility multicenter trial of the gore thoracic branch endoprosthesis. *Ann Thorac Surg* 2016;102(4):1190-1198.
11. Sultan I, Bavaria JE, Szeto W. Hybrid techniques for aortic arch aneurysm repair. *Semin Cardiothorac Vasc Anesth* 2016;20(4):327-332.
12. Vallabhajosyula P, Szeto WY, Desai N, et al. Type II arch hybrid debranching procedure. *Ann Cardiothorac Surg* 2013;2(3):378-386.
13. Hiratzka LF, Bakris GL, Beckman JA, et al. 2010 ACCF/AHA/AATS/CR/ ASA/SCA/SCAI/SIR/STS/SVM guidelines for the diagnosis and management of patients with thoracic aortic disease: A report of the American College of Cardiology Foundation/ American Heart Association task force on practice guidelines, American Association for Thoracic Surgery, American College of Radiology, American Stroke Association, Society of Cardiovascular Anesthesiologists, Society for Cardiovascular Angiography and Interventions, Society of Interventional Radiology, Society of Thoracic Surgeons, and Society for Vascular Medicine. *Circulation* 2010;121(13):e266-369.
14. Bavaria J, Vallabhajosyula P, Moeller P, et al. Hybrid approaches in the treatment of aortic arch aneurysms: Postoperative and midterm outcomes. *J Thorac Cardiovasc Surg* 2013;145(3 Suppl):S85-90.
15. Moulakakis KG, Mylonas SN, Markatis F, et al. A systematic review and meta-analysis of hybrid aortic arch replacement. *Ann Cardiothorac Surg* 2013;2(3):247-260.

## Chapter 2

# Aortic Valve-Preserving Surgery

*Omar Nawaytou and Gebrine El Khoury*

---

*“Facile est inventis addere”*



## Introduction

The first reports of surgical repair of the aortic valve are as old as the advent of cardiopulmonary bypass. Taylor and colleagues in 1958 proposed a circumclusion procedure for repair of aortic regurgitation, a procedure still used today with some modification, for aortic valve annuloplasty<sup>1</sup>. Starzl proposed an aortic valve bicuspidisation operation around the same time<sup>2</sup>. Apart from other anecdotal reports as well as the sporadic use in cases of limited endocarditis, the adoption of aortic valve repair in adult patients has not been widely taken up due to its technical complexity and early repair failures, as well as the excellent results of aortic valve replacement. It is only with the introduction of aortic valve-sparing root replacement (VSRR) in the early 1990's as a treatment option for aortic root aneurysms that interest in valve preservation has shown resurgence<sup>3, 4</sup>.

Aortic valve preservation thus emerged as a favourable option for treating young patients with aortic regurgitation (AR) as it obviates the need for a valve prosthesis with the associated increased risks of bleeding and thromboembolism with mechanical valves and structural valve degeneration necessitating future reoperations with bioprostheses<sup>5</sup>. In addition, there are reports of its haemodynamic superiority over valve replacement<sup>6</sup>.

The current techniques of valve-preserving surgery include the two most widely used VSRR procedures, reimplantation and remodelling and their different modifications, as well as many evolving leaflet repair and annuloplasty techniques. As such, the surgical community is still using the terms aortic valve-sparing root surgery and aortic valve repair as two separate treatment entities denoting two different reconstruction procedures for the aortic root and valve. As discussed in previous publications, we believe that we need to move away from this practice for the following reasons<sup>7</sup>:

1. It has been well established that the aortic valve should be thought of as a valve complex that includes, in addition to the leaflets, the functional aortic annulus denoting the sinotubular junction (STJ) and the ventriculo-aortic junction (VAJ) as well as the sinuses of Valsalva. All of these structures play an integral and combined role in achieving valve competency<sup>8</sup>.
2. Pathologies resulting in valve incompetence often affect the aortic valve complex at multiple levels necessitating the use of multiple procedures to achieve a sound and durable repair. For example, most bicuspid aortic valves (BAV) referred for repair display a degree of annular and sinus dilatation in addition to the leaflet pathology. Patients presenting with aortic root dilatation, especially in cases of connective tissue disorders, often exhibit leaflet involvement especially with long-standing valvular regurgitation<sup>7</sup>.
3. It is becoming more common to supplement one procedure addressing the root or the leaflets with the other to achieve a more durable long term repair. For example, it is now more widely accepted to supplement leaflet repair techniques in BAV or connective tissue disorders with an annuloplasty procedure in young patients to prevent future dilatation and repair failure. The preferred annuloplasty procedure at our institution is the David's reimplantation procedure especially in the presence of thin aortic sinus tissue regardless of aortic root dimension. It is also becoming more common to find that patients undergoing a valve-sparing root replacement are undergoing leaflet plication to achieve a taller effective leaflet height that correlates with a more durable repair in the long term<sup>9</sup>.

We believe that the surgical community should start to adopt a common nomenclature that describes treatment of pathologies rather than operations to allow an informed comparison of results among different units.

## Anatomy

Despite satisfactory outcomes, this field continues to expand because of advances in the understanding of the complex structure of the aortic root and how its different functional components interact to achieve valve competency. It is beyond the scope of this chapter to discuss the detailed anatomy of the aortic valve and root but certain aspects of it need to be highlighted for better understanding of the surgical techniques. As discussed earlier, the aortic valve should be described as a functional complex that includes the semilunar leaflets or cusps, the aortic annulus with its two components, the sino-tubular junction (STJ) and the ventriculo-aortic junction (VAJ), and finally the sinuses of Valsalva.

## Cusp morphology

The normal aortic valve has three leaflets: the right, left and non-coronary cusps corresponding to the adjacent sinuses of Valsalva. These cusps and their corresponding free margins are seldom of equal size and the span of the three sinuses and therefore their contribution to the total circumference of the root is unequal<sup>8</sup>. Appreciation of this fact is paramount in planning where to place the commissures within the graft when performing a VSRR.

Another important concept is the relationship between cusp mobility, free margin length, and length of basal cusp insertion. The following formula could depict this:

**Cusp mobility  $\approx$  Free margin length/ Length of cusp insertion**

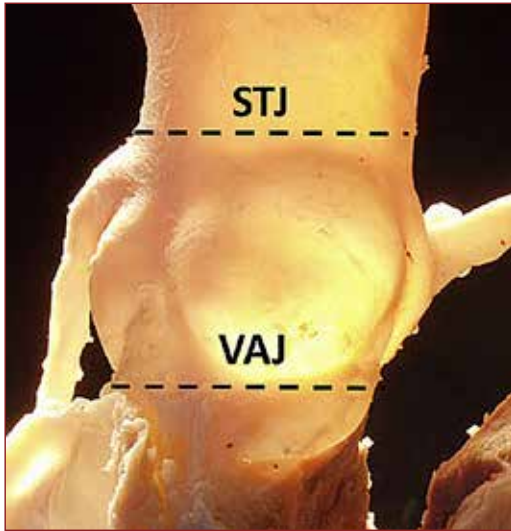
Excessive cusp mobility because of increased free margin length or decreased length of cusp insertion due to an over reductive annuloplasty or using a small size prosthesis in VSRR can lead to cusp prolapse. Similarly, reversing this ratio can lead to reduced cusp mobility and restriction. This can be observed in bicuspid aortic valves, which have a larger length of cusp insertion relative to the free margin, as well as in cases of overcorrection of cusp prolapse by plication of the free margin length<sup>7</sup>.

Finally, it is important to understand the concepts of geometric and effective leaflet height and their implications in valve repair<sup>10</sup>. The geometric leaflet height is the length of the leaflet in its mid part from the nodule of Arantius to the nadir of its basal attachment. It is thus a marker of the adequacy of leaflet tissue and an indirect indicator of its mobility post repair. The effective leaflet height is the distance between the highest point of coaptation and the level of the basal ring or annular plane in cross section or in long axis view on echocardiography. An effective leaflet height of  $\geq 9$ mm, in addition to other parameters, is an indicator of a durable long term repair. This should not be confused with the coaptation length, which is the distance of coaptation when the aortic leaflets are touching in mid diastole. A coaptation length of 2mm is satisfactory to achieve valve competence in a root with a normal sized functional aortic annulus. The longer the coaptation length, however, the more the reserve in case of future annular dilatation. It is thus recommended to achieve a coaptation length of  $\geq 4$ mm at the end of repair to ensure long term durability<sup>7</sup>.

## Functional Aortic Annulus

This is made up of a distal annulus, which is the sino-tubular junction corresponding to a line at the highest point of cusp insertion, and the proximal annulus that is the ventriculo-aortic junction or basal ring, which is an imaginary line joining the nadirs of the cusp insertions (Figure 1).

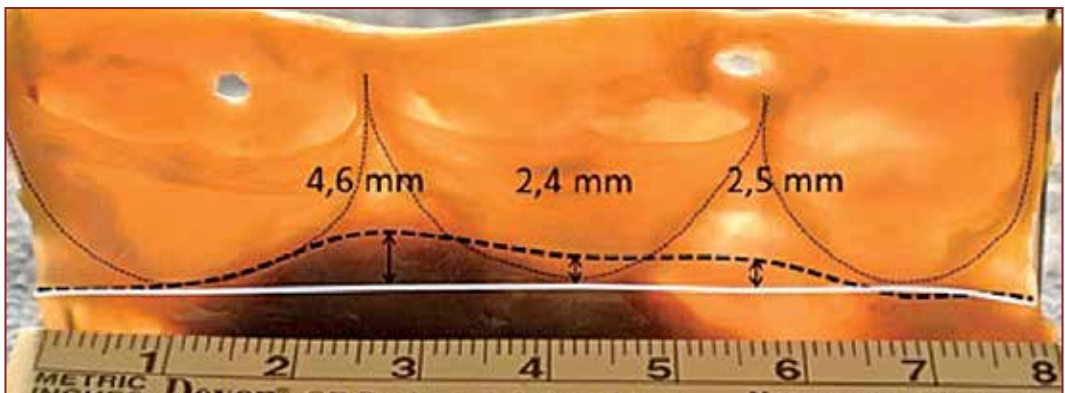
Anderson and colleagues have shown in numerous publications that the aortic valve annulus is not merely a simple ring of fibrous tissue surrounding the valve leaflets, but a complex interplay of fibrous and muscular tissues that varies in composition along the valve circumference and at various levels of the left ventricular outflow tract (LVOT)<sup>11</sup>. The basal ring is therefore at a different level from the anatomical ventriculo-aortic junction. We have demonstrated previously that this basal ring lies below the external ventriculo-aortic junction at the region between the left/right commissure and the right/non commissure (Figure 2)<sup>12</sup>.



*Figure 1: The functional aortic annulus (FAA) is composed of the sinotubular junction (STJ) distally and the ventriculoaortic junction (VAJ) proximally.*

In addition, it is this zone that displays the most profound annular dilatation in AR. We can try to explain this by the fact that the anterior annulus lacks the support of the fibrous skeleton of the heart present posteriorly. In other words, this anterior VAJ dilatation represents a “migration” of the supporting muscular interventricular septum (IVS) anteriorly and outwards towards the right ventricular outflow tract (RVOT). Consequently, annular support as a repair adjunct in regurgitant valves with a dilated annulus must address this area near the IVS.

The obstacle in addressing the annulus in this anterior region, however, lies in the fact that this area is inaccessible externally with routine root dissection due to the insertion of the right



*Figure 2: Dissected aortic root showing the discrepancy in the level of the anatomical ventriculoaortic junction (dotted black line) and the basal ring (continuous white line).*

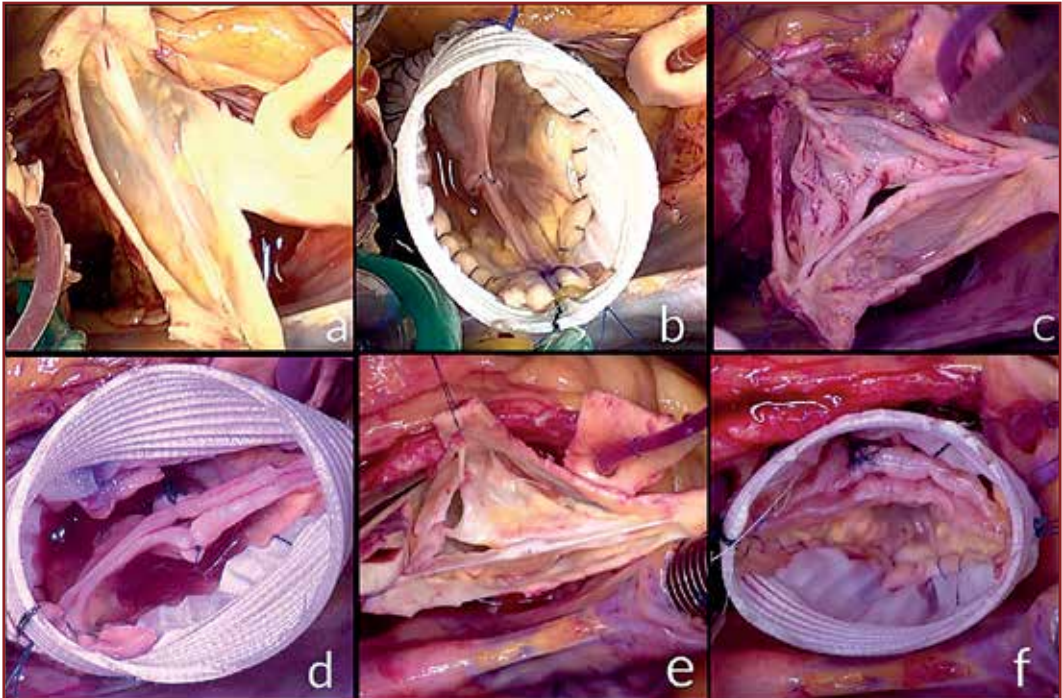
ventricular (RV) muscle bundles. Our group routinely dissects the annulus deeply along this anterior aspect to reach the level of the basal ring externally albeit opening the RV if necessary.

### Bicuspid Aortic Valves (BAV)

BAVs have a complex pathology that associates varying degrees of cusp dysmorphia and aortopathy. Sievers in 2007 proposed a classification system for aortic valves with cusp fusion based on the absence or presence of the remnant of cusp fusion, called the raphe<sup>13</sup>. This allowed distinction of BAVs into three types; Type 0 with no raphe; Type 1 with a single raphe; and Type 2 with two raphes.

**Type 0 valves** – these valves have no raphe. They generally present 2 symmetrical sinuses of Valsalva with a commissural orientation of 180°. The mechanism of aortic regurgitation at the cusp level is always prolapse of one or both cusps because of the presence of excess cusp tissue (Figure 3a).

**Type 1 valves** - these valves have a median raphe on the conjoined cusp, an asymmetric



*Figure 3: Intraoperative pictures of Sievers type 0 and two different examples of type 1 prolapsing bicuspid valves. (a) Type 0 with commissural orientation of 180° and anteroposterior cusp orientation, (b) Repair consisted of central plication on each cusp and valve-sparing reimplantation (VSR) at 180°, (c) Type 1 prolapsing with commissural orientation of 180° and right-left cusp fusion. (d) Repair consisting of thinning of the raphe, central plication of both cusps and VSR at 180°. (e) Type 1 prolapsing with commissural orientation of 180° and right-left cusp fusion, the right side of the raphe presents a ruptured band inducing prolapse of right portion of the fused cusp. (f) Repair consisting of debridement and direct closure of the raphe, VSR at 180°.*

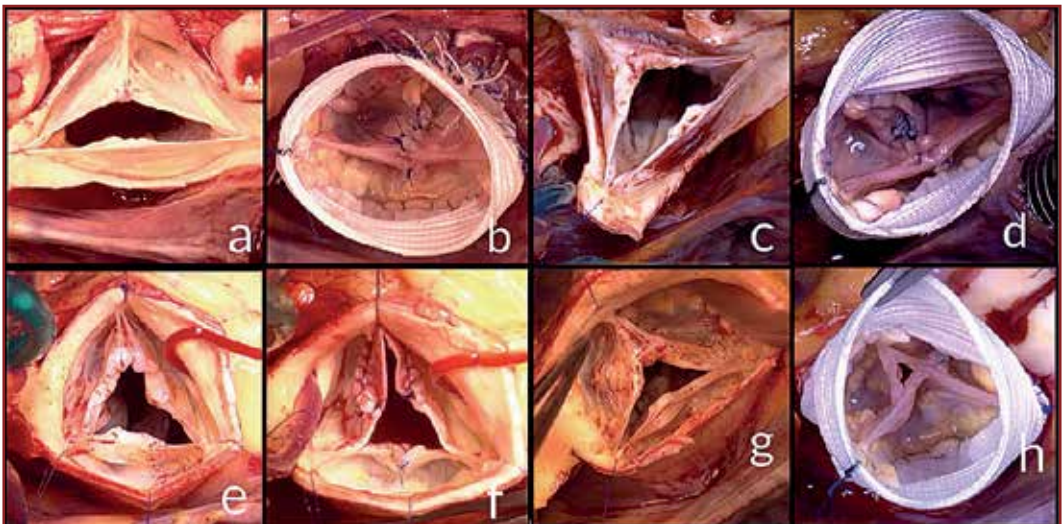


distribution of the aortic sinuses with a base of leaflet implantation greater and higher on the conjoined cusp than on the non-conjoined cusp. The mechanism of aortic regurgitation in Type 1 BAV differs according to the completeness of cusp fusion<sup>14</sup>. On one side of the spectrum, there is the complete or almost complete cusp fusion. These valves present with a non-distinct raphe sometimes only apparent as a faint thickening of the aortic wall (Figures 3c and e) The mechanism of aortic regurgitation in these cases is, like in Type 0, prolapse of the conjoined cusp. On the other side of the BAV Type 1 spectrum, the conjoined cusp is incompletely fused. The raphe is thicker, fibrous and at times calcified with an implantation higher on the aortic wall forming in some cases a pseudo-commissure. The mechanism of aortic regurgitation in this setting is secondary to a central triangular gap in coaptation created by the restrictive cusp and inadequate leaflet tissue (Figure 4).

**Type 2 valves** - we believe that Type 2 valves in the Sievers classification should not be considered with BAV since these are unicuspid valves whose surgical repair differs completely from that of BAV.

Another important anatomical feature to consider when repairing BAVs is the orientation of the commissures (Figure 5). This is always 180° in Type 0 valves and equals the angle subtended by the free margin of the non-conjoined cusp in Type 1 valves.

Aicher and colleagues have shown that commissural orientation is a risk factor for late failure of BAV repair on both uni- and multivariate analysis<sup>15</sup>. Valves with a larger than 160° angle usually have adequate leaflet tissue allowing symmetrical repair. Valves with an angle smaller than 160° are associated with a restrictive raphe and have inferior leaflet



**Figure 4:** Intraoperative pictures of four different examples of Sievers type 1 restrictive bicuspid valves. (a) Type 1 restrictive with commissural orientation of 160° and right-left cusp fusion. (b) Repair consisting of thinning and direct closure of the raphe, central plication of the non-fused cusp and valve sparing reimplantation (VSR) at 180°. (c) Type 1 restrictive with commissural orientation of 130° and right-left cusp fusion. (d) Repair consisting of thinning and direct closure of the raphe, central plication of the non-fused cusp and VSR at 180°. (e) Type 1 restrictive with commissural orientation of 120° and right-left cusp fusion. (f) Repair consisting of resection of the raphe, tricuspoidisation of the valve by commissural reconstruction with pericardium. (g) Type 1 restrictive with commissural orientation of 120° and right-left cusp fusion. (h) Repair consisting of tricuspoidisation of the valve by debridement and thinning of the raphe and VSR at 120°.

mobility post repair unless augmented with a pericardial patch.

Finally, regurgitant BAVs nearly always display a degree of annular dilatation that needs to be addressed concomitantly with cusp repair. This is achieved by either a reimplantation procedure or by a separate external annuloplasty ring when the aortic sinuses are both non-dilated and of adequate thickness.

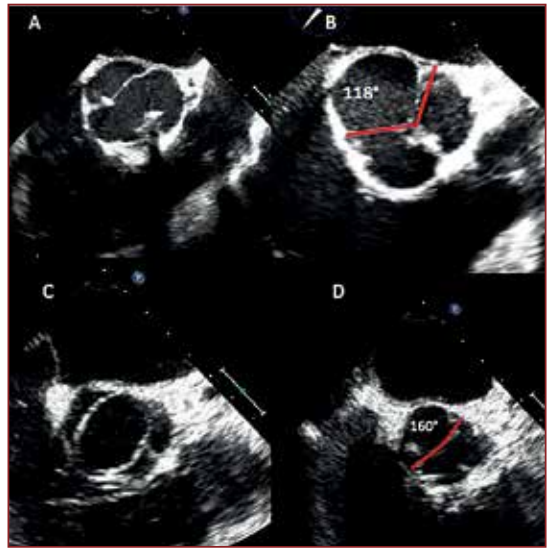
## Indications for valve-preserving surgery

Initially, valve-sparing root surgery, in the form of reimplantation and remodelling, was proposed for treating degenerative aortic root aneurysms with normal valve structure and function or mild central regurgitation. As surgical experience expanded over time, the indications have broadened to include patients with severe valve regurgitation, primary leaflet pathology (prolapse, restriction, mild calcification), bicuspid aortic valves, acute aortic dissections, infective endocarditis, and reoperations for failed previous repair or pulmonary autograft failure following the Ross procedure<sup>16</sup>.

Currently, the two commonest indications are aortic root aneurysms and severe aortic valve regurgitation with pliable aortic cusp tissue. We have proposed a functional classification system for aortic regurgitation according to leaflet motion similar to the Carpentier system for mitral regurgitation<sup>17</sup> (Figure 6). Type 1 disease is aortic regurgitation with normal cusp motion and is caused by lesions of the FAA or, less commonly, leaflet perforations; type 2 disease is caused by excessive motion or prolapse, and type 3 disease is caused by restrictive cusp disease such as in rheumatic cases, excessive calcification, or in extremely restrictive BAV disease. It is worth noting that multiple lesions can simultaneously contribute to the mechanism of AR; for example, dilatation of the aortic root may induce alterations in cusp geometry and eventually cusp prolapse. The second notion is that severe chronic valve insufficiency, as with the mitral valve, can lead to annular dilatation. Thus, any correction of cusp pathology in the setting of chronic severe AR should be accompanied by annuloplasty of the functional aortic annulus and its two components.


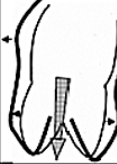
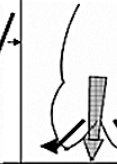



## Patient Selection

There are several factors to consider before embarking on a valve preservation procedure, the most important of which is whether one can achieve a sound repair with no or trivial AR which is durable over time. To achieve this, one must consider how favourable the anatomy of the valve is for repair, the experience of the operating surgeon and their team and whether acceptable alternatives to valve preservation are present. Another deciding factor is the patient's age, choice, and lifestyle in an argument similar to when deciding on a mechanical versus a bioprosthesis in cases of valve replacement.



*Figure 5: TOE measure of commissural orientation in mid oesophageal short axis view. A and B: Type 1 valve with a near 120° orientation; C and D: Type 1 valve with a near 180° orientation.*

The sine qua non of valve preservation as far as favourable anatomy is concerned is leaflet pliability. As discussed earlier, this is represented by an adequate geometric height as well as minimal leaflet calcification, fibrosis and retraction. It is difficult to quantify how much geometric height is adequate as there is a great variability between individuals, gender, and tricuspid versus bicuspid valves. Schäfers and colleagues have shown that, on average, a leaflet height of 20mm in tricuspid valves and 24mm in bicuspid valves should be adequate<sup>18</sup>. Severe annular dilatation (>28mm) preoperatively has been shown to decrease the long-term durability of valve repair<sup>19</sup>. The direction of the jet of regurgitation also impacts on valve repair. Eccentric jets, especially in tricuspid valves, are more difficult to repair than central jets as they are a marker of leaflet prolapse, which requires more complex repair techniques. The need for extensive pericardial patch augmentation also has unfavourable results. Finally, rheumatic, fibrosed, more than mildly stenosed and heavily calcified valves (type 3 AR in our functional classification) have a worse prognosis and repair should only be contemplated in highly selected cases (young females contemplating conception) with the patients sufficiently informed of the high risk of early reoperation. Acute aortic dissection, BAV, and the presence of minimal calcification or stenosis are not contraindications for valve preservation.

AI Class	Type I Normal cusp motion with FAA dilatation or cusp perforation				Type II Cusp Prolapse	Type III Cusp Restriction
	Ia	Ib	Ic	Id		
Mechanism						
Repair Techniques (Primary)	STJ remodeling Ascending aortic graft	Aortic Valve sparing: Reimplantation or Remodeling with SCA	SCA	Patch Repair Autologous or bovine pericardium	Prolapse Repair Plication Triangular resection Free margin Resuspension Patch	Leaflet Repair Shaving Decalcification Patch
(Secondary)	SCA		STJ Annuloplasty	SCA	SCA	SCA

*Figure 6: El Khoury functional classification for aortic regurgitation (SCA: Subcommissural annuloplasty is used much less frequently now than in the past).*

## Pre-operative Preparation

A detailed history and physical examination is paramount for successful valve preservation surgery. Important aspects to note are the patient's age, lifestyle choices and occupation. A family history and physical signs of BAV or connective tissue disorders are important in deciding on the optimal root management procedure (VSRR versus annuloplasty). Physical signs of important valve stenosis may also preclude valve repair.

Routine preoperative blood analysis and a chest X-ray are performed. An ECG is important to detect any preoperative conduction abnormalities, which may impact on the need for postoperative permanent pacemaker insertion. The single most important investigation, however, is a detailed echocardiogram. It is common in our unit to resort to transoesophageal echocardiography as a preoperative assessment tool prior to deciding on valve repair. Aspects of valve assessment include the degree and direction of the regurgitant jet assessed both qualitatively and quantitatively; the number and mobility of the valve cusps; when a BAV is present, the number of raphe, degree of raphe fusion, and commissural orientation is assessed; the presence of calcification, fibrosis, and perforations; and finally, root dimensions and geometry. Three-dimensional images are often acquired and are very helpful in depicting the root geometry and its dynamics during the cardiac cycle. Patients older than 40 years or those with a history of angina require coronary artery screening with either a CT or invasive angiogram.

## Surgical Technique

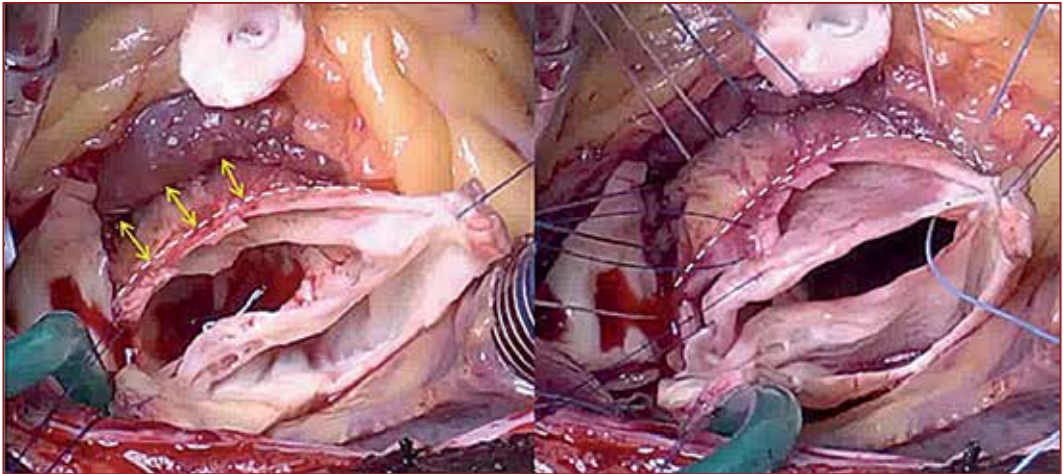
### Valve-sparing root replacement

Out of the two most commonly used techniques for VSRR, the reimplantation technique is our favourite for many reasons. It is easily reproducible and can be applied to nearly all root geometries. It is associated with less bleeding intraoperatively. It can be used to modify root geometry especially in BAVs with an acute commissural orientation, allowing repair in a 180° fashion. It does not require a concomitant annuloplasty as the base of the graft acts as the external annular support. The remodelling technique has shown excellent results in other centres but we would like to stress the fact that it is crucial to couple it with an annuloplasty procedure in patients with a dilated annulus, BAVs, and connective tissue disorders as this has been shown to be the Achilles' heel for long term durability in such cohorts.<sup>9</sup> In this section, we will try to share our tips and tricks for performing a successful and durable reimplantation procedure.

Following aortic cross clamping and administration of cardioplegia, the ascending aorta is near totally transected transversely more distal than usual to avoid a high coronary artery origin as well as the left-right commissural apex. Three suspension sutures are taken 2mm above the apices of the three commissures or the commissures and raphe in BAV. Meticulous root and cusp assessment is undertaken prior to committing to valve preservation taking note of all the aspects discussed earlier. The level of the basal ring along the anterior annulus is identified internally, and a note is made of the corresponding level externally. This will be the most proximal level of external root dissection anteriorly. External root dissection is then carried out along the non-coronary and left coronary sinuses posteriorly to the level of the basal ring. This is easily accomplished with routine dissection. The three sinuses are excised and the coronary buttons fashioned. Traction is then applied to the suspension suture overlying the left/right commissure/raphe towards the surgeon. Careful sharp dissection is then undertaken externally to separate the muscular tissues along the lateral anterior annulus in the plane between the right ventricular outflow tract and septal myocardium in a fashion similar to the plane developed during the Ross procedure. This deep dissection is undertaken along the annulus from the left/right commissure/raphe to just beyond the midpoint of the right coronary sinus. This is carried out as deep proximally as needed to reach the level of the basal ring externally. (Fig 7).



This depth is approximately 1cm deeper than the VAJ externally. In most cases this dissection is possible without breaching the RV cavity. In some cases, however, the RV cavity is breached, either inadvertently or intentionally, to allow exposure of the level of the basal ring externally. (If the RV cavity had been breached, it is later closed over the graft using either a separate Nylon suture line or the same distal suture line used for fixing the valve such that the needle pass incorporates the RV muscle followed by graft followed by sinus remnant from outside in, respectively.) Insufficient dissection along that anterior annulus will result in either a tilted basal attachment of the graft if the nadir of the RCS is not reached or in incorporation of a thick rim of RV muscle within the graft both resulting in root distortion and asymmetry. The deep anterior dissection technique helps avert this problem and achieve three important goals: firstly, it allows the base of the graft to sit at the level of the basal ring circumferentially thus allowing a symmetrical implantation, secondly it helps to relatively thin out the tissues of the root anteriorly with resultant incorporation of fewer muscle bands and accurate graft sizing and match, and finally it supports the interventricular septum and prevents future dilatation along this area and recurrent prolapse of the cusp.



*Figure 7: Technique of deep anterior annular dissection.*

We have simplified the process of graft sizing following in vitro assessment of normal aortic roots<sup>20</sup>. We have shown before that the height of the left-non commissure equals the diameter of the STJ. We thus measure this height from the apex of the commissure to the basal ring (imaginary line cutting the nadirs of the LCC and NCC) and use this as the graft size. (Fig 8) We use a Valsalva graft and trim the lower cuff below the sinus completely.

We then use an interrupted line of ten to twelve 2-0 Teflon pledgetted polyester sutures along the basal ring (going slightly higher at the base of the right-non commissure to avoid the conduction system) for the proximal suture line making sure the sutures are taken horizontally outwards. This is facilitated by the deep root dissection discussed earlier. The height of the right-non commissure is then measured from its apex to the Teflon pledget.

This is usually up to 10mm less than the left-non commissural height. A perpendicular cut is then made in the graft at that area. This allows the graft and its STJ to sit symmetrically and allows fixation of all three commissural apices at the same level (the graft STJ) (Figure 9).

These commissural fixing sutures are not cut and used for outward radial traction to facilitate the running distal suture line. Once this is completed, the root is pressurised with saline and any cusp repair techniques completed.

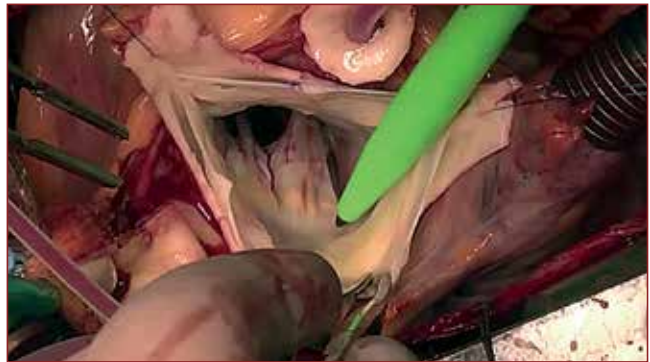
The coronary buttons are reimplanted in a regular fashion over a pericardial strip pledget and then the root is pressurised with cardioplegia to assess for haemostasis. The distal anastomosis to the ascending aorta is then finally completed (Figure 10).

### Leaflet repair techniques in Tricuspid Aortic Valve (TAV)

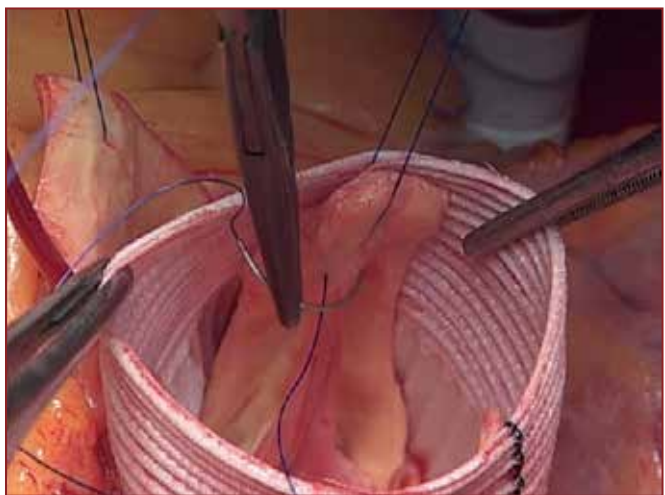
The commonest leaflet pathology requiring correction in TAV is cusp prolapse usually of the right followed by the non-coronary cusp. As explained earlier, this results from an increase in the ratio between free margin length and length of cusp insertion leading to a decrease in the height of the prolapsing cusp. Prolapse correction therefore requires a reduction in free margin length to raise the effective leaflet height.

By applying a vertical and outward tension on the three commissural sutures, the cusps can be stretched, facilitating the comparison between the free margin length of all three cusps. In single cusp prolapse, a 6-0 polypropylene suture is placed in the middle of the 2 non-prolapsing free margins at the nodule of Arantius. By applying gentle traction on this stitch and grasping the middle of the prolapsing free margin, the free margin lengths can be compared, and the excess length determined. In double cusp prolapse, a similar stay suture is placed in the middle of the non-prolapsing free margin, and the excess lengths of the 2 prolapsing free margins are determined similarly.

Prolapse of all 3 cusps is rare, but it can be occasionally induced after a valve-sparing procedure in case of a small graft size. In this situation, the reference used to correct prolapse can be the middle height of the sinuses, or it can be determined by a caliper to measure effective cusp height as previously described by

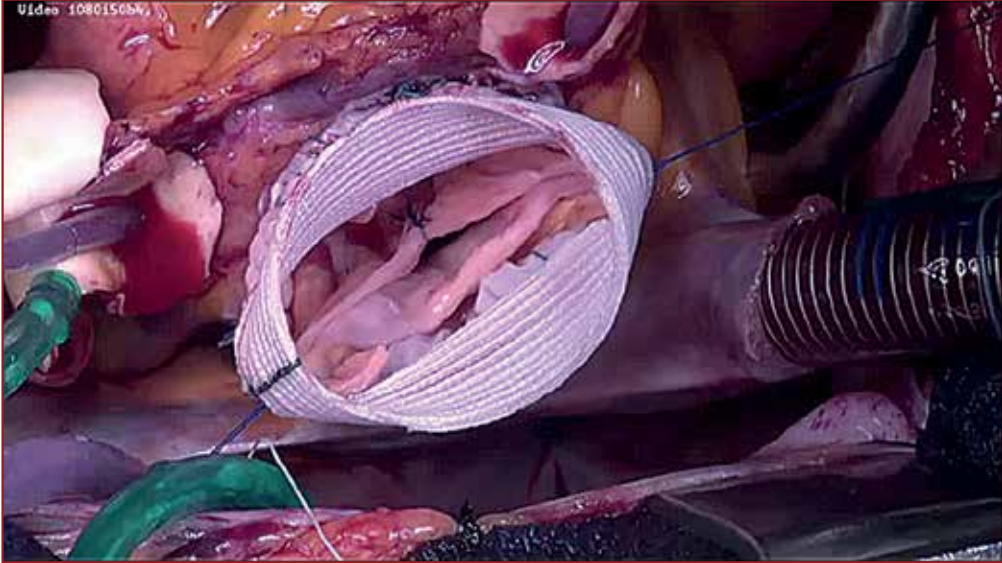


*Figure 8: Exposure of the basal ring beneath the left non commissure to allow graft sizing.*



*Figure 9: Attaching the apex of a commissure to the graft at the STJ.*

Schäfers and colleagues, and subsequently plicating the free margin to achieve a height of > 9mm<sup>10</sup>. The techniques we employ for cusp prolapse correction include free margin plication using 5-0 polypropylene suture, triangular resection in cases of excessive prolapse, and free margin resuspension with a running suture of polytetrafluoroethylene (PTFE). The latter should not be used in BAV.



*Figure 10: Final result after valve-sparing root replacement and leaflet plication in a bicuspid aortic valve.*

### Leaflet repair techniques in Bicuspid Aortic Valve (BAV)

Regurgitant bicuspid AVs frequently present with dilatation of the aortic annulus or root and therefore almost always require an annular reduction. The mechanism of AR in Type 0 BAV is usually prolapse of one or both cusps in addition to annular dilatation. This is repaired with leaflet plication or triangular resection as explained earlier. The mechanism of AR in Type 1 BAVs can either be due to a prolapsing conjoint cusp in cases of a complete raphe, or due to conjoint cusp retraction with a central coaptation gap in case of an incomplete raphe. In Type 1 valves, the median raphe is addressed first. If the raphe is pliable and only mildly thickened, it is preserved and shaved and any prolapse is corrected. If the raphe is restrictive or calcified it is resected. Then a 6-0 polypropylene suture is used to approximate the two cut ends of the free margin of the conjoint cusp to assess adequacy of tissue. If there is sufficient tissue such that there is a good valve opening and the leaflet edge is not splinted across it then the leaflet edges are reapproximated primarily. If this is not the case, then a triangular pericardial patch is used for cusp restoration.

### Annuloplasty

The choice of the optimum annuloplasty procedure is still under debate. There are four broad categories of annuloplasty techniques currently available. The first represents interrupted non-circumferential annular plication sutures or the subcommissural annuloplasty. It is



evident now that this is insufficient in treating a dilated annulus<sup>21</sup>. The second is a suture based circumferential cerclage as proposed by Taylor and modified by Schäfers<sup>22</sup>. Despite showing an improved rate of freedom from AR grade 2 and decreased risk of reoperation for isolated aortic valve repair, it has not decreased the risk of reoperation in root remodelling and has been shown to be a risk factor for repair failure on univariate analysis. Longer follow up is needed to assess its impact on long term repair durability.<sup>9</sup> Thirdly are circumferential internal or external prosthetic rings<sup>23-25</sup>. They all seem to achieve reduction in AR with good short to midterm results. There remains a paucity of studies comparing these different rings in similar cohorts of patients to allow judgment as to which technique is superior. Internal rings when tested in vitro seem to achieve a slightly better reduction in AR as well as an anatomically superior subvalvular implantation<sup>26</sup>. Despite being easier to implant, there are concerns regarding trauma to the leaflets, as was the case in our experience.

External rings are more difficult to implant under the coronary artery origins and can also lead to injury of neighbouring structures. Expansile rings allow annular motion and whether this translates into more durable and physiological valve repair over the long term is still to be verified. Finally, there is the reimplantation technique, which utilises the base of the graft as the supporting annuloplasty. This technique has been shown to provide excellent mid to long-term results<sup>27</sup>. There is concern, however, about the physiological derangement induced by implanting the valve cusps within a rigid graft but this has not been shown to be detrimental clinically<sup>28</sup>. There is also a higher rate of permanent pacemaker implantation resulting from encroachment on the AV bundle in proximity to the membranous septum.

## Results of aortic valve-preserving surgery

Data on the durability of AV repair techniques is limited to moderate sized series from highly experienced centres, with a follow-up of 5 to 10 years. Patients undergoing cusp repair with tricuspid AVs have an 8-year freedom from AV reoperation of 92%, and freedom from recurrent AR greater than 1+ of 71% in our experience<sup>29</sup>. Bicuspid AV repair leads to excellent survival of 94% at 10 years in our series, with a freedom from AV reoperation of 81%. The reimplantation procedure for root and annular stabilisation leads to a more durable outcome than is seen with subcommissural annuloplasty or remodelling without a concomitant annuloplasty<sup>21</sup>. The low risk of long term morbidity is a consistent finding among all centres; thromboembolism (<0.7%/patient year), bleeding (<0.3%/patient year), and endocarditis (<0.2%/patient year).<sup>30</sup>

## Conclusion

Several advances in the field of aortic valve repair have led to wider adoption of this technique for the treatment of patients with aortic regurgitation. A better understanding of the complex anatomy of the aortic root as well as refinement of the surgical techniques has improved the long-term results. Further research into annuloplasty rings and materials to augment restrictive leaflets may help extend repair techniques to more complex cases of valve pathology.

## References

1. Taylor WJ, Thrower WB, Black H, et al. The surgical correction of aortic insufficiency by circumclusion. *J Thorac Cardiovasc Surg* 1958; 35: 192–205.
2. Starzl TC, Cruzat EP, Walker FB, et al. A technique for bicuspidization of the aortic valve. *J Thorac Cardiovasc Surg* 1959; 38: 262–70.
3. Sarsam MAI, Yacoub M. Remodeling of the aortic valve annulus. *J Thorac Cardiovasc Surg* 1993; 105: 435–8.
4. David TE, Feindel CA. An aortic valve-sparing operation for patients with aortic incompetence and aneurysm of the ascending aorta. *J Thorac Cardiovasc Surg* 1992; 103: 617–22.
5. Saczkowski R, Malas T, de Kerchove L, et al. Systematic review of aortic valve preservation and repair. *Ann Cardiothorac Surg*. 2013 Jan;2(1):3-9.
6. Collins JD, Semaan E, Barker A, et al. Comparison of Hemodynamics After Aortic Root Replacement Using Valve-Sparing or Bioprosthetic Valved Conduit. *Ann Thorac Surg*. 2015 Nov;100(5):1556-62.
7. El Khoury G, de Kerchove L. Principles of aortic valve repair. *J Thorac Cardiovasc Surg*, 2013, 145(3 Suppl), S26 - S29.
8. De Kerchove L, Jashari R, Boodhwani M, et al. Surgical anatomy of the aortic root: implication for valve-sparing reimplantation and aortic valve annuloplasty. *J Thorac Cardiovasc Surg*. 2015 Feb;149(2):425-33.
9. Schäfers HJ, Raddatz A, Schmied W, et al. Re-examining remodelling. *J Thorac Cardiovasc Surg*. 2015 Feb;149(2 Suppl):S30-6.
10. Schafers HJ, Bierbach B, Aicher D. A new approach to the assessment of aortic cusp geometry. *J Thorac Cardiovasc Surg*. 2006;132:436-8.
11. Anderson RH, Devine WA, Ho SY, et al. The myth of the aortic annulus: the anatomy of the subaortic outflow tract. *Ann Thorac Surg*. 1991 Sep;52(3):640-6.
12. De Kerchove L, El Khoury G. Anatomy and pathophysiology of the ventriculo-aortic junction: implication in aortic valve repair surgery. *Ann Cardiothorac Surg*. 2013 Jan; 2(1): 57–64.
13. Sievers HH, Schmidtke C. A classification system for the bicuspid aortic valve from 304 surgical specimens. *J Thorac Cardiovasc Surg* 2007;133:1226–33.
14. Boodhwani M, de Kerchove L, Glineur D, et al. Repair of regurgitant bicuspid aortic valves: A systematic approach. *J Thorac Cardiovasc Surg* 2010;140:276-284.
15. Aicher D, Kunihara T, Abou Issa O, et al. Valve configuration determines long-term results after repair of the bicuspid aortic valve. *Circulation*. 2011; 123: 178– 85.
16. Mookhoek A, de Kerchove L, El Khoury G, et al. European multicenter experience with valve-sparing reoperations after the Ross procedure. *J Thorac Cardiovasc Surg*. 2015 Nov; 150(5): 1132-7.
17. Boodhwani M, de Kerchove L, Glineur D, et al. Repair-oriented classification of aortic insufficiency: impact on surgical techniques and clinical outcomes. *J Thorac Cardiovasc Surg* 2009; 137(2); 286-94.
18. Schäfers HJ, Schmied W, Marom G, et al. Cusp height in aortic valves. *J Thorac Cardiovasc Surg* 2013; 146 (2): 269-274.
19. Kunihara T, Aicher D, Rodionychewa S, et al. Preoperative aortic root geometry and postoperative cusp configuration primarily determine long-term outcome after valve-preserving aortic root repair. *J Thorac Cardiovasc Surg*, 143 (2012), 1389–1395.

20. De Kerchove L, Boodhwani M, Glineur D, et al. A new simple and objective method for graft sizing in valve-sparing root replacement using the reimplantation technique. *Ann Thorac Surg.* 2011; 92(2): 749-51.
21. Navarra E, El Khoury G, Glineur D, et al. Effect of annulus dimension and annuloplasty on bicuspid aortic valve repair. *Eur J Cardiothorac Surg.* 2013;44(2):316-22.
22. Schneider U, Aicher D, Miura Y, et al. Suture annuloplasty in aortic valve repair. *Ann Thorac Surg.* 2016 Feb;101(2):783-5.
23. Izumoto H, Kawazoe K, Kawase T, et al. Subvalvular circular annuloplasty as a component of aortic valve repair. *J Heart Valve Dis* 2002;11:383-5.
24. Lansac E, Di Centa I, Varnous S, et al. External aortic annuloplasty ring for valve-sparing procedures. *Ann Thorac Surg* 2005;79:356-8.
25. Rankin JS, Conger JL, Tuzun E, et al. In vivo testing of an intra-annular aortic valve annuloplasty ring in a chronic calf model. *Eur J Cardiothorac Surg* 2012;42:149-54.
26. De Kerchove L, Vismara R, Mangini A, et al. In vitro comparison of three techniques for ventriculo-aortic junction annuloplasty. *Eur J Cardiothorac Surg* 2012;41:1117-23; discussion 1123-4.
27. De Kerchove L, Boodhwani M, Glineur D, et al. Valve sparing-root replacement with the reimplantation technique to increase the durability of bicuspid aortic valve repair. *J Thorac Cardiovasc Surg.* 2011; 142:1430-8.
28. Erasmi A, Sievers HH, Scharfschwerdt M, et al. In vitro hydrodynamics, cusp-bending deformation, and root distensibility for different types of aortic valve-sparing operations: remodeling, sinus prosthesis, and reimplantation. *J Thorac Cardiovasc Surg* 2005;130:1044-9.
29. De Kerchove L, Mastrobuoni S, Boodhwani M, et al. The role of annular dimension and annuloplasty in tricuspid aortic valve repair. *Eur J Cardiothorac Surg.* 2016 Feb;49(2):428-37.
30. Aicher D, Fries R, Rodionychewa S, et al. Aortic valve repair leads to a low incidence of valve-related complications. *Eur J Cardiothorac Surg.* 2010;37:127-32.



## Chapter 3

# Thoracoabdominal Aortic Aneurysm Repair – Tips from Belgium

*Marianna Buonocore and Marc Schepens*

---

*“Dignus vindice nodus”*



## Introduction

Aneurysm is the second most frequent pathology affecting the aorta after atherosclerosis and is the most common reason for aortic surgery. An aneurysm is a dilation of an artery of at least 50% of its normal diameter at a given location, minding that the definition of “normal” aortic diameter is determined by several factors including age, sex, body size, anatomical level and method of measurement. An aortic aneurysm that extends from the diaphragmatic hiatus both proximally and distally is defined as a thoracoabdominal aortic aneurysm (TAAA) <sup>1</sup>.

The most common aetiology of aortic aneurysm is a degenerative process of the medial layer, with disruption and loss of elastic fibres, loss of smooth muscle cells and formation of proteoglycan deposits with which an atherosclerotic process may be associated. The persistence of a patent false lumen in a chronically dissected aorta may also cause aneurysm development due to a weakened outer wall. Altered histology of the aortic wall because of a genetic disorder may lead to similar consequences, with aortic wall weakness and progressive aortic enlargement, with or without dissection. Other possible causes of aneurysm development include: arteritis involving the aorta on an inflammatory or infective basis, flow-related mechanical forces as in post-coarctation aneurysms, or post-traumatic pseudo-aneurysms.

## Indications and patient selection

The outcome of open TAAA repair is strongly related to the initial clinical presentation and the occurrence of symptoms. Symptomatic aortic aneurysms are rare, except for the often-reported vague back pain that is difficult to relate solely to the aneurysm. For this reason, thoracic aortic aneurysms are often referred to as “silent killers”, having as a first manifestation either death or a very critical clinical scenario such as aortic rupture or dissection.

When frank symptoms occur, there is always an indication for urgent intervention. Symptoms are usually the result of an impending or an actual rupture of the aneurysm and its haemodynamic consequences: severe pain accompanied by signs of hypovolaemic shock, haemoptysis or haematemesis as signs of fistulation into the respiratory or gastrointestinal tract respectively. Emergent surgery in the presence of such symptoms carries an 80% risk of death, with very few patients surviving and with major complications affecting both quality and length of life <sup>2</sup>. Other symptoms in the absence of rupture can be attributed to the compression of surrounding organs or structures such as the trachea, left main bronchus and lung (dyspnoea and stridor), oesophagus (dysphagia), left laryngeal recurrent nerve (hoarseness) or heart (decompensation). In the absence of other relevant comorbidities, patients with compression symptoms have considerably better results with a 10-20% risk of death <sup>2</sup>.

In asymptomatic patients, the indication for elective open TAAA repair is mainly based upon the measured maximum aortic diameter. Following the 2010 Guidelines on the Diagnosis and Management of Thoracic Aortic Disease, open repair is recommended in patients with chronic aortic dissection, especially in the presence of a connective tissue disorder and without significant comorbidity, when the aortic diameter exceeds 5.5 cm (class I, level B) <sup>2</sup>. In other cases, when thoracic endovascular aortic repair (TEVAR) is not possible despite an elevated surgical morbidity, open repair is recommended when the aortic diameter exceeds 6.0 cm, or lower for connective tissue disorders (class I, level C) <sup>2</sup>. In the 2014 ESC Guidelines, there is no distinction between degenerative and post-dissection aneurysms, with an indication for open surgery in patients with a descending thoracic aortic aneurysm

with maximal diameter exceeding 6.0 cm, when TEVAR is not feasible (class IIa, level C). In patients with indication for treatment and in the presence of Marfan syndrome or other elastopathies, surgery is indicated rather than TEVAR, except in emergency situations as a bridge to a definitive open surgical therapy (class IIa, level C)<sup>3</sup>. In patients undergoing elective open surgical TAAA repair the risk of death varies between 3% and 10% depending on the extent of the aneurysm.

Despite the rarity of symptoms, attention must be paid to the history of the patient because there are clinical conditions considered at high risk for a concomitant thoracic aortic aneurysm. Recently in the literature some clinical “associates” have been reported, such as intracranial aneurysm, aortic arch anomalies, bicuspid aortic valve, simple renal cysts, temporal arteritis, positive family history of aneurysm disease, and a positive thumb-palm sign<sup>4</sup>. The presence of any of these conditions should arouse suspicion of concomitant aortic aneurysm and requires an imaging study of the entire aorta.

## Pre-operative work-up

The success of TAAA surgery mandates excellent teamwork and attention to detail. Optimal communication between the anaesthetist, surgeon and perfusionist is crucial to delineate an overall strategy for perioperative care. Before the planning of an elective operation, patients with TAAA should be screened at the level of all major organ systems including cardiac, renal and respiratory, that are potentially at risk during surgery. Concomitant atherosclerotic lesions can be present both centrally and distally in the vascular system and the reported incidence of coronary artery disease in patients with TAAA is not negligible (27% to 36%)<sup>5,6</sup>. It is therefore essential to perform a baseline ECG and a transthoracic echocardiogram, avoiding transoesophageal echocardiogram to prevent stress-related hypertension. For the same reason cyclo-ergometry tests should not be performed, preferring pharmacologic stress tests in case of suspected myocardial ischaemia. Coronary angiography is only performed in patients with symptoms and positive stress test for cardiac ischaemia, or in those with previous myocardial infarction, coronary artery bypass surgery or coronary stents. Duplex scanning of the cerebral vessels should be also performed to assess the risk of post-operative stroke related to atherosclerosis of these vessels.

Since both abdomen and thorax are opened during the repair with circumferential division of the diaphragm and transection of the costal margin, patients are particularly prone to developing postoperative respiratory failure. Smoking and chronic obstructive pulmonary disease are frequently encountered in this population and are linked to the growth and rupture of the aneurysm<sup>7</sup>. Chest X-ray is of little value in assessing lung function, but it is important to have a pre-operative baseline chest x-ray to compare with post-operative films. Computed tomography scanning can add further information about tracheal or left main bronchial compression or deviation due to the aortic aneurysm. Single lung ventilation with exclusion of the left lung is necessary in the case of left heart bypass, thus it is mandatory to perform a careful evaluation of the respiratory system with lung function tests and blood gas analysis at rest before a surgical plan is made. Pulmonary reserve may be optimised by cessation of smoking, the use of bronchodilators and a comprehensive exercise programme. A preoperative assessment of vocal cord mobility is advisable due to the risk of left recurrent laryngeal nerve stretching as a result of aneurysm enlargement, and the risk of damage during surgery at the level of the aortic isthmus with dissection manoeuvres, clamping, suturing or the simple use of electrocautery to neighbouring structures<sup>8</sup>.

The kidneys are the most sensitive visceral organs to ischaemia during the abdominal aortic clamping stage. Moreover, renal arteries are frequently involved in the aneurysmal extent or have intrinsic disease due to atherosclerosis or dissection. Pre-operative measurement of serum creatinine and glomerular filtration rate is necessary as post-operative renal impairment is possible. In elective surgery, the use of angiographic contrast shortly before surgery should be avoided and in case of pre-operative acute renal injury the operation should be deferred until laboratory values are normalised.

Patients with a history of stroke should undergo thorough neurologic evaluation, possibly including a CT scan of the brain. The presence of infectious foci should be excluded and coagulation parameters should be checked in order to safely insert a spinal catheter, and to correct pre-operative conditions that put the patient at higher risk of red blood cell transfusion.

Paraplegia remains one of the most devastating complications of TAAA surgery and modern open repair strategies include many modalities aimed at reducing the risk of spinal cord ischaemia related to both the surgical management and the disease itself (extensive aneurysms, aortic dissection or rupture, severe atherosclerotic disease, previous aortic surgery, hypotension, prolonged aortic cross-clamp time, sacrifice of intercostal arteries). It is fundamental in elective cases to place a spinal catheter to drain cerebrospinal fluid (CSF) to keep a CSF pressure (CSFP) below 10 mmHg, thus increasing the spinal cord perfusion pressure (SCPP) according to the following formula:  $SCPP = MAPd - (CSFP \text{ or } CVP \text{ [whichever is greater]})$  where MAPd is the distal mean aortic pressure and CVP is the central venous pressure.

The anaesthetist inserts the spinal catheter the day before the surgery and it is kept in place 48 hours post-operatively. When needed, CSF is drained at 10ml/h up to a maximum of 20ml/h if signs of paraparesis become evident. Draining too large a volume of CSF over a short period is a documented risk factor for subdural intracranial hemorrhage. The spinal catheter is also used during surgery for administration of intrathecal papaverine (40 mg/2ml in 2 ml of Glucose 5%) 10 minutes before aortic cross-clamping to increase spinal cord perfusion and provide additional spinal cord protection, as assessed in the study from the Cleveland group<sup>9</sup>.

## **Surgical technique: tips and tricks**

To achieve optimal results and avoid undesired complications, it is essential to check that all the required monitoring tools and protection systems are correctly placed before the start of surgery:

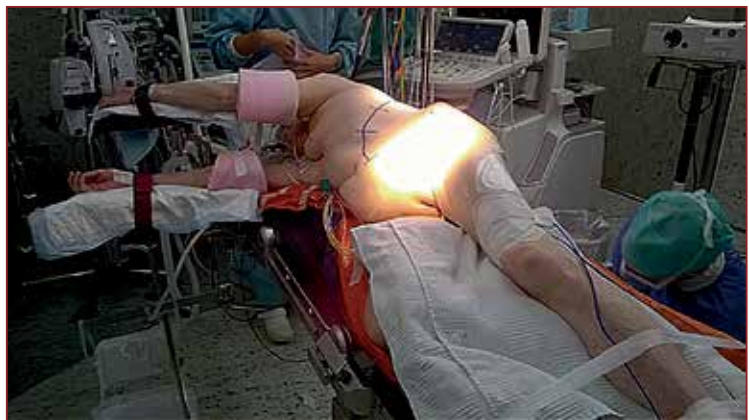- Nasogastric tube,
- Oesophageal temperature probe,
- Endobronchial blockers under fiberoptic surveillance,
- Transoesophageal echo probe,
- Arterial pressure line in the right radial artery,
- Arterial pressure line in the right arteria dorsalis pedis or the right femoral artery,
- Trauma catheter in the left jugular vein,
- Rapid volume infuser,
- Pulmonary artery catheter,
- Urinary catheter,

- Rectal temperature probe,
- Cerebral and eventually spinal oximetry,
- Drainage system connected to the CSF drain,
- Two return electrodes for electrocautery,
- Cotton wool wrapping of all the bony extensions (such as heels) to prevent pressure wounds.

The patient is positioned in partial right lateral decubitus with the aid of a vacuum mattress and both arms positioned on arm supports on the right side of the table, avoiding overextension and possible peripheral nerve injuries (Figure 1).

The TAAA is approached through a left thoracophrenolaparotomy with an incision at the level of the fifth intercostal space. We incise the diaphragm circumferentially at the costal insertion to avoid transection of phrenic branches, taking care to leave about 1.5cm of muscle on the ribs to help the reconstruction at the end of the procedure. During the diaphragmatic incision, we bluntly dissect the peritoneum preserving its integrity in order to reach the aorta posteriorly in the retroperitoneal space. Keeping the peritoneum closed allows a clearer surgical field avoiding the “invasion” of the abdominal organs, and limits the risk of bacterial contamination. If small holes occur in the peritoneum, we close them immediately with a polypropylene suture.

Our surgical strategy for TAAA open repair consists of a staged cross-clamp repair, proceeding in a cranio-caudal direction from the proximal anastomosis and gradually moving the cross clamps distally allowing for reimplantation of arterial side branches. The most frequent problems associated with aortic cross-clamping are an abrupt increase in afterload with resulting increase in proximal aortic pressure and at the same time ischaemia of the organs distal to the aortic cross-clamp. To overcome this, it is necessary to support the circulation during the clamping stages. This can be achieved either with the use of extracorporeal circulation (partial or total), requiring full heparinisation, or with left heart bypass (LHB). We prefer the use of LHB for every case except if right lung ventilation is not tolerated because of inadequate pulmonary reserve (we will then use partial cardiopulmonary bypass) or if clamping of the aneurysm is impossible because of the size of the aneurysm (total cardiopulmonary bypass with deep hypothermic circulatory arrest is utilised in these circumstances). Left heart bypass diverts oxygenated blood from the left side of the circulation through a centrifugal pump into the distal circulation below the distal aortic clamp, thus providing at the same time control of both the proximal (afterload of the heart) and distal aortic pressure with adequate renal, splanchnic and spinal cord perfusion (Figure 2).



*Figure 1: Position of the patient on the table*

The location of cannulation sites depends upon the specific anatomical details of the aneurysm but in general our preferred cannulation sites are the left pulmonary vein for the outflow and the left common femoral artery for the inflow. The left femoral artery is cannulated first through the interposition of a 10mm Dacron tube graft to avoid prolonged left leg ischaemia (Figure 3). Cannulation of the left pulmonary vein then follows which has the advantage of being extra-pericardial compared to direct left atrial cannulation, and less arrhythmogenic than the left atrial appendage. In our circuit, we do not include an oxygenator which has the advantage of avoiding systemic heparinisation.



*Figure 2: Left heart bypass circuit*

We only use 5000 IU Heparin in 3000 mL priming fluid in a heparin coated circuit of approximately 700 ml, thus limiting the heparinisation impact on bleeding risk. LHB demands an activated clotting time (ACT) around 200 s and to achieve this a liberal infusion of fresh frozen plasma is often required. ACT measurement should be repeated every 30 min or even more frequently in the case of massive blood loss. Usually a flow of 1.5 to 2.5 L/min is sufficient to control proximal and distal

aortic pressure, with the goal of keeping the systolic proximal pressure  $\geq 100$  mmHg and a distal MAP  $\geq 80$  mmHg to provide adequate spinal cord, renal and splanchnic perfusion. A continuous interaction between the anaesthesia and perfusion team is imperative to adjust proximal and distal perfusion pressures at all times.

Before placing the clamps, it is necessary to encircle the aneurysm with vessel loops at determined points to control the aorta during surgical manoeuvres: for example, at the proximal clamping site, at diaphragmatic level and at the infrarenal distal clamping site (Figure 4).

The impact of this operation and the anatomical extension mean the risk of harming the patient is high. The only possible solution is therefore to perform “meticulous surgery”, which means respecting the anatomical integrity of the tissues and organs encountered during aortic repair and avoiding unnecessary blood loss from the beginning of the skin incision to the very end of the procedure, chasing every red blood cell. Preferably blood is suctioned with a cell saver, through which it is washed and returned to the patient. Two cell-saver devices and a rapid infusion device are provided to deal with rapid and massive blood loss. Transfusion of homologous blood products is known to be associated with a higher incidence of post-operative respiratory dysfunction. In contrast, use of cell-saving device blood had no adverse impact on pulmonary function<sup>10</sup>.

As soon as the left lung is excluded from ventilation, it collapses and shrinks. It is normally not necessary to push or pull on it to reach the aorta. Such manoeuvres must be avoided because they can cause contusions leading to intra-pulmonary haemorrhage and post-operative respiratory complications.

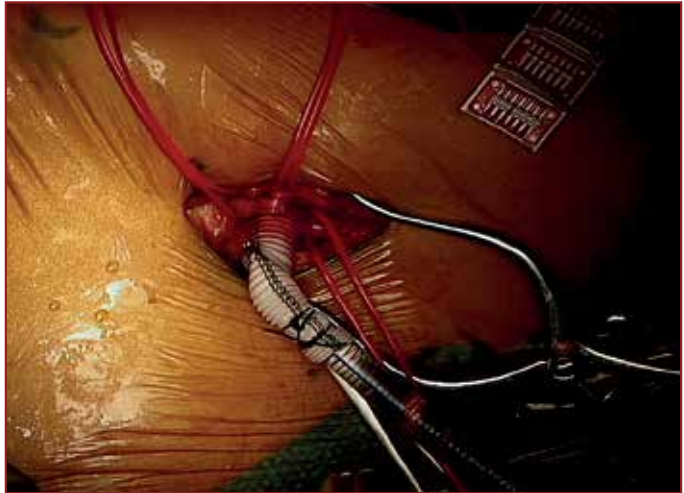


Care must be taken when dissecting peri-aortic tissues, especially in post-dissection aneurysms where very often peri-aortic inflammation develops making it more difficult to encircle the aorta. It is preferable to work very close to the aortic wall, of course avoiding aortic perforation, but also keeping the correct dissection plane and avoiding damage to surrounding structures like the oesophagus. For the same reason, it is necessary to transect the aorta completely at the level of the isthmus, thus providing a clear view of the posterior aortic wall and to avoid suturing the oesophagus during the execution of the proximal anastomosis.

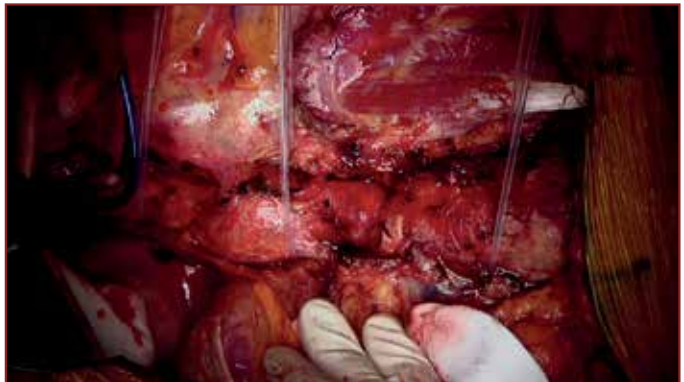
Another important structure that it is crossed at the isthmus is the left recurrent laryngeal nerve. In recent literature, the incidence of post-operative hoarseness in TAAA open repair is reported to be 15%<sup>11</sup>. To avoid this complication, it is necessary to look for the vagus nerve that usually crosses the anterior wall of the aortic arch between the emergence of the left carotid artery and the left subclavian artery, follow it and find the origin of the left recurrent laryngeal nerve just beyond the ligamentum arteriosum, even leaving in place a strip of aortic wall if the aneurysm at this point is too big and the nerve is too closely adherent to be safely dissected from it. Care must be taken in using electrocautery near this nerve.

It is also necessary to identify the left phrenic nerve which runs laterally on the pericardial sac to the diaphragm. Injury to this nerve leads to ipsilateral hemidiaphragm paralysis which may cause severe post-operative respiratory complications in patients whose ventilatory capacity has already been compromised by pain from the thoracotomy, incision of the left hemi-diaphragm and left lung exclusion.

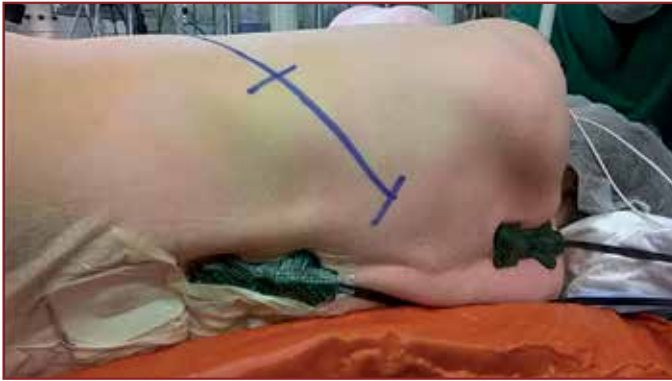Once the aneurysm is opened, the wall is not resected but left in place and used to wrap the vascular prosthesis. The intercostal and lumbar arteries that are considered too small to



*Figure 3: Left femoral artery cannulation with Dacron graft interposition for left heart bypass institution*

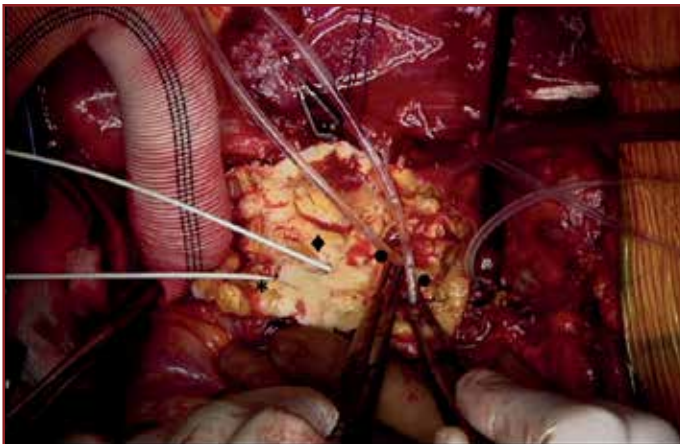


*Figure 4: Aortic aneurysm encircled at the mid-thoracic, the diaphragmatic and the infra-renal levels*



*Figure 5: Near-infrared spectroscopic monitoring of the spinal cord*

the entire operation through the internal iliac arteries with LHB. We do not use evoked potentials to monitor the spinal cord because the installation of the recording system and the need for a dedicated neurophysiologist constantly during surgery make this procedure cumbersome. We recently introduced into our practice near-infrared spectroscopy of the spinal cord, which has the advantage of a more visual and direct interpretation of data and the possibility of prolonging monitoring when the patient is transferred to the ICU (Figure 5).



*Figure 6: Aortic aneurysm opened at the abdominal segment: the coeliac trunk (\*) and the superior mesenteric artery (♦) are occluded with balloon catheters to avoid back-bleeding. The renal arteries (•) are perfused with cold crystalloid solution.*

blood perfusion of the bowel and splanchnic organs during this phase because it is cumbersome to set up a separate arterial perfusion line and have perfusion catheters in the surgical field whilst working on the anastomosis. Only kidneys are highly susceptible to ischaemia and for this reason as soon as the clamps are placed and the abdominal aorta is opened, we perfuse both kidneys with 300 ml of cold crystalloid solution (500 mL Ringer's Acetate with 20 mL Mannitol 20 % at a temperature of 4° C) at a flow of 100 mL/kidney/min (Figure 6).

be reimplanted are visualised and oversewn to avoid back-bleeding. We believe in the reimplantation of segmental arteries of meaningful size between T6 and L2. When necessary for example in atherosclerotic aneurysms, we perform endarterectomy first to have better aortic tissue for suturing, usually performed including a small patch of the aortic wall. We also believe in the importance of continuous spinal cord perfusion during

In the same fashion, we perform reimplantation of the visceral arteries on an island of aortic wall tissue, usually sewing separately only the left renal artery for geometrical reasons and to avoid having too big an aortic patch that may progressively enlarge. This is particularly true in patients with connective tissue disorders like Marfan syndrome, in whom a direct suture of the arterial ostium onto the prosthesis or through a side-branched aortic graft is advisable<sup>12</sup>.

During the clamping stage of the abdominal aorta, the visceral arteries are no longer perfused. We do not perform

If the visceral anastomoses are not completed and the blood flow restarted within 20 minutes, it is necessary to administer a second dose of 200ml/kidney. Once the renal arteries are reimplemented and reperfused, 40 mg of indigocarmin is administered intravenously. Indigocarmin will be excreted by the kidneys and it will colour the urine blue. The goal is to evaluate renal perfusion and function after reperfusion. We measure the time from injection to the appearance of blue in the urine (the reappearance time). A reappearance time longer than 30 minutes is considered a risk factor for post-operative haemodialysis<sup>13</sup>.

Another protective measure for visceral and spinal cord ischaemia is mild hypothermia. We let the body temperature passively drop during surgery to 32°C. If the rectal temperature becomes lower, the patient is actively rewarmed by the heat exchanger on the left heart bypass circuit. At the end of the procedure the patient can be warmed up to 33°C before discontinuation of LHB, and then further active external rewarming is started on the ICU, as a slow rewarming process is considered beneficial for spinal cord protection.

### Contemporary results of thoracoabdominal aortic repair

At the cardiac surgery unit of Sint Jan Hospital in Brugge, 61 open surgical repairs for thoraco-abdominal aneurysm have been performed between April 2009 and July 2016. Eighty percent of our patients were male, mean age 55 years. The prevalence of comorbidities is comparable to other series (Table 1).

*Table 1: Preoperative characteristics*

Gender (Male)	80%
Age (Yrs)	55.3 ± 14.7 (min 18; max 78)
BSA (m <sup>2</sup> )	2 ± 0.3
BMI (Kg/m <sup>2</sup> )	26.4 ± 4.8
Obesity (BMI > 30)	15%
Hypertension	64%
Diabetes	7%
CAD	16%
Previous CABG	7%
COPD	26%
Renal Insufficiency (GFR < 60ml/h)	16%
CVA	4%
Spinal Injury	2%
Crawford extent	
Type I	11.5%
Type II	62%
Type III	13%
Type IV	11.5%
Type V	2%

*BMI=body mass index; BSA=body surface area; CABG=coronary artery bypass grafting; CAD=coronary artery disease; COPD=chronic obstructive pulmonary disease; CVA= cerebrovascular accident; GFR= glomerular filtration rate.*



Of note, the low prevalence of diabetes (only 7%) compared to the general population confirms the intriguing observation from other studies of a negative association of diabetes with TAAA<sup>14</sup>. The majority of TAAA were post-dissection aneurysms (69%), followed by degenerative atherosclerotic aneurysms (28%). In one third of our patients there was a diagnosed genetic defect, mostly Marfan (21%) or Loeys-Dietz syndrome (3%). The anatomical extent was a Crawford type II in 62% of patients. Aortic arch surgery had already been performed in 29% of cases, open abdominal aneurysm surgery in 8%, open thoracic aneurysm surgery in 8% and 13% of patients were treated after TEVAR, mostly for endoleak and continuous expansion of the aneurysm sac or further dilatation of the aorta in the adjacent segments. We applied our surgical protocol with LHB support, CSF drainage and cold crystalloid perfusion of the kidneys in 93% of patients. In 7% a more extended proximal approach into the aortic arch was necessary requiring the use of cardiopulmonary bypass with full heparinisation and deep hypothermic circulatory arrest. The 30-day mortality was 7%, with an intra-operative mortality of 2%, and a need of surgical revision in 7% of patients (one for prosthetic infection, 2%). The median ICU length of stay was 7 days, with a median length of mechanical ventilation support of 19 hours. In 38% of patients a further non-invasive method of ventilation was needed, ARDS was diagnosed in 11% and in 5% a tracheostomy was performed.

Post-operative acute kidney injury was defined following the RIFLE criteria system, that stratifies renal failure into three grades of increasing severity based on changes in either plasma creatinine or urine output from baseline (Risk, Injury, Failure) and two outcome classes (loss of kidney function, end-stage kidney disease)<sup>15</sup>. According to the RIFLE definitions, seven patients experienced acute kidney injury (RIFLE class I, 11.5%), while two patients required temporary continuous veno-venous haemofiltration (CVVH) (RIFLE class F, 3%) but none needed dialysis. Spinal cord injury occurred in 8%, but one patient (2%) fully recovered from paraparesis. The incidence of stroke was 2% and left laryngeal nerve palsy was 8%.

## Summary

Open staged repair of thoracoabdominal aortic aneurysms is a major cardiovascular intervention affecting multiple organ systems and may be complicated by serious intra- and postoperative problems. A meaningful collaboration between each member of the team during the selection, evaluation and preparation of the patient, together with meticulous surgery and an attentive post-operative care, make it possible to achieve excellent results in terms of both mortality and morbidity. Organ protection through the use of left heart bypass, low heparinisation, mild hypothermia, cold perfusion of the kidneys, and cerebrospinal fluid drainage are the cornerstones of our surgical approach.

## References

1. Johnston KW, Rutherford RB, Tilson MD, et al. Suggested standards for reporting on arterial aneurysms. Subcommittee on Reporting Standards for Arterial Aneurysms, Ad Hoc Committee on Reporting Standards, Society for Vascular Surgery and North American Chapter, International Society for Cardiovascular Surgery. *J Vasc Surg.* 1991 Mar;13(3):452-8.
2. Hiratzka LF, Bakris GL, Beckman JA, et al. 2010 ACCF/AHA/AATS/ACR/ASA/SCA/SCAI/SIR/STS/SVM guidelines for the diagnosis and management of patients with thoracic aortic disease: executive summary. A report of the American College of Cardiology Foundation/American Heart Association Task Force on Practice Guidelines, American Association for Thoracic Surgery, American College of Radiology, American Stroke Association, Society of Cardiovascular Anesthesiologists, Society

for Cardiovascular Angiography and Interventions, Society of Interventional Radiology, Society of Thoracic Surgeons, and Society for Vascular Medicine. *Catheter Cardiovasc Interv*. 2010 Aug 1;76(2):E43-86.

3. Erbel R, Aboyans V, Boileau C, et al. 2014 ESC Guidelines on the diagnosis and treatment of aortic diseases: Document covering acute and chronic aortic diseases of the thoracic and abdominal aorta of the adult. The Task Force for the Diagnosis and Treatment of Aortic Diseases of the European Society of Cardiology (ESC). *Eur Heart J*. 2014; 35(41):2873–926.
4. Ziganshin BA, Elefteriades JA. Guilt by association: a paradigm for detection of silent aortic disease. *Ann Cardiothorac Surg*. 2016 May;5(3):174-87.
5. Coselli JS, Bozinovski J, LeMaire SA. Open surgical repair of 2286 thoracoabdominal aortic aneurysms. *Ann Thorac Surg* 2007;83:S862-4; discussion S890-2.
6. Safi HJ, Estrera AL, Azizzadeh A, et al. Progress and future challenges in thoracoabdominal aortic aneurysm management. *World J Surg* 2008;32:355-60.
7. Coady MA, Rizzo JA, Goldstein LJ, et al. Natural history, pathogenesis, and etiology of thoracic aortic aneurysms and dissections. *Cardiol Clin* 1999;17:615-35; vii.
8. Ishii K, Adachi H, Tsubaki K, et al. Evaluation of recurrent nerve paralysis due to thoracic aortic aneurysm and aneurysm repair. *Laryngoscope* 2004;114:2176-81.
9. Lima B, Nowicki ER, Blackstone EH, et al. Spinal cord protective strategies during descending and thoracoabdominal aortic aneurysm repair in the modern era: the role of intrathecal papaverine. *J Thorac Cardiovasc Surg*. 2012 Apr;143(4):945-952.
10. Etz CD, Di Luozzo G, Bello R, et al. Pulmonary complications after descending thoracic and thoracoabdominal aortic aneurysm repair: predictors, prevention, and treatment. *Ann Thorac Surg*. 2007 Feb;83(2):S870-6.
11. Coselli JS, LeMaire SA, Preventza O, et al. Outcomes of 3309 thoracoabdominal aortic aneurysm repairs. *J Thorac Cardiovasc Surg*. 2016 May;151(5):1323-37.
12. De Rango P, Estrera AL, Miller C 3rd, et al. Operative outcomes using a side-branched thoracoabdominal aortic graft (STAG) for thoraco-abdominal aortic repair. *Eur J Vasc Endovasc Surg*. 2011 Jan;41(1):41-7.
13. Schepens M, Dossche K, Morshuis W, et al. Introduction of adjuncts and their influence on changing results in 402 consecutive thoracoabdominal aortic aneurysm repairs. *Eur J Cardiothorac Surg*. 2004 May;25(5):701-7.
14. Jiménez-Trujillo I, González-Pascual M, Jiménez-García R, et al. Type 2 Diabetes Mellitus and Thoracic Aortic Aneurysm and Dissection: An Observational Population-Based Study in Spain From 2001 to 2012. *Medicine (Baltimore)*. 2016 May;95(18):e3618.
15. Bellomo R, Ronco C, Kellum JA, et al. Acute Dialysis Quality Initiative workgroup. Acute renal failure—definition, outcome measures, animal models, fluid therapy and information technology needs: the Second International Consensus Conference of the Acute Dialysis Quality Initiative (ADQI) Group. *Crit Care*. 2004;8:R204-12.



## Chapter 4

# Management of the Infected Aortic Root

*Mustafa Zakkar and Alan J Bryan*

---

*“Hoc opus, hic labor est”*

## Introduction

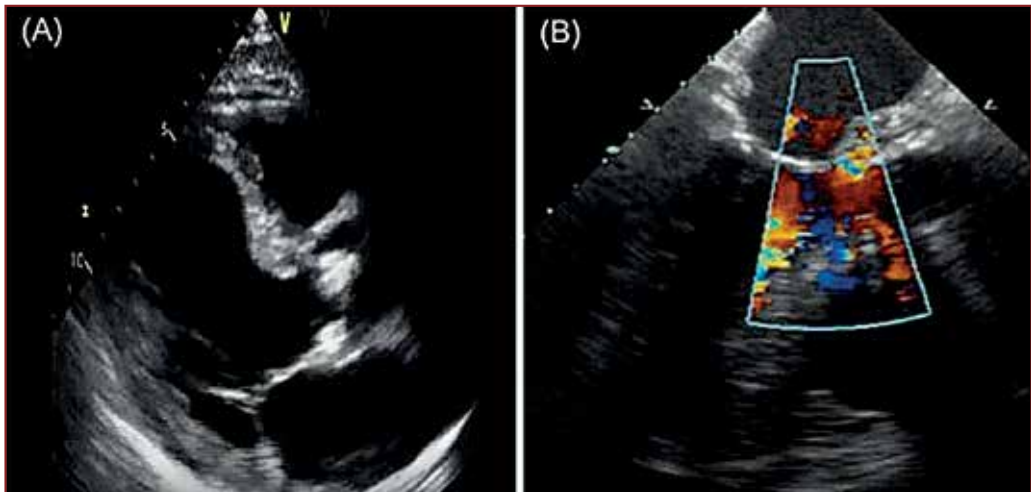
The management of the infected aortic root is not a surgical problem where there is usually a queue of enthusiastic cardiac surgical colleagues vying with each other for the opportunity to treat such patients. There are essentially three elements of this problem involving treatment of patients with:

- 1) Native aortic valve (AV) and aortic root infective endocarditis.
- 2) Infected aortic valve prostheses – early and late prosthetic valve endocarditis.
- 3) Aortic root infection following aortic root reconstructions.

These are all demanding groups of patients for the practicing adult cardiac surgeon with increasing levels of complexity and inherent surgical risk. It is beneficial to note that despite a set of challenging surgical problems that have largely remained the same for 40 years, there remain significant areas of controversy in relation to optimal surgical approaches. This largely relates to the relative rarity of these problems even within large surgical programmes and the associated small size of published series. There is marked heterogeneity of the clinical cases and there must be an understanding that the importance of individual surgeon's technical skill in applying the broad range of techniques that may be employed to treat this range of problems may be difficult to analyse in a systematic fashion.

## Background

It is accepted that prompt and appropriate antibiotic therapy is the mainstay of treatment for patients with infective endocarditis (IE); however, those patients with extensive evidence of aortic root infection will require surgical intervention<sup>1,2</sup>. A range of factors can determine the timing of intervention, including the virulence and destructive nature of the organism, the presence of vegetations and the potential for embolism, and the extension of infection into the periannular tissues resulting in the formation of paravalvular abscesses,



**Figure 1:** (A) Long axis TTE view showing aortic valve vegetation and thickening in the aorto-mitral continuity. (B) Short axis TTE view with colour Doppler demonstrating flow into root abscess cavity.

fistulae and false aneurysms<sup>1,2</sup>. By and large, those infections caused by *Staphylococcus aureus* are the most destructive and are the most likely to need urgent surgical intervention because of abscess formation. Periannular complications occur in up to 40% of patients with aortic IE and may be the result of a delay in diagnosis resulting in localised extension of infection<sup>3</sup>; this can be due to the limited sensitivity of transthoracic echocardiography (TTE) in detecting abscesses (< 50%) and the fact that many cases of periannular extension are frequently discovered when performing TOE (Figure 1)<sup>1,4</sup>.

Conventional surgical thinking often dictates that in a clinically stable patient, a period of antibiotic therapy can be useful to eliminate the systemic elements of sepsis and serve to sterilise and control the local infection and in so doing potentially reduce the potential for reinfection at the time of surgery. Nevertheless, it is possible this logic is flawed and this longstanding approach is contradicted by contemporary series of surgically treated patients where better outcomes are associated with earlier treatment on the basis of reduced risk of embolisation<sup>5</sup>. The challenges posed by these patients, the complexity of their treatment (echocardiographic monitoring and microbiological therapy) and a changing clinical picture, has provided impetus for the development of a multidisciplinary 'endocarditis team' approach to the management of these patients; contemporary guidelines uniformly endorse this approach<sup>1,2,6,7</sup>.

## Principles of surgical intervention

Once an aortic root abscess is diagnosed, surgery is required because antibiotics alone will fail to control the infection, and successful surgery is usually curative<sup>5</sup>. However, the surgical management of periannular abscess can be challenging with reported mortality rates up to 23%<sup>18,9</sup>. Well-judged and executed surgery can result in elimination of infection and long term survival.

Our preference for dealing with this condition is to use a full sternotomy approach. The cannulation strategy is guided by the intraoperative TOE findings and is usually ascending aortic and two stage cavoatrial cannulation, unless there is evidence of significant mitral valve involvement or fistulae from the aorta to other cardiac chambers, most commonly the right atrium. Intermittent cold blood retrograde and antegrade cardioplegia is the preferred myocardial protection strategy. Several principles that apply to the surgery have evolved over the years:

- 1) Radical debridement of infected material is important. There is now a much greater understanding that adequate resection of infected material may be the most important principle. This has been well described by Feindel – "It's not what you put in that's important, it's what you take out"<sup>10</sup>.
- 2) Reconstruction of anatomical defects following debridement by patch reconstruction using biological material such as pericardium if possible but alternatively synthetic Dacron®/Æ patches.
- 3) Abscess cavities debrided and either left open or patched but not closed under tension.
- 4) Use of appropriate valve or aortic root substitutes in specific cases. Historically this has favoured the use of cryopreserved allografts; however, more contemporary series tend to support the idea that the type of valve substitute does not determine the risk of reinfection or survival<sup>11,12</sup>.



The application of these techniques will now be considered in more detail. The range of techniques utilised for treating native valve endocarditis and prosthetic valve endocarditis are largely the same and will be considered together. It is worth noting that destruction associated with prosthetic valve endocarditis tends to be more extensive and when infection is based around the sewing ring then there is a typical picture of abscess formation with the annulus “blown apart” circumferentially with detachment of the anterior leaflet of the mitral valve.

## Radical Debridement, Reconstruction and Conventional Valve Replacement

This technique involves the resection of the native aortic valve or prosthetic valve followed by careful inspection of all adjacent structures and radical debridement of all visibly infected tissue. Defects subsequently can be closed by direct suture or incorporated into the valve implant suture line if this can be accomplished without tension. Alternatively patch reconstruction may be required for larger defects to accomplish tension free closure. Fistulae between the aortic root and the right atrium or the right ventricle or septal defects should be patched from the left ventricular outflow side sutured against healthy tissue with a margin of tissue from the defect. The free edge of pericardial patches can be incorporated into the valve implantation suture line. Occasionally, valve implant sutures may need to be placed from outside the aorta. Bulky vegetations on the right atrial side may require direct removal by a direct approach through the right atrium. Satisfactory early and long-term clinical outcomes have been reported by different groups using such a range of techniques.

In a study of 36 consecutive patients with acute aortic valve IE and paravalvular abscesses, Bauernschmidt et al. demonstrated low rates of recurrent endocarditis (3.6%) during the hospital stay with an overall mortality of 14%. In this series, the abscesses were radically resected and the cavities closed either with direct suture or with Dacron patches, followed by mechanical valve replacement <sup>13</sup>.

In a retrospective study of 122 patients with IE (native valve IE, n=76; prosthetic valve IE, n=46) of which 62 patients had paravalvular abscesses, d’Udekem et al. demonstrated an operative mortality of 7.4% with 76% of patients free of recurrent infection at 8 years and an actuarial survival at 10 years of  $61 \pm 6\%$  <sup>14</sup>. The abscesses were treated by radical resection of the valve and surrounding tissues, annular reconstruction with either fresh autologous pericardium or glutaraldehyde-fixed bovine pericardium, and valve replacement.

These results were supported by a more recent study by Aagaard et al. in 50 patients with aortic and/or mitral valve (MV) active IE (AV, n=24 patients; MV, n=21 patients, AV and MV, n=5 patients) where 48% of patients had annular destruction and needed radical debridement and valve replacement <sup>15</sup>. This study reported an early mortality of 12% and a 2% recurrence of endocarditis during a median follow-up period of 45 months (range, 6 to 66 months).

Occasionally, the intervalvular fibrous body between the aortic and mitral valves is involved and will require debridement and reconstruction. This can be achieved, as described by David, by approaching the aortic and mitral valves through the aortic root and the dome of the left atrium <sup>16</sup>. After excising the aortic valve, the intervalvular fibrous body and the mitral valve, a tailored patch of Dacron or pericardium can be sutured to the lateral and medial fibrous trigones and to the aortic root thus re-establishing both the aortic and mitral annuli. A prosthetic mitral valve is then implanted and a separate patch is used to close the left atriotomy before implantation of a prosthetic aortic valve. A recent analysis by David’s group in 76 consecutive patients demonstrated 10% operative and 24% late mortality. The

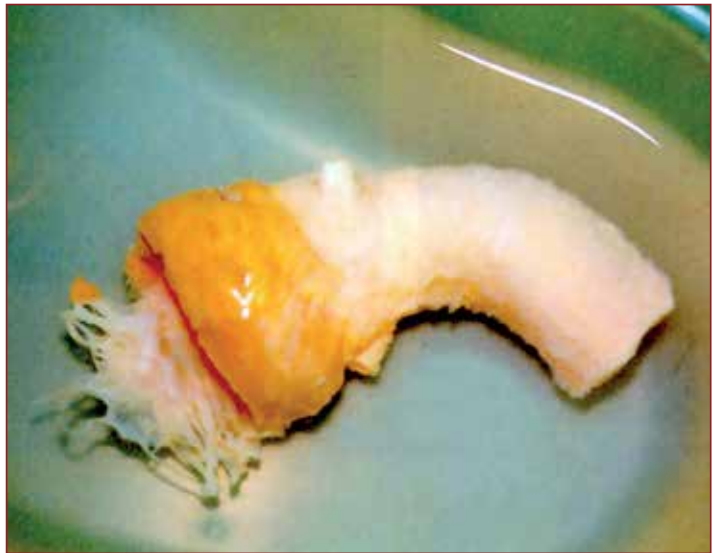10-year survival was  $50\% \pm 9\%$  suggesting that although reconstruction of the intervalvular fibrous body is a technically challenging operation, it can be useful in this small subset of patients with complex valve pathology for whom no alternative procedure is available <sup>17</sup>.

A complex modified aortic translocation technique (modified Danielson's) has been described in patients with prosthetic valve IE and extensive periannular extension (extensive root infection with major disruption of the aortic annulus, dehiscence of greater than 50% of the valve prosthesis with perivalvular necrosis extending to greater than 50% of annular circumference, and the presence of one or more periannular abscesses) <sup>18</sup>. This technique involves transecting the aorta circumferentially 1 cm above the coronary ostia, closure of the native coronary ostia, placement of a prosthetic valve sewn inside the Dacron tube in the ascending aorta and bypass grafting of coronary circulation. This group reported a hospital mortality of 14% and no prosthetic aortic valve endocarditis recurrence at long term follow up <sup>20</sup>. We have no experience of this technique and indeed have not encountered practical situations in which it seems necessary.

## Radical debridement and aortic root replacement

Aortic root replacement can be carried out using autografts (Ross procedure), cryopreserved allografts (Figure 2), stentless xenograft aortic roots and composite mechanical/biological root prostheses. We find this to be necessary in only a minority of cases and our preference is strongly to retain the anatomical native aortic root and to opt for reconstruction wherever possible.

The Ross procedure has proven to be a valid option to treat aortic valve disease <sup>19</sup>. The advantages of the pulmonary autograft have been clearly established, mainly resistance to infection, absence of thromboembolism, long-term durability and excellent haemodynamic performance. This procedure is particularly well suited for left ventricular outflow tract reconstruction after extensive debridement of infected and necrotic perivalvular tissue in active or advanced IE <sup>20</sup>. Excellent results have been reported in patients with active IE.



*Figure 2: Cryopreserved Aortic Allograft conduit.*

Birk et al. reported a small series of 9 patients aged between 8 months and 38 years, with aortic IE who underwent the Ross procedure <sup>21</sup>. There were no perioperative or late deaths, and no recurrent endocarditis of the implanted valves. Echocardiographic evaluation at discharge showed trivial to mild aortic insufficiency with no stenosis at the left ventricular outflow tract. At follow up (range, 4 months to 5.5 years), none of the patients showed progression of aortic valve insufficiency or developed significant outflow tract stenosis.

Schmidtke et al. reported no recurrence of IE after the Ross procedure in 296 patients including 20 with active IE<sup>22</sup>. Their criteria for use of the Ross procedure rather than a prosthetic valve were age, confinement of the endocarditic process to the aortic root, presence of an experienced surgeon, and the availability of an allograft.

Nevertheless, there is often criticism of the Ross procedure and its use in what is already a complex and demanding surgical setting. This technique constitutes a double valve replacement for single valve disease and requires a longer aortic cross clamp time in an already challenging surgical situation. With an experienced surgeon in the right situation, it can clearly be successfully applied. However, in real world practice, only a minority of cases are treated in this way.

Cryopreserved allograft aortic valve replacement is an alternative option for the treatment of extensive aortic IE. This is most commonly applied as a free-standing root replacement rather than the older subcoronary implantation technique which has largely been superseded. These valve substitutes have several potential advantages in comparison to a mechanical valve: superior hemodynamic function, avoidance of anticoagulation, freedom from thromboembolism and greater resistance to infection. Allografts have the technical advantage of being more flexible compared to the rigid ring of prosthetic valves as well as the presence of additional periannular tissue, including both a muscular cuff and the anterior leaflet of the mitral valve. These can be used to fill irregular tissue defects after extensive debridement or using the anterior mitral leaflet to patch defects.

Sabik et al. reported their experience of aortic root replacement with allografts in 103 consecutive patients with prosthetic aortic valve endocarditis, where 78% of patients had an aortic root abscess<sup>23</sup>. Hospital mortality was 3.9%. Survival at 1, 2, 5 and 10 years was 90%, 86%, 73%, and 56%, respectively. In this series, 4 patients underwent reoperation for recurrent infection of the allograft (95% freedom from recurrent IE at 2 years).

Musci et al. presented a series of 221 patients who had allograft aortic root replacement due to either native valve endocarditis (n=99, 45%) or prosthetic valve endocarditis (n=122, 55%)<sup>24</sup>; periannular abscesses were present in 189 patients (86%). Overall survival for native valve endocarditis at 30 days and 1, 5, and 10 years was 83.8%  $\pm$  3.7%, 76.6%  $\pm$  4.3%, 66.5%  $\pm$  4.9%, and 47.3%  $\pm$  5.6%, respectively; this was significantly better than for patients with prosthetic valve endocarditis, who had a greater tendency toward abscess formation (p=0.029). Thirty-one patients (14%) required reoperation for either structural valve deterioration (n=19, 8.6%) or recurrent endocarditis of the allograft (n=12, 5.4%). One-year reoperation mortality rate was 16.1% (n=5).

It is important to note that allografts have their own drawbacks of a high rate of early calcification and limited availability, particularly in the larger sizes; therefore, alternative bioprostheses have been utilised, such as the Freestyle xenograft porcine stentless valves (Medtronic, Dublin, Ireland), which offer a useful alternative for reconstruction in a radically debrided annulus and do not suffer from a shortage of supply. They again have limitations based on length and size range but despite this are a useful alternative.

Schneider et al. reported a series of 55 Freestyle prostheses that were implanted for aortic valve IE involving the root in 54 patients<sup>25</sup>. Early and late mortality were 11% (6 patients) and 14% (7 patients), respectively, with an estimated overall survival at 1 and 5 years of 83% and 70%, respectively. In this study, 1 patient underwent reoperation for recurrent endocarditis 2.3 years after the initial procedure and there was no survival difference between patients with native or prosthetic valve IE.

In a smaller series of 32 patients who received a Freestyle aortic root replacement for aortic IE, Heinz et al. demonstrated a 30-day mortality of 19.4% with an actuarial survival at 5 and 10 years of 61.9% and 54.2%, respectively<sup>26</sup>. A composite end-point of freedom from death, reoperation for prosthetic dysfunction and recurrence of endocarditis at 5 and 10 years was 56.3% and 53.1%, respectively.

For comparison of the results of porcine xenografts and allografts, Siniawski et al. compared the use of stentless aortic valve replacement in 25 consecutive patients with aortic annular abscess to 68 consecutive historical patients with similar disease in whom an aortic allograft was implanted<sup>27</sup>. In this study, 60-day mortality was 16% (11 patients) in the allograft group compared with 12% (3 patients) in the stentless xenograft group; recurrent infection occurred in 4% in both groups.

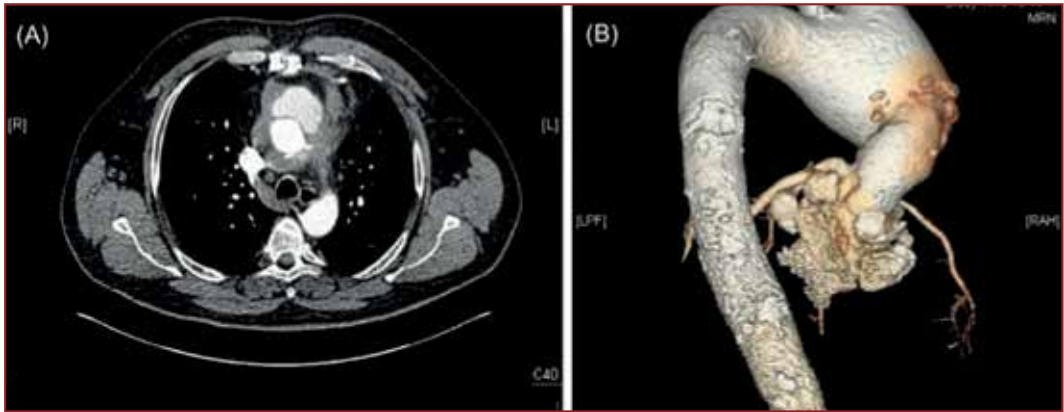
When comparing outcomes between allografts and mechanical valve replacement, Gulbins et al. studied 77 patients (mean age  $49 \pm 9$  years) operated on for acute aortic valve IE<sup>28</sup>. Aortic homografts were implanted in 43 patients, and mechanical valve prostheses in 34 patients. Perioperative mortality was significantly lower in the homograft group (11.5%,  $n=5$  patients) compared to the mechanical valve group (20.5%,  $n=7$  patients,  $p < 0.05$ ), however, in patients with paravalvular abscesses, the difference in perioperative mortality was much greater (mechanical vs homograft, 57.1% versus 12.5%,  $p < 0.05$ , respectively).

Leyh et al. reported a series of 29 patients with prosthetic aortic valve endocarditis combined with aortic root destruction who underwent reoperation<sup>29</sup>. In this series, 16 patients underwent aortic root replacement with allografts and were compared to 13 patients who underwent replacement with a composite prosthetic valve/graft. Hospital mortality was 18.5% ( $n=5$  patients, 3 in the allograft group). Survival at 1 and 5 years was  $81\% \text{ @ } \pm 10\%$  and  $81\% \text{ @ } \pm 10\%$  in the allograft group, and  $85\% \pm 10\%$  and  $85\% \pm 10\%$  in the composite valve/graft group, respectively, suggesting that good long-term results can be achieved regardless of the material used for aortic root replacement in patients with prosthetic aortic valve endocarditis.

Similarly, Jassar et al. studied 134 patients (90 reoperative cases) who underwent aortic root replacement for active IE<sup>30</sup>. In this series, 110 patients had an abscess (82.1%) and 62 (46.3%) patients had a pseudoaneurysm, rupture or both. A mechanical composite valve/graft was used in 43 patients (32.1%), a non-allograft biologic valve conduit in 55 patients (41.0%), and an allograft valve in 36 patients (26.9%). There was no significant difference between the groups in the incidence of major complications or in-hospital mortality. During a mean follow-up of  $32.1 \text{ @ } \pm 29.4$  months, the rates of readmission, reinfection and reoperation were similar for the three groups. The mean 5-year survival in the study was  $58 \pm 9\%$  for the mechanical composite group,  $62 \pm 7\%$  for the biological composite group, and  $58 \pm 9\%$  for the allograft group, respectively ( $p=0.48$ ), suggesting again that the material used does not impact on outcomes.

## Infected aortic root prostheses

Extensive aortic root infection is a significant challenge to the practising surgeon. Nevertheless, infection in the context of previous surgery to replace part of or the whole of the aortic root although rare, represents a further daunting challenge (Figure 3)<sup>31</sup>. Proven infection of the aortic root, particularly where there is loss of integrity of any of the suture lines resulting in false aneurysm formation, is an indication for further surgery.



*Figure 3: (A) Axial CT Scan view of the ascending thoracic aorta showing false aneurysms at the proximal anastomosis of a biological root. (B) 3D reconstruction demonstrating the presence of false aneurysms with an additional progressive aneurysm formation of the proximal arch.*

Initial treatment should, as usual, be based on appropriate antibiotic therapy for a prolonged period. Further decision making must therefore be based on an assessment of the surgical options and acceptance by the patient of the higher levels of risk these will entail.

However, where there is less evidence of tissue destruction, an individual decision should be made with respect to the predicted risk of further definitive surgery.

Where there is clear evidence of infection, the alternatives are:

### 1 Prompt operative treatment

This strategy can be associated with significant early mortality particularly as patients may often present in a poor clinical condition which may mandate urgent or emergency intervention. Careful judgement is required with respect to timing where antibiotic therapy has the potential to reduce the effects of systemic sepsis and potentially reduce the risk of operation, set against the inherent risk of the destructive effect of ongoing local infection.

The principles include complete debridement of infected and necrotic tissue, removal of infected prosthetic material, local antiseptic irrigation, appropriate long-term specific systemic antibiotics and the use of pedicle flaps to obliterate space, which can be either muscle flaps or transposed vascularised omental flaps<sup>31,32,33,34</sup>.

It is preferable to use biological material which can be accomplished with the utilisation of an allograft root replacement, composite porcine/pericardial (Shelhigh/Biointegral prosthesis) or porcine root replacement (Figure 4)<sup>23,34,35,36</sup>. Conventionally, the allograft has been the choice for this kind of reconstruction. However, the main limitations of the lack of availability of larger sizes and the limitations of length to bridge long segment defects have led surgeons to develop custom made solutions including the creation of a neo-aorta with heterologous pericardium<sup>35,36</sup>.

Lytle et al. presented a series of 27 patients with prosthetic aortic valve IE after previous ascending aortic replacement (aortic root replacement in 13, aortic valve replacement with a supracoronary graft in 14); root abscess formation was present in 89% and aortoventricular discontinuity in 41%. Radical debridement of infected prosthetic material was performed,



along with allograft aortic root and ascending aorta replacement combined with intravenous antibiotic therapy<sup>37</sup>. The group reported in-hospital mortality of 3.7% and survival at 1, 2, 5, and 7.5 years was 92%, 88%, 70%, and 56%, respectively, with only one patient requiring reoperation for recurrent IE within a year after surgery. These are truly outstanding results in a very challenging group of patients and may not be representative of outcomes in this group of patients across a broad range of centres.

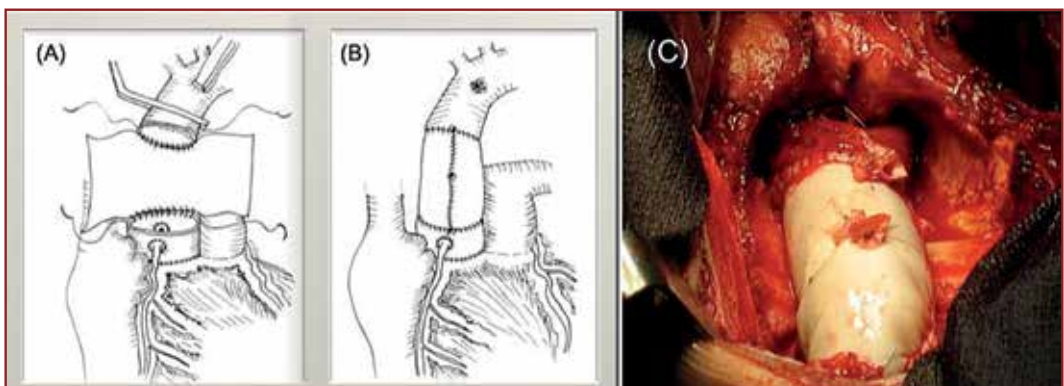
Where suture lines are not intact and there is false aneurysm formation then definitive reconstruction is the only viable option<sup>30</sup>. Given that infected false aneurysm formation may impinge on sternal re-entry then a further range of techniques may be required to mitigate this risk including profound systemic hypothermia and apical left ventricular venting via a left 4th interspace minithoracotomy to guard against left ventricular distension during cooling. These approaches in themselves add further levels of complexity and risk to already complicated surgical scenarios.

Importantly, it essential to understand that there is no perfect conduit/valve replacement, and all available substitute materials have their limitations including limited availability, length, size range, the risk of false aneurysms or ongoing infection, and an individualised approach to deal with specific situations may be required.

## 2 Non-operative treatment with long term antibiotic therapy

This technique can be utilised in a specific set of patients where early graft infection occurs sometimes in association with major infective sternal wound complications, where the risk of radical surgery is considered too high. We have previously demonstrated that radical treatment of the source of infection without explant of the prosthesis but with omental transposition or muscle flaps can be sufficient as a palliative approach and associated with good outcomes at least in the medium term<sup>38</sup>. Long term antibiotic therapy can effectively suppress infection but it is hard sometimes to persuade microbiology colleagues that long term antibiotics are an acceptable approach but sometimes a pragmatic approach is required to these problems.

Recently, the use of endovascular occluding devices or plugs have been used to occlude the entry to infected false aneurysms in patients who are deemed very high risk and not suitable



*Figure 4: Illustration of the use of porcine xenograft with a neo-aorta to replace the ascending aortic segment (A) A pericardial patch is sutured both proximally and distally to the aorta then the two remaining free edges joined anteriorly. (B) The final appearance of the replaced segment. (C) Intraoperative view of the porcine xenograft in situ.*



for surgical intervention; however, the data is limited and this remains a controversial issue due to the risk of developing further infection on the device itself even with long-term antibiotics<sup>39,40,41</sup>.

## Conclusions

Periannular complications are frequently detected in patients with IE especially when the diagnosis and commencement of appropriate antibiotic therapy is delayed. Surgical intervention in this group of patients is challenging, particularly for those with extensive tissue destruction and involvement of the intervalvular fibrous body and mitral valve. Once such complications are suspected, urgent surgery is required as medical treatment alone will fail to control the infection and surgery is potentially curative. The main principles of surgical intervention are radical debridement of all macroscopically infected tissue followed by the reconstruction of subsequent defects to restore functional and anatomic integrity which can be extremely challenging.

A range of different surgical techniques are required to treat the surgical pathologies encountered, including closure of defects with a patch and valve replacement, or root replacement using biological or prosthetic material. The use of biological material, such as allografts, may have some advantages in certain situations including superior haemodynamic performance and resistance to reinfection but is restricted by the limited supply. The Ross operation is also an excellent option in term of haemodynamics but it is surgically demanding and requires two valve replacements for single valve pathology, so it may not be suitable for all patients especially elderly patients with multiple co-existing comorbidities. Its application in these patients is likely to remain limited.

Stentless porcine aortic valves demonstrate haemodynamic performance similar to that of an aortic allograft and use a minimum of non-biological material. Xenograft porcine root replacement offer a useful biological alternative with low reinfection rates in favourable circumstances.

However, if radical debridement is performed, short- and long-term outcomes can be satisfactory regardless of conduit selection for aortic root replacement. It is necessary to consider the patient's status, age and existing comorbidities, as well as the structural and anatomical challenges when planning surgical intervention in this group of patients, as well as local surgical expertise.

Patients presenting with prosthetic aortic root infection although rare, represent a high-risk subset of patients. The management of these patients depends largely on the integrity of suture lines and the general condition of the patient, and can vary between radical debridement and repeat biological device implantation, or conservative management by controlling the source of infection with long-term antibiotics. Endovascular approaches can be used as an adjunct on occasion to treat infected false aneurysms.

## References

1. Habib G, Lancellotti P, Antunes MJ, et al. 2015 ESC Guidelines for the management of infective endocarditis: The Task Force for the Management of Infective Endocarditis of the European Society of Cardiology (ESC). Endorsed by: European Association for Cardio-Thoracic Surgery (EACTS), the European Association of Nuclear Medicine (EANM). *Eur Heart J*. 2015;36:3075-128.
2. Nishimura RA, Otto CM, Bonow RO, et al. 2014 AHA/ACC Guideline for the Management of Patients With Valvular Heart Disease: a report of the American College of Cardiology/American Heart Association Task Force on Practice Guidelines. *Circulation*. 2014 Jun 10;129(23):e521-643.

3. Mocchegiani R, Nataloni M. Complications of infective endocarditis. *Cardiovasc Hematol Disord Drug Targets* 2009;9:240-8.
4. Evangelista A, Gonzalez-Alujas MT. Echocardiography in infective endocarditis. *Heart* 2004;90:614-17.
5. Kang DH, Kim YJ, Kim SH, et al. Early surgery versus conventional treatment for infective endocarditis. *N Engl J Med* 2012 Jun 28;366(26):2466-73.
6. Chambers J, Sandoe J, Ray S, et al. The infective endocarditis team: recommendations from an international working group. *Heart* 2014 Apr;100(7):524-7. doi: 10.1136/heartjnl-2013-304354.
7. Chirillo F, Scotton P, Rocco F, et al. Impact of a multidisciplinary management strategy on the outcome of patients with native valve infective endocarditis. *Am J Cardiol.* 2013 Oct 15;112(8):1171-6.
8. Bozbuga N, Erentug V, Erdogan HB, et al. Surgical Treatment of Aortic Abscess and Fistula. *Tex Heart Inst J* 2004;31:382-86.
9. Leontyev S, Borger MA, Modi P, et al. Surgical management of aortic root abscess: a 13-year experience in 172 patients with 100% follow-up. *J Thoracic Cardiovascular Surg* 2012;143:332-7.
10. Feindel CM. It's not what you put in that is important, it's what you take out. *J Thorac Cardiovasc Surg.* 2016 May;151(5):1249-50.
11. Kim JB, Ejiogor JI, Yammine M, C et al. Are homografts superior to conventional prosthetic valves in the setting of infective endocarditis involving the aortic valve?. *J Thorac Cardiovasc Surg.* 2016 May;151(5):1239-46, 1248.e1-2.
12. Avierinos JF, Thuny F, Chalvignac V, et al. Surgical treatment of active aortic endocarditis: homografts are not the cornerstone of outcome. *Ann Thorac Surg.* 2007 Dec;84(6):1935-42.
13. Bauernschmitt R, Vahl CF, Lange R, et al. Surgical treatment of acute endocarditis of the aortic valve with paravalvular abscess: considerations justifying the use of mechanical replacement devices. *Eur J Cardiothorac Surg.* 1996;10(9):741-7.
14. D'Udekem Y, David TE, Feindel CM, et al. Long-term results of surgery for active infective endocarditis. *Eur J Cardiothorac Surg.* 1997;11:46-52.
15. Aagaard J, Andersen PV. Acute endocarditis treated with radical debridement and implantation of mechanical or stented bioprosthetic devices. *Ann Thorac Surg* 2001;71:100-3; discussion 04.
16. David TE, Kuo J, Armstrong S. Aortic and mitral valve replacement with reconstruction of the intervalvular fibrous body. *Thorac Cardiovasc Surg.* 1997 Nov;114(5):766-71; discussion 771-2.
17. De Oliveira NC, David TE, Armstrong S, et al. Aortic and mitral valve replacement with reconstruction of the intervalvular fibrous body: an analysis of clinical outcomes. *J Thorac Cardiovasc Surg.* 2005 Feb;129(2):286-90.
18. Nottin R, Al-Attar N, Ramadan R, et al. Aortic valve translocation for severe prosthetic valve endocarditis: early results and long-term follow-up. *Ann Thorac Surg* 2005;79:1486-90.
19. Sievers HH, Stierle U, Charitos EI, et al. Major adverse cardiac and cerebrovascular events after the Ross procedure: a report from the German-Dutch Ross Registry. *Circulation* 2010;122:S216-23.
20. Niwaya K, Knott-Craig CJ, Santangelo K, et al. Advantage of autograft and homograft valve replacement for complex aortic valve endocarditis. *Ann Thorac Surg* 1999;67:1603-8.
21. Birk E, Sharoni E, Dagan O, et al. The Ross procedure as the surgical treatment of active aortic valve endocarditis. *J Heart Valve Dis.* 2004;13:73-7.
22. Schmidtke C, Dahmen G, Sievers HH. Subcoronary Ross procedure in patients with active endocarditis. *Ann Thorac Surg* 2007;83:36-9.

23. Sabik JF, Lytle BW, Blackstone EH, et al. Aortic root replacement with cryopreserved allograft for prosthetic valve endocarditis. *Ann Thorac Surg* 2002;74:650-9; discussion 59.
24. Musci M, Weng Y, Hubler M, et al. Homograft aortic root replacement in native or prosthetic active infective endocarditis: twenty-year single-center experience. *J Thorac Cardiovasc Surg* 2010;139:665-73.
25. Schneider AW, Hazekamp MG, Versteegh MI, et al. Stentless bioprostheses: a versatile and durable solution in extensive aortic valve endocarditis. *Eur J Cardiothorac Surg*. 2016;49:1699-704.
26. Heinz A, Dumfarth J, Ruttman-Ulmer E, et al. Freestyle root replacement for complex destructive aortic valve endocarditis. *J Thorac Cardiovasc Surg* 2014;147:1265-70.
27. Siniawski H, Lehmkuhl H, Weng Y, et al. Stentless aortic valves as an alternative to homografts for valve replacement in active infective endocarditis complicated by ring abscess. *Ann of Thorac Surg* 2003;75:803-8; discussion 08.
28. Gulbins H, Kilian E, Roth S, et al. Is there an advantage in using homografts in patients with acute infective endocarditis of the aortic valve? *J Heart Valve Dis.* 2002;11:492-7.
29. Leyh RG, Knobloch K, Hagl C, et al. Replacement of the aortic root for acute prosthetic valve endocarditis: prosthetic composite versus aortic allograft root replacement. *J Thorac Cardiovasc Surg* 2004;127:1416-20.
30. Jassar AS, Bavaria JE, Szeto WY, et al. Graft selection for aortic root replacement in complex active endocarditis: does it matter? *Ann Thorac Surg* 2012;93:480-7.
31. Coselli JS, Koksoy C, LeMaire SA. Management of thoracic aortic graft infections. *Ann Thorac Surg.* 1999;67:1990–1993.
32. Coselli JS, Crawford ES, Williams TW Jr, et al. Treatment of postoperative infection of ascending aorta and transverse aortic arch, including use of viable omentum and muscle flaps. *Ann Thorac Surg.* 1990;50:868–881.
33. Mitra A, Spears J, Perrotta V, et al. Salvage of infected prosthetic grafts of the great vessels via muscle flap reconstruction. *Chest.* 2005;128:1040–1043.
34. Mahesh B, Caputo M, Angelini GD, et al. Treatment of an aortic fungal false aneurysm by composite stentless porcine/pericardial conduit: a case report. *Cardiovasc Surg.* 2003 Feb;11(1):93-5.
35. Czerny M, von Allmen R, Opfermann P, et al. Self-made pericardial tube graft: a new surgical concept for treatment of graft infections after thoracic and abdominal aortic procedures. *Ann Thorac Surg.* 2011 Nov;92(5):1657-62.
36. Rahman IA, Angelini GD, Hamilton M, et al. Pericardial neo-aorta to bridge long segment defects after infected aortic reconstructions. *J Card Surg.* 2013 May;28(3):295-7.
37. Lytle BW, Sabik JF, Blackstone EH, et al. Reoperative cryopreserved root and ascending aorta replacement for acute aortic prosthetic valve endocarditis. *Ann Thorac Surg.* 2002 Nov;74(5):S1754-7; discussion S1792-9.
38. Akowuah E, Narayan P, Angelini G, et al. Management of prosthetic graft infection after surgery of the thoracic aorta: removal of the prosthetic graft is not necessary. *J Thorac Cardiovasc Surg.* 2007 Oct;134(4):1051-2.
39. Jimenez Valero S, Garcia E, Gonzalez Pinto A, et al. Percutaneous closure of pseudoaneurysm of the mitral-aortic intervalvular fibrosa [in Spanish]. *Rev Esp Cardiol* 2005;58(12):1473–5.
40. Babaliaros VC, Lerakis S, Thourani VH, et al. Transapical closure of a pseudoaneurysm of the mitral-aortic intervalvular fibrosa. *Tex Heart Inst J.* 2015 Jun 1;42(3):285-8.
41. Takamiya Y, Miura S, Sako H, et al. Pseudoaneurysm of the mitral-aortic intervalvular fibrosa following infective endocarditis in a patient with acute heart failure: a case report. *J Cardiol.* 2007 Jun;49(6):353-6.

## Chapter 5

# Surgical Options in Acute Type B Dissection

*Mobamad Bashir, Amer Harky and Aung Oo*

---

*“Per angusta ad augusta”*

## Introduction

Type B aortic dissection involves the aorta distal to the left subclavian artery and accounts for 25% to 40% of all aortic dissections<sup>1</sup>. Management of acute type B aortic dissection represents a dilemma with different groups advocating differing approaches, either surgical, medical or endovascular. However, the current trend in the literature is to adopt a “complication-specific approach”, reserving surgical replacement of the descending aorta for patients with rupture, organ ischaemia, refractory pain, uncontrollable hypertension, sizeable dilatation of the false lumen, or other life-threatening conditions<sup>2</sup>. On admission to hospital, approximately 25% of acute type B dissections are complicated by malperfusion syndrome or haemodynamic instability, resulting in a high risk of early death if untreated<sup>1, 3, 4</sup>. Furthermore, the surge of endovascular techniques has shifted the paradigm with more patients now being treated medically despite the presence of complications that would have previously prompted operative treatment. In this chapter, we present a succinct overview of each option employed in the armamentarium of acute type B aortic dissection management.

## Clinical Manifestations and Signs of Impending Instability

In recent years, the focus has been on identifying uncomplicated acute aortic dissection in patients at a high risk of aortic enlargement and aortic complications who might benefit from early surgical intervention. Dake et al. proposed a new mnemonic-based classification that addresses six specific anatomic and clinical aspects and can help in decision-making (DISSECT: duration of disease, intimal tear location, size of dissected aorta, segmental extent of aortic involvement, clinical complications and thrombosis of false lumen)<sup>5</sup>.

Partial thrombosis of the false lumen has been shown to increase the risk of aortic expansion and to predict late mortality<sup>5,6</sup>. Identifiable risk factors for partial false lumen thrombosis include visceral branches arising from the false lumen, re-entry tears and the maximum diameter of the abdominal aortic false lumen<sup>7</sup>.

Ulcer-like projections (localised blood-filled pouches) which protrude into the thrombosed false lumen on computed tomography (CT) are associated with late aortic events<sup>8</sup>. However, certain studies suggest that a primary entry tear located on the concavity of the distal aorta instead of the convexity is more frequently associated with complicated dissections and this might have an impact on the optimal strategy employed to treat type B aortic dissection<sup>9,10</sup>.

A large entry tear [ $>10$  mm] in the proximal part of the dissection identified a high-risk subgroup of patients with more rapid aortic expansion and a higher incidence of dissection-related events, probably due to the higher false-lumen pressures achieved in the presence of larger tears. Furthermore, in many patients, dissection complications appeared after 3 years of follow-up, suggesting that the haemodynamic or structural factors responsible have a slow effect over time<sup>11</sup>.

Regarding timing of intervention, this remains a matter of controversy. The optimal timing of thoracic endovascular aortic repair (TEVAR) in uncomplicated acute dissection is also debatable. Earlier treatment may provide benefit in terms of complete remodelling due to maximum ductility of the dissection flap, however, the process of acute inflammation of the aortic wall might increase the risk of iatrogenic damage by either the wires or the stent graft, thus increasing the risk of retrograde dissection.

Desai et al. have evaluated the impact of timing on major complications in 132 patients who underwent stent graft intervention<sup>12</sup>. They found a correlation between earlier intervention and increased peri-procedural complications (38.7% vs. 27.3% vs. 5.6%, respectively, in acute-early, acute-delayed and subacute patients). Probably, the subacute phase might be the ideal timing to perform intervention, reinforcing the notion that close monitoring is crucial.

## Diagnosis

Accurate diagnosis of aortic dissection and a high index of suspicion are imperative especially in patients with predisposing risk factors such as hypertension, known and documented aneurysmal disease of the aorta, or familial connective tissue disorders. A full history and knowledge of the patient's medical status is not always possible, for example, when patients are moribund.

## Biochemical markers

The quest for the ideal biomarker for the detection and screening of aortic aneurysm and dissection continues. A standard blood-based test, capable of detecting individuals at risk of aortic aneurysm and dissection is still not yet available. Currently, several biomarkers are being investigated as indicators for prediction, risk stratification and prognostic evaluation in aortic patients including: D-dimer, Plasmin, Fibrinogen, Matrix metalloproteinases, Cytokines, CD4+ CD28- cells, C-reactive protein, Elastin peptide, Endothelin, Hepatocyte growth factor, Homocysteine and Ribonucleic acid signature.

D-dimer has previously been identified as a potential biomarker in aortic dissection having a sensitivity of 99%. Its disadvantage though is that elevated D-dimers are highly non-specific, particularly in diseases of the chest. This critical point negates its usefulness as a sole biomarker. The development of RNA signatures is yielding significant interest. These biomarkers measure RNA regulation related to aortic aneurysms and potentially could be useful in dissection and rupture prediction. Thus far, this RNA signature test has shown to be 80% accurate in determining whether a patient has an aneurysm, and may prove useful as a screening tool.

Smooth muscle myosin heavy chain, a major component of the smooth muscle in the aortic medial layer, is released into the circulation shortly after the onset of dissection. In a pilot study, the assay [ $>2.5$  microgram/L] had a sensitivity of 90.9% and specificity of 98% in detecting acute aortic dissection as compared to healthy volunteers<sup>13</sup>.

Elastin is another major structural component of the medial layer of the aortic wall. Shinohara and colleagues demonstrated that an ELISA measuring soluble elastin fragments [sELAF] in the serum with the cut-off set at + 3 SD (standard deviation) above the mean of age-adjusted healthy subjects had a sensitivity of 88.9% and specificity of 99.8%. However, the ELISA for sELAF takes 3 hours to perform, a major drawback for a time sensitive condition such as acute aortic dissection.

## Imaging

The choice of diagnostic imaging depends upon the patient's stability, local expertise, and availability. It should be used to diagnose aortic dissection, identify the type/extent, and locate intimal tears. Imaging should confirm the presence of the true and false lumen and whether thrombus is present and assess any aortic side branch involvement. In addition, it



is important to detect any aortic regurgitation or coronary artery dissection, and aid in the identification of other potential sequelae of dissection such as malperfusion.

Aortography has lost its place as the gold standard test due to several serious disadvantages, including the use of a heavy dose of intravenous contrast [1 mg/kg], the risks of an invasive procedure, and the extended time it takes to complete the procedure [up to 2+ hours]. In 2002 the International Registry of Acute Aortic Dissection (IRAD) reported that computed tomography angiography (CTA) is used in 63% of cases of suspected aortic dissection, followed by transoesophageal echocardiography (TOE) in 32%, aortography 4%, and magnetic resonance angiography (MRA) in 1%<sup>14</sup>.

Computed tomography angiography, TOE and MRA have similar pooled sensitivity (98%–100%) and specificity (95%–98%) although the pooled positive likelihood ratio appeared to be higher for MRA (positive likelihood ratio, 25.3; 95% confidence interval (CI), 11.1–57.1) than for TOE (14.1; 6.0–33.2) or CTA (13.9; 4.2–46.0). CTA is widely available and relatively rapid, provides visualisation of the entire aorta down to the iliac arteries, and delineates the involvement of aortic side branches<sup>14,15</sup>. Using ECG-gated CT, the patient's ECG signal is used to omit scan data acquired during the systolic phase of highest cardiac motion. With this approach, cardiac pulsation artefacts in CT studies of the aorta, of paracardiac lung segments, and of coronary bypass grafts can be effectively reduced. Whilst CTA is the definitive first imaging choice, it does include the requirement that patients are transported to the CTA suite, the use of potentially nephrotoxic contrast, and the inability to assess aortic insufficiency.

MRA is highly accurate and does not require the use of a contrast dye. It is, however, usually unavailable on an emergency basis and requires patients to be in the MRA suite for an extended period. Other issues such as claustrophobia, ventilated patients, and patient's use of metal devices [pacemakers, aneurysmal clips] may further complicate its routine use<sup>17</sup>.

TOE is a viable alternative in patients who are critically ill and or haemodynamically unstable. The main advantages of a TOE include speed, good sensitivity and specificity, and the fact that it can be performed at the patient's bedside. Its main limitations are lack of widespread expertise and subjective reporting which necessitates a high level of expertise to avoid false positive reports.

## Medical Management of Acute Type B Dissection

Historically, the medical management of acute type B dissection gained credence with the introduction of the concept of anti-impulse therapy as described by Wheat et al.<sup>16</sup>. They demonstrated force of contraction (dP/dt max) and blood pressure in the propagation of acute dissection in a dog model<sup>17</sup>. Starting in the early 1970's, medical management of uncomplicated type B dissection was increasingly gaining the position as the standard of care due to availability of antihypertensives and the lower mortality compared to surgery.

A combination therapy of anti-impulsive therapy and antihypertensives remains the cornerstone of modern medical management of type B aortic dissections. However, the concept of medical management has been challenged by various authorities worldwide. The issues include: how to delineate patients with hypertensive crises or refractory hypertension, malperfusion and patients who are haemodynamically stable but have impending risk of rupture.

The IRAD trial data showed that in-hospital mortality after medical management was significantly increased in average-risk patients with type B aortic dissection under medical

therapy with refractory hypertension/pain compared with those without these features (35.6% vs. 1.5%;  $p = 0.0003$ )<sup>18</sup>. The same applied to malperfusion which was too subtle to be detected early.

In most cases, patients who underwent medical therapy presented with uncomplicated dissection, although a percentage required early intervention for complications that developed during the hospital stay. A minority of patients with complications were treated with medical therapy only, either due to the lack of appropriate facilities or due to the presence of comorbidities or morphology that made open surgery or endovascular intervention not feasible. For acute aortic dissections treated medically, the pooled early mortality rate was 6.4% (95% CI: 5.1% to 7.9%). The pooled rates of stroke and spinal cord ischaemia developing early during medical management alone were 4.2% (95% CI: 2.3% to 7.4%) and 5.3% (95% CI: 3.4% to 8.4%), respectively, with a combined early neurological complication event rate of 10.1% (95% CI: 7.5% to 13.5%). Long-term survival ranged from approximately 70.2% to 89% at 5 years<sup>19-30</sup>.

In the current era, the Interdisciplinary Expert Consensus Document on Management of Type B Aortic Dissection, presented outcome data on 1,529 patients with acute complicated type B aortic dissection submitted to open surgical repair<sup>31</sup>. The pooled early mortality rate was 17.5% (95% CI: 15.6% to 19.6%). The pooled mean rates of early stroke and spinal cord ischaemia after treatment were 5.9% (95% CI: 4.8% to 7.3%) and 3.3% (95% CI: 2.4% to 4.5%), respectively. Five-year survival rates ranged from 44% to 64.8%. Freedom from aortic events and re-intervention ranged from 58.7% to 68% at 5 years.

The expert consensus also reported a summary of pertinent results for endovascular intervention of acute type B aortic dissection on available data from 2,359 patients<sup>31-33</sup>. The early pooled mortality rate was 10.2% [95% CI: 9.0% to 11.6%]. Pooled rates of early stroke and spinal cord ischaemia after treatment were 4.9% [95% CI: 4.0% to 6.0%] and 4.2% [95% CI: 3.3% to 5.2%], respectively. Survival rates ranged from 56.3% to 87% at 5 years and freedom from aortic events ranged from 45% to 77% at 5 years.

## What have we learned from the INSTEAD Trial?

The INvestigation of STent Grafts in Aortic Dissection (INSTEAD) Trial represents the first prospective randomised study of elective stent graft placement in survivors of uncomplicated chronic type B aortic dissection. It demonstrated that thoracic stent graft placement failed to improve the rates of 2-year survival and adverse events when compared with optimal medical therapy. The trial included one hundred and forty patients in a stable clinical condition at least 2 weeks after index dissection, who were randomly subjected to elective stent graft placement in addition to optimal medical therapy ( $n=72$ ) or to optimal medical therapy alone ( $n=68$ ) with surveillance (arterial blood pressure according to World Health Organization guidelines of 120/80 mm Hg). The primary endpoint was all-cause death at 2 years, whereas aorta-related death, progression (with need for conversion or additional endovascular or open surgery), and aortic remodelling were secondary endpoints. There was no difference in all-cause deaths, with a 2-year cumulative survival rate of  $95.6 \pm 2.5\%$  with optimal medical therapy versus  $88.9 \pm 3.7\%$  with TEVAR ( $p=0.15$ ).

Moreover, the aorta-related death rate was not different ( $p=0.44$ ), and the risk for the combined end point of aorta-related death (rupture) and progression (including conversion or additional endovascular or open surgery) was similar ( $p=0.65$ ). Three neurological adverse events occurred in the TEVAR group (1 paraplegia, 1 stroke, and 1 transient paraparesis), versus 1 case of paraparesis with medical treatment. Finally, aortic

remodelling (with true-lumen recovery and thoracic false-lumen thrombosis) occurred in 91.3% of patients with TEVAR versus 19.4% of those who received medical treatment ( $p < 0.001$ ), which suggests ongoing aortic remodelling after endovascular intervention<sup>32</sup>.

Of major concern in this trial was the fact that the study was underpowered to evaluate the mortality end point, as was pointed out by the authors in their article. For the study to have adequate power, 28 events needed to be observed, but only 11 events were observed. Thus, the significance of the negative results of this study must be called into question. Extending the follow-up of these patients would potentially provide further time points to allow for a more meaningful analysis of the data<sup>35, 36</sup>.

## Patient Selection & Treatment Options

According to the Interdisciplinary Expert Consensus Document on Management of Type B Aortic Dissection, the panellists' suggestions for treatment of acute type B aortic dissection were as follows:

- Patients with uncomplicated acute type B aortic dissection should be treated with medical therapy. At present, there is no evidence of advantage with TEVAR or open surgery.
- TEVAR, when feasible, should be considered the first-line treatment in complicated acute type B dissection. A survival benefit is achieved by TEVAR in comparison with open surgery.
- Aneurysmal evolution and eventual rupture may occur even in the absence of warning symptoms, and imaging follow-up must be performed at regular intervals. CT or MRI scan should be used to monitor uncomplicated dissections and should be performed at admission, after 7 days, on discharge, and at 6 weeks, because the risk of instability is higher in the early phase.
- Despite reasonably low early operative morbidity and mortality, there is a likelihood of aortic adverse events after TEVAR, and all patients should undergo ongoing surveillance after treatment.

## Surgical Options for Acute Type B Aortic Dissection.

### Endovascular Intervention

The aim of TEVAR for aortic dissection is to discontinue blood flow into the false lumen by covering the primary entry tear, and to restore blood flow into the true lumen. The false lumen subsequently depressurises, preventing extension of dissection and ideally leading to false lumen thrombosis with subsequent aortic remodelling<sup>37, 38</sup>.

Adequate preoperative sizing of the stent-graft is a key aspect to achieve adequate fixation, without damaging the aortic wall. Device 'oversizing' in type B dissection patients remains debatable as it is associated with severe complications such as stent-graft-induced new entry tears, retrograde type A dissection, and proximal neck dilatation with subsequent stent-graft migration<sup>13, 40, 41</sup>. In general, oversizing by no more than 0–10% is recommended for patients with aortic dissection.

Mismatch-sizing of the stent-graft can be avoided by keeping in mind the dynamic behaviour of the aorta<sup>14, 42</sup>. Adequate device size should be based on the diameter of the

aorta proximal to the dissected segment. Furthermore, a proximal aortic neck length of at least 2 cm is needed to achieve adequate fixation of the stent-graft<sup>37</sup>.

The first technical challenge for TEVAR procedures is introducing the stent-graft into the usually narrowed true lumen. Transoesophageal echocardiography may offer valuable assistance for this task. In addition, intravascular ultrasound and phased array intracardiac ultrasound have been reported as useful imaging tools for this procedure. Accurate deployment of the stent-graft requires endovascular experience and may be assisted by blood pressure and pulse regulation<sup>15,32</sup>.

When access challenges are encountered, an antegrade approach via the brachial artery might offer a solution to snare a guidewire in the aorta. Iliac artery endoconduits have also emerged as safe alternative access routes<sup>33</sup>. For deployment of the stent-graft, a tip-capture system allows selective release of the proximal spring which permits repositioning before fully releasing the endograft. Such a system is particularly useful for deploying a stent-graft in a curved vessel like the thoracic aorta<sup>43-44</sup>. After deployment, ballooning is not recommended due to the risk of devastating complications such as retrograde type A aortic dissection and aortic rupture<sup>18, 19, 20, 45</sup>. Based on the self-expanding character of the stent and the time required for aortic remodelling, a conservative approach is advised after deployment, even if the stent-graft has not fully expanded. Technical success rates of TEVAR are high for both acute type B dissection, ranging from 93.3% to 100%, as well as for chronic type B dissection, ranging from 77.6% to 100%<sup>21-24</sup>.

## ADSORB Trial

TEVAR has now gained broad approval for the treatment of dissection of the descending thoracic aorta, which includes the treatment of uncomplicated dissections, despite a lack of robust data to support this indication. Specifically, no level A evidence exists to support endovascular treatment of acute, uncomplicated DeBakey III dissections, and medical management is still considered the best treatment as we indicated above.

The ADSORB trial is the first randomised trial of acute dissection and compares best medical treatment (BMT) with BMT plus thoracic stent grafting of the primary entry tear in patients with acute uncomplicated type B dissection<sup>25</sup>. This multicentre, prospective randomised controlled trial, performed at 17 European centres, randomised 61 patients (31 BMT group, 30 BMT + TEVAR group), aged 18 to 80 years, with uncomplicated (no rupture, malperfusion, or refractory pain) acute type B dissection (penetrating ulcer and intramural haematoma patients excluded). Important exclusion criteria included retrograde extension of the dissection proximal to the left subclavian artery, anatomy not amenable to TEVAR, severe renal or respiratory insufficiency, and the presence of a connective tissue disorder.

The calculation of sample size at trial inception in 2002 called for 250 patients to be randomised, but this was subsequently revised because of slow recruitment as well as newer data from the INSTEAD trial suggesting the study end points could be assessed with a smaller sample size.

The primary study endpoint was a composite of: (1) incomplete or no false lumen thrombosis at 1 year; (2) aortic dilatation [ $\geq 5$  mm or maximum aortic diameter  $\geq 55$  mm] at 1 year, and (3) descending thoracic or abdominal aortic rupture up to the 1-year follow-up visit. The alternative hypothesis for the trial was that the proportion of patients being event free at 1 year would be greater for those treated with TEVAR and medical therapy versus medical therapy alone. Analysis of the primary end point was based on intention to treat

regardless of treatment received, and morphological analysis of the imaging end points was done by an independent core laboratory.

Early results of the trial were discussed at the Aortic Symposium in New York in 2016, and indicated a statistically significant greater freedom from the composite end point at 1-year in the BMT plus TEVAR group as compared to those in the BMT alone cohort [57% vs 3%,  $p < 0.001$ ], although it appears that this was driven almost entirely by a significant difference in false lumen thrombosis between groups, as no significant difference was seen in the aortic dilatation and rupture components of the composite end point.

Secondary aortic remodelling end points also favoured the BMT plus TEVAR group, with a statistically significant larger true lumen and smaller false lumen, and a trend toward smaller overall aortic diameter, as compared to the BMT alone cohort.

On critical appraisal of the ADSORB trial however, certain defining points raise issues regarding its culprit and focus analysis. Firstly, the definition of false lumen thrombosis was not the same in the BMT plus TEVAR and BMT groups. For patients treated with BMT plus TEVAR, the false lumen was considered thrombosed if no flow was visualised in the false lumen parallel to the endograft(s), excluding the distal 2 cm, whereas in the BMT group the false lumen was only considered thrombosed if there was no flow in any segment of the thoracic aorta, a difference that would appear to favour the TEVAR group<sup>26</sup>. In addition, many feel the surrogate composite end point does not yield clinically useful information on which to base treatment decisions, although it should be acknowledged that ADSORB was conceived as a feasibility study rather than the definitive answer to the question regarding best therapy for acute uncomplicated type B dissection<sup>27</sup>. Finally, given the small sample size and short duration of follow-up, the trial is not powered to detect differences in aortic-related and all-cause mortality, a study that would require >2000 subjects and several years of follow-up.

## Open Surgical Repair

Open surgical repair for type B dissection is currently reserved for patients in whom endovascular management is not feasible or has failed. The aim of open surgical repair is to replace the descending aorta with a graft, excising the intimal tear, restoring peripheral and visceral perfusion, and repairing or preventing aortic rupture.

Currently, there are no randomised controlled trials available to compare the different open surgical techniques and therefore the level of evidence regarding optimal treatment is low. Generally, the descending aorta is exposed through a left posterolateral thoracotomy. Left heart bypass can be established through the left atrium and femoral artery and has been widely used. Subsequently, the proximal entry tear is resected and a surgical graft is implanted to replace the dissected aorta.

In patients with retrograde arch involvement of the dissection, full cardiopulmonary bypass, using the femoral artery and vein, may be required. Hypothermic circulatory arrest has been adopted for cerebral protection in a subset of patients who are managed with open proximal graft anastomosis and may be accompanied by selective antegrade perfusion<sup>28-30</sup>. Surgical aortic fenestration or extra-anatomical bypass has been used for treating ischaemic complicated acute type B dissection, but with the introduction of minimal invasive techniques this procedure is only used as an alternative treatment in case of contraindications or failure of endovascular management<sup>20</sup>.



In patients presenting with complications such as imminent rupture, aortic expansion, or malperfusion syndromes, classic open surgery carries a significant risk of morbidity, including irreversible spinal injury and postoperative death. Although the results of open surgical repair of the descending aorta have improved over the last decades they remain unsatisfying, with in-hospital mortality for type B dissection patients of about 25–50%<sup>34, 46, 47</sup>.

The preoperative condition of the patient highly influences the outcome of surgical repair. Patients older than 70 years with hypotension and shock have less favourable outcomes, while those with a normal blood pressure at the time of surgery have better outcomes. Preoperative severe visceral malperfusion and spinal cord ischaemia are correlated with a poor prognosis after open surgery, and therefore may be spared such invasive therapy. In addition, extensive co-morbidity, such as end stage malignant disease and severe chronic obstructive pulmonary disease are considered contraindications for surgical aortic repair. Complications predominantly associated with the extent and duration of the operation include paraplegia, temporary paraparesis and stroke.

## Discussion

Multiple consensus statements recommend TEVAR as the treatment of choice for acute complicated type B aortic dissection. The US Food and Drug Administration approved the Gore® C-TAG® (WL Gore & Associates, Inc, AZ, USA) and Medtronic Valiant® (Medtronic Vascular, CA, USA) devices for the treatment of acute and chronic, complicated and uncomplicated dissections of the descending thoracic aorta, although the clinical trials leading to approval of each device included only acute, complicated (rupture or malperfusion) cases.

In the literature, direct comparison between TEVAR, open surgery, and medical therapy is invalidated by unbalanced populations (unmatched illness conditions and rates of complicated vs. uncomplicated cases of patients assigned to each treatment). This might produce an overly optimistic interpretation of the results, with an underestimation of mortality and complication rates in populations at lower risks (uncomplicated cases) usually assigned to medical therapy with respect to worse populations (more often complicated) treated by TEVAR and open surgery. Analysis of data from the Interdisciplinary Expert Consensus Document on Management of Type B Aortic Dissection summarised the pertinent results of TEVAR for acute type B aortic dissection in 2,359 patients. The early pooled mortality rate was 10.2% (95% CI: 9.0% to 11.6%). Pooled rates of early stroke and spinal cord ischaemia after treatment were 4.9% (95% CI: 4.0% to 6.0%) and 4.2% (95% CI: 3.3% to 5.2%), respectively. Survival rates ranged from 56.3% to 87% at 5 years. Freedom from aortic events ranged from 45% to 77% at 5 years.

Direct comparison of results between medical therapy and TEVAR for acute aortic dissection was available from a meta-analysis revealing that the early mortality rate was lower with medical therapy alone (odds ratio (OR): 0.50, 95% CI: 0.27 to 0.95), whereas the risk of early neurological complications (stroke and spinal cord ischaemia) was comparable between groups (OR: 0.55, 95% CI: 0.23 to 1.32)<sup>29</sup>. Other studies<sup>3, 48</sup>] are available for direct comparison of outcomes between TEVAR and open surgery for acute type B aortic dissection; one was a registry and the other was based on administrative codes that did not specify whether dissections were complicated or not<sup>37, 48</sup>. The pooled early mortality rate was significantly higher after open surgery (OR: 2.66, 95% CI: 1.37 to 5.17). There were no significant differences in rates of early stroke (OR: 0.90, 95% CI: 0.30 to 0.95) or spinal cord ischaemia (OR: 0.82, 95% CI: 0.50 to 1.33) after repair.

## Conclusion

Although the aetiology, pathophysiology, risk factors and clinical presentation for the diagnosis of acute type B aortic dissection are widely known, there is still ambiguity regarding the optimal management. The timing of intervention after dissection onset and complications is not widely understood. Patients assigned to medical treatment, TEVAR, or open surgery often significantly differ in baseline comorbidity illnesses and severity of the disease, making direct comparison among treatment strategies difficult. For complicated type B dissection, endovascular therapies are becoming the standard of care in many centres as they have been shown to have better outcomes compared to open repair.

## References

1. Hughes GC, Andersen ND, McCann RL. Management of acute type B aortic dissection. *J Thorac Cardiovasc Surg*, 145 [Suppl] 2013, pp. S202–S207.
2. Charilaou P, Ziganshin BA, Peterss S, et al. Current Experience With Acute Type B Aortic Dissection: Validity of the Complication-Specific Approach in the Present Era. *Ann Thorac Surg*. 2016 Mar;101(3):936-43.
3. Fattori R, Tsai TT, Myrmet T, et al. Complicated acute type B dissection: is surgery still the best option?: a report from the International Registry of Acute Aortic Dissection. *J Am Coll Cardiol Intv* 2008;1:395–402.
4. Tsai TT, Fattori R, Trimarchi S, et al. International Registry of Acute Aortic Dissection. Long-term survival in patients presenting with type B acute aortic dissection: insights from the International Registry of Acute Aortic Dissection. *Circulation* 2006;114:2226–31.
5. Dake MD, Thompson M, van Sambeek M, et al. DEFINE Investigators. DISSECT: a new mnemonic-based approach to the categorization of aortic dissection. *Eur J Vasc Endovasc Surg* 2013; 46:175–190.
6. Trimarchi S, Eagle KA, Nienaber CA, et al. International Registry of Acute Aortic Dissection [IRAD] Investigators. Importance of refractory pain and hypertension in acute type B aortic dissection: insights from the International Registry of Acute Aortic Dissection [IRAD]. *Circulation* 2010;122:1283–9.
7. Tsai TT, Evangelista A, Nienaber CA, et al. Partial thrombosis of the false lumen in patients with acute type B aortic dissection. *N Engl J Med* 2007; 357:349e59.
8. Jonker FH, Trimarchi S, Rampoldi V, et al. and the International Registry of Acute Aortic Dissection [IRAD] Investigators. Aortic expansion after acute type B aortic dissection. *Ann Thorac Surg* 2012; 94:1223–1229.
9. Qin YL, Deng G, Li TX, et al. Risk factors of incomplete thrombosis in the false lumen after endovascular treatment of extensive acute type B aortic dissection. *J Vasc Surg* 2012; 56:1232–1238.
10. Augoustides JG, Szeto WY, Woo EY, et al. The complications of uncomplicated acute Type-B dissection: the introduction of the Penn classification. *J Cardiothorac Vasc Anesth* 2012; 26:1139.
11. Weiss G, Wolner I, Folkmann S, et al. The location of the primary entry tear in acute type B aortic dissection affects early outcome. *Eur J Cardiothorac Surg* 2012; 42:571–576.
12. Desai ND, Gottret JP, Szeto WY, et al. Impact of timing on major complications after thoracic endovascular aortic repair for acute type B aortic dissection. *J Thorac Cardiovasc Surg*. 2015 Feb;149(2 Suppl):S151-6.
13. Ehrlich M, Grabenwoeger M, Cartes-Zumelzu F, et al. Endovascular stent graft repair for aneurysms on the descending thoracic aorta. *Ann Thorac Surg* 1998; 66:19–24.



14. Muhs BE, Vincken KL, van Prehn J, et al. Dynamic cine-CT angiography for the evaluation of the thoracic aorta; Insight in dynamic changes with implications for thoracic endograft treatment. *Eur J Vasc Endovasc Surg* 2006; 32: 532–536.
15. Van Prehn J, Bartels LW, Mestres G, et al. Dynamic aortic changes in patients with thoracic aortic aneurysms evaluated with electrocardiography-triggered computed tomographic angiography before and after thoracic endovascular aneurysm repair: Preliminary results. *Ann Vasc Surg* 2009; 23: 291–297.
16. Wheat MW Jr, Palmer RF, Bartley TD, et al. Treatment of dissecting aneurysms of the aorta without surgery. *J Thorac Cardiovasc Surg*. 1965 Sep;50:364-73
17. Nienaber CA, Eagle KA. Aortic dissection: new frontiers in diagnosis and management: Part I: from etiology to diagnostic strategies. *Circulation*. 2003; 108:628–635
18. Rimbau V, Zipfel B, Coppi G, et al. RELAY Endovascular Registry for Thoracic Disease RESTORE Investigators. Final operative and midterm results of the European experience in the RELAY Endovascular Registry for Thoracic Disease [RESTORE] study. *J Vasc Surg* 2011; 53: 565–573.
19. Neuhauser B, Czermak BV, Fish J, et al. Type A dissection following endovascular thoracic aortic stent-graft repair. *J Endovasc Ther* 2005; 12: 74–81.
20. Kpodonu J, Preventza O, Ramaiah VG, et al. Retrograde type A dissection after endovascular stenting of the descending thoracic aorta. Is the risk real? *Eur J Cardiothorac Surg* 2008; 33: 1014–1018.
21. Chemelli-Steingruber I, Chemelli A, Strasak A, et al. Endovascular repair or medical treatment of acute type B aortic dissection? A comparison. *Eur J Radiol* 2010; 73:175–180.
22. Pearce BJ, Passman MA, Patterson MA, et al. Early outcomes of thoracic endovascular stent-graft repair for acute complicated type B dissection using the Gore TAG endoprosthesis. *Ann Vasc Surg* 2008; 22: 742–749.
23. Shu C, He H, Li Q-M, et al. Endovascular repair of complicated acute Type-B aortic dissection with stent graft: Early and mid-term results. *Eur J Vasc Endovasc Surg* 2011; 42: 448–453.
24. Ruan Z-B, Zhu L, Yin Y-G, et al. Risk factors of early and late mortality after thoracic endovascular aortic repair for complicated Stanford B acute aortic dissection. *J Card Surg* 2014; 29: 501–506.
25. Brunkwall J, Lammer J, Verhoeven E, et al. ADSORB: A study on the efficacy of endovascular grafting in uncomplicated acute dissection of the descending aorta *Eur J Vasc Endovasc Surg* 2012;44:31–36.
26. Voûte MT, Gonçalves FB, Verhagen HJM. Commentary on “ADSORB: A study on the efficacy of endovascular grafting in uncomplicated acute dissection of the descending aorta.” *Eur J Vasc Endovasc Surg* 2012;44:37.
27. Hinchliffe RJ, Thompson MM. ADSORB: A prospective randomised study on the efficacy of endovascular grafting vs. best medical treatment in uncomplicated acute dissection of the descending aorta *Eur J Vasc Endovasc Surg* 2012;44:38–39.
28. Coselli JS, LeMaire SA, de Figueiredo LP, et al. Paraplegia after thoracoabdominal aortic aneurysm repair: Is dissection a risk factor? *Ann Thorac Surg* 1997; 63: 28–35.
29. Miller DC. Surgical management of acute aortic dissection: New data. *Semin Thorac Cardiovasc Surg* 1991; 3: 225–237.
30. Svensson LG, Crawford ES, Hess KR, et al. Dissection of the aorta and dissecting aortic aneurysms. Improving early and long-term surgical results. *Circulation* 1990; 82: IV24–38.
31. Fattori R, Cao P, De Rango P, et al. Interdisciplinary Expert Consensus Document on Management of Type B Aortic Dissection, *J Am Coll Cardiol*. 2013;61(16):1661-1678.

32. Czerny M, Funovics M, Sodeck G, et al. Long-term results of thoracic endovascular aortic repair in atherosclerotic aneurysms involving the descending aorta. *J Thorac Cardiovasc Surg* 2010; 140: S179–184.
33. Van Bogerijen GHW, Williams DM, Eliason JL, et al. Alternative access techniques with thoracic endovascular aortic repair, open iliac conduit versus endoconduit technique. *J Vasc Surg* 2014; 60: 1168–1176.
34. Estrera AL, Garami Z, Miller CC, et al. Cerebral monitoring with transcranial Doppler ultrasonography improves neurologic outcome during repairs of acute type A aortic dissection. *J Thorac Cardiovasc Surg* 2005; 129: 277–285.
35. Kwolek CJ, Watkins MT. “The INvestigation of STent Grafts in Aortic Dissection [INSTEAD] Trial, The Need for Ongoing Analysis.” *Circulation* 2009;120(25):2513-2514.
36. Nienaber CA, Rousseau H, Eggebrecht H, et al. Randomized comparison of strategies for type B aortic dissection: the INvestigation of STent Grafts in Aortic Dissection [INSTEAD] trial. *INSTEAD Trial. Circulation.* 2009 Dec 22;120[25]:2519-28.
37. Svensson LG, Kouchoukos NT, Miller DC, et al. Society of Thoracic Surgeons Endovascular Surgery Task Force. Expert consensus document on the treatment of descending thoracic aortic disease using endovascular stent-grafts. *Ann Thorac Surg.* 2008 Jan;85(1 Suppl):S1-41.
38. Andacheh ID, Donayre C, Othman F, et al. Patient outcomes and thoracic aortic volume and morphologic changes following thoracic endovascular aortic repair in patients with complicated chronic type B aortic dissection. *J Vasc Surg* 2012; 56: 644–650; discussion 650.
39. Mani K, Clough RE, Lyons OTA, et al. Predictors of outcome after endovascular repair for chronic type B dissection. *Eur J Vasc Endovasc Surg* 2012; 43: 386–391.
40. Dong ZH, Fu WG, Wang YQ, et al. Retrograde type A aortic dissection after endovascular stent graft placement for treatment of type B dissection. *Circulation* 2009; 119:735–741.
41. Hansen CJ, Bui H, Donayre CE, et al. Complications of endovascular repair of high-risk and emergent descending thoracic aortic aneurysms and dissections. *J Vasc Surg* 2004; 40: 228–234.
42. Van Herwaarden JA, Bartels LW, Muhs BE, et al. Dynamic Magnetic resonance angiography of the aneurysm neck: Conformational changes during the cardiac cycle with possible consequences for endograft sizing and future design. *J Vasc Surg* 2006; 44: 22–28.
43. Fang TD, Lippmann M, Kakazu C, et al. High-dose adenosine-induced asystole assisting accurate deployment of thoracic stent grafts in conscious patients. *Ann Vasc Surg* 2008; 22: 602–607.
44. Greenberg RK, O’Neill S, Walker E, et al. Endovascular repair of thoracic aortic lesions with the Zenith TX1 and TX2 thoracic grafts: Intermediate-term results. *J Vasc Surg* 2005; 41: 589–596.
45. Heijmen RH, Thompson MM, Fattori R, et al. Valiant thoracic stent-graft deployed with the new captivia delivery system: Procedural and 30-day results of the Valiant Captivia registry. *J Endovasc Ther* 2012; 19: 213–225.
46. Coselli JS, LeMaire SA, Conklin LD, et al. Left heart bypass during descending thoracic aortic aneurysm repair does not reduce the incidence of paraplegia. *Ann Thorac Surg* 2004; 77: 1298–1303.
47. Neri E, Massetti M, Barabesi L, et al. Extrathoracic cannulation of the left common carotid artery in thoracic aorta operations through a left thoracotomy: Preliminary experience in patients. *J Thorac Cardiovasc Surg* 2002; 123: 901–910.
48. Brunt ME, Egorova NN, Moskowitz AJ. Propensity score-matched analysis of open surgical and endovascular repair for type B aortic dissection. *Int J Vasc Med.*; 2011.

## Chapter 6

# Team Building and Subspecialisation in Aortic Surgery

*John Pepper*

---

*“Mater artium necessitas”*

## Introduction

Disease of the thoracic aorta is mostly indolent and is only discovered in the context of an emergency such as dissection or by serendipity during a radiological investigation for another disease. The aorta has been called the orphan organ and there are many claimants at the orphanage: cardiac surgeons, vascular surgeons, interventional cardiologists or radiologists. There is a strong argument to apply a team approach and to make this a truly patient-centric speciality. The impact of advanced imaging, CT and MRI in particular, has transformed the management of patients with aortic disease. By combining the diagnostic and interventional skills of individuals from different specialities who have a passion for this intriguing group of diseases we can provide timely and appropriate treatment for the patient.

## The size of the problem

### Aortic dissection

In a report from Sweden in 2007, Ollson and colleagues found that the prevalence and incidence of thoracic aortic disease was higher than previously reported and increasing year on year<sup>1</sup>. Thirty-day surgical mortality and long-term mortality have improved significantly to form a growing cohort of patients who require counselling, management decisions, operations, catheter-based interventions and extended post-operative surveillance. Between 1987 and 2002 in Sweden, 4425 cases of aortic dissection were identified within a population of about 8.7 million, which equates to 3.4 per 100,000 people per year. The annual incidence of aortic aneurysm and dissection combined increased by 50% in men and 30% in women during these 16 years. But this may be an under-estimate as hospital-based reports do not account for deaths before the patient is admitted. A prospective analysis of 30,412 middle-aged men and women with 20 years of follow-up reported 15 cases per 100,000 patient-years at risk for aortic dissection, with a 67.5% male predominance<sup>2</sup>. In those 65-74 years old, the incidence may be even higher at 35 cases per 100,000 patients per year<sup>3</sup>.

Women with aortic dissection are more likely to present at an older age than men and to have atypical symptoms, which often delays diagnosis, leading to a higher mortality. This finding remains true even after adjustment for age and hypertension and despite the higher incidence of aortic dissection in men than in women (16 cases per 100,000 men per year versus 8 cases per 100,000 women per year in those older than 50 years)<sup>4</sup>.

### Congenital abnormalities of the aortic root and aorta

Progressive aortic root dilatation occurs in a number of congenital heart defects both repaired and unrepaired and may often involve the ascending aorta as well. Inherited connective tissue disorders, such as Marfan syndrome and bicuspid aortic valve, have served as aortopathy models both in terms of pathogenesis and treatment. But similar aortic wall abnormalities have been reported in a wider range of disparate congenital heart defects, including coarctation of the aorta, Fallot's tetralogy and transposition of the great arteries. Aortic enlargement is usually clinically silent but may produce symptoms due to progressive aortic regurgitation or acute aortic dissection. Thus, early identification of aortopathy is important for appropriate follow-up and timely intervention. As the life expectancy of patients with congenital heart disease increases, several cardiovascular risk

factors may superimpose on the inherent aortic wall abnormalities and may increase the incidence of aortic complications.

An aortic unit should therefore seek close collaboration with adult congenital cardiac units so that these young patients are not lost to follow-up and receive timely advice. In addition, there is a need to screen families and to do this in an organised manner requires the skills of a clinical geneticist and access to a fully equipped clinical genetics and genomic laboratory.

## **Construction of a team**

The building of an effective aortic team to look after patients with diseases of the thoracic aorta requires a small group of tough-minded people with different skills who have a passion for this type of work. A hierarchical system may be effective initially but in the medium term does not work well. Progress is fuelled by a positive optimistic outlook with people empowered by praise and encouragement. What is required is a patient-centered approach both in word and deed. This is the essence of professionalism and can readily be achieved in an aortic unit.

Diseases affecting the thoracic aorta are often complex and the risks of surgery, both mortality and morbidity, are higher than other types of cardiac surgery, often in the 5-10% range for 30-day mortality. Given that many elective patients are asymptomatic this is a significant challenge. When considering elective surgery on the thoracic aorta it is wise to see the patient and their partner on two or three occasions, preferably with members of the team, such as nurses and physiotherapists to give them confidence and to ensure that they understand the risks involved particularly regarding complications.

A group of hospital consultants working together need to trust each other and provide a viable, authentic presence on the clinical front line. This means combined ward rounds, combined out-patient clinics and effective weekly multi-disciplinary team meetings (MDTs). These meetings need to be recorded and letters written in a timely manner to the referring consultants. Such a team needs to have a regular business meeting at least twice a month to ensure that a shared vision and strategy is followed. Transparency is vital and applies not just to results but to progress, aims and defects. Above all in this emerging speciality, there needs to be collaboration across boundaries.

One of the most positive and exciting impacts of the trans-catheter valve trials and which has become the new standard in clinical practice is the development of the Heart Team. Cardiologists, both non-invasive and interventional, radiologists and cardiac surgeons evaluate all high-risk patients as an integrated team in a joint clinic setting and make a single joint recommendation after considering the individual needs of the patient. This is a very patient-centered approach and contrasts with the previous era of an adversarial approach between cardiologist and surgeon in the management of patients with coronary artery disease. This new model has led to improved dynamics and co-operation between the different healthcare professionals. The collaboration between cardiac and vascular surgeons in an aortic unit is a further vital and important step. Vascular surgeons bring a wealth of experience of dealing with the thoraco-abdominal aorta and they have become adept at wire-based treatments such as TEVAR. Until recently, some 70% of a vascular surgeon's work was of an emergency nature but the creation of aortic units enables them to extend their expertise into the aortic arch and ascending aorta. Cardiac surgeons bring a detailed knowledge and familiarity of extracorporeal circulation (ECC) either in the form of

total cardiopulmonary bypass or left heart bypass. Familiarity with the side effects of ECC, especially the pulmonary and coagulation systems is a crucial part of the total care package. Adversarial positions between vascular and cardiac surgery which were prevalent 10 to 15 years ago, especially in North America, are giving way to a more intelligent approach in which it is realised that the different specialities bring essential skills to the aid of the patient and by working together with mutual trust the final product is greater than the sum of its parts.

Within the surgical team there are a number of vital partners who need to work together in such a way that there is mutual respect for different skills. Anaesthetists who are dedicated to this type of work are the linchpin of successful, lengthy operations on the thoracic or thoraco-abdominal aorta. Their ability to foresee problems and anticipate a crisis allowing effective preventive action to be taken is critical to the success of the procedure. While the surgeons are concentrating on a technical problem in the aorta, the anaesthetist can influence behaviour in a very positive way in the rest of the operating room. Central to the success of these procedures is a small group of experienced perfusionists who are very familiar with left heart bypass but also sufficiently flexible to alter perfusion arrangements when unexpected problems arise. Likewise, it is very helpful to have a small team of theatre nurses for scrubbing in and running who are familiar with these procedures, understand the difficulties which may be encountered and are keen to train junior nurses to enable the programme to run on over many years.

Once in the ICU, very close monitoring of the patients is required and a close professional relationship between intensivist and surgical team is essential. These patients can be very demanding, unlike routine elective cardiac surgery, and a well-thought-out approach which retains flexibility is the key to a successful outcome. Again, a high level of mutual respect between surgeons, intensivists and ICU nurses is vital to enable a complex patient to come through well without serious complications. Of course, death and complications will sometimes occur but the subsequent mortality and morbidity discussions need to be handled professionally so that discussions can centre not on a blame basis but as an opportunity for learning by everyone.

Cardiologists and dedicated radiologists bring essential skills in diagnosis and treatment. They provide special expertise in cardiac CT scanning, magnetic resonance angiography and PET scanning. The direction of travel is towards more wire-based treatment and here the skills of the specialist cardiologist or radiologist with a “photographer’s eye” are paramount.

In any aortic unit, there is a need to establish a connective tissue disease clinic to screen and monitor patients with the Marfan syndrome and related disorders. This should occur in collaboration with an adult congenital heart unit so that these patients have easy access to the different sub-specialities.

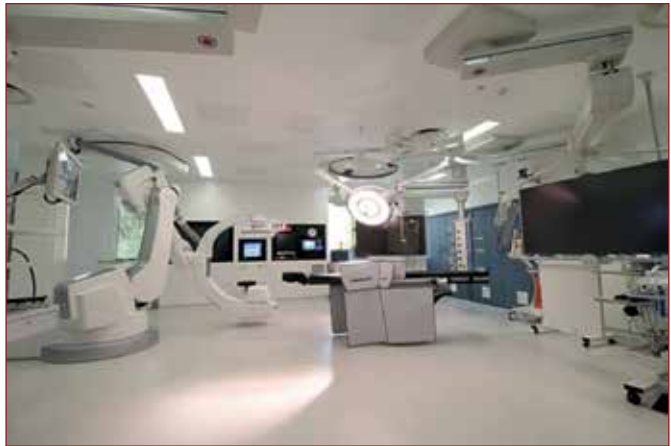## **Equipment**

It is generally agreed that a hybrid operating theatre with the capacity to produce state-of-the-art images is a pre-requisite for the management of complex aortic problems (Figure 1).

Increasingly, the options for endovascular stenting or conventional surgery or a combination of both are discussed at the MDT. The goal is to provide a treatment plan that is effective but results in the least biological insult to the patient. It is helpful to create a small core of anaesthetists who can agree on protocols and have a genuine interest in this kind of work. Thoraco-abdominal aortic surgery is a major undertaking. While the frequency of these



operations is falling in many aortic units in favour of TEVAR, there remains a small group of patients who are unsuitable for TEVAR but for whom there is a clear indication for this type of intervention. The measurement and monitoring of somato-motor and somato-sensory potentials are a prerequisite for these procedures to prevent damage to the spinal cord. A neurophysiology technician is necessary to undertake this intensive form of monitoring and to maintain the necessary equipment. Although primarily used for thoraco-abdominal procedures, somato-motor potentials are also very helpful for complex aortic arch reconstruction and TEVAR procedures to the descending thoracic aorta.



*Figure 1: A hybrid operating theatre at Royal Brompton Hospital 2015.*

The recent improvements in diagnostic imaging will enable increasingly rapid and accurate detection of acute aortic conditions. Current precision imaging may enable us to understand the underlying pathological processes beyond just the diameter in acute dissection, including early intramural haematoma, more subtle forms of aortic wall disease and patients who are at risk of developing an acute aortic dissection. For instance, phase-contrast sequences and velocity maps acquired in 4D might enable haemodynamic assessment of flow patterns and derive aortic wall stress parameters, providing information that reaches beyond anatomical assessment for the extent of dissection and aortic diameter<sup>5,6</sup>. Another type of functional imaging that may be useful in aortic dissection is positron emission tomography (PET) which can depict the distribution of injected <sup>18</sup>F-fluorodeoxyglucose along the entire aorta and identify areas of enhanced metabolic activity, usually from accumulated inflammatory cells or invading macrophages in areas of acute injury. PET in conjunction with anatomical imaging using CT or MRI is already being used to identify areas of tissue inflammation. These approaches may be instrumental in judging the risk of rupture and the need for preventive treatment in chronic dissection<sup>6,7</sup>.

In open surgery and endovascular procedures of the dissected aorta and in elective procedures on the thoracic aorta, the dreaded complication is paraplegia due to spinal cord injury (SCI). The reported risk for thoraco-abdominal repair is 5-20% for open, 0-30% for hybrid open-endovascular and 9-16% for endovascular procedures<sup>8,9</sup>. The mechanism of nerve injury is reduction of spinal cord perfusion pressure and hypoxia from impaired collateral supply to spinal arteries fed from the vertebral, internal mammary, intercostal, lumbar and hypogastric arteries. Replacement with a graft or coverage with an endovascular stent graft can compromise collateral perfusion. Monitoring of spinal cord function can be achieved by using somato-sensory or somato-motor evoked potentials that assess neuronal function in the ventral grey matter and the sensory dorsal horn. Attenuation of signals implies critically reduced perfusion, with ischaemic neurons ceasing to function. These defects are reversible with increased blood flow. As perfusion pressure is directly related to arterial pressure and inversely related to cerebrospinal fluid pressure<sup>10</sup>, cerebrospinal

fluid drainage, permissive hypertension and re-implantation of intercostal arteries can reduce or abolish SCI. Furthermore, neuronal metabolic demand can be reduced with local or systemic hypothermia. Development of SCI remains a risk after intervention, and continuation of spinal cord protection is important for 48-72 hours while the collateral network is recruited. New strategies for SCI prevention, such as staged repair and preconditioning, rely on this time-dependent collateral recruitment<sup>11</sup>.

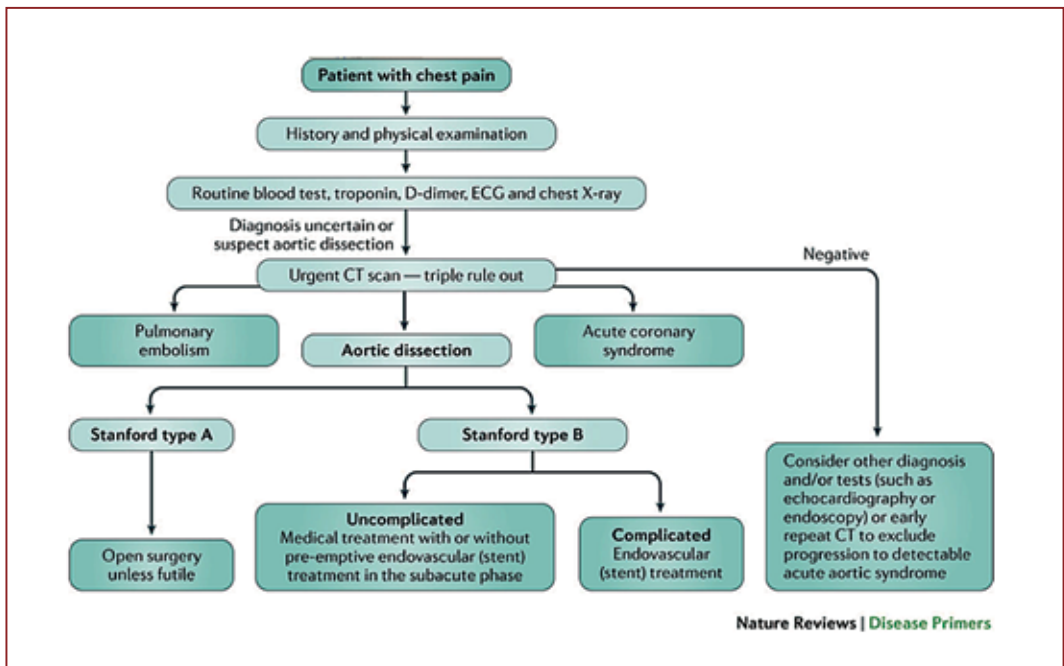
An essential component of an aortic unit is an appropriately trained technician who can set up and monitor these nerve signals. It is no exaggeration to state that from the hospital governance point of view interventions on the thoraco-abdominal aorta should not be undertaken without this monitoring being in place and a competent technician to use it.

## Emergency procedures

The acute aortic syndrome which includes dissection, intra-mural haematoma (IMH) and penetrating aortic ulcer (PAU) remains a logistic challenge. The goal is to reduce the time from the onset of symptoms to diagnosis and to the onset of definitive treatment. While the mean time is around 12 hours from onset of symptoms to definitive diagnosis in the UK, a system whereby an individual in an accident and emergency department can establish contact with the on-call aortic surgeon can be effective as measured by a reduction in 30-day mortality. In Liverpool and in the North West Thames region of London such an arrangement has resulted in a reduction of the 30-day mortality from a national average of 25% to a range of 12 to 16%. Decision making in patients with the acute aortic syndrome can be difficult and requires the combined skills of radiologists, surgeons and interventional cardiologists. Precise ECG-gated CT scans to avoid confusion with motion artefact can provide a direct route to diagnosis but with growing experience more subtle signs of impending mesenteric ischaemia can also be detected. In patients with IMH or PAU, serial observation of CT scans over a period of days can be instrumental in deciding when intervention is required in order to anticipate and prevent a full-blown aortic dissection.

Acute aortic dissection and other types of acute aortic syndrome are best managed in aortic centres by experienced teams. Most patients can be transported safely provided they are not in cardiogenic shock and both pain and blood pressure are well controlled. An algorithm for aortic dissection is shown in Figure 2.

Until recently the management of ascending aortic dissection, Stanford Type A was surgical and that for Type B, descending was medical unless complications occurred. The management of Type B is changing thanks to the development of endovascular repair of the thoracic aorta, known as thoracic endovascular aneurysm repair or TEVAR. The core principle underlying this treatment is to place a covered stent over the entry tear in the descending aorta. The deployment of the stent drives changes in the haemodynamics of the dissected aorta resulting in a reduction in pressure within the false lumen and rapid expansion of the true lumen. Patients with malperfusion, tears that are large but with a single entry point into the aortic wall, repetitive symptoms, or refractory hypertension are especially likely to develop complications of acute dissection and therefore benefit from endovascular treatment<sup>12</sup>. Expansion of the true lumen will correct dynamic malperfusion of the viscera and lower limbs, whereas false lumen collapse and thrombosis will prevent bleeding from rupture of the false lumen. The endovascular approach may induce re-approximation and remodelling of the dissected segment and remove the need for open surgery at a later stage.



*Figure 2: An algorithm for the management of acute aortic dissection*

## Research and development

Much of the research undertaken on the thoracic aorta has been of a technical nature to reduce the mortality and the morbidity of surgical procedures on patients who in the elective setting are often asymptomatic. Thus, much effort has been expended on protection of the brain and spinal cord, on the development of alternative surgical approaches such as de-branching of the head vessels and on new procedures in endovascular aortic interventions. These developments which have arisen from experimental work on large mammals have proved to be very effective but so far, they have not been tested in a randomised controlled trial. It is focused aortic teams who will take forward the leading edge of endovascular treatment into the ascending aorta, using branched devices in the arch and the visceral segment, protecting the spinal cord.

Research of a translational nature has been less common but there is a growing interest in the role of inflammation as a trigger for aneurysm enlargement in the thoracic aorta. Much effort continues to be expended on the genetic and genomic mechanisms underlying inherited disease of the aortic valve, aortic root and ascending aorta but this is yet to have a major impact in clinical decision making. Next generation sequencing with “aortic panels” are in use in specialist centres. These panels allow for genetic scrolling of the entire spectrum of aortic defects in one test.

A new area of interest is developing in adult congenital heart disease and in particular in those adults who in infancy underwent radical repair or “total correction” of cono-truncal abnormalities. At the forefront of these problems are patients who having undergone the arterial switch operation for transposition of the great vessels now present more than 20 years later with an enlarging ascending aorta. The natural history of this condition is

unknown and will depend on careful follow-up with MRI scans over the next 20 years. Although there has been a flurry of exponential research in the field of Marfan syndrome, related disorders and bicuspid aortic valve disease, there is a paucity of data in terms of genetic screening and the development of new medical treatments. Despite the success in defining FBN-1 mutations in Marfan there is no clear genotype-phenotype correlation. Our understanding of the molecular mechanisms within the extracellular matrix of the aortic wall remains incomplete, thus beta-blockers continue to be the mainstay of drug therapy. The role of angiotensin receptor blockers remains unclear despite several recent randomised controlled trials in which the effect on enlargement of the ascending aorta and aortic root in comparison to standard care was neutral. But molecular imaging of aortic aneurysms holds a promising future and can capture key cellular events in early aortic disease such as increased MMP activity<sup>13</sup>.

The interplay between a clinical aortic unit and the academic discipline of Vascular Biology is crucial for the future development of both. There are three facets of vascular function which have dominated research since the seminal discovery of endothelium-derived nitric oxide by Furchgott and Zawadzki in 1980<sup>14</sup>. These are vasomotor tone, inflammation and the balance between thrombosis and thrombolysis. Of these, inflammation is of particular interest to those of us caring for patients with aortic disease. Why is it that in this indolent condition the diseased aorta may lie dormant for long periods of time and then begin to enlarge and eventually produce symptoms? Latent inflammatory processes combined with extracellular matrix degradation may be part of the explanation. New and emerging technologies are continuing to reveal that the microbiome plays a critical role in the maintenance of vascular health and the development of vascular disease. The diversity of the human microbiome between individuals, in both species and pattern of colonisation may underlie the different phenotypic expression of vascular disease and ultimately establish a new paradigm in personalised medicine.

The relationship between humans and microbes reflects a two-way interaction in which it appears that both have co-evolved to their mutual benefit. An example of this is the finding that vitamins essential for human health such as vitamin K and some B vitamins are the products of microbial metabolism in the gut<sup>15</sup>. To understand the mechanisms by which the microbiome regulates vascular function, metabolomic profiling has been used to identify specific bacteria-derived molecules related to energy metabolism and vascular homeostasis. Experiments have identified trimethylamine as the gut metabolite and bacteria-derived chemical with the clearest association with cardiovascular disease<sup>16</sup>. In clinical studies, unbiased metabolic profiling further revealed a significant increase in the levels of trimethylamine –N-oxide (TMAO) and related molecules in plasma samples from patients with increased risk for cardiovascular disease compared with matched control subjects<sup>17</sup>. TMAO is formed by bacterial metabolism of choline and phosphatidylcholine in the gut to produce trimethylamine which is oxidised in the liver by the enzyme flavin mono-oxygenase-3 to form TMAO<sup>16</sup>.

Studies in patients, cultured cells and animal models have converged on a comprehensive view of TMAO as a critical molecule associated with atherosclerosis, myocardial infarction, stroke, insulin resistance and chronic kidney disease. TMAO has become the target of several therapeutic interventions, ranging from schemes to reduce the dietary intake of trimethylamine precursors to manipulations of the gut microbiome to reduce trimethylamine synthesis. The demonstration that atherosclerosis susceptibility could be transmitted from an atherosclerosis-prone strain of mice to another strain typically

resistant to atherosclerosis simply by the transplantation of gut microbes, an effect that was closely related to TMAO levels, provided additional evidence to support the role of the gut microbiome in regulating atherosclerosis<sup>18</sup>.

## Training and education

Aortic intervention, because of its multidisciplinary nature and the range of subspecialties which are involved, can be a career goal for individuals from a wide range of disciplines. The most likely entry points are from cardiac surgery and vascular surgery but increasingly we need talented individuals from interventional cardiology and radiology. In addition, we need non-interventional cardiologists to look after the growing population of young people with aortopathy.

While many areas of conventional cardiac surgery are contracting, the aorta is an example along with adult congenital heart disease, of an expanding sub-speciality. In an increasingly risk-averse environment there is a need for formally trained aortic surgeons. There is much we need to understand about the pathophysiology of aortic diseases. In an ageing population, aortic problems are becoming more prevalent and at the other end of the age spectrum the increased lifespan of patients with congenital heart disease will increase and fill the out-patient clinics.

We should now be able to offer two years of peri-CCT (certificate of completion of training) training in an aortic unit to surgeons and interventional cardiologists. During this period, they have the opportunity to learn the pathophysiology of the diseases and the methods of diagnosis. The impact of imaging has been immense and time spent in an experienced aortic unit gives the chance to understand CT and MRI scans in depth. Each patient study contains a wealth of information, only a part of which can be included in the “report”. The ability to sit with an experienced radiologist and learn how to “read” one of these scans is arguably the most valuable part of a training programme.

By the end of a two-year attachment, surgeons should be able to safely undertake elective ascending aorta and arch operations and operate on acute aortic dissection. It is to be hoped that young surgeons will grab the opportunity to be skilled at wire-based procedures such as TEVAR, but the likelihood is that young interventional cardiologists, excited by the possibilities in the management of disease of the thoracic aorta, will come to take the lion’s share of wire-based stenting of the aortic arch and descending aorta. They will need to learn how to use a hybrid operating room efficiently and to its full advantage.

Operations on the thoracic aorta are only successful if there is a sincere, committed team approach. What is required is a small group of dedicated anaesthetists who work closely with the surgeons, both cardiac and vascular. The additional complexities of aortic surgery from the anaesthetic viewpoint include protection of the brain and spinal cord, an ability to deal with large shifts of volume within the circulation in a prolonged general anaesthetic. These patients need to be monitored very closely indeed on the ICU, where the need for CSF drainage may become critical.

The management of aortic disease is changing rapidly so it is vital that the leaders of any unit keep themselves up to date. New techniques may need to be learned or pioneered. International, professional friendships are vital as it may become necessary to arrange proctoring when new procedures are adopted.



A genuine commitment to training of young surgeons and cardiologists in aortic interventions is a vital and very worthwhile task. We need to produce a cadre of enthusiastic, skilled individuals who will continue to advance our understanding of these diseases and to improve the treatments we offer. Within the aortic team there needs to be a culture of inquiry and openness. A culture of innovation should be developed which is idea-friendly and where new ideas are valued and welcomed. With growing confidence over time a successful aortic team will go further and be idea-hungry and seek for radical improvement beyond the existing limits.

## Conclusion

Operations for diseases of the aorta, once considered to be too high risk for many surgeons, are now a part of the daily routine. We have learned something about the nature of the aorta, how to analyse the images and how to correct the defects. While major surgery of the thoraco-abdominal aorta is likely to decline, TEVAR is in the ascendancy. Although the early results are encouraging and the morbidity significantly less than for open surgery, the long-term results remain uncertain. Whether the future will lie in hybrid procedures or be dominated by a stent-based approach is uncertain. What is certain is that this area of activity will continue to fascinate and challenge all those who choose to tread this path.

## References

1. Olsson C, Thelin S, Stahle E, et al. Thoracic aortic aneurysm and dissection: increasing prevalence and improved outcomes reported in a nationwide population-based study of more than 14,000 cases from 1987 to 2002. *Circulation* 2006; 114: 2611-2618.
2. Landenhed M, Engstrom G, Gottsater A, et al. Risk profiles for aortic dissection and ruptured or surgically treated aneurysms: a prospective cohort study. *J Am Heart Assoc.* 2015; 4:e001513.
3. Howard DPJ, Banerjee A, Fairhead JF, et al. Population-based study of incidence and outcome of acute aortic dissection and premorbid risk factor control: 10-year results from the Oxford Vascular Study. *Circulation* 2013; 127: 2031-2037.
4. Nienaber C, Fattori R, Mehta RH, et al; on Behalf of the International Registry of Acute Aortic Dissection. Gender related differences in acute aortic dissection. *Circulation* 2004; 109: 3014-3021.
5. Clough RE, Waltham M, Giese D, et al. A new imaging method for assessment of aortic dissection using four-dimensional phase-contrast magnetic resonance imaging. *J.Vasc. Surg.* 2012; 55: 914-923.
6. Sakalihasan N, Nienaber CA, Hustinx R, et al. Vascular metabolic imaging and peripheral plasma biomarkers in the evolution of chronic aortic dissections. *Eur Heart J Cardiovasc Imaging* 2015; 16: 626-633.
7. Hertault A, Maurel B, Pontana F, et al. Benefits of completion 3D angiography associated with contrast enhanced ultrasound to assess technical success after EVAR. *Eur J Vasc Endovasc Surg* 2015; 49: 541-548.
8. Drinkwater SL, Goebells A, Haydar A, et al. The incidence of spinal cord ischaemia following thoracic and thoraco-abdominal aortic endovascular intervention. *Eur J Vasc Endovasc Surg.* 2010; 40: 729-735.
9. Bisdas T, Pannucio G, Sugimoto M, et al. Risk factors for spinal cord ischaemia after endovascular repair of thoraco-abdominal aortic aneurysms. *J Vasc Surg.* 2015; 61: 1408-1416.



10. Verhoeven ELG, Katsargyris A, Bekkema F, et al. Editor's choice: ten year experience with endovascular repair of thoraco-abdominal aneurysms; results from 166 consecutive patients. *Eur J Vasc Cardiovasc Surg.* 2015; 49: 524-531.
11. Augoustides JG, Stone ME, Drenger B. Novel approaches to spinal cord protection during thoraco-abdominal aortic interventions. *Curr Opin Anaesthesiol.* 2014; 27: 98-105.
12. Nienaber CN, Clough RE. Management of acute aortic dissection. *Lancet* 2015; 385: 800-811.
13. Buxton DB. Molecular imaging of aortic aneurysms. *Circulation Cardiovasc Imaging* 2012; 5: 392-399.
14. Furchgott RF, Zawadzki JV. The obligatory role of endothelial cells in the relaxation of arterial smooth muscle by acetylcholine. *Nature* 1980; 288: 373-376.
15. Said HM. Intestinal absorption of water-soluble vitamins in health and disease. *Biochem J.* 2011; 437: 357-372.
16. Tang WH, Hazen SL. The contributory role of gut microbiota in cardiovascular disease. *J Clin Invest.* 2014; 124: 4204-4211.
17. Wang Z, Klipfell E, Bennett BJ, et al. Gut flora metabolism of phosphatidylcholine promotes cardiovascular disease. *Nature* 2011; 472: 57-63.
18. Gregory JC, Buffa JA, Org E, et al. Transmission of atherosclerosis susceptibility with gut microbial transplantation. *J Biol Chem.* 2015; 290: 5647-5660.
19. Nienaber CA, Clough RE, Sakalihasan N, et al. Aortic Dissection. *Nature Reviews Disease Primers* 2016; 2: 1-17.



## Chapter 7

# Blood Conservation and Transfusion in Aortic Surgery

*Seema Agarwal*

---

*“Sapiens qui prospicit”*

## The coagulopathy with aortic surgery

Cardiac surgery, in particular aortic surgery, can be associated with a profound coagulopathy and massive transfusion requirement<sup>1</sup>. Whilst there is no substitute for a meticulous surgical technique there are numerous other factors which contribute to the bleeding tendency. In common with most cardiac surgery, aortic surgery necessitates the use of cardiopulmonary bypass (CPB), either full or partial left heart. It is well known that the extracorporeal circulation can contribute to the development of an extensive coagulopathy. Blood contact with the surfaces of the bypass machine leads to platelet dysfunction, thrombin activation within the bypass circuit and disruption of coagulation factor function (Table 1). Platelet dysfunction arises secondary to mechanical destruction in the bypass circuit, haemodilution and activation due to contact of blood with artificial surfaces. There is loss of Von Willebrand and GPIIb/IIIa receptors and widespread degranulation.

Deep hypothermia is widely used as a cerebral protection technique during periods of circulatory arrest (DHCA). The temperature to which the patient is cooled remains variable with a recent trend in larger centres to the use of moderate hypothermia (22-25°C) rather than the usual 15-18°C if possible. The use of deep hypothermia leads to alterations in both the platelets and coagulation factors. As the patient is cooled there is a prolongation of the prothrombin and activated partial thromboplastin times due to the inhibition of the enzyme functions of the coagulation cascade which function optimally at 37°C. There is also hyperfibrinolysis due in part to the abnormal expression of tissue plasminogen activator, activation of fibrinolysis and platelet aggregation<sup>2</sup>. During hypothermia, there is sequestration of platelets in the liver and a reduction in platelet aggregation; although these return to normal with a return to normothermia, this may not occur for up to 24 hours after surgery. The use of heparin for systemic anticoagulation further contributes to the coagulopathy.

*Table 1: Key issues causing coagulopathy*

Interaction with artificial surface leading to platelet destruction and dysfunction, activation of coagulation and thrombin deposition
Hypothermia leading to disrupted physiology and hyperfibrinolysis

In comparison, left heart bypass does not cause as many iatrogenic problems. There remain issues with the use of an extracorporeal surface and activation of coagulation factors but there is less platelet destruction due to the lack of an oxygenator. In general, normothermia is maintained and lower levels of heparinisation are required (aiming for an ACT of 300secs rather than 480secs).

There are also patient-specific issues usually found with this type of pathology which include a generalised activation of coagulation pre-operatively shown by high levels of antithrombin, thrombin-antithrombin complexes and plasmin-antiplasmin complexes<sup>3</sup>. Peri-operatively there may be major blood loss and a resultant dilutional coagulopathy with a significant reduction in fibrinogen first, followed by a reduction in all factors and an elevation in D-dimers. If there is intestinal ischaemia, this may precipitate a Disseminated Intravascular Coagulation (DIC) with high tissue plasminogen activator and high levels of fibrinogen degradation products<sup>2</sup>.

Predictors of massive haemorrhage in this situation include pre-operative haemoglobin, CPB and DHCA times, emergent and reoperative status<sup>4</sup>. In our institution, a patient undergoing thoracic aortic surgery requiring DHCA requires on average 4 units of red cell concentrate (RCC), 4 units of fresh frozen plasma (FFP), 3 pools of platelets and 2 units of cryoprecipitate. This is a fairly typical transfusion requirement for patients undergoing aortic surgery associated with DHCA. Welsby and colleagues reported on 168 patients undergoing procedures requiring DHCA who required a median of 3 units of RCC, 3 pools of platelets and 6 units of FFP with a total median of 13 units transfused per patient<sup>4</sup>; similar numbers have been published by others<sup>5</sup>.

*Table 2: Blood conservation methods*

<b>Pre operative</b>
anaemia management
autologous predonation
<b>Intra operative</b>
antifibrinolysis
acute normovolaemic haemodilution
point of care testing
factor concentrates
cell salvage
<b>Post operative</b>
restrictive transfusion
peri operative iron

Attempts to limit the transfusion requirement must start prior to surgery and ideally should follow the principles of patient blood management, focussing on the three pillars of preoptimisation by optimising the patient's own blood volume and red cell mass, reducing peri-operative blood loss and optimising the patient-specific tolerance of anaemia (including the use of restrictive transfusion thresholds) (Table 2).

## Pre-operative Measures

### *Anaemia Management*

Firstly, it is desirable that the patient starts with a normal haemoglobin level. A survey performed by the UK Association of CardioThoracic Anaesthetists (ACTA) found that 31% of patients presenting for cardiac surgery had pre-operative anaemia<sup>6</sup>. These patients had an increased risk of requiring blood transfusion peri-operatively and a higher risk of mortality; pre-operative anaemia was an independent predictor of both morbidity and mortality. The causes of the anaemia may be dietary (B12, folate or iron deficiency) which should be identified and treated prior to surgery. Oral iron may be used but it is generally poorly tolerated and will take 4-6 weeks to be effective. Intravenous iron will work within 2-3 weeks to raise the haemoglobin level with newer formulations having low immunogenicity and often can be given as a single dose.

A proportion of patients will have a functional iron deficiency (previously called anaemia of chronic disease or iron-restricted anaemia) whereby there is malfunction of the hepcidin-ferroportin axis. Ferroportin is the only cellular iron exporter, it is expressed on reticulo-endothelial macrophages, hepatocytes, duodenal and placental cells. Hepcidin is an iron regulatory hormone which causes a decrease in serum iron by binding to ferroportin and internalising it thereby preventing iron absorption. In normal physiology when iron stores are low, hepcidin production is suppressed allowing ferroportin to function; when iron stores are high, hepcidin is produced to prevent further iron absorption. Hepcidin is also an acute phase protein which is increased in inflammatory conditions. It is thought

that in chronic cardiovascular disease there is generalised inflammation, a high level of hepcidin and a functional iron deficiency whereby dietary iron cannot be absorbed. It may be possible to treat these patients with iron infusions and studies are currently underway to ascertain its effectiveness although this may be limited by the high hepcidin levels.

## Autologous Predonation

Autologous predonation involves the patient giving their blood to be stored for their use perioperatively. It has been used successfully in numerous centres. Svensson, discussing a number of advances in aortic arch surgery at the Cleveland Clinic, described a method whereby patients donated one unit of red cells and fresh frozen plasma per week for up to four weeks prior to surgery<sup>7</sup>. Additionally, platelets were donated three to six days prior to surgery and platelet rich plasma was obtained after the induction of anaesthesia. The centre reported a reduction in transfusion of allogeneic blood and blood products in the patients who donated pre-operatively, with an associated reduction in post-operative intubation time and ICU length of stay.

## Intraoperative Measures

### 1 Anti-fibrinolysis

Fibrin production is essential to provide a haemostatic seal during repair of an injured vessel, and in normal physiology is balanced by the fibrinolytic pathway to prevent excessive fibrin production and occlusion of vessels (Figure 1). Plasminogen activators (tissue plasminogen activator and urokinase) control fibrinolysis, but during major surgery, this regulation may become disrupted resulting in hyperfibrinolysis and the resultant breakdown of any clot which is formed. This can be prevented by using anti-fibrinolytic medications. Tranexamic acid (TXA) and aminocaproic acid are lysine analogues that bind to the lysine-binding site on plasminogen to limit its activation and effects. Various dosing regimens for TXA exist ranging from a bolus of 5 to 10mg/kg followed by an infusion of 1 to 5mg/kg/hr.

Aprotinin is a non-specific serine protease inhibitor utilised for its anti-fibrinolytic and anti-inflammatory effects<sup>8,9</sup>. There are numerous dosing regimes, as listed below:

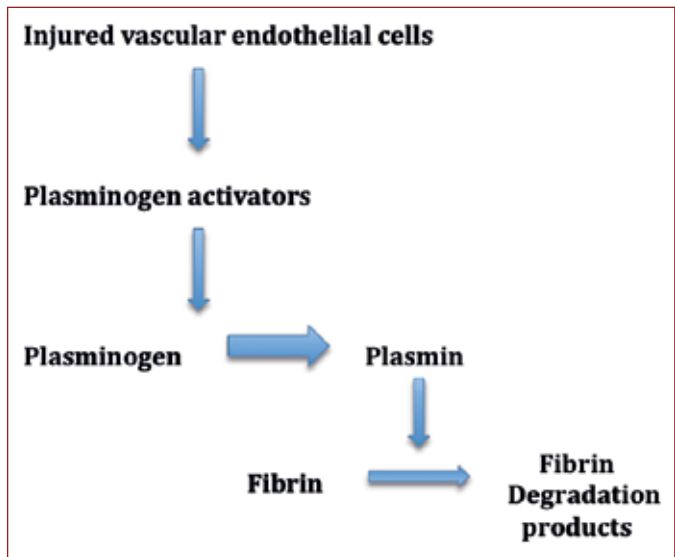
- *high dose (full Hammersmith)* – 280mg IV bolus (2 x 106 KIU) before sternotomy, then 70mg/hr IV infusion (5 x 105 KIU/hr) plus 280mg (2 x 106 KIU) added to CPB pump prime.
- *low dose (half Hammersmith)* – 140mg IV bolus (1 x 106 KIU) before sternotomy, then 35mg/hr IV infusion (2.5 x 105 KIU/hr) plus 140mg (1 x 106 KIU) added to CPB pump prime.
- *pump prime only* – 280mg (2 x 106 KIU) added to CPB pump prime

There have been concerns about the safety of aprotinin after the publication of a number of studies which showed an increase in renal failure and cardiovascular events<sup>10,11</sup>. This concern was amplified in those patients having surgery requiring DHCA who are already at an increased risk of renal failure in the perioperative period. However, there is a well proven decrease in bleeding in cardiac surgery with the use of aprotinin as compared with other antifibrinolytics<sup>12</sup>. However, these concerns have been mostly dismissed due to concerns with the handling of the data. Mangano and colleagues looking specifically at those having DHCA and found that the administration of aprotinin did not increase the risk of renal dysfunction<sup>13</sup>. Sniecinski et al. demonstrated that patients receiving TXA compared to



those receiving aprotinin (prior to its withdrawal) reported a significantly higher requirement for transfusion of platelets, fresh frozen plasma and cryoprecipitate<sup>14</sup>. More patients also developed a severe coagulopathy requiring treatment with recombinant factor VII. Additionally, analyses of patients receiving aprotinin for aortic surgery have shown reduced platelet transfusion requirements and suggested a trend towards a reduction in ventilation time, respiratory complications and arrhythmias<sup>15</sup> with a slight increase in the incidence of mild renal dysfunction<sup>9</sup>. It should be

noted that aprotinin has been shown to artificially prolong activated clotting times (ACT) when activation with celite is used, leading to potential under-anticoagulation during cardiopulmonary bypass. To cope with this, ACT targets should be kept at levels exceeding 500 seconds when celite is used<sup>16</sup> or testing should be performed using a kaolin activator<sup>17</sup>.



*Figure 1: The fibrinolytic pathway*

## 2 Acute Normovolaemic Haemodilution

Acute normovolaemic haemodilution (ANH) involves the removal of blood from a patient either immediately before or on induction of anaesthesia with the simultaneous replacement of plasma substitute to maintain normovolaemia. There are 2 main concepts behind this – firstly, that a haemodiluted patient will lose fewer red cells per millilitre of blood lost and, secondly, that the reinfused blood will prevent or limit exposure to allogeneic blood. When compared with other blood conservation techniques, ANH has some clear advantages – it is inexpensive and easily available, it reduces patient exposure to allogeneic blood (thus reducing exposure to blood antigens and blood borne pathogens), and it provides autologous blood for transfusion on completion of haemostasis. It may also improve tissue oxygenation by reducing blood viscosity. There are however numerous concerns, not least that it is not efficacious in preventing allogeneic transfusion and puts patients with cardiac disease at risk.

Tolerance to ANH in the general population is dependent on the maintenance of tissue oxygenation. This in turn is a result of an increase in cardiac output (in part due to improved blood fluidity, in part due to increased sympathetic drive) and an increase in oxygen extraction. In patients with coronary artery disease (which often accompanies aortic disease) there is a reduction in coronary reserve as the coronary blood flow cannot be increased and so the myocardial oxygen supply is limited. Significant aortic stenosis is often considered a contraindication to ANH as there is decreased coronary vascular reserve, a hypertrophied myocardium and a limited ability to compensate by increasing stroke volume through a restricted valve. Other contradictions include anaemia (Hb <90g/l), impaired renal function, sepsis, coagulation abnormalities and significant pulmonary disease.

The efficacy of ANH is debatable. The studies that have been performed to date are older, use small numbers of patients and out-dated techniques. Newer studies have not shown a benefit but they have used a low volume of ANH as part of a patient blood conservation strategy<sup>18,19</sup>.

Several groups have used a form of ANH to good effect in aortic surgery. Autologous platelet rich plasma has been successfully used to reduce allogeneic transfusions in ascending and transverse arch surgery, in some instances replacing the need for allogeneic platelet transfusion<sup>17,20</sup>. After the induction of anaesthesia, blood is taken (usually between 1000 and 1500mls dependent on patient weight and stability) into a bag containing Adenosine–Citrate–Dextrose (ACD). This blood is then centrifuged in a cell saver to produce red cells (which may be reinfused immediately to prevent cardiovascular instability, or used to prime the bypass pump), platelet rich plasma (PRP) and platelet poor plasma. The plasmas are stored on a continuous agitator in theatre until after separation from the bypass machine and protamine administration at which time it is reinfused.

Zhou et al. found that the use of autologous platelet rich plasma led to a reduction of red cell transfusion by 34%, fresh frozen plasma by 53%, cryoprecipitate by 70% and platelets by 57% in patients having elective ascending and aortic arch repair surgery<sup>17</sup>. Of note they did not report any issues with patient safety. It is of paramount importance that any blood or blood products produced in this manner are correctly labelled, stored and do not leave theatre. They should be labelled with the patient's name, identification number and date of birth and they should be marked "FOR AUTOLOGOUS USE ONLY, NOT TO LEAVE THEATRE". Whole blood should be agitated periodically whilst filling the bags to ensure mixing with the anticoagulant; however, once they have been filled, assuming the proper use of anticoagulant, there is no need for them to be agitated further. Blood may be kept at room temperature for up to 4 hours, after which it should be stored at 6°C. Conversely, platelets (including PRP) should not be cooled and should be agitated continuously.

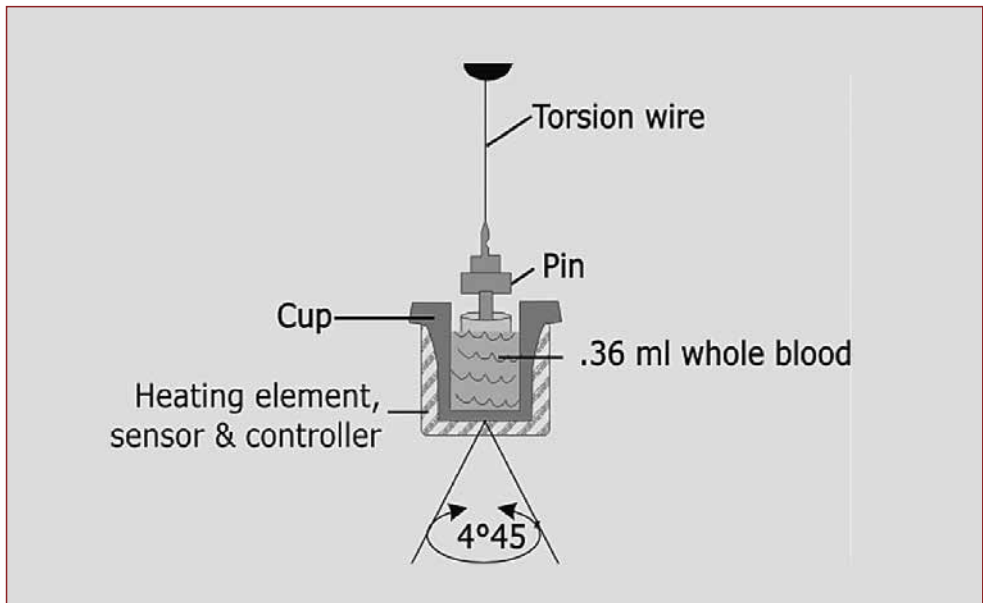
### 3 Cell Salvage

Cell salvage involves the reinfusion of blood spilt in the operative field, usually after it has been washed. Unwashed cell salvage blood is generally viewed less favourably as it contains inflammatory cytokines and can lead to hypotension, an inflammatory response with hyperthermia and an increase in perioperative bleeding. Additionally, when shed blood from the cardiotomy reservoir is reinfused without processing there is an increased incidence of cerebral lipid microemboli. The evidence base for the use of cell salvage is limited, in part by a number of small studies dealing mostly with coronary artery surgery. A meta-analysis performed in 2009 found that the use of cell salvage reduces patient exposure to autologous transfusion<sup>21</sup>. A Cochrane review performed in 2010 concluded that there was a relative risk reduction in exposure to allogeneic blood of 23% (95% CI=14-31%) and that the risk reduction was superior with washed cell salvage rather than unwashed<sup>22</sup>. The Society of Thoracic Surgeons, in their 2011 practice guidelines concluded that "routine use of red cell saving is helpful for blood conservation in cardiac operations using CPB, except in patients with infection or malignancy"<sup>23</sup>.

### 4 Point of Care Testing

Prior to the end of bypass, point of care tests (POCT) may be performed to assess the extent of the coagulopathy. These are most commonly performed on either the Thromboelastograph® (TEG®) or the Rotational Thromboelastometer® (ROTEM®).

These devices work in a similar fashion to assess the viscoelastic properties of blood under low shear conditions. In the TEG® there is a stationary cylindrical cup which holds 360µl of whole blood and oscillates for 10secs at a time. A pin is suspended in the blood sample via a torsion wire and is monitored for motion. After fibrin-platelet bonding has occurred, linking the pin and the cup together, the torque of the rotation is transmitted to the pin which is then converted by an electromagnetic signal into an electrical signal – the TEG® trace. The strength of the bonds affects the magnitude of the pin motion so output is directly related to the strength of the formed clot. With clot retraction and lysis, the fibrin-platelet bonds are broken (Figure 2).



*Figure 2: A cross sectional diagram of the mechanism of thromboelastography®. The cup oscillates at 4-45 degrees. As the blood clots the torque of the torsion wire changes leading to the familiar trace.*

Several tests can be performed to assess various parts of the coagulation system. If performed prior to the end of bypass, all must use heparinase to negate the effects of the heparin in the patient. A baseline trace is usually performed (Kaolin activated on TEG®, Intem on ROTEM®), together with an assessment of fibrinogen (Functional Fibrinogen in TEG®, Fibtem in ROTEM®). These then allow blood products to be requested.

On separation from cardiopulmonary bypass protamine is administered to reverse residual heparinisation and the pre-ordered blood products, usually comprising fresh frozen plasma and platelets, are administered pre-emptively to treat the inevitable significant coagulopathy. Further transfusions can be guided by further use of the POCT devices. At this point, 4 tests are commonly performed – a baseline Kaolin activated (TEG®) or Intem (ROTEM®), a baseline with heparinase to assess whether there is any residual heparin, an assessment of fibrinogen and a tissue factor-activated trace (RapidTEG® or extem (ROTEM®)) which will give a quick assessment of clot strength (Figure 3).

TEG-ACT	R	K	ANGLE	MA	LY30
CK	6.3 4.6-9.1	1.1 0.8-2.1	75.0 63-78	61.1 52-69	1.3 0.0-2.6
CRT	87.9 82-152	0.4 0.3-1.1	79.4 60-78	65.3 52-70	1.4 0.0-2.2
CKH	6.4 4.3-8.3	1.3 0.8-1.9	71.4 64-77	61.0 52-69	
CFF				27.4 15-32	500.0 278-581

*Figure 3: The 4 common TEG® tests. CK is a citrated blood kaolin-activated trace, CRT is a citrated blood tissue factor-activated ("Rapid") trace, CKH is a citrated blood kaolin-activated trace with heparinise addition, CFF is a citrated fibrinogen trace.*

Thromboelastography has been used in cardiac surgery for over 30 years and has been shown consistently to reduce all transfusion requirements when used in algorithm-based studies.<sup>24</sup> In aortic surgery, Mohr and colleagues found a significant reduction in transfusion associated with the use of ROTEM® from a median of 16 units to a median of 9 units transfused per patient undergoing a procedure requiring DHCA<sup>25</sup>. They also demonstrated a significant decrease in the need for massive transfusion.

## 5 Factor Concentrates

Some centres in Europe now administer factor concentrates, such as 4 factor prothrombin complex and fibrinogen concentrate, rather than allogeneic plasma and cryoprecipitate<sup>26</sup>. The commonly found prothrombin concentrates (Octaplex™ and Beriplex™) contain factors II, VII, IX and X as well as quantities of proteins C and S. They are presented as powders containing human proteins which must be reconstituted prior to administration. It is typically 20x more concentrated in factors than FFP (Table 3).

Fibrinogen concentrate (Riastap™) is presented as a powder for solution containing human fibrinogen which must be reconstituted prior to use. When reconstituted as per the manufacturer's guidance, it contains 20mg/ml of fibrinogen. In contrast, cryoprecipitate contains not only fibrinogen (at a concentration of between 1-1.5mg/ml) but also Factor VIII:C, von Willebrand factor, fibronectin and Factor XIII. Gorlinger et al. found a reduction in all transfusion requirements and re-sternotomy with the introduction of a novel algorithm which incorporated point of care testing with the use of factor concentrates in complex cardiac surgery<sup>26</sup>. The use of concentrates has numerous potential advantages including a small infusion volume, typically 100-150mls for the equivalent dose of four units of FFP and 2 units of cryoprecipitate, as well as the benefit of not needing timely cross-matching and defrosting of products. It must however be noted that whilst some prothrombin concentrates are licensed for use in acquired coagulopathy, fibrinogen concentrate is not yet licensed for use in this setting.

Fibrinogen concentrate has been gaining popularity in complex cardiac surgery. In studies to date, where blood loss is on-going, fibrinogen concentrate has been advocated as a first-line therapy before transfusion of blood products. In these studies, the dose has been

**Table 3:** The typical constituents of reconstituted prothrombin complex

Active Ingredient	Prothrombin complex (reconstituted) (IU/ml)
Factor II	20-48
Factor VII	10-25
Factor IX	20-31
Factor X	22-60
Protein C	15-45
Protein S	12-38

guided by measurement of the maximum clot firmness (MCF) of the ROTEM® FIBTEM trace using the formula below:

$$\text{Fibrinogen concentrate (g)} = \frac{[22 \text{ (mm)} - \text{FIBTEM MCF (mm)}] \times \text{body weight (kg)}}{140}$$

In phase I and II studies, Rahe-Meyer et al. found use of fibrinogen concentrate as a first-line therapy was more successful in cessation of bleeding than transfusion of FFP and platelets, and hypothesised that the higher circulating concentration of fibrinogen may compensate for the lower number and function of platelets<sup>27</sup>. However, despite showing an excellent safety profile, a phase III randomised controlled trial failed to show any benefit, in fact the use of fibrinogen concentrate was associated with an increase in allogeneic blood transfusion<sup>28</sup>. This was an unexpected finding and there has been much speculation that the study design may have inadvertently biased the results. In a separate study in complex cardiac surgery, it was found that the use of fibrinogen concentrate leads to a significant reduction in allogeneic transfusion<sup>29</sup>.

In cases of on-going bleeding refractory to administration of clotting products, the use of recombinant factor VII (rFVIIa) has been advocated. Recombinant factor VII, when complexed with tissue factor, can activate Factor X to Xa and Factor IX to IXa. Factor Xa then converts prothrombin to thrombin which in turn leads to the formation of a haemostatic plug by the formation of fibrin from fibrinogen. This in turn leads to local haemostasis and the further activation of platelets. DiDomenico et al. describe the profound effect that a single dose of rFVIIa at 120mcg/kg had on bleeding rates in their institution, although smaller doses of 60mcg/kg may be sufficient to improve coagulation and reduce the risk of thromboembolic events<sup>30</sup>.

## Optimising the reserve of anaemia

### 1 Liberal versus restrictive transfusion

The debate regarding what level of haemoglobin we should aim for rages on. In 2007, Murphy and colleagues produced data aiming to quantify the association of transfusion with clinical outcome<sup>31</sup>. They found that transfusion was associated with an increased risk of infection (OR 3.38 (95% CI 2.6-4.4)) and ischaemic outcomes (OR 3.35 (95% CI 2.68-4.35)) as well as an increased length of hospital stay and increased mortality. Despite this,

a randomised controlled trial published by the same group comparing a liberal versus a restrictive transfusion threshold (7.5g/dl vs 9g/dl) failed to show a difference in the primary outcome of serious infection or ischaemic events<sup>32</sup>. This is in keeping with the Cochrane review of randomised controlled trials of transfusion in the critically ill and surgical patients which also showed that outcomes were similar in those treated in a restrictive or liberal manner<sup>33</sup>. However, the Murphy study showed significantly more deaths in the restrictive group than the liberal group leading the authors to postulate that perhaps in this group of patients, with known cardiovascular disease, possibly at the limits of their cardiovascular reserve, an extra gram of haemoglobin provided a crucial boost to oxygen carrying capacity. It is worth noting, however, that the haemoglobin level aimed for in this group was still only 9g/dl.

## 2 Peri-Operative Iron

In patients where there is not the time or opportunity to correct pre-operative anaemia or in patients who develop anaemia in the peri-operative period, there may be benefit to giving intravenous (iv) iron perioperatively. In a randomized controlled trial of perioperative iron in abdominal surgery, Froessler and colleagues gave patients a single dose of iv iron immediately before surgery and a dose of iv iron based on estimated blood loss in theatre. They found a reduction in the need for transfusion which was associated with a shorter hospital stay and higher mean haemoglobin concentration 4 weeks after surgery<sup>34</sup>.

## Conclusion

The management of bleeding in aortic surgery remains challenging. Massive blood loss and transfusion are well known to be independently associated with operative morbidity and mortality. Despite this, there are strategies that can be taken to modify risk factors, such as pre-operative anaemia, and target therapy appropriately. Application of these strategies can reduce peri-operative transfusion requirements and may be helpful in improving overall patient outcomes.

## References

1. Achneck H, Sileshi B, Parikh A, et al. Pathophysiology of bleeding and clotting in the cardiac surgery patient. *Circulation* 2010; 122: 2068-2077.
2. Gertler JP, Cambria RP, Brewster DC. Coagulation changes during thoracoabdominal aneurysm repair. *J Vasc Surg.* 1996; 24 ; 936-45.
3. Cina CS, Clase CM. Coagulation disorders and blood product use in patients undergoing thoracoabdominal aortic aneurysm repair, *Transfusion Medicine Reviews*, 2005; 19(2): 143-54.
4. Williams J, Phillips-Bute S, Bhattacharya S, et al. Predictors of Massive Transfusion with Thoracic Aortic Procedures Utilizing Deep Hypothermic Circulatory Arrest. *J Thorac Cardiovasc Surg.* 2011 May; 141(5): 1283–1288).
5. Girdauskas E, Kempfert J, Kuntze T, et al. Thromboelastometrically guided transfusion protocol during aortic surgery with circulatory arrest: A prospective randomised trial. *Journal of Thoracic and Cardiovascular Surgery* 2010 140, 1117-1124.
6. Klein A, Collier T, Brar M et al. The incidence and importance of anaemia in patients undergoing cardiac surgery in the UK. *Anaesthesia* 2016; 71: 627-35.
7. Svensson L. Progress in Ascending and Aortic Arch Surgery: Minimally invasive surgery, blood conservation and neurological deficit prevention. *Ann Thorac Surg* 2002; 74: S1786-8.



8. McEvoy MD, Reeves ST, Reves JG, et al. Aprotinin in cardiac surgery: A review of conventional and novel mechanisms of action. *Anesthesia and Analgesia* 2007; 105: 949-962.
9. Nicolau-Raducu R., Subramaniam K., Marquez J., et al. Safety and efficacy of tranexamic acid compared with aprotinin in thoracic aortic surgery with deep hypothermic circulatory arrest. *Journal of Thoracic and Cardiovascular Surgery* 2010; 24: 73-790.
10. Mangano DT, Miao Y, Vulysteke A, et al. Mortality associated with aprotinin during 5 years following coronary artery bypass graft surgery. *J Am Med Assoc* 2007; 297: 471-9.
11. Fergusson AA, Hébert PC, Mazer CD, et al. A comparison of aprotinin and lysine analogues in high risk cardiac surgery. *NEJM* 2008; 358: 2319-31.
12. Royston D, Taylor K, Bidstrup B, et al. Effect of aprotinin on need for blood transfusion after repeat open heart surgery. *Lancet* 1987; 330: 1289-91.
13. Mangano C, Neville M, Hsu P, et al. Aprotinin, blood loss and renal dysfunction in deep hypothermic circulatory arrest. *Circulation* 2001; 204 [suppl 1]: I 276-281.
14. Sneicinski RM, Chen EP, Makadia SS, et al. Changing from aprotinin to tranexamic acid results in increased use of blood products and recombinant factor VIIa for aortic surgery requiring hypothermic arrest. *Journal of Cardiovascular and Thoracic Anesthesia* 2010; 24: 959-963.
15. Sedrakyan A, Wu A, Sedrakyan G, et al. Aprotinin use in thoracic aortic surgery: Safety and outcomes. *Journal of Thoracic and Cardiovascular Surgery* 2006; 132: 909-917.
16. Bechtel JF, Prosch J, Sievers HH, et al. Is the kaolin or celite activated clotting time affected by tranexamic acid? *Annals of Thoracic Surgery* 2002; 74: 390-393.
17. Zhou SF, Estrera AL, Loubser P, et al. Autologous platelet-rich plasma reduces transfusions during ascending aortic arch repair: a prospective, randomized, controlled trial. *Ann Thorac Surg* 2015 Apr;99(4):1282-90.
18. Casati V, Speziali D, D'Alessandro C, et al. Intraoperative low volume acute normovolaemic haemodilution in adult open heart surgery. *Anesthesiology* 2002; 97: 367-73.
19. Hohn L, Schweizer A, Licker M, et al. Absence of beneficial effect of acute normovolaemic haemodilution combined with aprotinin on allogeneic blood transfusion in cardiac surgery. *Anesthesiology* 2002;96: 276-82.
20. Zhou SF, Estrera AL, Miller CC 3rd, et al. Analysis of autologous platelet-rich plasma during ascending and transverse aortic arch surgery. *Ann Thorac Surg*. 2013 May;95(5):1525-30.
21. Wang G, Bainbridge D, Martin J, et al. The efficacy of an intraoperative cell saver during cardiac surgery: a meta-analysis of randomized trials. *Anesth Analg*. 2009 Aug;109(2):320-30.
22. Carless PA, Henry DA, Moxey AJ, et al. Cell salvage for minimising perioperative allogeneic blood transfusion. *Cochrane Database Syst Rev*. 2010;4:CD001888.
23. Ferraris VA, Brown JR, Despotis G, et al. 2011 update to the Society of Thoracic Surgeons and Society of Cardiovascular Anaesthesiologists blood conservation clinical practice guidelines. *Ann Thor Surg* 2011; 91: 944-82.
24. Despotis G, Avidan M, Eby C. Prediction and management of bleeding in cardiac surgery. *J Throm Haemostasis* 2009; 7 (suppl 1).
25. Girdauskas E, Kempfert J, Kuntze T, et al. Thromboelastometry guided transfusion protocol during aortic surgery with circulatory arrest: A prospective randomised trial. *J Thorac Cardiovasc Surg* 2010; 140: 1117-24.
26. Gorlinger K, Dirkmann D, Hanke A, et al. First-line therapy with coagulation factor concentrates combined with point of care coagulation testing is associated with decreased allogeneic blood transfusion in cardiovascular surgery. *Anesthesiology* 2011;115:1179-1191.

27. Rahe-Meyer N, Solomon C, Winterhalter M, et al. Thromboelastometry-guided administration of fibrinogen concentrate for the treatment of excessive intra-operative bleeding in thoracoabdominal aortic aneurysm surgery. *Journal of Thoracic and Cardiovascular Surgery* 2009; 138: 694-702.
28. Rahe-Meyer N, Levy J, Mazer C, et al. Randomised evaluation of fibrinogen vs placebo in complex cardiovascular surgery (REPLACE): a double-blind phase III study of haemostatic therapy. *British Journal of Anaesthesia* 2016; 117(1) 41-51.
29. Ranucci M, Baryshnikova E, Crapelli G, et al. Randomised, double blind, placebo controlled trial of fibrinogen concentrate supplementation after complex cardiac surgery. *Journal of the American Heart Association* 2015; 4: e002066.
30. DiDomenico RJ, Massad MG, Kpondonu J, et al. Use of recombinant activated factor VII for bleeding following operations requiring cardiopulmonary bypass. *Chest* 2005; 127: 1828-1835.
31. Murphy G, Reeves B, Rogers C, et al. Increased mortality, post-operative morbidity and cost after red cell transfusion in patients having cardiac surgery. *Circulation* 2007; 116: 2544-2552.
32. Murphy G, Pike K, Rogers C, et al. Liberal or restrictive transfusion after cardiac surgery. *New England Journal of Medicine* 2015; 372 : 997-1008.
33. Carson JL, Carless PA, Hebert P. Transfusion thresholds and other strategies for guiding allogeneic red blood cell transfusion. *Cochrane Database Systemic Review* 2012; 4 CD002042.
34. Froessler B, Palm P, Weber I, et al. Important role for intravenous iron in perioperative patient blood management in major abdominal surgery. *Ann Surg* 2016; 264: 41-46.

## Chapter 8

# Distal Aortic Repair for Acute Ascending Aortic Dissection

*Nisbith Patel and Pedro Catarino*

---

*“Omnem movere lapidem”*

## Introduction

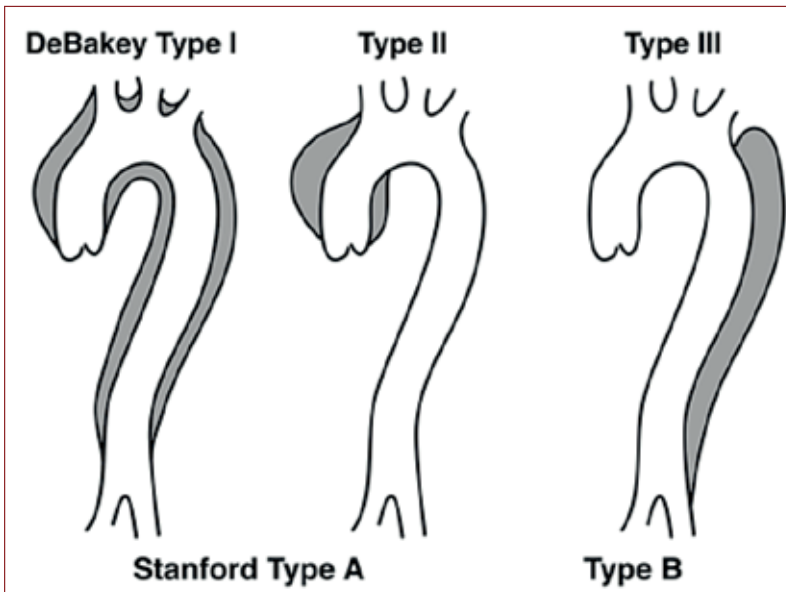
Acute ascending aortic dissection (AAD) is a surgical emergency with a high operative mortality of around 20% (range 3.6 to 33%) in contemporary series from experienced centres as well as national registries<sup>1-4</sup>. Non-operation is rarely considered, except if there are substantial co-morbidities or patient refusal, and the mortality is substantially higher (>60%)<sup>1</sup>.

AAD is often referred to as (Stanford) Type A aortic dissection. Type A dissections are currently treated according to the same surgical principles<sup>5,6</sup> largely unchanged for the past 2 decades (proximal aortic repair), which are to:

- i) excise the intimal “entry” tear;
- ii) replace the supracoronary ascending aorta with an interposition graft;
- iii) promote obliteration of the dissected ‘false’ lumen both proximally and distally.

The aim is to save the patient’s life by preventing rupture of the ascending aorta or further dissection into the pericardial sac resulting in tamponade. Additional procedures may be needed such as replacement of the aortic valve, or addressing an underlying root aneurysm or tissue weakness. Where the intimal tear extends into the aortic root, a formal root replacement may be required. Where the intimal tear is present in the aortic arch, this will necessitate arch replacement, but propagation of the dissection into the aortic arch and typically beyond, down the descending aorta, is generally not a reason to extend the repair into these areas.

The DeBakey classification (Figure 1) is helpful in distinguishing AAD which propagates into the arch and beyond (Type I) from AAD confined to the ascending aorta (Type II)<sup>6</sup>. Type I is the most common form representing 75% of AAD.



*Figure 1: Classification of acute aortic dissection*

## DeBakey

Type I: Intimal tear in the ascending aorta with dissection propagating distally to include at least the aortic arch and typically the descending aorta.

Type II: Intimal tear in the ascending aorta, with dissection confined to the ascending aorta.

Type III: Intimal tear in the descending aorta with dissection propagating most often distally.

## Stanford

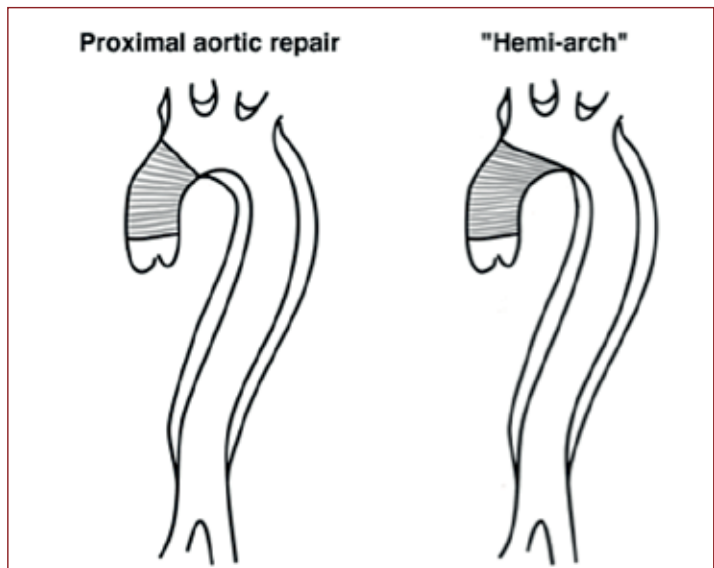
Type A: Dissection involving the ascending aorta irrespective of the site of tear.

Type B: Dissection not involving the ascending aorta.

Proximal aortic repair in DeBakey Type II gives a good result, since the dissected aorta is completely repaired. For DeBakey Type I, the efforts to obliterate the false lumen distally, which include gluing and suturing the inflow to the false lumen and diverting the blood flow down the true lumen, are not as successful. In most cases the false lumen persists and requires serial monitoring and subsequent operative re-intervention if there is expansion.

The “hemi-arch” procedure involves proximal aortic repair extending the distal aortic anastomosis along the undersurface of the aortic arch, without any re-implantation of supra-aortic vessels, and is essentially a form of proximal aortic repair (Figure 2). This should be distinguished from the “peninsula” repair described below (Figures 3a & 3b).

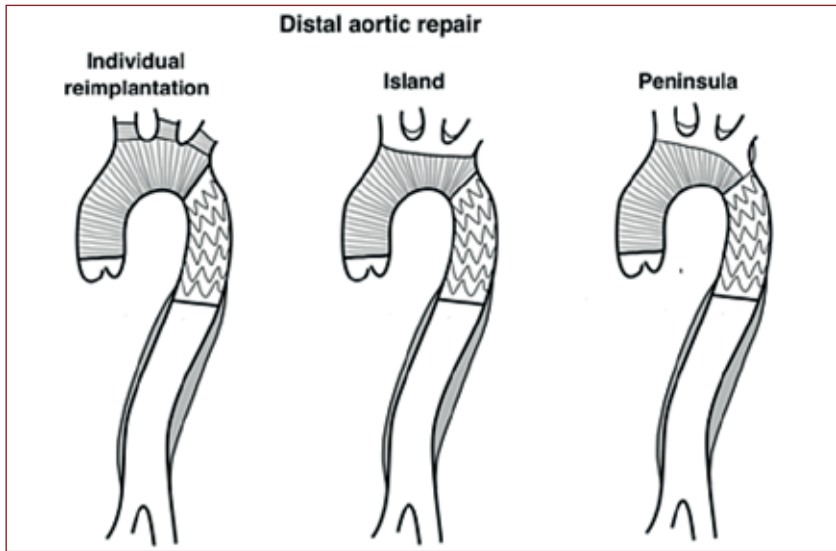
An alternative approach to Type I aortic dissection is that of distal aortic repair. The techniques to achieve this have greatly evolved over the past two decades, but can broadly be separated into two approaches:



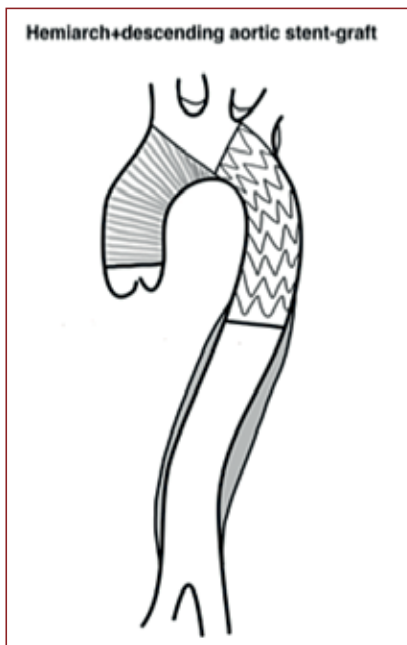
*Figure 2: Extent of repair of aortic dissection*

### 1 Total arch replacement ± distal aortic stent-grafting

This is achieved by replacement of the entire aortic arch with a synthetic graft, reimplanting the supra-aortic vessels en bloc as an island (or peninsula), or individual anastomosis of the supra-aortic vessels using branched grafts. There is typically a period of distal circulatory arrest, although the cerebral vessels are almost always perfused. This period of arrest leaves



*Figure 3a: Different forms of distal aortic repair*



*Figure 3b: Hemiarch and descending aortic stent graft - hemiarch replacement can be combined with descending aortic stenting, but will almost always lead to covering the origin of the left subclavian artery, possibly necessitating a carotid-subclavian bypass.*

the proximal descending aorta nicely exposed. The availability of hybrid arch grafts with frozen elephant trunk (FET) stent-grafts, enables straightforward deployment of a proximal descending aortic stent-graft. This physically enhances obliteration of the false lumen as well as facilitating distal anastomotic haemostasis. Where these hybrid grafts are not yet in standard use, e.g. USA, a stent-graft can nevertheless be introduced antegradely into the open descending aorta and fixed to the distal aortic arch suture line.

## 2 Hybrid debranching + retrograde / antegrade stent-grafting

Debranching techniques typically use trifurcated or other pre-fabricated grafts to re-locate the supra-aortic blood supply to the proximal ascending aorta, which enables a more limited proximal arch replacement with a synthetic graft. This graft then provides a suitable landing zone, permitting retrograde or antegrade endovascular stent-graft placement either concomitantly, or early after the primary surgery, guided by post-repair imaging.

Distal aortic repair procedures are less commonly performed (<15% of cases)<sup>5</sup> because they require more extensive surgery in an acutely unwell patient. There are certain situations where distal aortic repair is mandated, such as entry tear extending into the arch, complex tears, or where the arch is already



aneurysmal. However, in the great majority of cases, the decision to undertake a distal aortic repair is primarily aimed at achieving a higher rate of obliteration of the distal false lumen, and thus a lower rate of late operative re-intervention.

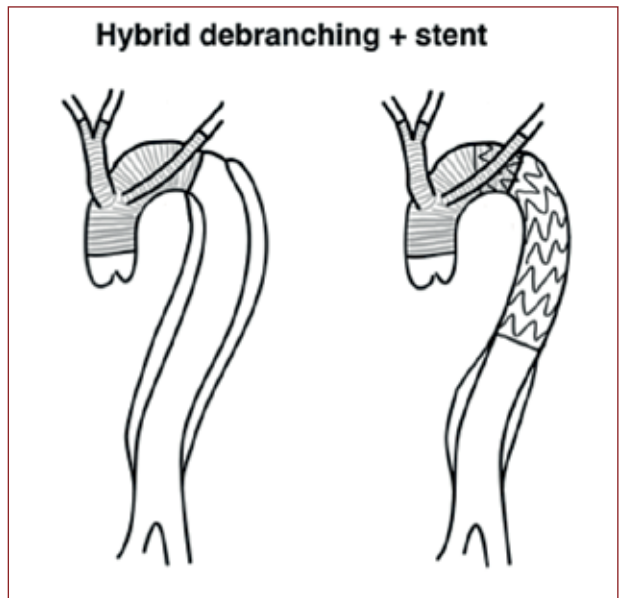
This chapter reviews the options, rationale and evidence regarding distal aortic repair in acute Type I aortic dissection.

## What is the natural history of Type A AAD treated by proximal aortic repair?

Data from large national and international registries reveals that the aorta distal to the ascending segment is involved in over 75% (and up to 90%) of patients with Type A AAD<sup>2,3</sup>. More than 30 studies have evaluated the fate of the residual false lumen after Type A aortic dissection repair and linked this to aneurysm expansion, need for distal reoperation and long term mortality.

The Mount Sinai group presents one of the most thorough analyses, widely quoted and often purported to support a relatively benign post-operative outlook<sup>7</sup>. In 179 patients with Type A AAD over 16 years (84% extending into the descending aorta), 162 patients underwent a standard proximal aortic repair as described above. Follow-up was possible for 89 patients with serial CT. The arch and descending thoracic aorta grew by 0.8mm and 1.0mm per year respectively. If there was a patent false lumen the growth rate was 1.2mm/year and if the aorta was already dilated above 4 cm, the growth rate was 1.3mm/year. Thus, there was a typically low growth rate with only 16% of patients undergoing re-operation at 10 years, with a re-operative mortality of 4%. However, no less than 40% of the late deaths were aorta-related or of unknown cause and the 10-year survival was 66% versus 79% in an age and sex-matched population. Perhaps most significantly, only 43% had a patent false lumen, the lowest figure in any publication, and this is undoubtedly the primary driving force for expansion and late events.

A contemporaneous report from the Philadelphia group reported outcomes in 221 patients with Type A AAD over an 11-year period<sup>8</sup>. Distal extension was seen in 72% and 98% underwent proximal aortic repair. Freedom from distal re-operation was 76.4% with a re-operative mortality of 31%. There was a 46% 10-year survival.



*Figure 4: Hybrid aortic repair with arch debranching and distal stent-graft.*

It certainly seems clear that post-operative false lumen patency and aortic diameter are the best predictors of aneurysm growth, distal re-intervention and survival<sup>9</sup>. More recently, The Cleveland Clinic reported their outcomes of Type A AAD patients who had undergone reoperative surgery on the distal aorta<sup>10</sup>. Over an 18-year period, 305 patients underwent distal aortic intervention, 95% of whom had had a DeBakey Type I dissection at initial presentation. False lumen patency was 78%. By 10 years the chance of re-intervention was 38% (with a 6.1% hospital mortality) and the chance of death was 28% without re-intervention, with an unadjusted 10-year survival of 65%. The median time to reoperative surgery was 3.8 years.

Kimura et al. have reported the largest single series describing the long-term effect of false lumen patency<sup>11</sup>. In 451 survivors of surgery for Type A AAD, a patent false lumen was observed in 62%, and over a 6.8-year follow-up, this increased distal aortic events by a hazard ratio (HR) of 4.1 (1.9-9.2) and reduced survival by HR 1.7 (1.1-2.6).

However, several factors cloud this issue. Type A dissection, for example, does not always extend into the descending aorta or even the arch and so the proportion of Type I versus Type II dissections in any study is a big factor in the reported false patency rate. Even so, not all Type I dissections will have a patent false lumen postoperatively and although a range from 43% to 91% is reported, the mode is closer to 60-70%<sup>7-13</sup>. However, with a proximal aortic repair, predicting which Type I dissections will have obliterated false lumina is not sufficiently accurate to be of clinical use. Despite great improvements in imaging, the presence of distal intimal tears cannot always be recognized, may not be reported in studies and failure to repair these are clearly an important factor in postoperative false lumen patency. Connective tissue disorders and younger age are associated with higher rates of false lumen patency. Post-operatively, higher blood pressure, greater aortic diameter and persistence of unresected tears are all associated with false lumen expansion. Overall a patent false lumen is associated with around 50-60% 10-year survival, compared to a 70-90% 10-year survival for a thrombosed false lumen<sup>11,13</sup>. Distal reoperation rates are around 30% at 10 years but this is highly dependent on the assiduousness of follow-up<sup>7-8, 10-11, 13</sup>.

## **Can we learn from the management of acute Type B dissections?**

Acute descending thoracic aortic dissection (Type B or Type III) is typically managed by blood pressure control unless there are complications such as impending rupture or malperfusion syndromes. The fate of the residual dissected aorta has been the subject of numerous studies, both observational and interventional, with some randomized controlled studies.

The IRAD database of such conservatively managed patients identifies 20% developing late complications requiring intervention and there is a 30-40% cumulative mortality by 5 years<sup>14</sup>. This seems higher than for repaired Type A AAD but is borne out by single institution experience<sup>15</sup>.

Surgical expansion of the true lumen and covering the intimal tear, with consequent obliteration of the false lumen, is best achieved by thoracic endovascular aortic repair (TEVAR). This is now well-established in the management of complicated acute dissection of the descending aorta, in an analogous manner to open surgical management of the acutely dissected ascending aorta<sup>6</sup>. That is, the aim is primarily to prevent the rupture, or restore the malperfusion, rather than to primarily address obliteration of the distal false lumen.

However, several studies looking at the effect of seeking early positive aortic remodeling in descending aortic dissection have been performed, and these surely have implications for the approach to Type I aortic dissection. The INSTEAD-XL randomized controlled trial of TEVAR + medical therapy versus medical therapy alone in chronic asymptomatic descending aortic dissection is certainly suggestive of a late survival advantage and lower re-intervention rate for patients with TEVAR<sup>16</sup>. This corresponded with better aortic remodeling at 2 and 5 years. The ADSORB trial similarly randomized patients to TEVAR or not, and the one year results confirm the positive aortic remodeling in this group of patients receiving TEVAR but do not show an effect on survival<sup>17</sup>. Late follow-up is awaited.

The association of positive aortic remodeling with improved survival would certainly have implications for the treatment of ascending aortic dissections. The current paradigm of converting an acute Type I dissection into a chronic distal dissection would need to be reassessed. Indeed, several centres now practice a more distal and complete aortic repair for these patients.

## **What are the results of Distal Aortic Repair in Type A AAD?**

Crawford first counseled against total arch replacement in type A aortic dissection based on a 30% mortality compared to a 16% mortality for ascending aortic replacement<sup>18</sup>. However, evolution in techniques for cerebral protection and in surgical prostheses have substantially decreased the risks of total arch replacement whilst proximal aortic repair mortality remains stubbornly elevated. The addition of a distal stent-graft or frozen elephant trunk to the total arch repair is increasingly widespread and serves to provide a physical enhancement of the false lumen obliteration, as well as covering distal entry or re-entry tears reducing retrograde pressurization of the false lumen, as well as covering small intimal tears adjacent to the anastomosis produced by suturing through fragile acutely dissected tissue.

There are a growing number of reports of this approach, all of which are retrospective cohort series. They are comprised of patients treated by some form of distal aortic repair, often framed in the context of a comparison with patients receiving proximal aortic repair. None are matched, and in some cases specific reasons for choosing a distal repair are given, and in some cases not. However, they are useful in placing contemporary 'ball park' figures to the risks of mortality, stroke, paraplegia and need for late reintervention.

### **Total arch replacement alone**

Rice et al. report one of the largest series of total arch replacement in type A AAD, with 49 of 489 patients undergoing this<sup>19</sup>. The remaining 440 patients received hemi-arch procedures and are used for comparison. Early mortality was 20.4% vs 12.9% respectively, stroke risk was 8.2% vs 10.5%; with ICU stays of 8.5 vs 9.1 days and re-exploration for bleeding 4% vs 7%, none of these comparisons achieving statistical significance. Late survival was also comparable.

The Bologna group presented their series of 28 arch replacements without elephant trunk, 14 arch replacement with floating elephant trunk and 11 with frozen elephant trunk, out of 240 patients with Type A AAD<sup>20</sup>. Total arch replacement was performed where there was a tear in the arch or descending aorta. The remaining 187 patients received proximal aortic repair. The mortality overall for arch replacement was 24.1% and did not correlate with specific arch management strategy. Early mortality in the proximal repair group was similar at 22.6%.

## Total arch replacement and frozen elephant trunk (TAR+FET)

Uchida and colleagues compared short and long term outcomes in 120 AAD patients who underwent either concomitant total aortic arch replacement (TAR) with frozen elephant trunk (FET) (n=65) or ascending aorta and hemiarch replacement (n=55)<sup>21</sup>. Patients were followed-up for 5 years. In-hospital mortality was similar between groups (4.6% vs 3.6%). No patients suffered stroke or spinal cord injury in either group. The survival rate after 5 years was significantly different at 95.3% for the TAR+FET group and 69.0% for the ascending aortic group. All patients in the TAR+FET group had a thrombosed false lumen whereas 29% of patients in ascending aortic group had a patent false lumen at 5-year follow-up.

Omura and colleagues reported short and long-term outcomes in 197 patients with DeBakey Type I AAD who underwent TAR+FET (n=88) or ascending aorta + hemi-arch replacement (n=109)<sup>22</sup>. Mean follow-up was 5 years. In-hospital mortality was 10.2% for the TAR group and 14.7% for the ascending aortic group. The 5-year survival was similar in both groups (88.6% vs 83.8%). However, freedom from distal aortic events (defined as freedom from surgery for distal aorta dilatation or distal arch diameter expanding to 50mm) at 5 years was significantly better in the TAR group (94.9%) compared to the ascending aortic group (83.6%). The difference became greater when assessing the same outcome at 10-years (91.7% in the TAR group and 64.3% in the ascending aortic group).

Tsakakis et al. reported the results of the Jotec E-vita open registry with 55 cases of acute aortic dissection treated by arch replacement + FET, with an early mortality of 11% and no postoperative spinal cord injuries in the acute patients<sup>23</sup>.

The Hannover group, who pioneered the FET technique, reported a series of 52 acute Type I aortic dissections receiving TAR+FET with 13% mortality at 30 days without any late re-operation for the arch at 40 months<sup>24</sup>. Spinal cord injury was 4%. The series began in 2004, since which time there have been stepwise technical advancements in the prostheses available. The most recent device, the Vascutek Thoraflex, used since 2013 in 11 cases had zero 30-day mortality.

The Philadelphia group reported outcomes in 78 Type I dissection patients with 42 undergoing proximal aortic repair and 36 undergoing antegrade deployment of a stent-graft in the open arch under direct vision together with a “peninsula” type arch repair which also fixed the stent in place<sup>25</sup>. Mean follow-up was 16 months. Hospital mortality was identical (14% vs 14%) but there was an additional 5.6% early mortality in the conservative group. Surprisingly postoperative stroke rates were 3% in the arch+stent group and 10% in the ascending aortic group, despite longer circulatory arrest times in the arch group. Transient paraparesis was 9% in the arch+stent group and 2% in the ascending aortic group with no permanent deficits in either group. There was an 80% thoracic false lumen obliteration in the stent group compared to 17% in the non-stented group, and whilst no patient required reoperative surgery in the arch+stent group, 11% required reoperative surgery in the ascending aortic group, with an imperfect follow-up.

In an evolution of their technique this group also reported on 61 patients with acute primary arch tears, comparing a classic total arch repair in 31 patients with a peninsula arch technique with concomitant antegrade stenting in 30 patients<sup>26</sup>. Early mortality was 26% vs 13% respectively although it did not reach statistical significance. There were no post-operative spinal cord injuries despite a move to using longer (15cm) stents. Substantially better false lumen thrombosis was seen with stenting (85%) compared to not stenting (43%) at 4-5 years.

## Hybrid repair – debranching + retrograde stent

Esposito et al. describe 89 consecutive patients with type A dissection extending into the descending aorta undergoing hybrid repair with the Lupiae technique<sup>27</sup>. Essentially a trifurcated graft is used to re-route the supra-aortic vessels off the replaced ascending aorta. Initially in the series, the arch was also largely replaced but latterly, only the ascending aorta such that there was at least a 2.5 cm potential landing zone distal to the supra-aortic branches. Patients then underwent standard retrograde stenting determined by malperfusion or persistence of the false lumen. With this strategy 3 were stented immediately, 50 at around 4 weeks, and a further 12 at 6 months, with 16 avoiding stenting altogether. Early mortality was 8.9%. There were no spinal cord injuries. Eight-year survival was 93.7% and correlated with “healing” of the false lumen.

## Systematic Reviews

The GERAADA registry reported on 658 patients with a DeBakey Type I AAD specifically excluding tears in the arch<sup>28</sup>. 518 patients underwent proximal aortic repair and 140 patients underwent distal aortic repair, some with isolated total arch and some with additional frozen elephant trunk. Thirty-day mortality was slightly lower in the ascending aortic group (18.7%) compared to the arch group (25.7%) but not statistically significant, and there were more unstable patients in the arch group. The incidence of new neurological deficit was similar in both groups (13.6% vs 12.5%).

Di Eusanio et al. carried out a meta-analysis comprising 13 studies with 598 patients undergoing arch replacement and proximal descending aortic stenting<sup>29</sup>. Early mortality was 10% (range 0-27.7%), post-operative stroke was 4.8% (range 0-12.0%) and spinal cord injury was 4.3% (0-13.8%). False lumen thrombosis was over 90% in over half of the studies with follow-up data.

There are two recent comparative meta-analyses which compare outcome data in proximal versus distal aortic repair in type A AAD. Yan et al.<sup>30</sup> identified 9 studies, which reported outcomes in 1236 patients receiving proximal aortic repair (PAR) versus 636 patients receiving total arch replacement. Proximal aortic repair was associated with 3.6% to 18.7%

*Table 1: Summary of figures with the strongest support in published series.*

	Proximal Aortic Repair	Distal Aortic Repair	Reference
Early mortality	10-25%	10-25%	29-31
5-year mortality	15-30%	5-10%	21,22
10-year mortality	40-50% with patent false lumen 10-30% with occluded false lumen	Not available	11,13
Stroke	5-8%	2-12%	29-31
Spinal cord injury	0-1%	0-4%	23-25,29
False lumen patency	60-70%	0-20%	21,25, 26, 29
Distal reoperation	20-40%	0-10%	22, 29-31



and TAR with 4.6% to 25.7% early mortality, with PAR having an overall significantly lower relative risk of early mortality, 0.69 (95% CI 0.54-0.90). Overall there was a significantly higher incidence of post-operative aortic events with PAR, including re-operation with a relative risk of 3.14 (95% CI 1.74-5.67).

Poon et al. included 14 studies, which reported outcomes in 1435 patients undergoing hemiarch aortic repair versus 786 patients undergoing TAR<sup>31</sup>. In summary, there was no significant difference in early mortality with a relative risk of 0.84 (95% CI 0.65-1.09), with a range from 3.6% to 24.1% in the hemiarch group and 3.8% to 28.6% in the TAR group. Aortic re-intervention was also not statistically different with a relative risk 1.45 (0.93-2.28).

Despite the statistical methodology, the studies included in these systematic reviews are clinically heterogenous, evidenced not least by the variability in outcomes between studies. In most cases, there are specific reasons for inclusion of patients into PAR or DAR ab initio, with DAR usually reserved for intimal tears in the arch, connective tissue disease and arch aneurysm. One study included in both comparative reviews reported PAR with concomitant endovascular management of the descending aorta (as in Figure 3b.). There is also a preponderance of Asian studies, with only 4 comparative studies reporting non-Asian cohorts. This is important because the non-Asian reports invariably have higher mortality for both proximal and distal aortic procedures, 13% to 24.1% and 20.4% to 28.6% respectively. It is also known that Asian patients are less likely to suffer progressive aortic enlargement, and seem to have a more benign course from intramural haematoma<sup>32</sup>. On the other hand, it is likely that proximal aortic repair is preferentially used in more critical patients, with a higher proportion of tamponade in most but not all studies. Similarly, distal aortic repair might be preferred in younger patients and by more experienced surgeons.

## Conclusion

The major difficulty in interpreting these retrospective data lies in the lack of validity in direct comparisons between patients undergoing either proximal or distal aortic repair. The discussion is often framed as a trade-off between a shorter procedure (proximal aortic repair) performed by all cardiac surgeons and providing a lesser mortality versus a longer operation (distal aortic repair) performed only by specialist aortic surgeons providing a lesser re-intervention rate<sup>30</sup>. Unfortunately, the data presented do not provide clarity on either front.

It remains undeniable however that ascending aortic dissection continues to carry a high operative mortality outside of Asia. Why is there this high mortality? Clearly AAD is a devastating pathology particularly when it extends through the whole aorta. Unmodifiable preoperative factors do play a large role in determining this mortality but nevertheless advances in surgical technique do offer the opportunity to correct more of the pathology than has hitherto been the norm<sup>6</sup>. Failure to obliterate a large area of false lumen permits a continued consumptive coagulopathy<sup>33</sup>, as well as potentiating distal malperfusion<sup>34</sup>. These are important determinants of early mortality. Persistence of the false lumen also leaves survivors susceptible to later aorta-related mortality, or re-intervention with further risk of operative mortality.

The mortality and morbidity following surgical treatment of the aortic arch in ascending aortic dissection, particularly when combined with stenting of the proximal descending aorta, has declined to a level comparable to that of proximal aortic repair<sup>31</sup>. Distal aortic repair appeals to the surgical principle of correcting the anatomical lesion, and hence the



pathological consequences, as far as possible. This approach, consistent with the trend in management of descending aortic dissection, may impact favourably on both early mortality and late re-intervention. As with descending aortic dissection the time has now come for a randomized controlled trial to answer this question.

## References

1. Pape LA, Awais M, Woznicki EM, et al. Presentation, Diagnosis, and Outcomes of Acute Aortic Dissection. 17-Year Trends From the International Registry of Acute Aortic Dissection (IRAD). *J Am Coll Cardiol* 2015;66(4):350–8.
2. Conzelmann LO, Weigang E, Mehlhorn U, et al. Mortality in patients with acute aortic dissection type A: analysis of pre- and intraoperative risk factors from the German Registry for Acute Aortic Dissection Type A (GERAADA). *Eur J Cardiothorac Surg* 2016;49(2):44–52.
3. Russo CF, Mariscalco G, Colli A, et al. Italian multicentre study on type A acute aortic dissection: a 33-year follow-up. *Eur J Cardiothorac Surg*, 2016. 49(1): p. 125–31.
4. Bridgewater B, Keogh B, Kinsman R, et al. Surgery on the aorta. Sixth National Adult Cardiac Surgical Database Report—Demonstrating quality. Henley-on-Thames, United Kingdom: Dendrite Clinical Systems Ltd., 2008:324–32.
5. Westaby S, Saito S, Katsumata T. Acute type A dissection: conservative methods provide consistently low mortality. *Ann Thorac Surg* 2002 Mar;73(3):707–13.
6. Nienaber CA, Clough RE. Management of acute aortic dissection. *Lancet* 2015; 385: 800–11
7. Halstead, JC, Meier M, Etz C, et al., The fate of the distal aorta after repair of acute type A aortic dissection. *J Thorac Cardiovasc Surg*, 2007. 133(1): 127–35.
8. Geirsson, A, Bavaria JE, Swarr D, et al., Fate of the residual distal and proximal aorta after acute type a dissection repair using a contemporary surgical reconstruction algorithm. *Ann Thorac Surg*, 2007. 84(6): 1955–64.
9. Song JM, Kim SD, Kim JH, et al. Long-term predictors of descending aorta aneurysmal change in patients with aortic dissection. *J Am Coll Cardiol*. 2007 Aug 21;50(8):799–804.
10. Roselli, EE, Loor GE, He J, et al., Distal aortic interventions after repair of ascending dissection: the argument for a more aggressive approach. *J Thorac Cardiovasc Surg*, 2015. 149(2 Suppl): p. S117–24 e3.
11. Kimura N, Itoh S, Yuri K, et al. Reoperation for enlargement of the distal aorta after initial surgery for acute type A aortic dissection. *J Thorac Cardiovasc Surg* 2015;149:S91–8.
12. Park KH, Lim C, Choi JH, et al. Midterm change of descending aortic false lumen after repair of acute type I dissection. *Ann Thorac Surg*. 2009 Jan;87(1):103–8.
13. Fattouch K, Sampognaro R, Navarra E, et al. Long-term results after repair of type A acute aortic dissection according to false lumen patency. *Ann Thorac Surg*. 2009 Oct;88(4):1244–50.
14. Tsai TT, Fattori R, Trimarchi S, et al. Long-term survival in patients presenting with type B acute aortic dissection: insights from the International Registry of Acute Aortic Dissection. *Circulation*, 114 (2006), pp. 2226–2231.
15. Evangelista A, Salas A, Ribera A, et al. Long-term outcome of aortic dissection with patent false lumen: predictive role of entry tear size and location. *Circulation*. 2012 Jun 26;125(25):3133–41.
16. Nienaber CA, Kische S, Rousseau H, et al. Endovascular Repair of Type B Aortic Dissection. Long-term Results of the Randomized Investigation of Stent Grafts in Aortic Dissection Trial. *Circ Cardiovasc Interv*. 2013;6:407–416.

17. Brunkwall J, Kasprzak P, Verhoeven E, et al. Endovascular repair of acute uncomplicated aortic type B dissection promotes aortic remodelling: 1 year results of the ADSORB trial. *Eur J Vasc Endovasc Surg.* 2014 Sep;48(3):285-91.
18. Crawford ES, Kirklin JW, Naftel DC, et al. Surgery for acute dissection of ascending aorta. Should the arch be included? *J Thorac Cardiovasc Surg.* 1992 Jul;104(1):46-59.
19. Rice RD, Sandhu HK, Leake SS, et al. Is Total Arch Replacement Associated With Worse Outcomes During Repair of Acute Type A Aortic Dissection? *Ann Thorac Surg* 2015;100(6): 2159–2166
20. Di Eusanio M, Berretta P, Cefarelli M, et al. Total Arch Replacement Versus More Conservative Management in Type A Acute Aortic Dissection. *Ann Thorac Surg.* 2015;100(1):88-94.
21. Uchida N, Shibamura H, Katayama A, et al. Operative strategy for acute type A aortic dissection: ascending aortic or hemiarch versus total arch replacement with frozen elephant trunk. *Ann Thorac Surg,* 2009. 87(3): p. 773-7.
22. Omura A, Miyahara S, Yamanaka K, et al. Early and late outcomes of repaired acute DeBakey type I aortic dissection after graft replacement. *J Thorac Cardiovasc Surg,* 2016. 151(2): p. 341-8.
23. Tsagakis K, Pacini D, Di Bartolomeo R, et al. Arch replacement and downstream stent grafting in complex aortic dissection: first results of an international registry. *Eur J Cardiothorac Surg.* 2011;39(1):87-93.
24. Shrestha M, Fleissner F, Ius F, et al. Total aortic arch replacement with frozen elephant trunk in acute type A aortic dissections: are we pushing the limits too far? *Eur J Cardiothorac Surg* 2015;47(2):361-6
25. Pochettino A, Brinkman WT, Moeller P, et al. Antegrade thoracic stent grafting during repair of acute DeBakey I dissection prevents development of thoracoabdominal aortic aneurysms. *Ann Thorac Surg,* 2009. 88(2): p. 482-9.
26. Vallabhajosyula P, Gottret JP, Robb JD, et al. Hemiarch replacement with concomitant antegrade stent grafting of the descending thoracic aorta versus total arch replacement for treatment of acute DeBakey I aortic dissection with arch tear. *Eur J Cardiothorac Surg.* 2016;49(4):1256-61.
27. Esposito G, Cappabianca G, Bichi S, et al. Hybrid repair of type A acute aortic dissections with the Lupiae technique: ten-year results. *J Thorac Cardiovasc Surg.* 2015;149(2 Suppl):S99-104.
28. Easo J, Weigang E, Hölzl PP, et al. Influence of operative strategy for the aortic arch in DeBakey type I aortic dissection: analysis of the German Registry for Acute Aortic Dissection Type A. *J Thorac Cardiovasc Surg,* 2012. 144(3): p. 617-23.
29. Di Eusanio M, Castrovinci S, Tian DH, et al. Antegrade stenting of the descending thoracic aorta during DeBakey type 1 acute aortic dissection repair. *Eur J Cardiothorac Surg.* 2014;45(6):967-75.
30. Yan Y, Xu L, Zhang H, et al. Proximal aortic repair versus extensive aortic repair in the treatment of acute type A aortic dissection: a meta-analysis. *Eur J Cardiothorac Surg.* 2016;49(5):1392-401.
31. Poon SS, Theologou T, Harrington D, et al. Hemiarch versus total aortic arch replacement in acute type A dissection: a systematic review and meta-analysis. *Ann Cardiothorac Surg.* 2016;5(3):156-73.
32. Jonker FH, Trimarchi S, Rampoldi V, et al. Aortic expansion after acute type B aortic dissection. *Ann Thorac Surg.* 2012 Oct;94(4):1223-9.
33. Guan XL, Wang XL, Lui YY et al. Changes in the Hemostatic System of Patients With Acute Aortic Dissection Undergoing Aortic Arch Surgery. *Ann Thorac Surg.* 2016 Mar;101(3):945-51.
34. Girdauskas E, Kuntze T, Borger MA, et al. Surgical risk of preoperative malperfusion in acute type A aortic dissection. *J Thorac Cardiovasc Surg.* 2009;38(6):1363-9.



## **Section 2 -**

# **Thoracic Surgery - Minimally Invasive Lung Resection**

Michael Shackcloth

Steven Woolley

---

*“Salus ubi multi consilarii”*



## Chapter 9

# Video-Assisted Thoracoscopic Surgery versus Open Lobectomy

*Douglas J. Mathisen, MD*

---

*“Dimidium facti, qui coepit habet”*

## Historical Perspective

The introduction of video-assisted thoracic surgery (VATS) has transformed general thoracic surgery as a specialty. With the introduction of individual ligation of vessels and hilar dissection, it has become an acceptable method of pulmonary resection.

There are known contraindications to VATS lobectomy including the inability to tolerate one-lung ventilation. If the surgeon thinks that a complete resection is not achievable by this method, an open resection is preferable. It is generally accepted that T3 and T4 tumors or the presence of N2 or N3 disease is a contraindication to performing VATS lobectomy. Indications for VATS lobectomy continue to expand and sleeve lobectomies and even carinal resections now have been shown to be feasible. D'Amico and others have stated that as the indications have increased so has the conversion rate however <sup>1</sup>.

The performance of VATS lobectomy continues to increase in frequency and at the Massachusetts General Hospital, the percentage of lobectomies performed by VATS per year has steadily increased from 27% in 2007 to 66% in 2014 (Table 1). A consecutive group of 535 patients had an 11% incidence of atrial fibrillation, median length of stay of four days, air leak greater than five days of 5.5% and no operative mortality (personal communication, Table 2).

*Table 1: Lobectomy – VATS and Open (Retrospective)*

	2007	2008	2009	2010	2011	2012	2013	2014
VATS	51	64	90	79	142	114	88	128
OPEN	136	129	116	136	117	104	88	68
% VATS	27.3	33.2	43.7	36.7	54.8	52.3	50	65.3

*Table 2: VATS Lobectomy Complications*

Patients	535
Tumor size	2.2cm
Median LOS	4 days
A Fib	11%
Air leak (>5days)	5.5%
Mortality	0

This trend has been confirmed in large national databases. Using the STS National Database for a period between 2009 and 2012 with data from 165 sites, there were roughly even numbers of VATS lobectomies and open lobectomies; 3725 VATS procedures per year and 3605 open procedures per year. The next three-year interval with data from 198 sites saw an increase in VATS lobectomies to 5,324 per year compared to 3519 open procedures per year (see table 3). These data are somewhat skewed by the institutions reporting. Most of these are large groups, university practices, or those with a special interest in minimally invasive thoracic surgery.



When using a large national cancer database with 1473 hospitals reporting and over 68,350 lobectomies performed from 2007-8, Paul and colleagues showed that 85% of lobectomies were done as an open procedure compared to only 15% for VATS from 2007 to 2008<sup>2</sup>. These data would suggest that VATS lobectomy has been slower to be adopted in the general practice of thoracic surgery compared to those large university groups.

**Table 3:** Society of Thoracic Surgeons (STS) National Database comparison of VATS lobectomies compared to open. (Interpret in the context of selection bias from institutions reporting).

2009-2012	2012 – 2014
STS Database	STS Database
165 SITES	198 SITES
VATS 11,172 = 3,725/YEAR	VATS 15,973 = 5,324/YEAR
OPEN 10,813 = 3,605/YEAR	OPEN 10,559 = 3,519/YEAR
Nationwide Inpatient Sample database 2007-2008	
1473 Hospitals	68350 lobectomies
VATS	10554 (15%)
Open	57796 (85%)

Any group that adopts VATS lobectomy will undoubtedly go through a learning curve. It has generally been accepted that exposure to 50 open lobectomies is required for proficiency, but once trainees have reached that level they have similar outcomes in operative time and morbidity, and no demonstrable difference in mortality compared to attending surgeons learning to do VATS lobectomies.

In a retrospective study, Puri and colleagues looking at the conversion rate during the VATS lobectomy learning curve, it was shown that this steadily declined from 28% in 2004 to 2006, to 15% in 2007 to 2009, to 11% for the period of 2009 to 2012<sup>3</sup>. An analysis of those 87 patients who underwent conversion during this interval of eight years revealed that 64% were converted for anatomical reasons, 25% were converted for vascular complications or indications, and 9% were converted because of unsuspected findings with lymph nodes. Of note, the VATS patients had an overall complication rate of 23% compared to a 42% complication rate during the same time interval for patients undergoing an open procedure. However, those patients who had a conversion from VATS to open had a slightly higher complication rate of 46%.

One of the limitations of comparing VATS to open lobectomy is the paucity of randomised prospective studies adequately powered to answer most questions about outcomes of the two procedures. Most of the data is derived from retrospective single institution studies, retrospective database comparisons, or attempts at propensity matching to try to overcome the limitations of retrospective studies. Villamizar in 2009 from a single institution performed propensity matching on 284 patients having open lobectomies versus 284 propensity-matched patients undergoing VATS lobectomy<sup>4</sup>. Statistically significant differences in favour of VATS lobectomy were found for overall complications, atrial fibrillation, air leak,

length of stay but no differences were found in mortality (Table 4). Gopalda et al. looking at a national database from nonfederal community hospitals in the USA showed slightly different results<sup>5</sup>. They reported on over 12,000 open procedures compared to 759 VATS procedures (Table 4). This underscores once again the low penetration of VATS lobectomy into the community setting. The average length of stay was virtually the same, 9.5 days for open procedures and 9.2 days for VATS procedures, 4.1% of patients undergoing VATS sustained an intraoperative complication compared to only 2.8% of the cohort undergoing open procedures. There was no difference in operative mortality (3.1% open and 3.4% VATS). (Table 4).

**Table 4: Comparisons of Open to VATS Lobectomy**

<b>Single Institution (Propensity matched)</b>			
<b>Non-Randomized</b>			
	<b>OPEN</b>	<b>VATS</b>	<b>P value</b>
<b>N</b>	284	284	
<b>COMPLICATIONS</b>	49%	36%	0.0001
<b>Atrial fibrillation</b>	21%	13%	0.01
<b>Air leak</b>	19%	13%	0.05
<b>Length of hospital stay</b>	5	4	0.001
<b>Death</b>	5%	3%	0.2
<i>Villamizar 2009 JTCVS 138:419-425</i>			
<b>National Database Non-Federal Hospitals (Community) Retrospective</b>			
	<b>OPEN</b>	<b>VATS</b>	<b>P value</b>
<b>N</b>	12860	759 (6%)	--
<b>Length of hospital stay</b>	9.5	9.2	--
<b>Intraoperative complications</b>	2.8%	4.1%	0.03
<b>Mortality</b>	3.1	3.4%	0.67
<i>Gopalda 2010 Ann Thorac Surg 89:1563-1570</i>			

Using the Society of Thoracic Surgeons database, Boffa showed that overall complication rate was 36% for open procedures and 30% for VATS lobectomies ( $p = 0.001$ ). This data from 2001 to 2010 included over 11,000 patients undergoing open lobectomy and over 4300 patients undergoing VATS lobectomies<sup>6</sup>. Individual outcomes for complications were listed for pulmonary complications, atrial fibrillation and the need for transfusion. All three of those complications were less common in the VATS population. Mortality, however, was not statistically different between the VATS and open procedures with 1.3% mortality for VATS versus 1.8% mortality for open procedures<sup>6</sup>.

Onaitis and colleagues reported on complications for both open and VATS lobectomy utilizing the Society of Thoracic Surgeons database for a similar time period of 2000 to 2010<sup>7</sup>.

They found a slightly different rate of overall complications, but still statistically significant. Their overall complication rate was 21.7% for open thoracotomy versus 17.8% for VATS lobectomy ( $p = 0.0001$ ). Of note, however, for those patients with a predicted FEV1 of less than 60%, they found an increased rate of complications in those undergoing open lobectomy. However, if the predicted FEV1 was greater than 60%, there was no difference in the overall complication rate. Burt et al., using the same Society of Thoracic Surgeons database but for a period of 2009 to 2011 and looking at a group of VATS (6568) versus open lobectomies, found that the mortality for VATS was significantly lower compared to open procedures, 0.7% and 4.8% respectively<sup>8</sup> ( $p = 0.003$ ). In those patients with an FEV1 less than 40%, the complication rate was 12.8% for VATS and 21.9% for open lobectomy ( $p = 0.005$ ). When DLCO was less than 40%, the complication rate for VATS was 10.4% and 14.9% for open lobectomies ( $p = 0.016$ ).

Yan and colleagues performed a meta-analysis comparing VATS lobectomy to open lobectomy for complications, systemic recurrence and five-year mortality<sup>9</sup>. There were 19 non-randomised studies and two randomized studies for early-stage lung cancer in patients undergoing the two procedures. They found no difference in air leak, arrhythmia, pneumonia, mortality, or local recurrence. They did find, however, an improved rate of systemic recurrence and five-year mortality for those undergoing VATS lobectomy. One could infer that there was more advanced disease in the open group.

Atrial fibrillation (AF) has been an important factor comparing open versus VATS lobectomy. Park and colleagues analyzed 389 patients undergoing lobectomy for stage I non-small cell lung cancer who were found to be in sinus rhythm preoperatively. From this group, they found 122 matched pairs for age and gender, from whom they could analyse the incidence of atrial fibrillation<sup>10</sup>. In those patients undergoing VATS lobectomy, the incidence of atrial fibrillation postoperatively was 12%, for the open group it was 16%. These results were not statistically significant with a p-value of 0.36. The VATS patients generally had a better DLCO and less induction therapy thereby calling into question as to how equally matched the two groups were.

## Quality of Life and Pain

It has been claimed by many authors that there is a distinct advantage to VATS lobectomy compared to open lobectomy when measuring postoperative pain. Again, it is very difficult to draw firm conclusions since there is very little randomised prospective data that is adequately powered. Most studies are small and frequently retrospective. Normori et al. reported a retrospective study comparing VATS lobectomy to anterior thoracotomy<sup>11</sup>. Their conclusions were that VATS lobectomy lost its pain advantage after two weeks. They also found that there were similar results between the two approaches when comparing pulmonary function, muscle strength and walking postoperatively. Erus et al. compared VATS to axillary thoracotomy<sup>12</sup>. No difference was seen in pain, complications, performance status or quality of life. They did show an overall improvement in length of stay for VATS patients. Quality of life is often difficult to assess and rarely done. Rizk and colleagues from the Memorial Sloan Kettering Cancer Institute performed a prospective trial assessing quality of life after VATS lobectomy or open lobectomy<sup>13</sup>. They observed the patients for 12 months and utilized four time periods to record their observations. They concluded that results were similar in the VATS and open groups for the physical component of their observations and pain. Interestingly, the scores were worse for VATS in the mental component summary score. The authors felt that this could possibly be related to missed

expectations of their postoperative course. Their feeling was patients were led to believe that it would be easier than it was and were disappointed when they had the degree of discomfort that was experienced.

## Cost

It is often touted that the cost of VATS lobectomy is less than open lobectomy mainly because of the difference in length of stay. Farjar et al. performed a 90-day cost analysis of VATS versus open lobectomy<sup>14</sup>. They utilised a cohort study of 9962 patients, 31% of whom had VATS lobectomies, 69% of whom had open lobectomies. They analysed prolonged hospital stay, 90-day emergency department visit rate, and readmissions in their cost analysis. All three variables were generally higher in the open group showing 7.2%, 24%, and 12% respectively compared to 3%, 22%, and 10% in the VATS cohort. Analysis of cost at 90 days was \$3476 less for VATS lobectomies compared to the open cohort of ( $p = 0.001$ ). However, when the data was adjusted for length of stay, there was no statistical difference and the average difference in cost was only \$1276 in favor of VATS. Their conclusion was that had more attention been paid to the length of stay in the open group, cost would not be a significant factor comparing open versus VATS lobectomy.

## Lymph Node Analysis

VATS lobectomy and open lobectomy are similar operations, but not exactly performed the same way. The sequence of taking the vital structures, pulmonary arteries, pulmonary veins, bronchus, and fissure are frequently different between the two procedures. There is now the concept of fissureless VATS lobectomies to reduce air leaks. This might suggest that obtaining lymph nodes in the fissure might be less effective for VATS lobectomies but it is too soon to draw that conclusion. Many authors have looked at the issue of lymph node retrieval and upstaging of lymph nodes. Denlinger and colleagues performed a retrospective non-randomised study of stage I lung cancer patients undergoing VATS versus open thoracotomy<sup>15</sup>. There were 464 open thoracotomies compared to only 79 VATS lobectomies. While the differences between the overall number of nodes and N2 nodes were small, it was nonetheless statistically significant in favour of open lobectomies. There was a total of 8.9 nodes found in the open group compared to 7.4 in the VATS group and 3.7 N2 nodes compared to 2.5 N2 nodes in the VATS group. There was no difference in the number of N1 nodes found. They found statistically significant differences albeit very small when looking at 7R nodes and 7L nodes. There was no statistical difference in level 5 and level 6 lymph nodes comparing open versus VATS lobectomy. There were no differences in 4R nodes between open and VATS lobectomies.

To overcome the limitations of retrospective analysis, Scott and colleagues performed a propensity matched analysis comparing open lobectomy to VATS lobectomy for length of stay, complications, lymph nodes, mean number of lymph nodes, and mortality<sup>16</sup>. They found no significant differences in overall mortality, complication rate and lymph nodes. They did find that in the open group there was a trend to more lymph nodes being found with a mean of 18 in the open group compared to 14.8 in the VATS group. There was a statistically significant difference in length of stay in favour of VATS lobectomy (four days versus seven days for open lobectomies,  $p = 0.0001$ ). The same author, in a secondary analysis of the ACOSOG Z0030a randomised clinical trial looking at 686 patients who underwent open lobectomy versus 66 patients who underwent VATS lobectomy found a tendency to more lymph nodes found in the open group (19 vs. 15,  $p=0.147$ ). They

concluded that a longer time period was required to determine the overall oncologic equivalency of VATS versus open lobectomy<sup>17</sup>.

Boffa and colleagues utilizing the STS database from 2001 to 2010 analysed the findings in open lobectomy (n = 7137) compared to VATS lobectomy (n = 4394) for lymph node involvement<sup>18</sup>. A statistically significant increase was found in overall nodal upstaging in the open group compared to the VATS group (14.3% versus 11.6%,  $p < 0.001$ )<sup>18</sup>. Upstaging from N0 to N1 was more common in the open group (9.3% versus 6.7%,  $p < 0.001$ ); however, upstaging from N0 to N2 was similar between groups (5% open and 4.9% VATS,  $p = 0.52$ ). When looking at propensity-matched pairs, N0 to N1 upstaging remained more common in the open group than the VATS group (9% and 6.8%,  $p = 0.002$ ).

Utilising 208 propensity matched pairs, Lee et al. confirmed these findings showing an increased number of nodes in open procedures compared to VATS (14.3 vs 11.3,  $p = 0.001$ )<sup>19</sup>. The number of stations sampled was significantly greater for open procedures (3.8 compared to 3.1 for VATS  $p = 0.001$ ). There was no difference in survival, however, at three and five years.

Licht and colleagues, utilising the Danish National Lung Cancer Registry for clinical stage I lung cancer from 2007 to 2011, found highly significant differences in lymph nodes between open and VATS lobectomies<sup>20</sup>. Utilising 924 patients in the open category compared to 751 patients in the VATS lobectomy category, the incidence of upstaging from N0 to N1 was 14% in the open and 8.3% in the VATS group. For N0 to N2, the results were even more dramatic with 10.9% of patients upstaged in the open group compared to 3.6% in the VATS group ( $p = 0.001$ ). These authors questioned “whether VATS may be an inferior oncologic operation in some hands”. Some have questioned whether this increase in upstaging may be related to more central tumors in the open group compared to the VATS group. If indeed this is true, then it is likely that there may be a difference in comparability in staging between the two groups and any conclusions regarding survival could be called into question.

Finally, Zhang and colleagues performed a meta-analysis of 24 studies regarding the issue of lymph nodes comparing VATS to open lobectomy<sup>21</sup>. Three thousand patients undergoing open lobectomy were compared to 2115 patients undergoing VATS lobectomy. For N1 disease, VATS and open lobectomy were equivalent. For N2 disease, it was found that open lobectomy identified more nodes.

## Patterns of Recurrence and Survival

A trial sponsored by the American College of Surgeons ACOSOG Z0030 was designed to compare survival of open versus VATS lobectomy<sup>22</sup>. There were 686 patients in the open group and only 66 patients in the VATS group. The median follow-up was 6.7 years for the two groups and the median survival for T1 cancers was 9.1 years and for T2 cancers was 6.5 years. The five-year survival for T1 tumors was 72% and 55% for T2 lesions. There was no difference in survival in the VATS versus the open categories.

Flores and colleagues compared 520 patients undergoing VATS lobectomy to 652 patients undergoing open lobectomy and showed minimal differences in local or regional recurrence for VATS versus open, 4% and 5% respectively<sup>23</sup>. However, it did show an 11% incidence of distant recurrence for those undergoing open lobectomy compared to only 6% in those having VATS procedures. There was no difference in the incidence of metachronous recurrence (3%). The overall recurrence rate was 19% in the open procedure versus 13%

in the VATS group ( $p = 0.01$ ). The authors admitted there was major selection bias in that patients were non-randomised and the chosen procedure was based on the surgeon's choice. They concluded that the several randomised studies performed to date have been too underpowered to draw any meaningful conclusions about survival.

Some have argued that VATS lobectomy might allow more adjuvant chemotherapy to be given when indicated. Licht and colleagues analysed this issue utilising the Danish National Cancer Registry Database<sup>24</sup>. They evaluated 1968 patients operated on between the years 2007 and 2012. There were 990 patients in the VATS group and 978 patients in the open group. Upstaging occurred in 22.9% of those undergoing open lobectomy compared to 11.8% undergoing VATS lobectomy ( $p < 0.001$ ). Upstaging from N0 to N1 occurred in 8.1% of the VATS patients and 13% of the open patients, and from N0 to N2, they found 3.7% upstaging in the VATS group compared to 9.9% in the open group ( $p = 0.001$ ). They found no difference in adjuvant chemotherapy compliance between VATS and open lobectomy. Predictors of compliance in their study were age, comorbidity, and pathologic N status<sup>24</sup>.

Nwogu underscored some of the difficulties in interpreting propensity-matched studies. CALGB 31001 was a propensity-matched study of 175 pairs of patients comparing VATS to open lobectomy<sup>25</sup>. The variables analysed were length of stay, complications, independent home discharge, and survival. There were statistically significant benefits for VATS lobectomy with regards to length of stay, complications and independent home discharge ( $p$  values from 0.0001 for length of stay to 0.001 for complications and discharge). The length of stay was 8 days in the open lobectomy compared to 5.4 days in the VATS lobectomy group. Complications were recorded in 25% of patients undergoing open lobectomy compared to 15% in the VATS lobectomy group. Independent home discharge was achieved in 90% of open patients and 93% of VATS patients. Survival was analysed at 36 months and was slightly in favour of open lobectomies, but not statistically significant. The authors recognised that despite their efforts of propensity matching, many patients were missing important information on lymph nodes, pulmonary function tests, and that a few institutions contributed a disproportionately large number of the patients thereby skewing the data. The study did not control in any way for surgeon motivation in terms of the procedure chosen. They felt that to date, well-designed prospective multi-institutional studies have not been done to answer some of the pressing questions comparing open versus VATS lobectomy.

## Conclusion

Video-assisted thoracic surgery is undoubtedly growing in frequency and this is reflected in large databases. It has been slow to be adopted in the community hospitals. In 2016, the minority of thoracic surgeons still performs VATS lobectomy. There is always a learning curve when adopting a new procedure. There are some unique complications that are not encountered with open lobectomies such as transection of pulmonary arteries or pulmonary veins, unplanned pneumonectomies, bilobectomy and airway injuries. It has been shown, however, that over time the incidence of these complications and the conversion rates do decline as more experience is gained.

To date almost all the data that we rely upon is underpowered, retrospective and from single institutions. Often those performing VATS lobectomy do so under a strict set of patient pathways or guidelines, whereas open lobectomies have not benefited from this



same level of rigor in avoidance of complications, management, pain management and postoperative care. There certainly is conflicting data in the literature regarding virtually any topic regarding VATS lobectomies, be it complications, cost, lymph nodes, or survival. There is a consensus however that VATS lobectomies are associated with less pain, but that advantage may diminish after 1 month.

While reduced complications, overall quality of life, reduced length of stay and reduced cost are all important variables in lung cancer surgery, the overarching concern, however, is survival. VATS lobectomy is not a new treatment; it is a new procedure. It is thought to achieve the same outcomes technically as open lobectomy. Once again, the lack of adequately powered randomised prospective studies makes definitive conclusions difficult about the comparability of these two procedures in treating patients with early-stage lung cancer. The most concerning evidence that has been reported is the increased finding of upstaging in open lobectomies compared to VATS lobectomies. This calls into question the adequacy of VATS lobectomies as a cancer operation compared to open lobectomies. Some have argued this difference is simply related to more central tumors in the open group compared to the VATS lobectomy group. While this might be true, and could explain differences in upstaging, it means these groups are not comparable in extent of disease. The claims of equivalent survival may be called into question. These issues really will never be answered until an adequately powered randomised prospective study is performed. If nodal upstaging affects survival, we might be doing disservice to patients by offering a procedure that is not as likely to cure them, and its only benefit is in pain, quality of life, and complications. In over 40 years, the overall cure rate of lung cancer has gone from 10% to 20%. If we were to find that the most favorable group of patients undergoing lung cancer surgery, those with clinical stage I lung cancer, had a 5% reduction in their overall survival with VATS lobectomy compared to open lobectomy, we would be doing a disservice to our patients. If a small difference was found in favor of open lobectomy, patients may still demand a minimally invasive surgical procedure. VATS lobectomy undoubtedly has been a transforming procedure in thoracic surgery. It can now be performed in a very comparable way to open lobectomy and may indeed have some advantages. The open question remains as to whether it is still equivalent to open lobectomy and this needs to be answered. Since this debate is not likely to be answered soon, it may be most appropriate to follow the advice of Chang and Wood: “surgeons should advocate for specialty care and surgical quality that assures best outcomes regardless of the surgical approach”<sup>26</sup>!

## References

1. Hanna JM, Berry MF, D’Amico TA. Contraindications of video-assisted thoracoscopic surgical lobectomy and determinants of conversion to open. *J Thorac Dis.* 2013 Aug;5 Suppl 3:S182-9.
2. Paul S, Sedrakyan A, Chiu YL, et al. Outcomes after lobectomy using thoracoscopy vs thoracotomy: a comparative effectiveness analysis utilizing the Nationwide Inpatient Sample database. *Eur J Cardiothorac Surg.* 2013 Apr;43(4):813-7.
3. Puri V, Patel A, Majumder K, et al. Intraoperative conversion from video-assisted thoracoscopic surgery lobectomy to open thoracotomy: a study of causes and implications. *J Thorac Cardiovasc Surg.* 2015 Jan;149(1):55-61, 62.
4. Villamizar NR, Darrabie MD, Burfeind WR, et al. Thoracoscopic lobectomy is associated with lower morbidity compared with thoracotomy. *J Thorac Cardiovasc Surg.* 2009 Aug;138(2):419-25.
5. Gopaldas RR, Bakaeen FG, Dao TK, et al. Video-assisted thoracoscopic versus open thoracotomy lobectomy in a cohort of 13,619 patients. *Ann Thorac Surg.* 2010 May;89(5):1563-70.

6. Boffa DJ, Dhamija A, Kosinski AS, et al. Fewer complications result from a video-assisted approach to anatomic resection of clinical stage I lung cancer. *J Thorac Cardiovasc Surg.* 2014 Aug;148(2):637-43.
7. Ceppa DP, Kosinski AS, Berry MF, et al. Thoracoscopic lobectomy has increasing benefit in patients with poor pulmonary function: a Society of Thoracic Surgeons Database analysis. *Ann Surg.* 2012 Sep;256(3):487-93.
8. Burt BM, Kosinski AS, Shrager JB, et al. Thoracoscopic lobectomy is associated with acceptable morbidity and mortality in patients with predicted postoperative forced expiratory volume in 1 second or diffusing capacity for carbon monoxide less than 40% of normal. *J Thorac Cardiovasc Surg.* 2014 Jul;148(1):19-28, discussion 28-29.
9. Yan TD, Black D, Bannon PG, et al. Systematic review and meta-analysis of randomized and nonrandomized trials on safety and efficacy of video-assisted thoracic surgery lobectomy for early-stage non-small-cell lung cancer. *J Clin Oncol.* 2009 May 20;27(15):2553-62.
10. Park BJ, Zhang H, Rusch VW, et al. Video-assisted thoracic surgery does not reduce the incidence of postoperative atrial fibrillation after pulmonary lobectomy. *J Thorac Cardiovasc Surg.* 2007 Mar;133(3):775-9.
11. Nomori H, Horio H, Naruke T, et al. What is the advantage of a thoracoscopic lobectomy over a limited thoracotomy procedure for lung cancer surgery? *Ann Thorac Surg.* 2001 Sep;72(3):879-84.
12. Erus S, Tanju S, Kapda li M, et al. The comparison of complication, pain, quality of life and performance after lung resections with thoracoscopy and axillary thoracotomy. *Eur J Cardiothorac Surg.* 2014 Oct;46(4):614-9.
13. Rizk NP, Ghanie A, Hsu M, et al. A prospective trial comparing pain and quality of life measures after anatomic lung resection using thoracoscopy or thoracotomy. *Ann Thorac Surg.* 2014 Oct;98(4):1160-6.
14. Farjah F, Backhus LM, Varghese TK, et al. Ninety-day costs of video-assisted thoracic surgery versus open lobectomy for lung cancer. *Ann Thorac Surg.* 2014 Jul;98(1):191-6.
15. Denlinger CE, Fernandez F, Meyers BF, et al. Lymph node evaluation in video-assisted thoracoscopic lobectomy versus lobectomy by thoracotomy. *Ann Thorac Surg.* 2010 Jun;89(6):1730-5; discussion 1736.
16. Scott WJ, Matteotti RS, Egleston BL, et al. A comparison of perioperative outcomes of video-assisted thoracic surgical (VATS) lobectomy with open thoracotomy and lobectomy: results of an analysis using propensity score based weighting. *Ann Surg Innov Res.* 2010 Mar 22;4(1):1.
17. Scott WJ, Allen MS, Darling G, et al. Video-assisted thoracic surgery versus open lobectomy for lung cancer: a secondary analysis of data from the American College of Surgeons Oncology Group Z0030 randomized clinical trial. *J Thorac Cardiovasc Surg.* 2010 Apr;139(4):976-81; discussion 981-3.
18. Boffa DJ, Kosinski AS, Paul S, et al. Lymph node evaluation by open or video-assisted approaches in 11,500 anatomic lung cancer resections. *Ann Thorac Surg.* 2012 Aug;94(2):347-53; discussion 353.
19. Lee PC, Nasar A, Port JL, et al. Long-term survival after lobectomy for non-small cell lung cancer by video-assisted thoracic surgery versus thoracotomy. *Ann Thorac Surg.* 2013 Sep;96(3):951-60; discussion 960-1.
20. Licht PB, Jørgensen OD, Ladegaard L, et al. A national study of nodal upstaging after thoracoscopic versus open lobectomy for clinical stage I lung cancer. *Ann Thorac Surg.* 2013 Sep;96(3):943-9; discussion 949-50.

21. Zhang Z, Feng H, Wang X, et al. Can lymph node evaluation be performed well by video-assisted thoracic surgery? *J Cancer Res Clin Oncol*. 2015 Jan;141(1):143-51.
22. Su S, Scott WJ, Allen MS, et al. Patterns of survival and recurrence after surgical treatment of early stage non-small cell lung carcinoma in the ACOSOG Z0030 (ALLIANCE) trial. *J Thorac Cardiovasc Surg*. 2014 Feb;147(2):747-52: Discussion 752-3.
23. Flores RM, Ihekweazu UN, Rizk N, et al. Patterns of recurrence and incidence of second primary tumors after lobectomy by means of video-assisted thoracoscopic surgery (VATS) versus thoracotomy for lung cancer. *J Thorac Cardiovasc Surg*. 2011 Jan;141(1):59-64.
24. Licht PB, Schytte T, Jakobsen E. Adjuvant chemotherapy compliance is not superior after thoracoscopic lobectomy. *Ann Thorac Surg*. 2014 Aug;98(2):411-5; discussion 415-6.
25. Nwogu CE, D'Cunha J, Pang H, et al. VATS lobectomy has better perioperative outcomes than open lobectomy: CALGB 31001, an ancillary analysis of CALGB 140202 (Alliance). *Ann Thorac Surg*. 2015 Feb;99(2):399-405.
26. Cheng AM, Wood DE. VATS versus open surgery for lung cancer resection: moving beyond the incision. *J Natl Compr Canc Netw*. 2015 Feb;13(2):166-70. Review.



## Chapter 10

# Avoiding and Treating Complications in VATS Lobectomy

*Ariel W. Knight and Shanda H. Blackmon*

---

*“Sublata causa tollitur effectus”*

## Introduction

It has been well established in multiple large case series that video-assisted thoracoscopic surgical (VATS) lobectomy is a feasible, safe procedure with similar oncologic efficacy to open lobectomy<sup>1-5</sup>. Furthermore, it has been shown that compared to a traditional thoracotomy, VATS lobectomy is associated with significantly lower rates of postoperative pulmonary complications, arrhythmias and transfusion requirements<sup>2, 6, 7</sup>. It also tends to be better tolerated in elderly patients and those with decreased pulmonary reserve demonstrated by preoperative investigations<sup>8, 9</sup>. However, less than half of all lobectomies are currently performed via a VATS approach<sup>8, 9</sup>. The lack of widespread adoption of VATS lobectomy may be due to the technical challenges associated with a minimally invasive approach, the risks associated with an unplanned conversion to thoracotomy and debate regarding sufficient pulmonary and mediastinal lymphadenectomy or upstaging<sup>10</sup>.

Increased experience with VATS has led to lower conversion rates<sup>6, 7, 11</sup>. Earlier conversions and more liberal approaches to starting thoracoscopically, even for the most difficult cases, are often seen as surgeons gain experience. Approximately half of all VATS conversions to thoracotomy are performed in an emergent fashion<sup>11</sup>. Roughly a quarter occur due to vascular injuries, most commonly involving the pulmonary arteries<sup>11</sup>. The remaining majority are typically done to accommodate anatomic limitations, namely intrathoracic adhesions, tumour size, or lymph node involvement prohibiting VATS resection<sup>11</sup>. Common principles of reducing urgent conversion and enhancing safety include practicing for emergencies, recording all cases for review when the unexpected is encountered, and constant re-training. However, in general, both open and VATS lobectomy are associated with good outcomes, although open resections, and particularly conversions, are associated with higher rates of postoperative complications, including arrhythmias, pneumonia, and respiratory failure<sup>11</sup>.

Vascular injuries during thoracic surgery, in both open and VATS cases, can quickly lead to significant bleeding. Unfortunately, this is the most feared intraoperative complication. Fortunately, major bleeding is encountered in less than 5% of VATS lung resections<sup>2, 3, 7, 11, 14</sup>. Once a surgical team has trained to handle such events and has a standard operating procedure in place, risks beyond blood loss can be readily managed. However, bleeding complications can be managed safely and effectively via a VATS approach, and do not always necessitate immediate conversion to thoracotomy. Surgeons who are proficient with intracorporeal thoracoscopic suturing can sometimes primarily repair an injury. Topical haemostatic agents can also usually control most bleeding. Most often, the reaction to an injury causes more damage than the actual injury itself, and as such, once the bleeding slows, the surgeon should gently hold pressure, start a timer, and wait. As such, while VATS management of vascular injuries is associated with significantly higher intraoperative blood loss and procedural duration, it is not associated with a longer length of hospital admission or inferior long-term outcomes<sup>16-18</sup>.

Overall, it is important to consider on a case-by-case basis the specific factors that may increase the risk of intraoperative complications. It is also vital to confirm the individual patient's anatomy on preoperative imaging. In the operating room, the primary surgeon should remain in close communication with his or her team, particularly at critical portions of the case. Preparation for an intraoperative emergency is paramount, and involves having necessary VATS and thoracotomy equipment readily at hand in addition to a protocol that will rapidly activate a response team. In the event of a bleeding complication, applying direct pressure until the anesthesia team has caught up and transfused prior to examining a major injury will create a calmer and more controlled environment.



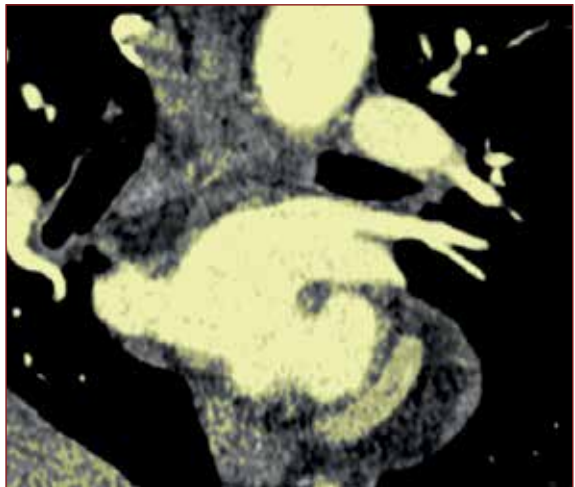
## Preoperative Planning

As with any surgical procedure, it is imperative to be aware of potential intraoperative complications upfront and prepare accordingly before they occur. Anticipating a difficult or atypical dissection allows the surgeon to anticipate potential complications and even preemptively act to prevent them. Noting how many pulmonary artery branches exist, any aberrant or replaced arteries or veins, and carefully looking for anomalies including bronchus suis, azygos lobe, replaced pulmonary veins, and a common pulmonary vein trunk (Figures 1 and 2). In patients who have undergone prior coronary artery bypass graft surgery, particularly with utilization of the left internal mammary artery, preoperative imaging is essential to confirm the position of the bypass graft to avoid intraoperative transection or other injury (Figure 3).

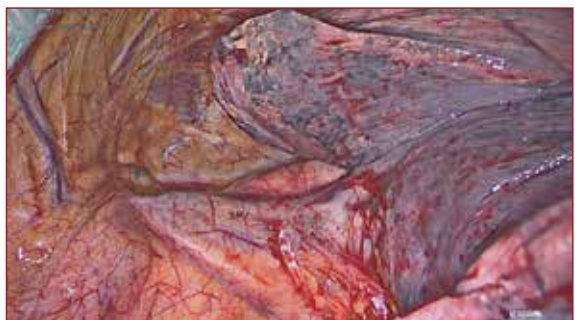
Patient-specific risk factors that are associated with an increased incidence of intraoperative bleeding complications include a larger body habitus, receipt of neoadjuvant chemotherapy or radiation therapy, and prior cardiothoracic surgery<sup>19</sup>. Disease-specific risk factors associated with increased intraoperative bleeding include granulomatous disease, larger tumour size, proximity of the primary tumour to pulmonary vasculature, lymph node calcification, and metastatic lymph node involvement<sup>3, 19, 20</sup>.

Preoperative computed tomography imaging must be carefully and meticulously assessed for pulmonary vasculature anomalies and other anatomic variants that may influence surgical planning. Reassuringly, over 95% of pulmonary vascular anatomy can be accurately visualized and assessed via CT imaging<sup>21-25</sup>. Obviously, it is essential to note the tumour location relative to other structures, particularly pulmonary artery branches. In some instances, it may be useful to obtain a preoperative pulmonary angiogram for three-dimensional reconstruction of the vasculature to identify branching patterns more accurately.

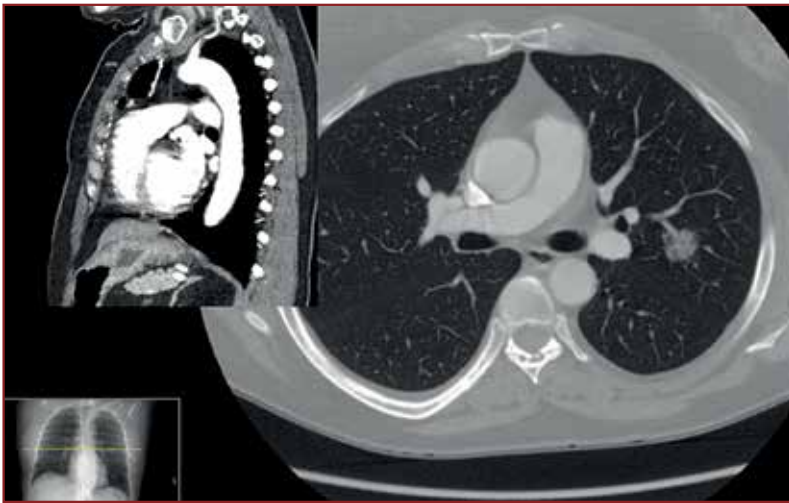It is also important to evaluate for evidence of lymph node calcification, which is associated with increased risk of vascular injury. Hilar node calcification is associated with a 37% increased risk of conversion from VATS to thoracotomy and bronchial node calcification with a 25% risk, both due to bleeding complications<sup>14</sup>.



*Figure 1: Anomalous left-sided common pulmonary vein demonstrated on high resolution contrast computed tomography*



*Figure 2: Direct visualization via VATS of an aberrant right upper lobe superior pulmonary vein.*



*Figure 3: Demonstration of a patent LIMA-LAD coronary artery bypass graft in the setting of a left upper lobe malignancy via high resolution contrast and non-contrast computed tomography.*

Regardless of the radiologic modalities utilized, the surgeon must always have a conversion strategy preoperatively. Conversion should not be viewed as a failure, just a more invasive approach.

## **Pulmonary Arteries**

The pulmonary artery is a fragile vessel with high volume blood flow, which makes it more prone to injury during pulmonary resection compared to other hilar structures. Attempts to repair pulmonary artery branches can easily lead to further tearing and worsening bleeding, and may ultimately extend to involve the main pulmonary artery<sup>10</sup>. Pulmonary arterial injury can quickly lead to life-threatening haemorrhage, and intraoperative damage may necessitate a more extensive pulmonary resection than planned<sup>10</sup>. The consequences of these complications are more severe in the setting of pulmonary hypertension, which must be evaluated for in the preoperative setting. Fortunately, in high volume, tertiary care centers, the overall incidence of pulmonary arterial bleeding is 5% or less. In such a setting, these complications are associated with a lower mortality rate<sup>2, 3, 7, 11-14</sup>. Furthermore, it has been demonstrated that careful preoperative planning and meticulous surgical technique both decrease the risk of pulmonary artery injury.

It is critical to recognize that pulmonary artery injuries are not always immediately apparent intraoperatively. For example, it is not uncommon to experience bleeding during lymph node dissection and division of bronchial arterial branches. Certainly, this bleeding is not life-threatening, but can obscure adequate visualization and subsequently increase the risk of injury to other structures. As such, it is imperative to never assume that bleeding is simply from a minor structure. In general, however, bright red blood is more likely to be from a lymph node or a bronchial vessel while darker, gushing bleeds are far more concerning for a pulmonary artery injury<sup>10</sup>. Bleeding in this area can be controlled with pressure, packing, or a topical haemostatic agent. Often, moving to another area and allowing the bleeding to stop will give the surgeon time to clean the area and return to a bloodless field.

Pulmonary artery anatomy is highly variable between individuals, and thus is a common cause of bleeding complications in pulmonary resection. Notably the left upper lobe arterial supply is the most variable, containing anywhere from four to seven branches, and is therefore most prone to injury.

Intraoperative injury to the pulmonary artery typically occurs during dissection of either adjacent hilar structures or the pulmonary artery itself. The pulmonary artery is especially prone to injury during bronchial dissection, when it lies directly posterior to the bronchus being dissected. As such, maintaining direct contact between the anterior structure and the dissecting instrument to avoid placing undue tension or torsion on the posterior pulmonary artery allows for a generally safe dissection<sup>10</sup>. If using an energy device for dissection, it is also important to avoid unintended contact between the instrument and the pulmonary artery to avoid causing lateral thermal spread.

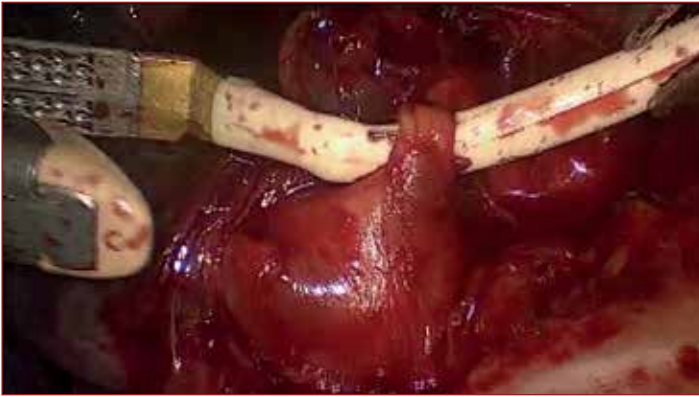The other common scenario in which pulmonary artery bleeding occurs is during dissection of the artery itself. These injuries tend to occur when dissection of another area or branch of the same pulmonary artery places excessive tension on the damaged area. Retraction of lung parenchyma, other hilar structures, or other pulmonary artery segments risks placing excess tension on the pulmonary artery, which can lead to tearing<sup>15</sup>. Again, without an overlying structure to tamponade bleeding, this usually leads to an unstable clinical situation in which significant blood loss can occur early and quickly<sup>10</sup>. Initial control is obtained by applying direct pressure with a sponge stick to the site of bleeding and releasing any retraction on the lobe without causing further injury.

Injuries that are more proximal on the pulmonary artery lead to increased blood loss and tend to require more complex resections and subsequent repairs. Proximal pulmonary artery injuries are at high risk of extending into the main pulmonary artery, which can quickly progress to uncontrolled haemorrhage and require salvage pneumonectomy. Conversely, distal pulmonary artery bleeds are typically easier to control proximally and thus tend to bleed less. They also are associated with a lower incidence of converting to thoracotomy and are less likely to require more extensive anatomic resection.

There is also a difference between upper and lower lobectomy-related pulmonary artery injuries<sup>10</sup>. Notably, lower lobectomy-associated injuries do not typically involve or affect the proximal pulmonary artery. As such, repair attempts are less likely to require division of the main pulmonary artery, and thus the possibility of salvage pneumonectomy is lower. However, lower lobectomy-associated pulmonary artery bleeds may still be significant. Conversely, upper lobectomy-associated injuries are more likely to involve the proximal pulmonary artery. Thus, creating and exacerbating an injury in this location is more likely to lead to uncontrolled haemorrhage and necessitate a salvage pneumonectomy to achieve adequate haemostasis.

## **Pulmonary Veins**

As is the case with pulmonary artery branches, the pulmonary venous anatomy can be markedly anomalous and is also a cause of lobectomy-related bleeding, both via VATS and thoracotomy. The most common pulmonary vein anatomic variation is the take-off of a segmental vein posterior to the bronchus intermedius, present in approximately 6% of patients<sup>26</sup>. Within this variant, 55% drain to the superior pulmonary vein, 41% to the inferior pulmonary vein, and 4% to the superior segmental vein<sup>27</sup>.



*Figure 4: Intraoperative use of a stapler guide to direct a stapler anvil across a vessel branch during a VATS pulmonary resection.*

in 4%<sup>29</sup>. The final 2% of patients have a solitary right pulmonary venous trunk. At the time of resection, it is imperative to watch for the right middle lobe vein when dissecting and dividing the right upper lobe vein. Regarding left-sided pulmonary vein anatomy, 86% of patients have two pulmonary veins, of which 33% share a common ostium<sup>30</sup>. The remaining 14% have a single left-sided pulmonary vein (Figure 1). There are certainly less common right- and left-sided anatomic variations of pulmonary venous anatomy, which again highlights the extreme importance of preoperative imaging studies.

## Surgical Technique

Thoracic vascular dissection, particularly when performed via a VATS approach, must be done in a meticulous fashion to ensure the creation of an adequate plane for unrestricted passage and firing of staplers. Notably, stapler introduction is a common mechanism of vascular injury, and the primary surgeon must have refined his or her technique to minimize complications.

A stapler guide, red rubber catheter, or Penrose drain may be utilized to guide the stapler's anvil through the appropriate tissue plane once the dissection is complete (Figure 4). Periodically silk sutures or vessel loops are utilized intracorporeally to maximize potential space for safe anvil passage around hilar structures (Figure 5).

A refined stapling technique is also imperative to intraoperative VATS lobectomy safety. The stapler must be properly aligned with the created tissue plane to avoid placing undue tension and traction on adjacent vascular structures during deployment. Furthermore, vascular clip placement should generally be avoided to prevent interference with stapler firing later in the case<sup>31</sup>.

## Device Troubleshooting

Most intraoperative device malfunctions are due to operator error rather than a true equipment failure<sup>19</sup>. As the primary surgeon, it is critical to be familiar with equipment and its various settings to avoid complications. Developing a sense of haptic feedback, visual cues, and traction on vessels are all important skills for a successful VATS surgeon.

The number and distribution of pulmonary veins is also variable between individuals. Concerning right-sided pulmonary venous drainage, 71% of patients have two pulmonary veins<sup>28</sup>. The middle lobe vein joins the superior pulmonary vein in 68% and the inferior pulmonary vein in 3% of cases. Another 28% of patients have between three and five pulmonary veins. Three trunks are present in approximately 10% of patients and 4-5 trunks

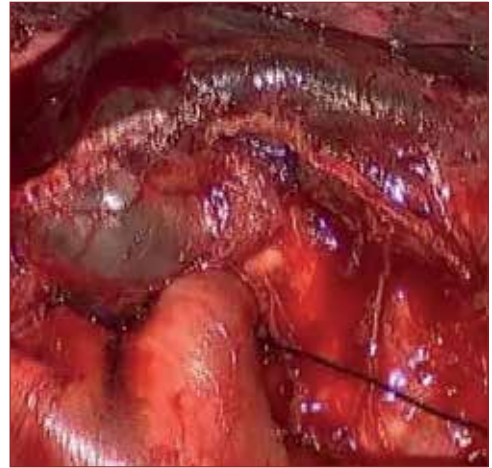


Most device-related complications involve staplers. These typically consist of poor or incomplete seal formation, true device failure, suture line separation, improper firing, and sticking of the various components of the device on others. The three most common stapler-related malfunctions leading to intraoperative complications are partial firing, misfiring, and failure to release the stapling mechanism<sup>32</sup>.

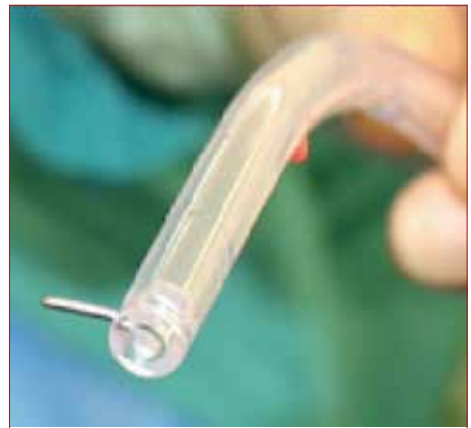Certainly, many VATS staplers have technical limitations. The advent of angled staplers has allowed poor port placement to be more easily overcome. It also permits the surgeon to pass the device around a tubular structure, something that is more challenging with a linear stapler. However, the ability to easily pass a stapler around a dissected structure does not ensure that it will fire easily or without applying tension to adjacent anatomy. This can be made easier by using a curved tip, angled stapler or placing a stapler guide, red rubber catheter, or Penrose drain on the stapler anvil to guide the device through the appropriate plane (Figure 4). Passing a stapler through a dissected plane from a different angle may allow it advance easily via the initial approach, even if this means placing additional ports. There are now 5mm platform staples available, locking clips, and even energy sources that are now replacing some of the larger staples.

Nevertheless, extreme caution should be exercised when passing a stapler around pulmonary vessels, particularly at the hilum, as there is a risk of significant injury with undue torsion and manipulation. Even away from the hilum, the tension applied with the firing of a stapler can tear smaller vessels. As such, it is imperative that the surgeon be mindful of the retraction forces he or she applies during staple ligation to avoid a vascular injury. Releasing tension, visually observing the staple line prior to retracting the stapler, and of course avoiding trauma to the staple line after firing are important aspects of safe stapling.

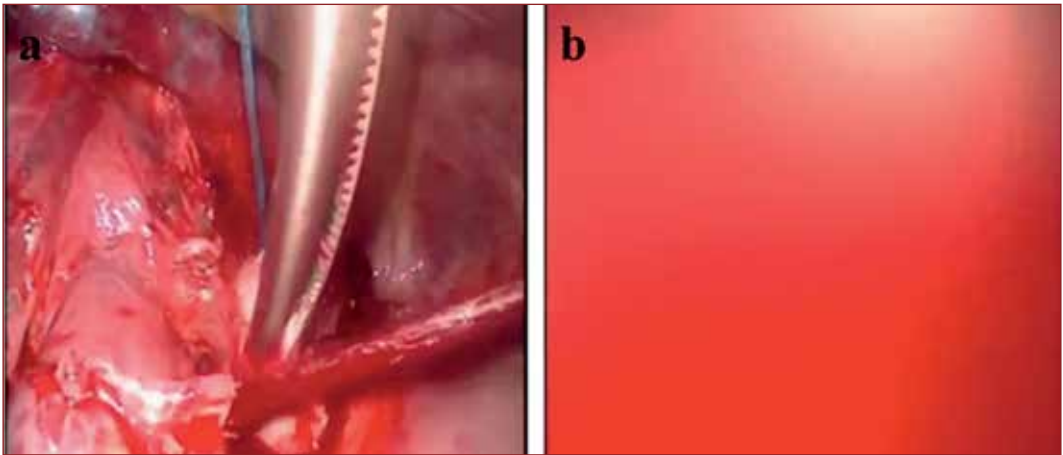
Staple line oozing is a common complication in both VATS and open lobectomy, and is usually adequately treated with application of direct pressure with a sponge stick, using a tonsil sponge<sup>33</sup>. Beware of using the sucker tip as a staple can be easily caught, and the instrument then becomes a weapon (Figure 6). Exposing entry and exist points and testing passage with straight clamps and enlarging stapler paths helps facilitate stapler safety.



*Figure 5: Passage of a silk suture behind a pulmonary vessel branch to help maximize potential space for safe stapler anvil passage during a VATS resection.*



*Figure 6: A surgical clip caught in the end of a VATS suction catheter, which can now act as a dangerous weapon and cause significant injury to bilar structures.*



*Figure 7: a) Overly aggressive dissection and improper tension placement on a pulmonary artery branch during a VATS resection, causing vessel rupture and subsequent bleeding. b) Inadequate hemostasis has rapidly obscured thoracoscopic visualization of the surgical field.*

## Initial Haemorrhage Control

The mainstay principles of intraoperative pulmonary haemorrhage focus upon obtaining immediate vascular control and adequate visualization<sup>16</sup>. If control is easily obtained, the primary surgeon's experience and discretion should determine whether a VATS approach is still pursued or if the conversion to a thoracotomy is made. Certainly, if neither control nor visualization can be readily accomplished during a VATS case, the procedure should be immediately converted to a thoracotomy (Figure 7).

During dissection of pulmonary artery branches, injury can often be avoided by limiting dissection at vessel branch points and avoiding significant manipulation of distal vessel segments, moving in from the artery and staying in the plane of Leriche makes for a safer dissection. However, if a possible pulmonary vessel bleed is encountered during dissection of an overlying bronchus, gentle pressure is immediately applied to the anterior structure with a sponge stick to tamponade the bleeding. Again, the sponge stick should be created with a tonsil sponge (Figure 8). Full Ray-Tec sponges (Pearson Surgical, Sylmar, CA) are difficult to introduce between the closed ribs of a utility incision, and a loose sponge rarely provides adequate tamponade. A smaller peanut sponge improperly applied is small enough to enlarge a pulmonary artery tear rather than control it. In some circumstances, adjacent lung parenchyma may be used to tamponade a bleeding vessel. Fortunately, this approach is usually sufficient given the low pressure of both the pulmonary arterial and venous systems. Another option for haemorrhage control is a topical haemostatic agent and application of direct pressure, which can also be useful in combination. Notably, clamping the pulmonary artery at the site of injury will often worsen the tear and cause further bleeding.

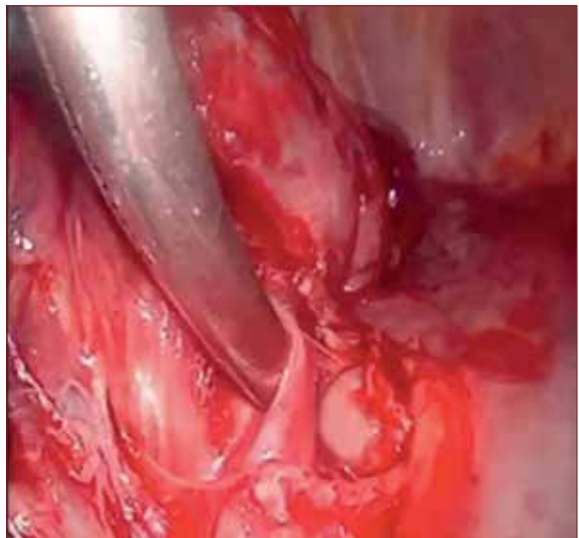
If an emergency thoracotomy is required, a hand can often be placed across the hilum to prevent haemorrhage until the patient is adequately resuscitated (Figure 9). It is imperative to notify the anaesthesia and operating room teams about a probable arterial bleed as soon as possible and the potential imminent conversion to a thoracotomy. Appropriate large bore intravenous access should be ensured prior to any further manipulation of the bleeding vessel in the event the injury is exacerbated during a re-attempted dissection<sup>34</sup>.



However, prior to proceeding further in the case, the surgical team must have a definitive plan for haemorrhage control, either via VATS or conversion to thoracotomy. Certainly, there are arguments against proceeding with further dissection as planned in the setting of a pulmonary artery bleed, namely that ongoing manipulation of the artery and its adjacent hilar structures either via instrument passage or applied tension or torque can lead to a more significant injury that is more difficult to access, control, and ultimately repair. It is also imperative that adequate time be allowed to achieve haemostasis.

However, if a repeat attempt at dissection is to be attempted, the surgeon should consider proceeding to a different step of the operation. If not already performed, it may be helpful to open the fissure to approach the injured pulmonary artery branch from a different angle. It is also sometimes beneficial to open the pericardium to preemptively gain proximal control by placing a vessel loop or clamp around the main pulmonary artery prior to proceeding with further dissection.

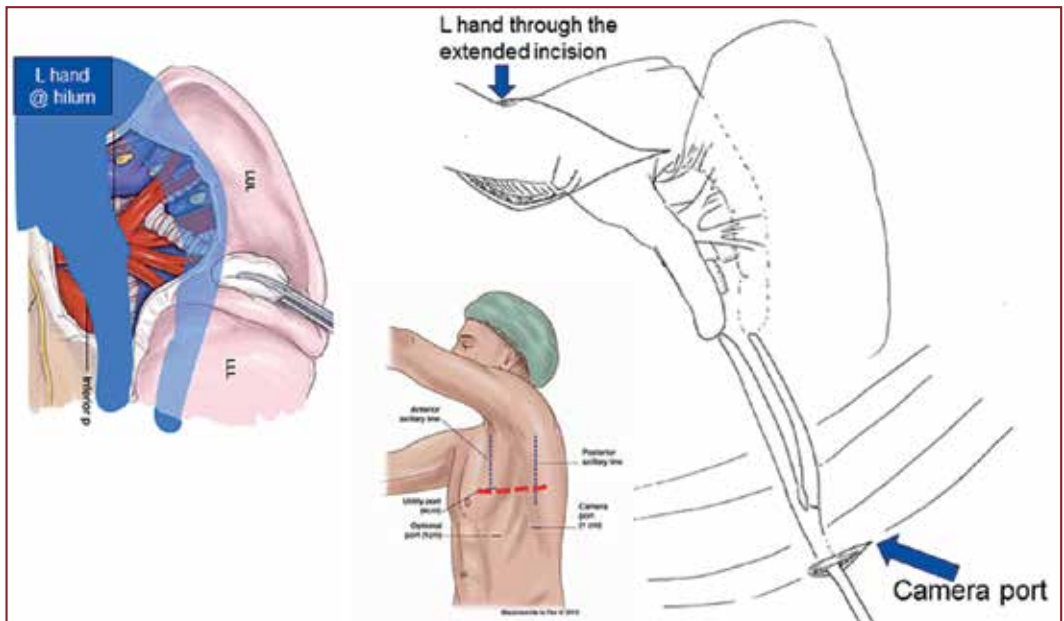
Regardless of the repair approach taken, the surgeon needs to consider his or own experience and expertise in choosing a strategy. It has been demonstrated that with increased VATS experience, thoracic surgeons are less likely to need to convert to a thoracotomy for pulmonary vascular bleeding. Nevertheless, most experts strongly recommend conversion from VATS to thoracotomy for major bleeding complications, particularly those related to the pulmonary artery. There are demonstrated limitations of VATS in managing vascular injuries, namely that adequate tamponade sacrifices adequate visualization and vice versa. Sufficient vascular control may require certain instrument placement and positioning, which can prevent further repair of the injury. Another significant limitation of VATS is visualization, particularly during bleeding events. It can be helpful to pull the thoracoscope back into the port to gain a wider view of the surgical field to be aware of other parts of the chest that are otherwise unseen.



*Figure 8: Proper application of a tonsil sponge stick to achieve adequate hemostasis after a vascular injury sustained during VATS pulmonary resection.*

Proximal control of a pulmonary artery bleed can be achieved in a number of ways via a VATS approach. Passage of a vessel loop or umbilical tape with a tourniquet twice around the main pulmonary artery and gentle application of tension often allows for good vascular control in addition to further operative dissection<sup>35</sup>. If necessary, this can even be performed intrapericardially for complex or more proximal injuries. So long as this process does not exceed 10 minutes in duration, systemic heparinization is not necessary<sup>35</sup>.

Distal vascular control is typically far more straightforward as it can be directly performed on the vessel of interest<sup>35</sup>. Back bleeding can also be controlled by isolating the pulmonary vein.



*Figure 9: Appropriate hand and straight vascular clamp placement for hilar control during conversion from VATS to thoracotomy. The hilum is controlled between the thumb and four fingers to achieve initial hemostasis. A straight vascular clamp is then passed through the VATS camera port and the tips approximated to the thumb and forefinger, which can then act as guides to direct the clamp across the hilum as the hand is removed. Placement of the clamp through the camera port allows for sufficient control without sacrificing visualization or access via thoracotomy.*

## Vascular Repair Considerations

Fortunately, most pulmonary vasculature injuries can be repaired primarily with a permanent monofilament suture. It is paramount, however, that the vessel lumen is not excessively narrowed to avoid immediate or delayed thrombosis, particularly with pulmonary artery repair<sup>36</sup>.

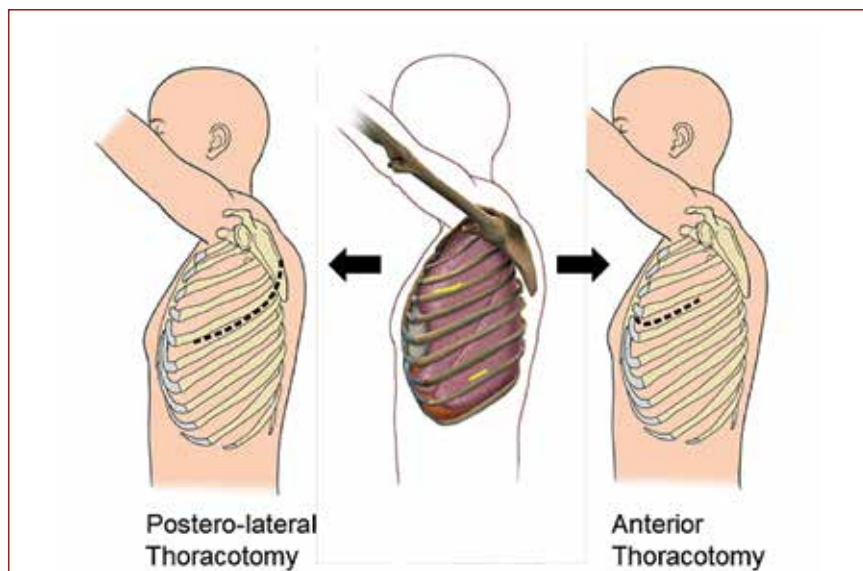
Vascular injuries involving less than 30% of the vessel circumference can be repaired primarily as discussed above. Those injuries involving between 30% and 50% of the vessel circumference can be repaired with a patch graft made with autologous vein, autologous or bovine pericardium, or a prosthetic material<sup>34</sup>. Patch grafts may be advantageous because they can readily be tailored to the specific defect for which they are utilized. Finally, repair of injuries with greater than 50% circumferential involvement necessitates an end-to-end anastomosis, an interposition graft, or vessel ligation<sup>19</sup>. Conduits used in this fashion are typically created from autologous pericardium, autologous pulmonary vein, or polytetrafluoroethylene (PTFE). It is imperative that the surgeon pays close attention to the length of the graft, as longer grafts are more likely to kink or rotate inappropriately following lung re-expansion<sup>37-41</sup>.

If there is a simultaneous bronchial injury, an intercostal muscle flap may be used as an interposition graft between the bronchus and vascular repair to avoid the formation of a broncho-arterial fistula.

Lastly, complex pulmonary vein repair is periodically necessary, and almost always requires conversion to thoracotomy. This complication is most closely associated with stapling across the common trunk of the left pulmonary vein. Once adequate control is achieved, this is typically repaired via a primary end-to-end anastomosis, an autologous or bovine pericardial patch, or the use of a vein cuff left over from the pulmonary vein attached to the resected lobe<sup>36, 42, 43</sup>. As it is with most complications, it is better to develop a habit of identifying the pulmonary vein branches to be preserved prior to stapling, thus preventing injuries from the start.

## Conversion from VATS to Thoracotomy

The decision to convert a VATS lobectomy to a thoracotomy for intraoperative complications is one that is best pursued earlier rather than later<sup>31, 44</sup>. This certainly depends on the individual surgeon and his or her experience and comfort level with minimally invasive vascular repairs. Certainly, the most conservative approach is to convert to a thoracotomy, although conversion rates have been shown to decrease with increased VATS experience<sup>44</sup>. Most emergency conversions occur due to bleeding or stapler misfiring whereas planned conversions tend to be due to anatomic considerations such as large tumour size<sup>11</sup>. The decision to electively convert from VATS to thoracotomy should also be based upon individual limits of time, dissection ability, and failure to progress with the procedure. Conversion from VATS to thoracotomy is associated with prolonged operative time, increased blood transfusion incidence and volume requirements, and longer length of hospital admission as well as an increased incidence of postoperative arrhythmias, pneumonia, and respiratory failure when compared to VATS lobectomy<sup>11</sup>. Complication rates after conversion are similar to those seen with open lobectomy.



*Figure 10: VATS conversion can be safely and efficiently performed through either a traditional posterolateral thoracotomy through the 5th and 6th intercostal space or an anterior thoracotomy through the 4th and 5th intercostal space.*

Reassuringly, there are no adverse effects of conversion on short- or long-term VATS lobectomy outcomes, including survival and disease recurrence<sup>17</sup>.

Regarding thoracotomy approach, the anterior VATS access incision can be enlarged, which is typically more efficient and allows for more emergent access of the hilum (Figure 10). However, a traditional posterolateral thoracotomy incision may also be made. Regardless of the approach chosen in conversion from VATS to thoracotomy, the surgeon must decide the ideal approach to control the vascular injury as well as complete the index resection. It is also helpful to maintain continuous visual monitoring of the surgical field during conversion from VATS to thoracotomy to continually evaluate for any significant changes in the clinical scenario.

Haemorrhage control principles that apply in VATS scenarios are the same in an open procedure, namely, proximal and distal control must be obtained. From there, the injury must be meticulously assessed and subsequently repaired, as discussed earlier.

Deliberate practice for intraoperative emergencies and establishing a clear plan prior to the occurrence of a complication are critical for successful management of VATS lobectomy-related intraoperative crises. Close and ongoing communication with the anaesthesia team is imperative to an optimal outcome from a pulmonary artery bleed. If, upon converting to a thoracotomy, tamponade cannot be achieved or the patient becomes progressively unstable, the hilum should be controlled to allow the anaesthesia provider to resuscitate the patient. In this scenario, ideally only the main pulmonary artery is clamped to avoid damage to other structures. However, the entire hilum can be readily clamped if the pulmonary artery cannot be visualized or adequately controlled on its own. This can be accomplished via the thoracotomy incision or via the original VATS camera port with the application of a straight clamp, utilizing the guide of the surgeon's fingers. Placing this clamp through the camera port allows for adequate hilar control without obscuring visualization through the thoracotomy.

## **Conclusion**

In summary, VATS lobectomy is a technically safe, feasible, and oncologically effective surgical option for resection of lung cancer. Careful analysis of imaging studies and consideration of individual patient factors, paying close attention to anatomic variations that will influence surgical decision-making is important. It is also imperative that the surgeon be aware of potential intraoperative complications, especially those related to bleeding, and have a management protocol in place upfront. Conversion from VATS to thoracotomy should not be viewed as a technical failure, but rather a necessary, more invasive procedural step. While postoperative complication rates are higher in VATS to open conversions, they are similar to those seen in open lobectomy, and are not associated with inferior short- or long-term outcomes, including survival and disease recurrence. Lastly, it is well shown that VATS conversion rates decrease with increased experience, and thus deliberate practice and ongoing active learning are essential to ongoing improvement of technical skills and surgical outcomes.

## References

1. Kirby TJ, Mack MJ, Landreneau RJ, et al. Initial experience with video-assisted thoracoscopic lobectomy. *Ann Thorac Surg.* 1993;56:1248-52.
2. McKenna RJ, Houck W, Fuller CB. Video-assisted thoracic surgery lobectomy: experience with 1,100 cases. *Ann Thorac Surg.* 2006;81:421-5; discussion 425-6.
3. Stephens N, Rice D, Correa A, et al. Thoracoscopic lobectomy is associated with improved short-term and equivalent oncological outcomes compared with open lobectomy for clinical Stage I non-small cell lung cancer: a propensity-matched analysis of 963 cases. *Eur J Cardiothorac Surg.* 2014;46:607-13.
4. Swanson SJ, Herndon JE, D'Amico TA, et al. Video-assisted thoracic surgery lobectomy: report of CALGB 39802—a prospective, multi-institution feasibility study. *J Clin Oncol.* 2007;25:4993-7.
5. Onaitis MW, Petersen RP, Balderson SS, et al. Thoracoscopic lobectomy is a safe and versatile procedure: experience with 500 consecutive patients. *Ann Surg.* 2006;244:420-5.
6. Cattaneo SM, Park BJ, Wilton AS, et al. Use of video-assisted thoracic surgery for lobectomy in the elderly results in fewer complications. *Ann Thorac Surg.* 2008;85:231-5; discussion 235-6.
7. Villamizar NR, Darrabie MD, Burfeind WR, et al. Thoracoscopic lobectomy is associated with lower morbidity compared with thoracotomy. *J Thorac Cardiovasc Surg.* 2011;23:191-5.
8. Paul S, Altorki NK, Sheng S, et al. Thoracoscopic lobectomy is associated with lower morbidity than open lobectomy: a propensity-matched analysis from the STS database. *J Thorac Cardiovasc Surg.* 2010;139:366-78.
9. Ceppa DP, Kosinski AS, Berry MF, et al. Thoracoscopic lobectomy has increasing benefit in patients with poor pulmonary function: a Society of Thoracic Surgeons Database analysis. *Ann Surg.* 2012;256:487-93.
10. Berry MF. "Pulmonary Artery Bleeding During Video-Assisted Thoracoscopic Surgery: Intraoperative Bleeding and Control." *Thoracic Surgery Clinics: Management of Intraoperative Crises.* Ed. SH Blackmon and MB Marshall. Vol. 25(3). Philadelphia: Elsevier, 2015. 239-47. Print.
11. Puri V, Patel A, Majumder K, et al. Intraoperative conversion from video-assisted thoracoscopic surgery lobectomy to open thoracotomy: A study of causes and implications. *J Thorac Cardiovasc Surg.* 2015;149(1):55-60; discussion 61-62.
12. Roviario G, Varoli F, Vergani C, et al. Video-assisted thoracoscopic major pulmonary resections: technical aspects, personal series of 259 patients, and review of the literature. *Eur J Cardiothorac Surg.* 2014;45:633-9.
13. Liang C, Wen H, Guo Y, et al. Severe intraoperative complications during VATS lobectomy compared with thoracotomy lobectomy for early stage non-small cell lung cancer. *J Thorac Dis.* 2013;5:513-7.
14. Samson P, Guitron J, Reed MF, et al. Predictors of conversion to thoracotomy for video-assisted thoracoscopic lobectomy: a retrospective analysis and the influence of computed tomography-based calcification assessment. *J Thorac Cardiovasc Surg.* 2013;145:1512-8.
15. Kawachi R, Tsukada H, Nakazato Y, et al. Morbidity in video-assisted thoracoscopic lobectomy for clinical stage I non-small cell lung cancer: is VATS lobectomy really safe? *Thorac Cardiovasc Surg.* 2009;57:156-9.
16. Sawada S, Komori E, Yamashita M. Evaluation of video-assisted thoracoscopic surgery lobectomy requiring emergency conversion to thoracotomy. *Eur J Cardiothorac Surg.* 2009;36:487-90.



17. Jones RO, Casali G, Walker WS. Does failed video-assisted lobectomy for lung cancer prejudice immediate and long-term outcomes? *Ann Thorac Surg.* 2008;86:235-9.
18. Yamashita S, Toukishi K, Moroga T, et al. Totally thoracoscopic surgery and troubleshooting for bleeding in non-small cell lung cancer. *Ann Thorac Surg.* 2013;95:994-9.
19. Villa M, Sarkaria IS. "Great Vessel Injury in Thoracic Surgery." *Thoracic Surgery Clinics: Management of Intraoperative Crises.* Ed. SH Blackmon and MB Marshall. Vol. 25(3). Philadelphia: Elsevier, 2015. 261-78. Print.
20. Villamizar NR, Darrabie M, Hanna J, et al. Impact of T status and N status on perioperative outcomes after thoracoscopic lobectomy for lung cancer. *J Thorac Cardiovasc Surg.* 2013;145:514-20.
21. Watanabe S, Arai K, Watanabe T, et al. Use of three-dimensional computed tomographic angiography of pulmonary vessels for lung resections. *Ann Thorac Surg.* 2003;75:388-92.
22. Fukuhara K, Akashi A, Nakane S, et al. Preoperative assessment of the pulmonary artery by three-dimensional computed tomography before video-assisted thoracic surgery lobectomy. *Eur J Cardiothorac Surg.* 2008;34:875-7.
23. Akiba T, Marushima H, Harada J, et al. Anomalous pulmonary vein detected using three-dimensional computed tomography in a patient with lung cancer undergoing thoracoscopic lobectomy. *Gen Thorac Cardiovasc Surg.* 2008;56:413-6.
24. Akiba T, Marushima H, Harada J, et al. Importance of preoperative imaging with 64-row three-dimensional multidetector computed tomography for safer video-assisted thoracic surgery in lung cancer. *Surg Today.* 2009;39:844-7.
25. Sugimoto S, Izumiyama O, Yamashita A, et al. Anatomy of inferior pulmonary vein should be clarified in lower lobectomy. *Ann Thorac Surg.* 1998;66:1799-800.
26. Endo S, Tsubochi H, Nakano T, et al. A dangerous venous variation in thoracoscopic right lower lobectomy. *Ann Thorac Surg.* 2009;87:e9-10.
27. Asai K, Urabe N, Yajima K, et al. Right upper lobe venous drainage posterior to the bronchus intermedius: preoperative identification by computed tomography. *Ann Thorac Surg.* 2005;79:1866-71.
28. Marom EM, Herndon JE, Kim YH, et al. Variations in pulmonary venous drainage to the left atrium: implications for radiofrequency ablation. *Radiology.* 2004;230:824-9.
29. Akiba T, Marushima H, Odaka M, et al. Pulmonary vein analysis using three-dimensional computed tomography angiography for thoracic surgery. *Gen Thorac Cardiovasc Surg.* 2010;58:331-5.
30. Patel AG, Clark T, Oliver R, et al. Anomalous midline common ostium of the left and right inferior pulmonary veins: implications for pulmonary vein isolation in atrial fibrillation. *Circ Arrhythm Electrophysiol.* 2008;1:407-8.
31. Demmy TL, James TA, Swanson SJ, et al. Trouble-shooting video-assisted thoracic surgery lobectomy. *Ann Thorac Surg.* 2005;79:1744-52.
32. Brown SL, Woo EK. Surgical stapler-associated fatalities and adverse events reported to the Food and Drug Administration. *J Am Coll Surg.* 2004;199:374-81.
33. Yano M, Takao M, Fujinaga T, et al. Adverse events of pulmonary vascular stapling in thoracic surgery. *Interact Cardiovasc Thorac Surg.* 2013;17:280-4.
34. Dunning J, Walker WS. Pulmonary artery bleeding caused during VATS lobectomy. *Ann Cardiothorac Surg.* 2012;1:109-10.
35. Rendina EA, De Giacomo T, Venuta F, et al. Lung conservation techniques: bronchial sleeve resection and reconstruction of the pulmonary artery. *Semin Surg Oncol.* 2000;18:165-72.



36. Flores RM, Ihekweazu U, Dycoco J, et al. Video-assisted thoracoscopic surgery (VATS) lobectomy: catastrophic intraoperative complications. *J Thorac Cardiovasc Surg.* 2011;142:1412-7.
37. Rendina EA, Venuta F, De Giacomo T, et al. Sleeve resection and prosthetic reconstruction of the pulmonary artery for lung cancer. *Ann Thorac Surg.* 1999;68:995-1002.
38. Solli P, Spaggiari L, Grazia F, et al. Double prosthetic replacement of pulmonary artery and superior vena cava and sleeve lobectomy for lung cancer. *Eur J Cardiothorac Surg.* 2001;20:1045-8.
39. Venuta F, Ciccone AM. Reconstruction of the pulmonary artery. *Semin Thorac Cardiovasc Surg.* 2006;18:104-8.
40. Cerfolio RJ, Bryant AS. Surgical techniques and results for partial or circumferential sleeve resection of the pulmonary artery for patients with non-small cell lung cancer. *Ann Thorac Surg.* 2007;83:1971-7.
41. Ibrahim M, Maurizi G, Venuta F, et al. Reconstruction of the bronchus and pulmonary artery. *Thorac Surg Clin.* 2013;23:337-47.
42. Endo T, Tetsuka K, Yamamoto S, et al. Transection of left common pulmonary vein during left upper lobectomy: how should it be reconstructed. *J Surg Case Rep.* 2012 Dec; 2012(12):rjs030.
43. Nakamura T, Koide M, Nakamura H, et al. The common trunk of the left pulmonary vein injured incidentally during lung cancer surgery. *Ann Thorac Surg.* 2009;87:954-5.
44. Yan TD, Cao C, D'Amico TA, et al. Video-assisted thoracoscopic surgery lobectomy at 20 years: a consensus statement. *Eur J Cardiothorac Surg.* 2014;45:633-9.



## Chapter 11

# Complex Minimally Invasive Pulmonary Resections

*René Horsleben Petersen*

---

*“Audaces fortuna juvat”*

## Introduction

Minimal invasive thoracic surgery is becoming the standard of care in an increasing number of thoracic surgery departments around the world. Recently a report from the SCTS database showed that Video Assisted Thoracoscopic Surgery (VATS) included 40% of lobectomies performed in the UK 2014-2015<sup>1</sup>. Some institutions have reported that they perform VATS in 80% of lung cancer cases<sup>2</sup>. The adoption of VATS lobectomy in the UK in recent years has increased rapidly from only 2.4% in 2004-2005<sup>3</sup>. It is well described in the literature, that minimal invasive thoracic surgery has a learning curve<sup>4</sup>. Many surgeons have suggested 50 cases as a threshold for completing the learning curve, but this is probably a simplification. Probably the learning curve is longer and perhaps we are all on a learning curve for the rest of our careers; hopefully, we learn as long as we live. Being confident with easy procedures (Table 1) usually leads the thoracic surgeon to strive for more complex cases (Table 2).

The benefits of VATS compared to the traditional muscle-sparing thoracotomy include: less pain, earlier mobilisation, better shoulder function, better preservation of lung function, shorter length of stay, fewer complications and a better tolerance of adjuvant chemotherapy<sup>5,6,7</sup>. Evidence for this mainly derives from systematic reviews and meta-analyses of retrospective large database series, but recently a randomised controlled trial confirmed some of this data<sup>8</sup>. With these benefits in mind it seems obvious for the thoracic surgeon to expand the indication for a minimally invasive procedure to more complex cases.

*Table 1 Easy VATS cases*

Small peripherally located tumours
Lower lobes, middle lobe
No suspicion of N1 or N2 disease
No adhesions
No emphysema
Slim patients
No co-morbidity

*Table 2 Complex VATS cases*

Positive N1 lymph nodes
Adhesions
Former thoracic surgery on the same side
Former CABG with LIMA
Former TB
Obese patients
Severe emphysema
Severe co-morbidity
Former radiation
Single stage N2 disease
Pneumonectomy
Bronchial/vascular Sleeve resections
Down-staged tumours after chemo-radiation

## Adhesions secondary to inflammatory disease or prior surgery

In patients with a prior inflammatory infection, adhesions in the entire thoracic cavity are frequent. This may be cumbersome and time consuming and the thoracic surgeon might be tempted to convert to a thoracotomy. But with some experience adhesiolysis by VATS can be done safely. The angulation of a 30-degree thoracoscope exposes the thoracic

cavity better than in open surgery. Together with the magnification and the light source it becomes easier to perform an atraumatic adhesiolysis. This is important to reduce blood loss and minimise air leaks. Patients with prior tuberculosis or aspergillosis can be a severe challenge, even for an experienced VATS surgeon.

After a prior thoracotomy, it is usual to experience chest wall adhesions below the thoracotomy, and it is recommended not to make the utility incision in that line. Patients with former Coronary Artery Bypass Grafting (CABG) can be a challenge, especially a left VATS upper lobectomy where the left internal mammary artery graft can be adherent to the lung. Great care should be taken not to stretch or injure a patent graft.

## Locally advanced lung cancer

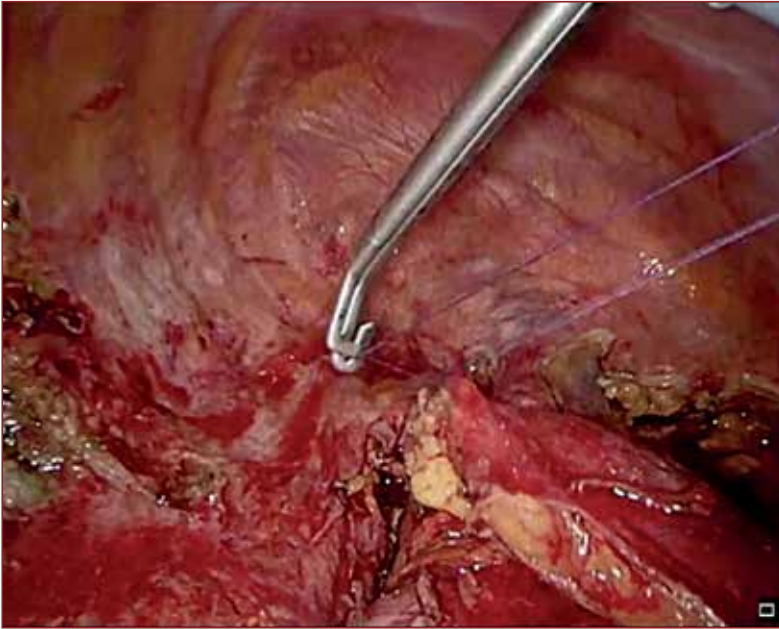
The American College of Chest Physicians Evidence-Based Clinical Practice Guidelines say: “For patients with clinical stage I NSCLC, a minimally invasive approach such as video-assisted thoracic surgery (thoracoscopy) is preferred over a thoracotomy for anatomic pulmonary resection and is suggested in experienced centers (Grade 2C)”. At present no guidelines recommend VATS surgery for locally advanced lung cancer. Patients with suspicious lymph nodes in the N1 position are potentially difficult cases. Fissureless lobectomy has gained widespread popularity, due to less risk of air leak, especially in emphysematous patients. But in patients with suspicion of N1 disease, it is not advisable due to the risk of leaving positive lymph nodes in the staple line. It is important to gain access to all the lymph nodes in the fissure.

For lower lobes, the positive lymph node might involve the pulmonary artery and resection proximal to the involvement may be necessary. But in most cases a cleavage between the artery and the capsule of the lymph node may be found and the lymph node can be resected. It is crucial to dissect inside the vascular sheet. An endoscopic scissor or Ligasure™ (Medtronic, Dublin, Ireland) may aid the dissection. Lymph nodes should always be removed through a protected port with a port protector, to prevent seeding of tumour cells to the thoracic wall. For upper lobes, it may be an advantage to divide the major vessels to the lobe first to reduce the risk of major bleeding. The posterior ascending artery on the right side can be challenging and division with Ligasure™ and clips may be a safer alternative to stapling. A complete removal of lymph nodes and fatty tissue is crucial and if this cannot be obtained, conversion to thoracotomy should be performed. In these patients one must expect and accept a higher conversion rate.

Most patients with confirmed involvement of N2 lymph nodes will be scheduled for neoadjuvant chemo-radiotherapy, but occasionally surgery is performed upfront for non-bulky single station N2 disease, usually 4R on the right side. This is usually not a very difficult task, but again it is important to perform a complete en bloc resection of lymph nodes and fatty tissue, and remove it through a protected port.

## Pneumonectomy

A pneumonectomy is not a very difficult procedure to perform but the indication should be correct. The survival rate after sleeve lobectomy is significantly higher than after pneumonectomy<sup>10</sup>. Every possibility to perform a sleeve or double sleeve lobectomy instead of a pneumonectomy should be pursued. For larger central tumours this will for most centres in the World involve a thoracotomy. But in selected cases where a pneumonectomy is unavoidable, or in case of completion pneumonectomy, this can be performed by VATS. Occasionally it may be necessary to open the pericardium to perform an intra-pericardial



*Figure 1: Pericardial fat pad used to cover the bronchial stump*

resection. It is of utmost importance to keep the bronchial stump short to minimize the risk of bronchial leak. This can be challenging by VATS. A suture proximal in the main bronchus before stapling facilitates traction, and a black stapler reload is recommended for stapling of the main bronchus. A vascularised pericardial fat pad can be prepared and fixed to cover the bronchial stump to prevent a bronchial leak (figure 1).

## **Chest wall resection**

For larger tumours with involvement of three ribs or more it may not seem reasonable to perform a VATS procedure, but in selected cases with involvement of a small area of the chest wall, a VATS procedure may have some advantages for the patient. A complete en-bloc resection may be performed keeping the muscles of the thoracic wall intact. This may potentially lower the risk of pneumonia and respiratory insufficiency and where necessary a Gore-Tex® patch can be applied<sup>11</sup>. Dedicated instruments such as long and flexible rib resectors are necessary for this procedure.

## **Sleeve resections**

In selected patients with central tumours, sleeve lobectomy can be performed by a VATS approach. The advantages compared to pneumonectomy include better preservation of lung function, a better quality of life, and improved long-term survival<sup>10</sup>. Although sleeve lobectomy has been considered a contraindication to thoracoscopic surgery over the past few years, a growing number of institutions are now capable of performing VATS sleeve lobectomy and double sleeve lobectomy using a multiple-port or even single-port approach due to improvements in thoracoscopic instrumentation and surgical skills.



The largest series published so far is from Fujian, China and consist of 32 cases with a mean tumour diameter of 2.8 cm. The technique used for anastomosis was a continuous polypropylene suture and the bronchial anastomosis was started by placing the first suture in the inner aspect of the deepest point of the posterior bronchial wall and knotting it outside the bronchus. A continuous suture was taken on the inner quarter of the posterior luminal circumference followed by the superficial quarter. After completing the posterior wall anastomosis, the sutures were tightened to regulate the tension around the anastomosis. The remaining two quarters of the anterior wall were sutured in the same manner. Finally, the last knot was made on the anterior portion with careful regulation of the suture tightness. In conclusion, they found their modified bronchial anastomosis technique was safe and feasible with satisfactory short-term and long-term outcomes. However, considerable experience in VATS is needed for widespread application of the technique<sup>12</sup>.

## Surgery after neoadjuvant chemoradiotherapy

Anatomical pulmonary resection after downstaging of lung cancers with neoadjuvant chemoradiotherapy is a challenging procedure in open lobectomies as well as by VATS. Especially after radiotherapy, the associated fibrosis makes the hilar dissection difficult and potentially dangerous. It is often difficult to predict the extent of fibrosis but in selected patients, a VATS procedure can be initiated. With careful selection, lobectomy is feasible and safe offering similar disease free and overall survival, but a higher conversion rate is recognised<sup>13</sup>.

## Conclusions

With an increase in experience in VATS lobectomy, thoracic surgeons have been able to expand the indication for a minimal invasive procedure to more complex cases. However, it is important that the surgeon carries out a similar oncological resection to the one that they would have performed with an open procedure.

## References

1. SCTS 2014-15 Thoracic Registry Data. [www.scts.org](http://www.scts.org)
2. McElnay P, Casali G, Batchelor T, et al. Adopting a standardized anterior approach significantly increases video-assisted thoracoscopic surgery lobectomy rates. *Eur J Cardiothorac Surg.* 2014 Jul;46(1).
3. Thoracic Blue Book 2008. [www.scts.org](http://www.scts.org)
4. Petersen RH, Hansen HJ. Learning thoracoscopic lobectomy. *Eur J Cardiothorac Surg.* 2010 Mar;37(3):516-20
5. Yan TD, Black D, Bannon PG, et al. Systematic review and meta-analysis of randomized and nonrandomized trials on safety and efficacy of video-assisted thoracic surgery lobectomy for early-stage non-small-cell lung cancer. *J Clin Oncol.* 2009 May 20;27(15):2553-62. doi: 10.1200/JCO.2008.18.2733. Review.
6. Downey RJ, Cheng D, Kernstine K, et al. Video-Assisted Thoracic Surgery for Lung Cancer Resection: A Consensus Statement of the International Society of Minimally Invasive Cardiothoracic Surgery (ISMICS) 2007. *Innovations (Phila).* 2007 Nov;2(6):293-302.
7. Cheng D, Downey RJ, Kernstine K, et al. Video-assisted thoracic surgery in lung cancer resection: a meta-analysis and systematic review of controlled trials. *Innovations (Phila).* 2007 Nov;2(6):261-92.

8. Bendixen M, Jørgensen OD, Kronborg C, et al. Postoperative pain and quality of life after lobectomy via video-assisted thoroscopic surgery or anterolateral thoracotomy for early stage lung cancer: a randomised controlled trial. *Lancet Oncol.* 2016 Jun;17(6):836-44.
9. Detterbeck FC, Lewis SZ, Diekemper R, et al. Executive Summary: Diagnosis and Management of Lung Cancer, 3rd ed: American College of Chest Physicians Evidence-Based Clinical Practice Guidelines. *Chest.* 2013;143(5\_suppl):7S-37S.
10. Shi W, Zhang W, Sun H, et al. Sleeve lobectomy versus pneumonectomy for non-small cell lung cancer: a meta-analysis. *World J Surg Oncol.* 2012;10:265.
11. Hennon MW, Dexter EU, Huang M, et al. Does Thoracoscopic Surgery Decrease the Morbidity of Combined Lung and Chest Wall Resection? *Ann Thorac Surg.* 2015 Jun;99(6):1929-34; discussion 1934-5
12. Chen H, Huang L, Xu G, et al. Modified bronchial anastomosis in video-assisted thoracoscopic sleeve lobectomy: a report of 32 cases. *J Thorac Dis.* 2016 Aug;8(8):2233-40
13. Park BJ, Yang HX, Woo KM, et al. Minimally invasive (robotic assisted thoracic surgery and video-assisted thoracic surgery) lobectomy for the treatment of locally advanced non-small cell lung cancer. *J Thorac Dis.* 2016 Apr;8(Suppl 4):S406-13. doi: 10.21037/jtd.2016.04.56.

## Chapter 12

# Microlobectomy

*Joel Dunning, Mubammad Izanee Mydin, Mohammed Elsaegh,  
Marco Nardini, Shanda Blackmon, Rene Peterson, Henrik Hansen,  
Bryan Helsel, Malcolm Will and William S Walker.*

---

*“Ancora imparo”*

## Introduction

Video assisted thoracoscopic surgical (VATS) lobectomy was first performed in 1991 in an era of rapid evolution and innovation in Europe and the USA<sup>1-4</sup>. However, the evolution of VATS lobectomy stagnated as the safety and efficacy of VATS lobectomy was questioned<sup>5</sup>.

VATS lobectomy is now in its second era of rapid expansion and innovation. Novel techniques, better instruments and equipment are now facilitating this resurgence. In the UK, lung cancer resection rates have increased by 5.6% between 2011 and 2014. Over the same period, VATS anatomical resection rates have doubled and there is a gradual decline in the open resection rates (SCTS Thoracic book).

Milestones in this new era of VATS lobectomy include newer techniques such as uniportal VATS lobectomy, which is gaining more acceptance worldwide. The initial excellent results in VATS lobectomy were then quickly followed up with more complex procedures such as VATS segmentectomy, bronchial sleeve resection and even vascular sleeve resections as the learning curve improved further<sup>6</sup>.

In parallel, there has been renewed interest in subxiphoid surgery which is not a new concept in thoracic surgery. In 1999 a technique was described for metastasectomy by VATS which included a subxiphoid port to allow manual palpation of all lobes in both hemithoraces without the need for a mini-thoracotomy<sup>7,8</sup>. This subxiphoid approach also enabled mediastinal masses to be removed with a single incision<sup>9</sup>.

The subxiphoid approach has more recently been expanded with novel subxiphoid uniportal approaches for thymectomies and lobectomies from innovators in the Far East<sup>10-14</sup>. Most recently, Jiang and colleagues from the Shanghai Pulmonary Hospital published a series of 153 cases of lobectomies of every lobe and 48 segmentectomies using this approach<sup>15</sup>.

In addition to moving from a 3 or 4 port technique to a uniportal approach and placing the utility incision away from the intercostal space, there have been rapid advances in the range and size of our endoscopic instruments, meaning that 5mm instruments and even 3mm instruments are now available and in routine use<sup>16,17</sup>.

Every innovation carries challenges. As the number of ports reduces and the utility incision changes, the difficulty of the operation may increase, and the safety margins and completeness of lymphadenectomy may change. We sought to investigate a hybrid approach to the novel techniques mentioned above. We attempt to balance the need to create an operation that was familiar to all surgeons and that allowed safe surgery, with our desire to reduce pain and invasiveness for our patients.

## Definition

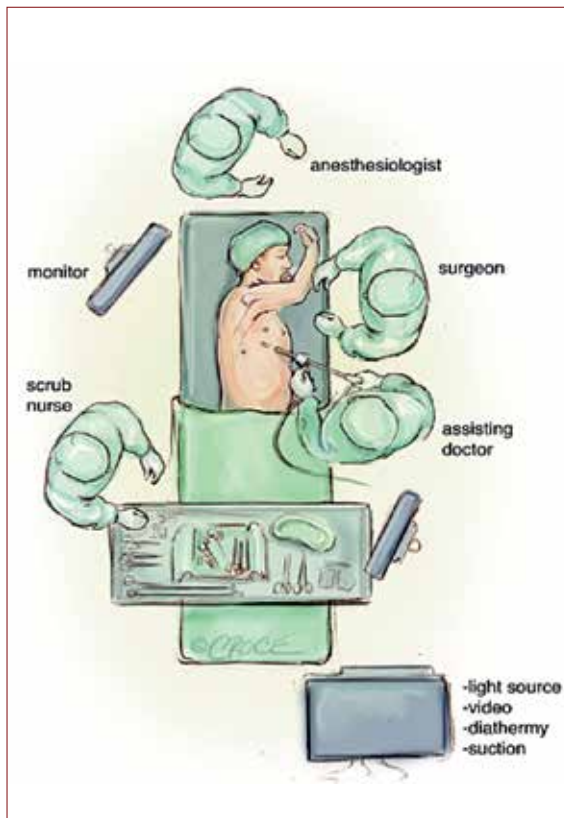
Video-assisted thoracoscopic lobectomy is usually defined as an endoscopic procedure where there is no rib spreading and the procedure is performed with the aid of a thoracoscope and video stack. In the usual 2, 3 or 4 port VATS lobectomies, one of the port sites is used as a utility incision, which facilitates dissection and specimen retrieval. The size of this varies but can be anywhere up to 6 cm.

We define microlobectomy as a VATS lobectomy with intercostal ports that are no greater than 5mm. A 5-mm camera is used along with 5mm instruments. The key to this procedure is the use of a 12-mm subxiphoid port, which functions as the utility incision. We use the 5mm Cardica Microcutter stapler for vascular structures (Cardica Inc, Redwood City, CA)

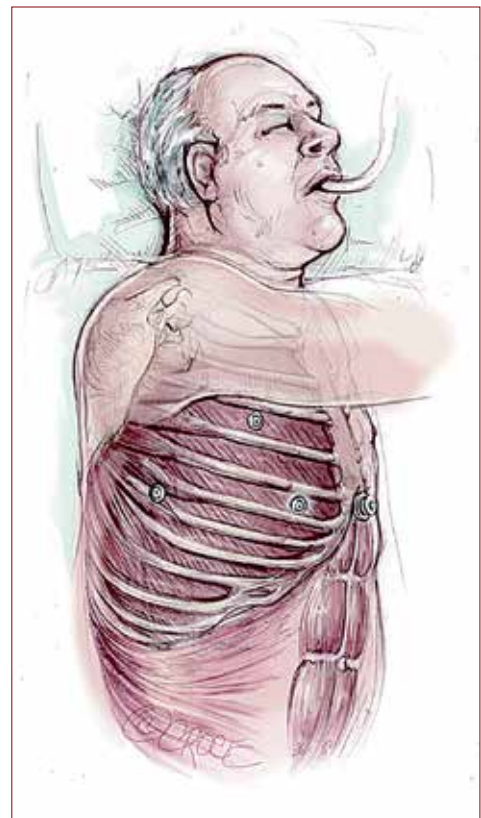but this can be substituted with the standard 12 mm endoscopic stapler which can be used via the subxiphoid utility port. Carbon dioxide insufflation is mandatory.

## Operative technique

The patient is intubated with single lung isolation and positioned in a standard lateral position (Figure 1 and 2). The patient should be positioned in the same position that the operating surgeon is familiar with, for their usual VATS technique. The only modification is that the xiphisternum, costal margins and the midline down to the umbilicus is marked prior to positioning. After turning into the lateral position, good access to the subxiphoid area must also be ensured (Figure 3).

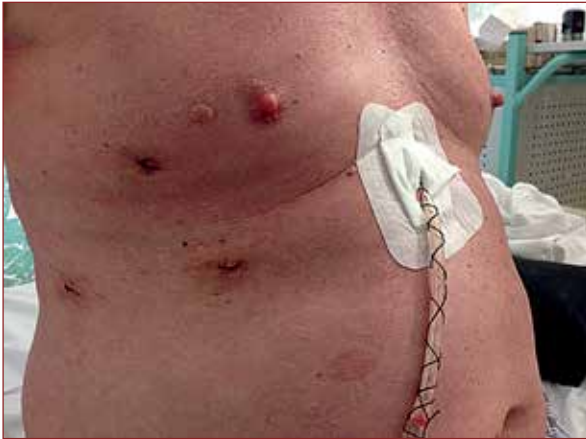

*Figure 1: Theatre set up for microlobectomy  
(Copyright Joel Dunning)*



*Figure 2: Port placements for  
microlobectomy (Copyright Joel  
Dunning)*

For patients undergoing an anterior approach lobectomy, the first port is placed in the 4th intercostal space between the inferior angle of the scapula and the nipple. In a normal VATS lobectomy, this would be the area of the utility incision and in uniportal surgery this is the location of the single incision. For Microlobectomy, a 5mm port is inserted here. Chest entry is gained under vision with the Kii-Fios first-entry port (Applied Medical, California, USA) with CO<sub>2</sub> running at 5 litres per minute (Figure 4). The camera is placed



*Figure 3: Position of the subxiphoid utility incisions and the other three 5 mm ports (Copyright Joel Dunning)*

in the centre of the clear plastic trocar and the port is inserted under vision. As soon as the trocar breaches the pleura the CO<sub>2</sub> pushes the lung away and this can be seen endoscopically. If there are adhesions, these will be seen and the CO<sub>2</sub> will facilitate their separation from the chest wall.

Once the chest has been entered, the hemithorax is insufflated to a pressure of 5-10mmHg. High CO<sub>2</sub> levels may cause hypercarbia, high airway pressures or hypotension so the flow rates may have to be adjusted temporarily to allow these parameters to stabilise.

The camera is then directed down to look at the inferior border of the sternum and the antero-medial diaphragm. A 20mm skin incision is made vertically just below the xiphisternum, then under vision the soft tissue is dissected down to the tip of the xiphisternum which marks the cranial portion of the linea alba. This is incised vertically for 15mm. It is important not to deviate into the rectus abdominis muscle as this will cause unnecessary post-operative pain. A finger is then passed cranially directly posterior to the xiphisternum and up behind the sternum as far as possible. This is similar to the move a surgeon makes prior to performing a sternotomy. The finger is then moved laterally into the hemithorax under direct vision.

Once the pleura is breached this can be followed with a 12mm port. The diaphragm is always well below this entry point due to the CO<sub>2</sub>, and we have not encountered any subdiaphragmatic entries with this method.

After the subxiphoid port has been placed, two further 5mm ports are made according to the usual positioning of the surgeon's further ports. Often this corresponds to the ports described as the standardised anterior approach by Hansen and Peterson<sup>18,19]</sup>, but the operation has also been performed safely using the posterior approach, with the camera port first being placed posterior to the inferior border of the scapula<sup>20</sup>.



*Figure 4: The Kii-Fios first entry trocar*



The operation is then conducted in the usual fashion using 5mm instruments. Retraction can be achieved through the subxiphoid port, and stapling can either be achieved using the 5mm Cardica Microcutter for vascular structures (Cardica Inc, Redwood City, CA), an energy device, or if none of these are available, a 12mm standard stapling device can be used from the subxiphoid port. This port is conveniently located at the anterior end of the oblique fissure on both sides and thus enables good access to the hilar structures for stapling. Further information on the surgical technique and useful instruments can be found at [www.microlobectomy.com](http://www.microlobectomy.com).

At the end of the procedure an Endobag™ (Medtronic, Dublin, Ireland) is placed from the subxiphoid port and then once the specimen is in the bag, under vision, the linea alba is extended as far as necessary to remove the tumour. The chest tube is inserted through the subxiphoid port and this wound is then closed, taking care to suture the linea alba under vision throughout its length to prevent an incisional hernia.

## Post-operative care

Standard post-operative care was implemented, although in many cases clinicians and staff were particularly proactive in early mobilization in response to this change in technique.

To improve post-operative mobilization, PCA pump use was reduced or ceased in favour of oral analgesia, paravertebral catheters were not placed in favour of intercostal local blockade placed at the time of surgery, and later in the series, Heimlich valve drain bags were used instead of underwater sealed drains to promote day of surgery mobilization. This enabled many of our patients to be converted to oral analgesics on day 1 and be discharged home.

## Discussion

Microlobectomy is one of a range of novel techniques currently under evaluation internationally. It has been created by an international group of VATS lobectomy surgeons and has some advantages for experienced VATS surgeons. Firstly, the technique of the lobectomy is not too dissimilar to the more usual VATS lobectomy. Our group has used this technique to perform resections of every lobe (both anterior and posterior approach) and we recommend that surgeons interested in trying this technique place their 5mm ports in the usual positions. We have also performed segmentectomies and sleeve resections safely, and a right pneumonectomy where a subxiphoid extraction was, in our view, particularly advantageous.

The main difference is that the retraction can only come via the subxiphoid utility port as all the other ports are 5mm and will not accommodate more than 1 instrument at a time. However, we feel this is advantageous as there will be potentially less neuropraxia using a 5-mm port as opposed to a 10-mm port. The intercostal spaces are often smaller than 10 mm.

Secondly, the reason for subxiphoid removal of the specimen is to avoid the need for an intercostal utility incision. While these utility incisions are often 6cm or less in the skin, in order to remove tumours of 2-5cm it is invariably necessary to incise the intercostal muscles for 8-10cm to allow the ribs to separate by this amount. Removing a large, air trapped lobe in a small patient, for example, can cause significant neuropathic pain post operatively, especially if accompanied by inadvertent rib fractures.

The advantage of the subxiphoid port is that the linea alba can be incised as far as necessary to remove even quite large tumours. The soft tissues expand more easily in every direction to allow easier removal than from an intercostal space. All incisions cause pain, but any pain from the upper abdomen is in our view more easily tolerated by patients and they are still able to cough without pain and take deep breaths. In addition, the drain is placed subxiphoid post-operatively, which further reduces pain from the intercostal spaces.

Our group uses CO<sub>2</sub> insufflation, which we feel is crucial in allowing safe dissection and placement of a subxiphoid port. It also allows more space in the hemithorax and aids with lung collapse at the start of surgery, especially in patients with air-trapping. Many surgeons do not use CO<sub>2</sub>. After the initial steps of the operation it also becomes less useful and may be turned off, if preferred. Of note our technique is a fully endoscopic technique and therefore forceful or uncontrolled suction may cause lung inflation. We prefer intermittent suction or the use of rolled-up tonsil-swabs to remove small amounts of blood intraoperatively.

There is a wide range of novel instrumentation to allow surgeons to perform less invasive surgery currently. The Covidien (Dublin, Ireland) Single Incision Laparoscopic Surgery (SILS) dissector is a 5mm instrument that can roticulate to 80 degrees. This is particularly useful for dissecting around vessels. The Cardica Microcutter (Dextera Surgical Inc, Redwood City, CA) is a stapling device that has recently received FDA approval. It is licensed for the transection of vessels up to 2mm in clamped wall thickness and is particularly useful for small segmental vessels. In addition to its narrow diameter it is also able to roticulate to 80 degrees. There is now a wide range of high quality 5mm cameras with a resolution not dissimilar to 10mm cameras. While 3D imaging is not yet possible in 5mm we believe that these 5mm cameras are very versatile and suitable for anatomical lung resection. Additionally, for the sleeve resections, 5mm endoscopic needle holders can be used (the sutures can be inserted via the subxiphoid 12 mm port).

In VATS lobectomy, safety is paramount and emergency maneuvers should be discussed in advance and prepared for. A key step in addressing significant bleeding in endoscopic lobectomy is the ability to apply pressure to the area of bleeding with a wide based swab or sponge stick. We routinely use one or two rolled tonsil swabs in the chest. Microlobectomy does not allow for the rapid insertion of a sponge stick, but we find that it is possible to grasp the tonsil swab in the chest and then apply pressure to the area of concern. An alternative method is to grasp the lung and place this over the area of bleeding. If bleeding is controlled, then conversion to thoracotomy can easily be performed. We have also easily converted to the standard VATS approach in bleeding simply by extending the size of the ports and creating a utility incision, and have been then able to deal with bleeding by VATS and complete the operation endoscopically.

We find that adhesions are not a barrier to microlobectomy. The CO<sub>2</sub> allows the separation of all but the densest of adhesions and allows entry into the chest. As the first port has the camera in the trocar, if adhesions are seen, then a sweeping action of this port under vision is a very safe way to create some space in the chest prior to the insertion of further ports. We have yet to convert to standard VATS due to adhesions to complete the case.

As the operation utilises the same view as a surgeon's usual approach, we have found that lymphadenectomy is no different to a standard VATS lobectomy. The nodes may be removed through the subxiphoid port and may be removed in a bag if they are large. The subxiphoid port is also useful for retraction for station 7 lymphadenectomy. A small bag may be inserted

into the chest, then retraction performed until the end of the lymphadenectomy and then the bag removed at the end of this part of the operation.

All operations have weaknesses and microlobectomy is no exception. Using the subxiphoid port for retraction rather than 2nd or 3rd instruments through the utility incision is sometimes cumbersome and some practice and experimentation with 5mm retraction devices is required. Suboptimal retraction can lead to delays in the operation. The closed chest technique does require valved suction and brief bursts of suction, as more prolonged periods of suction does cause lung re-inflation.

Our most important weakness is that we present no evidence that microlobectomy is superior to any other endoscopic lobectomy technique or indeed to a thoracotomy. We believe that at this stage it is for individual surgeons to select their own techniques from the range available. We present this chapter and additional learning resources to enable surgeons to try this method as part of their own journey to find their own optimal technique. This weakness is not new and there is currently no compelling evidence of superiority of any other one endoscopic lobectomy technique over another. Such is the doubt over the superiority of endoscopic lobectomy versus lobectomy by thoracotomy that there are currently several randomised controlled trials recruiting internationally including a large multicentre randomised trial called VIOLET aiming to recruit 495 patients in the UK to answer this question<sup>21</sup>.

## References

1. Rovario G, Rebuffat C, Varoli F, et al. Videoendoscopic Pulmonary Lobectomy for Cancer. *Surg Laparosc Endosc* 1992;2:244-7.
2. Walker WS, Carnochan FM, Pugh GC. Thoracoscopic pulmonary lobectomy. Early operative experiences and preliminary clinical results. *J Thorac Cardiovasc Surg* 1993;106:1111-7.
3. McKenna RJ. Lobectomy by video assisted thoracic surgery with mediastinal node sampling for lung cancer. *J Thorac Cardiovasc Surg* 1994: 107:879-81.
4. Kirby TJ, Rice TW. Thoracoscopic lobectomy. *Ann Thorac Surg* 1993; 56:784-6.
5. Kirby TJ, Mack MJ, Landreneau RJ, et al. Lobectomy--video-assisted thoracic surgery versus muscle-sparing thoracotomy. A randomized trial. *J Thorac Cardiovasc Surg.* 1995 May;109(5):997-1001; discussion 1001-2.
6. Gonzalez-Rivas D, Paradela M, Fieira E, et al. Single-incision video-assisted thoracoscopic lobectomy: initial results. *J Thorac Cardiovasc Surg.* 2012;143: 745-7.
7. Mineo TC, Pompeo E, Ambrogi V, et al. Transxiphoid video-assisted approach for bilateral pulmonary metastasectomy, *Ann Thorac Surg* 1999: 1808-1810.
8. Mineo TC, Ambrogi V, Paci M, et al. Transxiphoid Bilateral Palpation in Video-Assisted Thoracoscopic Lung Metastasectomy. *Arch Surg* 2001; 136: 783-788.
9. Kido T, Hazama K, Inoue Y, et al. Resection of Anterior Mediastinal Masses Through an Infrasternal Approach. *Ann Thorac Surg* 1999;67: 263-5
10. Liu CC, Wang BY, Shih CS, et al. Subxiphoid single-incision thoracoscopic left upper lobectomy. *The Journal of Thoracic and Cardiovascular Surgery* 2014;148,6,3250-3251.
11. Suda T, Ashikari S, Tochii S, et al. Single incision Subxiphoid Approach for bilateral metastasectomy. *Ann Thorac Surg* 2014;97:718-9.
12. Suda T, Sugimura H, Tochii D, et al. Single- port thymectomy through an infrasternal approach. *Ann Thorac Surg* 2012;93:334-6.

13. Liu C, Wang B, Shih C. Subxiphoid single-incision thoroscopic left upper lobectomy. *J Thorac Cardiovascular Surg.* 2014 December; 148(6):3250-1).
14. Chao-Yu L, Cheng-Sun L, Chia-Chuan L. Subxiphoid single-incision Thoracoscopic surgery for bilateral spontaneous pneumothorax. *Videosurgery Mininv.* 2015; 10(1): 125-128.
15. Hernandez-Arenas LA, Lin L, Yang Y, et al. Initial experience in subxiphoid uniportal video assisted thoracoscopy (VATS) for major lung resections. *Eur J Cardiothorac Surg* 2016 Dec;50(6):1060-1066.
16. Sihoe AD. The Evolution of VATS Lobectomy. In: Cardoso P. eds. *Topics in Thoracic Surgery.* Rijeka: Intech, 2011:181-210.
17. Chou SH, Li HP, Lee JY, et al. Needleoscopic video-assisted thoracic surgery for primary spontaneous pneumothorax. *Minim Invasive Ther Allied Technol* 2009;18:221-4.
18. Onaitis MW, Petersen RP, Balderson SS, et al. Thoracoscopic lobectomy is a safe and versatile procedure experience with 500 consecutive patients. *Ann Surg* 2006; 244: 420-5
19. Hansen HJ, Petersen RH, Christensen M. Video-assisted thoracoscopic surgery (VATS) lobectomy using a standardized anterior approach. *Surg Endosc* 2011;25:1263-9
20. Walker WS, Codispoti M, Soon SY, et al. Long-term outcomes following VATS Lobectomy for non-small cell bronchogenic carcinoma. *Eur J Cardiothorac Surg* 2003;23:397-402
21. Lim E, Brush T, Rogers C. 189 Video assisted thoracoscopic lobectomy versus conventional Open Lobectomy for lung cancer, a multi-centre randomised controlled trial with an internal pilot: the VIOLET study. *Lung Cancer* 2016;91(supplement 1):S68 - S69.

## Chapter 13

# Video-Assisted Thoracoscopic Tracheal and Carinal Resection

*Keng Ang, GuiLing Peng, JingPei Li and JianXing He*

---

*“Natura appetit perfectum”*

## Introduction

Video-Assisted Thoracoscopic Surgery (VATS) for tracheal and carinal resection is not commonly performed<sup>1,5</sup>. Even as an open procedure, tracheal and carinal resection can be challenging and demanding for both the surgeon and anaesthetist. In this article, we will share our experience acquired using the VATS approach for trachea/carinal resection, highlighting the key steps and principles that have made this possible.

## Pre-operative assessment and selection

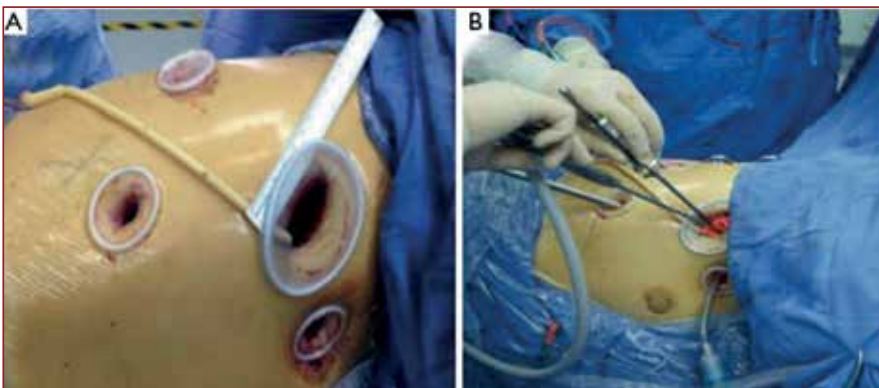
Careful patient assessment and selection is paramount for VATS tracheal/carinal resection to be successfully performed. The typical assessment should include the following:

- thoracic and abdominal contrast computed tomography (CT) with reconstruction of the airway,
- positon emission tomography scan, magnetic resonance imaging of the brain, and bone scintigraphy as required,
- preoperative bronchoscopy with multiple biopsies,
- cardiac assessment (including echocardiogram),
- pulmonary function assessments including transfer factor, ventilation/perfusion (V/Q) scan if pneumonectomy is required

Detailed assessment of the extent of tracheal involvement should be made from the CT reconstruction as well as with bronchoscopy and bronchoscopic biopsies. This is because for VATS resection to be feasible, the airway lesion should not involve  $\geq 4$ cm in length of the trachea otherwise there may be issues with achieving a tension free anastomosis<sup>1</sup>.

## General anaesthesia considerations

Patients are normally anaesthetised with intravenous anaesthetic agents and intubated with a small 6.5mm single lumen endotracheal (ET) tube. The reasons for using a small single lumen tube are, firstly, that it allows more “room” during manipulation for the airway anastomosis and, secondly, it is easier to advance into the distal bronchial airway if required. Depending on the type of airway resection, cross-field ventilation may be used.



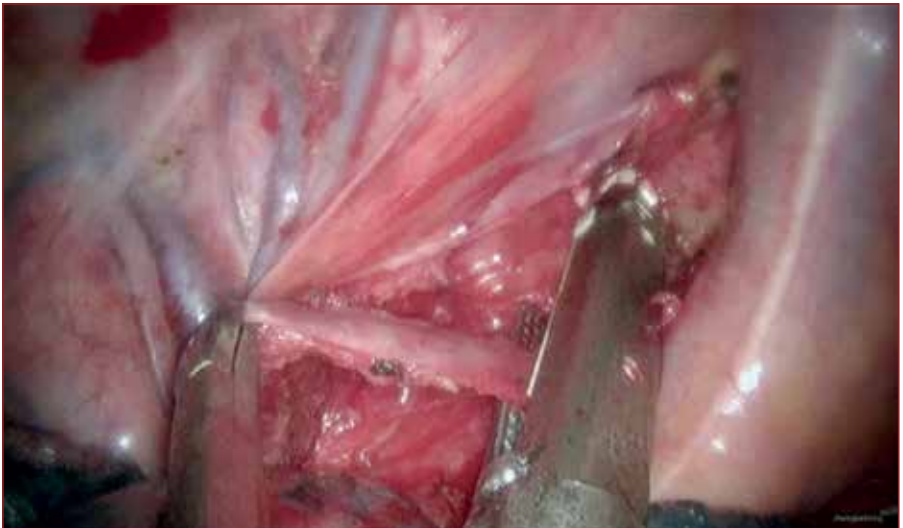*Figure 1: [A] Port Placement. [B] Views of instrumentation and cross-field ventilation (from reference<sup>2</sup> with permission)*



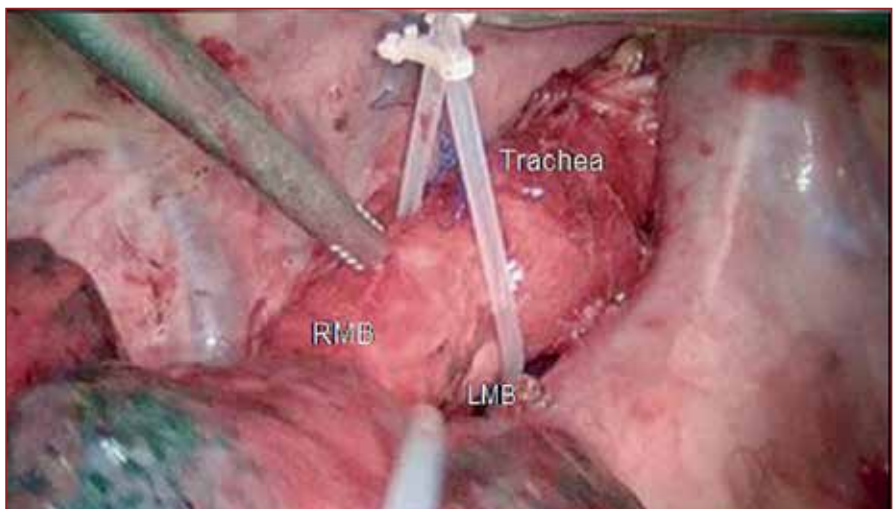
## Surgical considerations in general

The patient is positioned in a left lateral decubitus position, and typically 3-4 ports are used. Typical port placement is shown in Figure 1. The camera port (10mm) is placed at the seventh intercostal space along the right anterior axillary line; while the main 4cm operative port is located at the fourth intercostal space anterolaterally. There is an additional assisting port, at the seventh intercostal space along the right posterior axillary line. Cross-field ventilation if needed can be introduced through either the 4cm main operative port or an optional 10-mm port one intercostal space above the operating port as shown.

In order to dissect the trachea and mobilise it along with its distal extent, it is necessary first to divide the azygos vein (Figure 2) with a vascular stapler, and open the parietal pleura along the lateral border of superior vena cava.



*Figure 2: Division of azygos vein (from reference<sup>3</sup> with permission)*

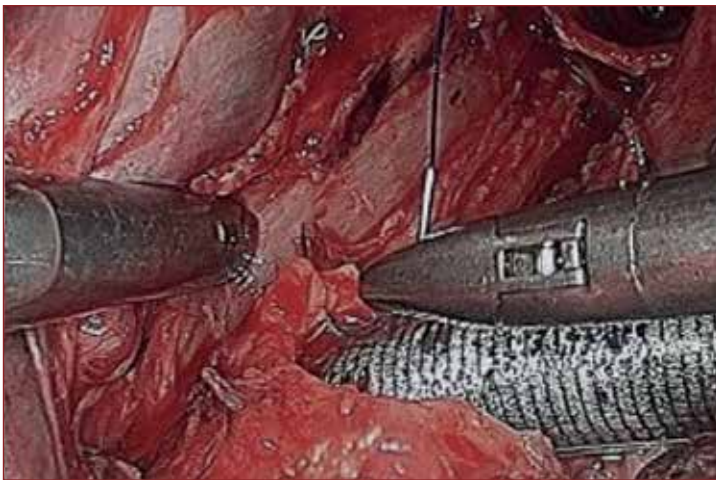


*Figure 3: Operative view: RMB=Right main bronchus; LMB=Left main bronchus (adapted from reference<sup>3</sup> with permission)*

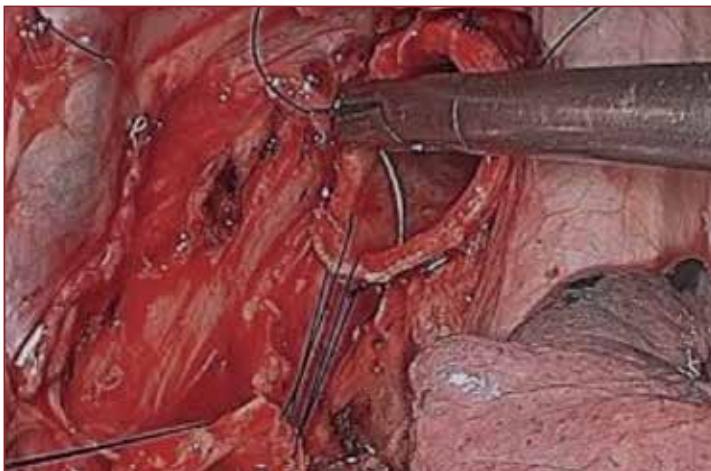
All peritracheal lymph nodes also must be removed. The airway is then mobilised by a harmonic scalpel (Ethicon, Johnson & Johnson Inc, Somerville, NJ, USA) and blunt dissection, avoiding injury to the bronchial blood supply, vagus and right recurrent laryngeal nerve. With these manoeuvres, it is possible to mobilise most of thoracic trachea and both bronchi (Figure 3).

## Tailored approach to tracheal and carinal resections

Broadly speaking, the principle of approach for VATS can be categorised into 3 main groups as summarised in Table 1: (1) those needing only tracheal surgery, (2) those needing complete carinal surgery, and (3) those needing right bronchial and partial carinal surgery. The principles used in open tracheal surgery still apply. They include avoiding disruption to the tracheal vascular supply during the dissection and ensuring that the airway anastomosis is tension free. We also find that it is important to minimise any size



*Figure 4: Cross-field ventilation tube in left main bronchus (from reference <sup>2</sup> with permission).*



*Figure 5: Anastomosis between left main bronchus and trachea – starting from the posterior aspect of the surgical view, using cross field tube (not in view) as retraction (from reference <sup>2</sup> with permission).*

*Table 1: Tailored approach to VATS tracheal/carinal surgery*

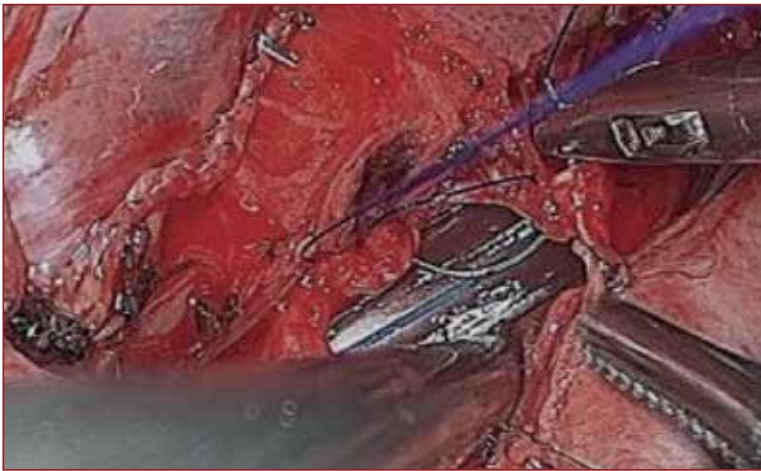<p><b>Surgery requiring tracheal resection &amp; reconstruction only</b></p>	<p><b>Anaesthetic:</b> Cross-field intubation is traditionally used. A small single lumen endotracheal (ET) tube is inserted at the start of the case. Once the lesion is resected, cross-field ventilation can be introduced into the distal airway via the operative port or an additional anterior port.</p> <p><b>Surgical:</b> Anastomosis is usually performed using continuous sutures starting from the posterior aspect of the surgical view. Once the posterior aspect of the anastomosis is completed, the cross-field tube can be removed, and the single lumen ET tube is then advanced to the distal airway to complete the anastomosis.</p> <p>Alternatively, the small single lumen ET tube can be directly inserted into the distal airway. Due to the small diameter of ET, it is possible to perform the anastomosis by working around the ET tube and avoiding the need for cross-field ventilation.</p>
<p><b>Surgery requiring complete carinal resection/reconstruction</b></p>	<p><b>Anaesthetic:</b> Cross-field ventilation as described above is used and the cross-field tube is inserted into the left main bronchus after the carina is resected (Figure 4).</p> <p><b>Surgical:</b> The posterior aspect of the anastomosis between the tracheal and left main bronchus is first completed (Figure 5), leaving an opening anteriorly that matches the size of the remaining right bronchial orifice. Next, the cross-field tube is removed and ET tube is advanced into the left main bronchus (Figure 6). The right bronchus is then anastomosed to this opening, by initially anastomosing the posterior aspect of right bronchus orifice to the inferior border of the opening formed by the superior aspect of the left bronchial free edge (Figure 7). Once this is done, the anastomosis is completed by anastomosing the anterior border of right bronchus to the trachea border as shown in Figure 8.</p> <p>If left bronchial resection is required, extra length of left bronchus can be mobilised by retracting the pleura and superior vena cava towards the sternum, and the anastomosis can be performed as described above.</p> <p>If right pneumonectomy is required, the right pulmonary artery and veins need to be divided before the carinal resection. The left main bronchus is then directly anastomosed to the trachea.</p>
<p><b>Surgery requiring partial carinal resection/reconstruction and right bronchial resection</b></p>	<p><b>Anaesthetic:</b> Cross-field ventilation is not necessary in this case. A small single lumen ET intubation can be advanced directly into the left main bronchus for the procedure.</p> <p><b>Surgical:</b> The key consideration here is to ensure that there is no significant size mismatch between the bronchial and tracheal orifices.</p>



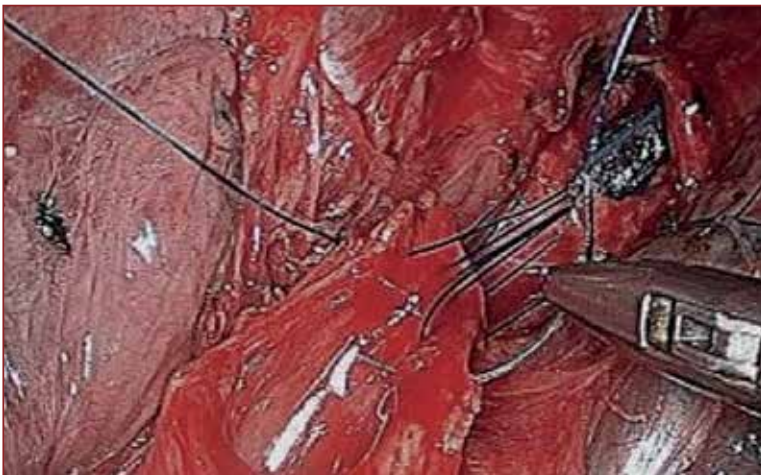
mismatch between the anastomosis of proximal to distal airway<sup>1</sup>. In VATS, the use of a continuous running suture is preferred over interrupted sutures for the anastomosis as it provides better visualisation of the working area.

## Alternative approaches

While cross-field ventilation remains the gold standard for maintaining adequate gas exchange, other techniques such as high frequency jet ventilation have been used to achieve the same objective<sup>1</sup>. More recently, we have also successfully performed VATS carinal resection under non-incubational spontaneous ventilation<sup>3</sup>. The key advantage for this approach is that it offers better visualisation without the interference from the endotracheal tube or cross-field ventilation tubing (Figure 9-10). However, this approach will require an anaesthetic and surgical team that is familiar with such an approach.



*Figure 6: Re-introduction of endotracheal tube into the left main bronchus after completing the posterior aspect of the anastomosis between the left main bronchus and trachea (from reference <sup>2</sup> with permission).*



*Figure 7: Beginning of the anastomosis of right bronchus (from reference <sup>2</sup> with permission).*

## Post-procedure

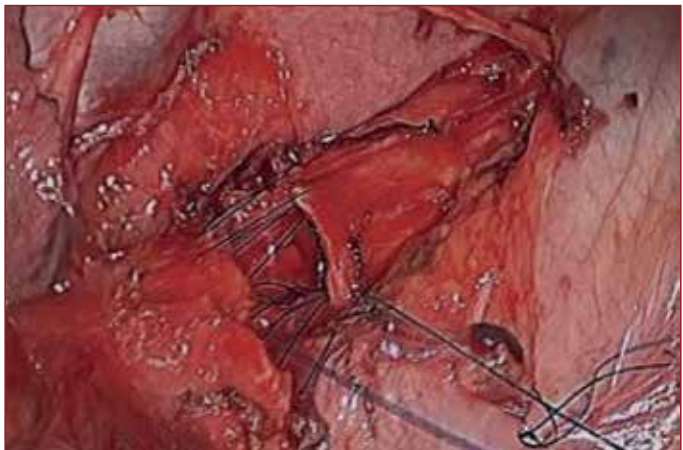
At the end of the procedure the anastomosis is tested for air-leaks by underwater testing (Figure 11). If there is an air-leak, the anastomosis is reinforced with extra sutures until it is air tight.

The chest is usually closed with one or two chest drains. Chin sutures are placed at the end of surgery to maintain the neck in flexion for at least 1-2 weeks to protect the anastomosis. Post-operative fibre optic bronchoscopy is performed if there are any concerns with airway secretions or the condition of the anastomosis. The chest drain is removed once there is no residual air space or effusion except in the case of pneumonectomy where drains are removed earlier.

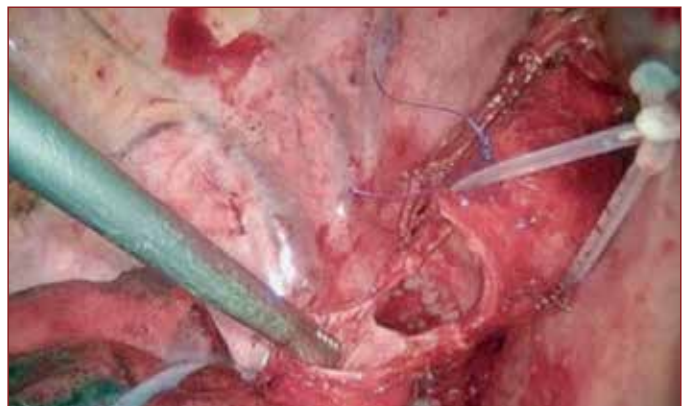
## Conclusion

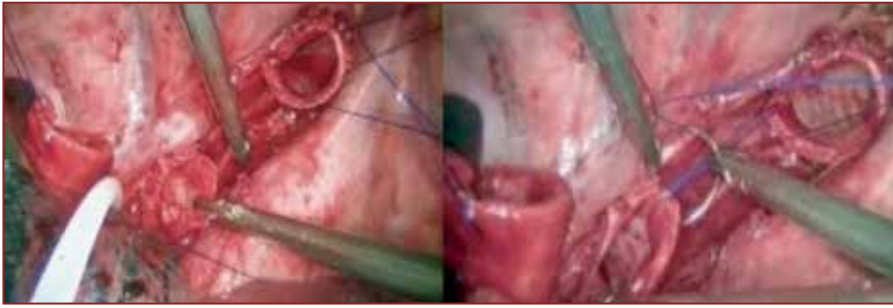
VATS tracheal and carinal resection can be challenging but it can be safely performed with careful patient selection and appropriate skills in video-assisted surgery. Hopefully, this article has provided some useful technical considerations that will be useful for those readers who wish to embark on VATS airway resections.

*Figure 8: Completion of the anterior aspect of the right bronchial anastomosis (from reference <sup>2</sup> with permission)*

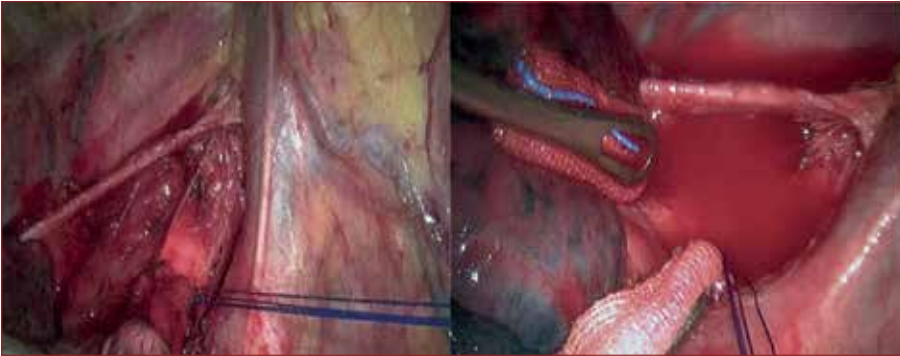


*Figure 9: Surgical view of airway once it is opened, when performed using non-intubational spontaneous ventilation: The trachea was retracted by a sling, while the right bronchial orifice was retracted by the VATS suction device. The left main bronchial opening can be seen between the trachea and right bronchial orifice. (from reference <sup>3</sup> with permission)*





*Figure 10: Surgical view (left) when the carina was resected, and (right) at the beginning of the anastomosis of the left main bronchus to trachea. (from reference <sup>3</sup> with permission)*



*Figure 11: (Left) Completion of anastomosis; (right) intra-operative check for air leak (from reference <sup>3</sup> with permission).*

## References

1. Li J, Wang W, Jiang L, et al. Video-Assisted Thoracic Surgery Resection and Reconstruction of Carina and Trachea for Malignant or Benign Disease in 12 Patients: Three Centers' Experience in China. *Ann Thorac Surg.* 102(1): p. 295-303.
2. He J, Wang W, Li J, et al. Video-assisted thoracoscopic surgery tracheal resection and carinal reconstruction for tracheal adenoid cystic carcinoma. *J Thorac Dis.* 8(1): p. 198-203.
3. Peng G, Cui F, Ang KL, et al. Non-intubated combined with video-assisted thoracoscopic in carinal reconstruction. *J Thorac Dis.* 8(3): p. 586-93.
4. Nakanishi R, Yamashita T, Muranaka K, et al. Thoracoscopic carinal resection and reconstruction in a patient with mucoepidermoid carcinoma. *J Thorac Cardiovasc Surg.* 145(4): p. 1134-5.
5. Jiao W, Zhu D, Cheng Z, et al. Thoracoscopic tracheal resection and reconstruction for adenoid cystic carcinoma. *Ann Thorac Surg.* 99(1): p. e15-7.



## Chapter 14

# Training in VATS Lobectomy

*Alberto Sandri, Michele Salati, and Alessandro Brunelli*

---

*“Integros haurire fontes”*

## Introduction

Video-Assisted Thoracoscopic Surgical (VATS) lobectomy is currently the recommended surgical approach for early stage lung cancer<sup>1</sup>. Its potential benefits compared to open lobectomy include reduced postoperative morbidity and mortality, decreased in-hospital stay and an at least equivalent oncological result<sup>2-8</sup>. It is due to these reasons that VATS lobectomy has gained an increasing interest among thoracic surgeons, who by the start of their specialty training strongly feel the need for specific training in this approach. It is envisaged that this will soon become a prerequisite for the next generation of thoracic surgeons.

Presently, a certified training programme in VATS lobectomy is not available. Surgeons attend training courses but are usually not surgically involved during these courses. Many surgeons are self-taught, as happened historically to those who pioneered this approach only gaining experience and confidence over the years<sup>9-10</sup>. However, this trend needs to be reformed owing to the highly technical and complex nature of the VATS approach, which if utilized by inexperienced surgeons has the potential to lead to major intraoperative complications<sup>11</sup>. Formal structured training in VATS lobectomy is needed to ensure patient safety and quality control.

## Feasibility of VATS Training

One of the main issues regarding VATS training is its feasibility. The difficulty in acquiring appropriate skills with this technique needs to be made reproducible for all surgeons. Ferguson and Walker addressed the feasibility of developing a VATS lobectomy programme and showed that this can be safely taught to senior trainees in thoracic surgery through appropriate senior supervision, without affecting mortality, blood loss or postoperative stay<sup>10</sup>. Furthermore, the authors suggested that training in VATS should be coordinated at a national level to facilitate standardization of this procedure. Training programmes are currently not standardized and differ from centre to centre, both at national and international level due to many reasons, including the small number of thoracic surgeons performing VATS lobectomies<sup>12</sup>. The fact that not all surgeons are suitable to train other surgeons despite their skills and that only few centres routinely perform VATS lobectomy procedures, has led to an overall training discrepancy.

Furthermore, the main aim of training is not just teaching how to perform a VATS lobectomy, but to let the training surgeon gain independence and self-confidence throughout the procedure, which in time will let them perform more challenging cases safely. Standardization of training will implement a uniform and stepwise approach leading to a reduction or elimination of errors, which would ultimately translate into increased procedural safety, fewer intraoperative complications and conversions, shortened operative times and lower postoperative morbidity/mortality<sup>13</sup>.

## Is experience in open lobectomy necessary?

Another aspect which has been investigated by several authors is whether VATS lobectomy should be started only after having gained sufficient experience in open lobectomy<sup>14-16</sup>. Most studies addressing this support the concept that even surgeons with limited experience in open lobectomy can safely perform VATS lobectomy. Surgical training has been found to be associated with an elevated conversion rate, but not with operative or postoperative metrics such as operative time, blood loss, chest tube duration and postoperative morbidity,

provided the surgeon has specific training in VATS lobectomy<sup>15, 16</sup>. Okyere et al. showed that the learning curve for VATS lobectomy is not affected by prior experience in open lobectomy<sup>17</sup>.

## A stepwise approach

As with every type of major surgery, VATS lobectomy training should proceed in a stepwise fashion. Generally, surgeons approach VATS lobectomy after having gained sufficient experience in other minor VATS procedures, such as operations for pneumothorax, pleural effusion, pleural biopsy and pulmonary wedge resections. This gives the surgeon experience with VATS instruments, thoroscopes and staplers, and also develops his dexterity, orientation and approach to lung exposure. For more senior surgeons who were not specifically trained in VATS lobectomy, this can be more challenging than for trainees in thoracic surgery. Learning opportunities may be limited to informal discussion with other VATS surgeons, study of the surgical literature both in-print and online, and training courses<sup>18, 19</sup>.

In comparison, current trainees in thoracic surgery progress in a stepwise manner firstly by holding the camera then placing ports, dissection of the pulmonary ligament and hilum exposure and only when the surgeon has gained sufficient confidence will they be allowed to proceed to vessel and bronchus dissection and lymphadenectomy<sup>9, 10, 20</sup>. This style of training is perhaps the most widely used because it gives a gradual approach to VATS lobectomy building up confidence in performing the procedure.

The updated European guidelines on structure and qualification of thoracic surgery recently published by the European Society of Thoracic Surgeons state that to be properly trained to perform VATS lobectomies, the trainee should be first exposed to increasingly difficult minor resections<sup>21</sup>. After approximately 100 basic VATS procedures and VATS wedge resections they can start to be trained specifically to perform VATS anatomic lung resections. The trainee should be exposed to at least 25 VATS lobectomies per year.

## Are quality standards affected by VATS lobectomy training?

Concerns have been raised by several authors that the learning curve of VATS lobectomy may affect the quality standards of the unit and ultimately patient safety<sup>15-17, 22</sup>. However, the results of these studies demonstrate that if the training is well-organized, structured and supervised, then quality is not affected.

Billé et al. demonstrated that of 100 patients who underwent VATS lobectomy for lung cancer, 66 were operated by a consultant (Group A) and the rest (n=34) by trainees (Group B)<sup>22</sup>. They were not able to find significant differences in terms of operating time (Group A: 125±30min; group B 133±26 min), conversion rates (Group A: 9.1%; Group B: 8.8 %), incidence of complications (Group A: 36.3%; Group B: 32.3%) and blood loss (Group A: 200±50 ml; Group B: 250±60 ml) between the groups. Median time to drain removal was 3 days in both groups and median hospital stay was also equivalent (Group A: 5.5 days; Group B: 5 days), showing no statistical differences.

Similar results were demonstrated by Wan et al., who compared the outcomes of VATS lobectomies performed by consultants with those by trainees<sup>9</sup>. The conversion rate, mean blood loss, operative duration, hospital stay, duration of chest tube drainage, 30-day mortality and complication rates, were not significantly different between the two groups. These results were related to a single centre retrospective analysis, with intrinsic biases

such as the consultant's decision to select the easier cases for the trainee. However, they showed that in a supervised environment, trainees can safely perform VATS lobectomies without affecting the unit's quality of care.

## **Out-of-theatre training: the role of technology**

In recent years, the impact of technology in thoracic surgery has been dramatic with the internet offering a series of educational opportunities that were once not available. One of the most useful materials is the publication of on-line videos and tutorials, which are readily available for interactive study, allowing every surgeon to review the different VATS operations performed by more experienced surgeons<sup>15</sup>. As suggested by Wan et al., a video library of VATS lobectomies performed can be made readily available, giving the opportunity to review the procedures in high definition, perhaps along with a senior surgeon, in order to critically analyse it and learn those steps that were troublesome at the time of the operation<sup>9</sup>.

One of the most critical aspects of the use of internet material for educational purposes is that many videos are not subject to any peer review or scientific control. Without appropriate critical supervision, a video presenting a procedure containing inappropriate or unsafe surgical steps can lead to catastrophic consequences in the hands of the more inexperienced surgeons. It would appear extremely important to have a central review process organized by a national or international scientific organization to select only those videos which have relevant educational content and are produced at internationally recognized VATS centres. The institution of a specific educational accreditation programme for VATS centres to certify their experience and ability to teach this procedure would thus appear necessary.

Several studies have shown a correlation between technology and its impact in our daily life and social behaviour. Younger surgeons' endoscopic skills have been investigated to find a link to skills when playing video games with some authors showing evidence of this<sup>23</sup>.

The idea of developing VATS simulators arises from the need of learning the lobectomy steps without learning on patients, since it offers the possibility to practice, improve and maintain dexterity with standardized experiences, fidelity and reproducibility<sup>24</sup>. Despite their usefulness, simulators and black boxes have some limitations. Jensen et al. performed the first study describing a commercially available virtual reality simulator for VATS lobectomy assessing surgical skills<sup>25</sup>. Surgeons (n=103) were divided according to the number of VATS lobectomies they had performed and classified as novices, intermediates and experienced; they then all performed a right upper lobectomy on the simulator and answered a series of questions regarding the content validity. The results showed that experienced surgeons thought that the simulator was a useful training tool for novice and intermediate thoracic surgeons, but not very useful as a training tool for experienced surgeons. Furthermore, the VATS simulator metrics could not distinguish between novel, intermediate and experienced surgeons, and made it difficult to compare the skills between surgeons. The assessment of procedural skills using virtual simulation has already been deemed challenging<sup>26, 27</sup>.

## **Evaluation and certification of VATS lobectomy training**

In surgery, as in any other educational field, the evaluation and assessment of competence is necessary for feedback and to obtain certification. Surgical skills are directly related to

patient safety and postoperative outcomes and formal certification should be considered. However, assessment of surgical skills is not an easy task since it deals with objective and structured judgment, standardized evaluation and entails ethical issues, for example, is it ethical to assess skills on a patient?

As an experienced VATS training centre, the Copenhagen group developed a tool aimed at assessing VATS surgical skills<sup>28</sup>. According to predefined parameters in a five-point rating scale, two examiner senior surgeons independently and blindly judged unedited and anonymous VATS lobectomy videos. Although this tool precluded assessing global performance, it was well-suited to evaluating specific tasks.

The possibility of assessing endoscopic surgical skills through simulation has been mentioned above, since it provides a safe environment, obviates the ethical issue of “learning-on patients” and could certify the out-of-theatre practice hours<sup>29</sup>. Drawbacks of evaluating surgical skill using simulators include: i) the scarce availability of a procedure-specific simulator for each VATS training centre, ii) the difficulty in correlating simulator performance to real world surgical skills and complications, iii) the difficulty or impossibility to assess skills adequately<sup>30</sup>.

## The role of scientific organizations

National and international scientific organizations must play an important role in surgical education. Their aim should be to act as a certifying body acknowledging those centres which have the experience and the organization to train young thoracic surgeons. However, the development of common recommendations on training in Europe is a difficult task. The specific content and organization of the training curriculum depends on the individual national regulations and is also dependent on the specific specialist recognition currently in place in each country (general thoracic, cardiothoracic, thoracic-vascular, general surgery with specific accreditation in thoracic surgery etc.). It will be the task of the European Board of Thoracic Surgery to harmonize the thoracic surgical educational criteria in the coming years and to define a core curriculum which should apply as a common denominator to the different Union Européenne des Médecins Spécialistes-affiliated countries. This obviously applies not only to the specific field of minimally invasive thoracic surgery but also to the whole specialty.

The European Society of Thoracic Surgeons (ESTS) is certainly playing an important role in this regard by working closely with the European Respiratory Society in developing a curriculum for thoracic surgery and thoracic oncology in general (HERMES project). In future, this will represent a base for harmonizing education across Europe. Furthermore, ESTS organises several courses on minimally invasive thoracic surgery and has created a Minimally Invasive Thoracic Surgery Interest Group (MITIG), which is a working group tasked with organising dedicated sessions during the annual meetings, interacting with industry on behalf of ESTS and possibly setting criteria for quality assurance in training of VATS surgery in Europe. The ESTS website contains also a section dedicated to video of VATS procedures which have been selected by an ad hoc committee as having appropriate educational content.

## Recommendations

1. Irrespective of the experience reached in open major lung resection, the training approach to VATS lobectomy should be a stepwise approach.

2. Before starting a VATS lobectomy programme, a thoracic surgeon should be competent in simpler minimally invasive procedures such as pneumothorax surgery and wedge resection.
3. When starting a VATS lobectomy programme, it is useful to attend a training course to obtain an overview of the latest surgical instruments, as well as their potential use in different phases of the surgical procedure.
4. The steps for completing a VATS lobectomy procedure should be gradually ascended (port position, hilum exposure, lymphadenectomy, vessel and bronchial dissection), ideally under the supervision of a surgeon experienced in these techniques.
5. Previous experience in open lobectomy could help influence the rate of conversion but not reduce the length of the learning curve.

## Conclusions

Due to the benefits of VATS lobectomy, interest in this approach has rapidly accelerated and the ability to routinely offer VATS lobectomy for early stage lung cancer would now appear necessary. Additionally, being able to perform VATS lobectomy will be a prerequisite for the next generation of thoracic surgeons. Unfortunately, apart some exceptions, the teaching of VATS lobectomy is still not formally and uniformly available in training centres and the need for a standardized educational programme is strongly felt among the thoracic community.

The feasibility of VATS lobectomy programmes has been assessed by several studies and, if properly structured in a supervised setting, does not affect quality standards. The impact of technology on the educational aspect of surgical practice (e.g. social media, internet, web-based content) has been dramatic in recent years. However, technology must be used wisely, ideally peer-reviewed and controlled by boards of experts endorsed by national and international scientific societies. Despite their limitations, the use of enhanced-reality simulators is increasing since they can offer surgeons unlimited hours of out-of-theatre training without the ethical issue of “learning on patients”.

Finally, although surgical skills are difficult to assess reliably, the need for formal certification following VATS lobectomy training is important, both for credentialing and medicolegal purposes. Scientific organization, such as ESTS, will play an important role in standardizing and certifying VATS lobectomy training programmes across Europe.

## References

1. Howington JA, Blum MG, Chang AC, et al. Treatment of stage I and II non-small cell lung cancer: Diagnosis and management of lung cancer, 3rd ed: American College of Chest Physicians evidence-based clinical practice guidelines. *Chest*. 2013 May;143(5 Suppl):e278S-313S.
2. McKenna RJ Jr., Houck W, Fuller CB. Video-assisted thoracic surgery lobectomy: experience with 1,100 cases. *Ann Thorac Surg*. 2006;81:421–426.
3. Walker WS, Codispoti M, Soon SY, et al. Long-term outcomes following VATS lobectomy for non-small cell bronchogenic carcinoma. *Eur J Cardiothorac Surg*. 2003;23:397–402.
4. Roviato G, Varoli F, Vergani C, et al. Long-term survival after videothoroscopic lobectomy for stage I lung cancer. *Chest*. 2004;126:725–732.
5. McKenna RJ, Wolf RK, Brenner M, et al. Is lobectomy by video-assisted thoracic surgery an adequate cancer operation? *Ann Thorac Surg* 1998; 66: 1903-1908.



6. Iwasaki A, Shirakusa T, Shiraishi T, et al. Results of video-assisted thoracic surgery for stage I/II non-small cell lung cancer. *Eur J Cardiothorac Surg* 2004; 26:158-164.
7. Walker WS, Codisopoti M, Soon SY, et al. Long-term outcomes following VATS lobectomy for non-small cell bronchogenic carcinoma. *Eur J Cardiothorac Surg* 2003; 23: 397-402.
8. Sandri A, Papagiannopoulos K, Milton R, et al. High-risk patients and postoperative complications following video-assisted thoracic surgery lobectomy: a case-matched comparison with lower-risk counterparts. *Interact Cardiovasc Thorac Surg*. 2015 Dec;21(6):761-5.
9. Wan IY, Thung KH, Hsin MK, et al. Video-assisted thoracic surgery major lung resection can be safely taught to trainees. *Ann Thorac Surg*. 2008 Feb;85(2):416-9.
10. Ferguson J, Walker W. Developing a VATS lobectomy programme--can VATS lobectomy be taught? *Eur J Cardiothorac Surg*. 2006 May;29(5):806-9.
11. Decaluwe H, Petersen RH, Hansen H, et al. ESTS Minimally Invasive Thoracic Surgery Interest Group (MITIG). Major intraoperative complications during video-assisted thoracoscopic anatomical lung resections: an intention-to-treat analysis. *Eur J Cardiothorac Surg*. 2015 Oct;48(4):588-98.
12. Society of Cardiothoracic Surgery of Great Britain and Ireland, Thoracic Audit. Available online: [http://www.scts.org/professionals/audit\\_outcomes/thoracic.aspx](http://www.scts.org/professionals/audit_outcomes/thoracic.aspx).
13. Sandri A, Filosso PL, Lausi PO, et al. VATS lobectomy: the trainee perspective. *J Thorac Dis*. 2016 Apr;8(Suppl 4):S427-30.
14. Yu WS, Lee CY, Lee S, et al. Trainees Can Safely Learn Video-Assisted Thoracic Surgery Lobectomy despite Limited Experience in Open Lobectomy. *Korean J Thorac Cardiovasc Surg*. 2015 Apr;48(2):105-11.
15. Billè A, Okiror L, Harrison-Phipps K, et al. Does Previous Surgical Training Impact the Learning Curve in Video-Assisted Thoracic Surgery Lobectomy for Trainees? *Thorac Cardiovasc Surg*. 2016 Jun;64(4):343-7.
16. Konge L, Petersen RH, Hansen HJ, et al. No extensive experience in open procedures is needed to learn lobectomy by video-assisted thoracic surgery. *Interact Cardiovasc Thorac Surg*. 2012 Dec;15(6):961-5.
17. Okyere S, Attia R, Toufektzian L, et al. Is the learning curve for video-assisted thoracoscopic lobectomy affected by prior experience in open lobectomy? *Interact Cardiovasc Thorac Surg*. 2015 Jul;21(1):108-12.
18. Demmy TL, James TA, Swanson SJ, et al. Troubleshooting video-assisted thoracic surgery lobectomy. *Ann Thorac Surg*. 2005 May;79(5):1744-52.
19. Hirji SA, Balderson SS, Berry MF, et al. Troubleshooting thoracoscopic anterior mediastinal surgery: lessons learned from thoracoscopic lobectomy. *Ann Cardiothorac Surg*. 2015 Nov;4(6):545-9.
20. Reed MF, Lucia MW, Starnes SL, et al. Thoracoscopic lobectomy: introduction of a new technique into a thoracic surgery training program. *J Thorac Cardiovasc Surg*. 2008 Aug;136(2):376-81.
21. Brunelli A, Falcoz PE, D'Amico T, et al. European guidelines on structure and qualification of general thoracic surgery. *Eur J Cardiothorac Surg*. 2014 May;45(5):779-86.
22. Billè A, Okiror L, Karenovics W, et al. Thoracoscopic lobectomy: is a training program feasible with low postoperative morbidity? *Gen Thorac Cardiovasc Surg*. 2013 Jul;61(7):409-13.
23. Rosser JC Jr, Lynch PJ, Cuddihy L, et al. The impact of video games on training surgeons in the 21st century. *Arch Surg*. 2007 Feb;142(2):181-6.

24. Iwasaki A, Okabayashi K, Shirakusa T. A model to assist training in thoracoscopic surgery. *Interact Cardiovasc Thorac Surg*. 2003 Dec;2(4):697-701.
25. Jensen K, Bjerrum F, Hansen H, et al. A new possibility in thoracoscopic virtual reality simulation training: development and testing of a novel virtual reality simulator for video-assisted thoracoscopic surgery lobectomy *Interact CardioVasc Thorac Surg* (2015) 21 (4): 420-426.
26. Van Bruwaene S, Schijven MP, Miserez M. Assessment of procedural skills using virtual simulation remains a challenge. *J Surg Educ* 2014;71:654–61.
27. Våpenstad C, Buzink SN. Procedural virtual reality simulation in minimally invasive surgery. *Surg Endosc* 2013;27:364–77.
28. Konge L, Lehnert P, Hansen HJ, et al. Reliable and valid assessment of performance in thoracoscopy. *Surg Endosc*. 2012 Jun;26(6):1624-8.
29. Tavakol M, Mohagheghi MA, Dennick R. Assessing the Skills of Surgical Residents Using Simulation. *J Surg Educ*. 2008 Mar-Apr;65(2):77-83.
30. Thijssen AS, Schijven MP. Contemporary virtual reality laparoscopy simulators: quicksand or solid grounds for assessing surgical trainees? *Am J Surg*. 2010 Apr;199(4):529-541.

## Chapter 15

# Robotic-Assisted Lobectomy: The Newcastle Experience

*Sasha Stamenkovic, Dharmendra Agrawal and Robert Slight*

---

*“Per aspera ad astra”*

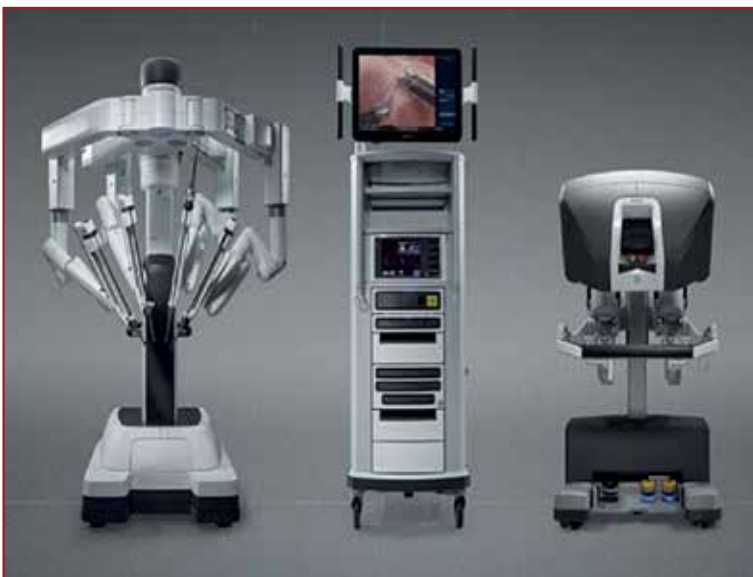## Introduction

Pulmonary lobectomy is an operation that removes a part of lung function from a patient who often has sub-optimal lung reserve, and who may also have cardiovascular morbidity. In addition, some patients have chronic pain requiring regular analgesia. An open operation can result in a reduced quality of life and put them at risk of significant complications, so it has become the Holy Grail of thoracic surgery to perform a minimally invasive operation with few or no sequelae.

There has been an evolution in surgery that has seen procedures moving from open surgery to video-assisted surgery with rigid instruments and 2D laparoscopic/thoracoscopic operations, to 3D high definition (HD) visualization with articulated arms with 7 degrees of freedom of movement that constitutes what we know as robotic-assisted surgery today. Although there have been several types of surgical robots, the da Vinci® platform (Intuitive Surgical, Inc., CA, US) is the most widely used across a variety of surgical disciplines. This platform continues to evolve and at least two other healthcare stakeholders are developing their versions of this. Worldwide, a robotic-assisted operation is performed every minute and there are currently 3600 systems in existence, 10,000 publications and 33,000 surgeons registered as robotic surgeons; three million patients have had robotic operations. For over 15 years, the robotic platform was seen as an extravagance and excessive surgical indulgence, and it is only recently that the surgical community has accepted that robotic surgery is now a routine part of the surgical armamentarium. The evolution of robotic-assisted lung resection surgery promises to provide the minimally traumatic operation that has been sought since the advent of video-assisted operations in the 1990's.

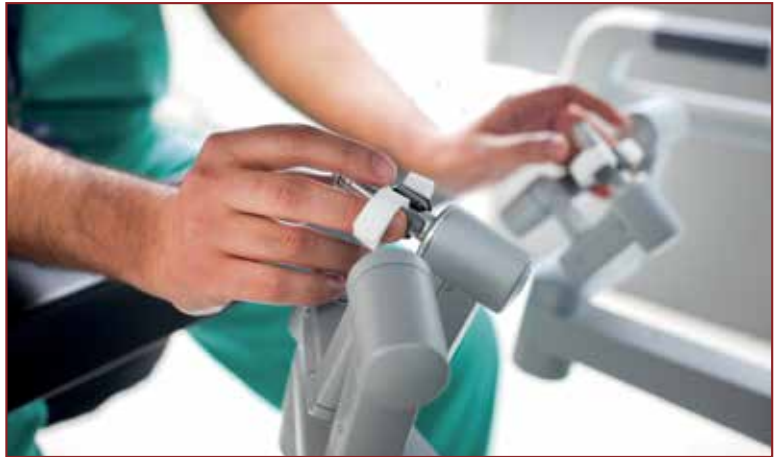## History of surgical robots

Robotic surgical systems were developed originally to assist the surgeon. One of the first approved devices was the endoscopic camera holder, the Automated Endoscopic System for Optimal Positioning (AESOP 2000), in 1994. This was a voice-activated arm under the surgeon's control, attached to the operating table, that positioned the thoracoscope



*Figure 1: The da Vinci® Xi surgical system.*

to allow better control of the visual field. Other robotic devices have followed in the last 20 years - the remote-controlled FIPS endoarm, the passively-moved TISKA (both from the Karlsruhe Institute of Technology, Germany), and the head-movement controlled Endo-Assist (Armstrong Healthcare Co., UK). Zeus (Computer Motion, USA) was an FDA-approved device developed for cardiac surgery in parallel with Intuitive's da Vinci platform, using AESOP as one arm and the other two arms were extensions of the surgeon's right and left arms. In 2003, Zeus production was phased out as Computer Motion was subsumed into Intuitive Surgical, and in reality there has been only one surgical robot in widespread use since then.



*Figure 2: The finger-tip controls for the surgical arms.*

The da Vinci system has three components - the surgeon cart, the patient cart and the vision cart (Figure 1). The surgeon cart is where the surgeon sits in an ergonomic environment with everything moveable to fit him or her. It provides an immersive environment with a stereoscopic binocular visor. There are two master arms which are controlled with finger-tip precision (Figure 2), clutched to allow the surgeon's arms to be in a comfortable neutral position, linked into camera movement/zoom/focus control, and which give 2-stage touch feedback when an energy device or stapler is used. These then connect to the patient cart where one arm carries the camera and the other 3 arms can be employed to "operate" using articulated end-effectors which move like fingers and wrists inside a body cavity, with 7 degrees of freedom, variable motion scaling and tremor reduction. The third arm acts as the surgeon's own assistant. The ports are placed so that they have a fulcrum in the rib space, which is called a remote centre. All gross movement of the arm occurs relative to this limiting the pressure on the intercostal nerve, thereby reducing pain. The vision cart houses all the software to interface and control the light intensity, the CO<sub>2</sub> management, the energy devices and the connectivity to recording devices. There is also technology tracking the position of the instrument tips.

## History of robotic-assisted lobectomy

There has been an evolution of the da Vinci robot over the last 15 years. It started as a 2-arm and camera device, with 2D optics and there was very poor uptake in thoracic surgery as it seemed to offer no advantage over conventional video-assisted thoracoscopic surgery. A few pioneer surgeons adopted robotic lobectomy but many regarded them as maverick operators who were proselytizing their experience.

The pioneer of robotic thoracic surgery was Dr Franca Melfi (Pisa, Italy) who moved from an open technique of lobectomy straight to robotic-assisted lobectomy. She published the use of the new technology in 2002 stating that thoracoscopic procedures using a robotic telemanipulation system may be technically feasible in selected cases and in the hands of experienced thoracic surgeons<sup>1</sup>, and followed this up in 2008 with an article on her learning curve<sup>2</sup>. Dr Bernard Park in Sloan Kettering, New York, USA, published his unit's early experience and concluded that robotic assistance for video-assisted thoracic surgical lobectomy was feasible and safe<sup>3</sup>. Similarly, Dr Robert Cerfolio published his experience in Alabama, USA, in 2009<sup>4</sup>.

In the United Kingdom, Stanbridge in London was the first to perform robotic lobectomy using the da Vinci S system. The robot of today is an extremely sophisticated machine capable of automated docking, dual cavity operating, completely exchangeable port instrumentation and 360-degree rotating staplers. There is an array of instruments that can be used and the thoracic surgical community has started to discuss more widely adopting this platform.

## **The set-up for robotic-assisted lobectomy**

The patient has no additional monitoring compared to a non-robotic procedure and airway isolation is achieved in the same way. There is more breaking of the bed to allow reverse-Trendelenburg to maximise arm movement. The ports are placed under direct vision up to two rib spaces more inferiorly than usual as there is the potential to use carbon dioxide insufflation in this total endoscopic procedure, and the capacity for 30° down camera scopes. If a sub-xiphoid port is to be made, it should be done after sufficient gas insufflation to be safe. Alternatively, an assistant port can be made antero-inferiorly in a rib space, which will be enlarged to retrieve the specimen. Once the ports are placed and docking is achieved, the operation is no different to a VATS lobectomy. Lower lobectomies and left upper lobectomies are more commonly done with a fissure-first technique whereas right upper and middle lobectomies are performed with a fissure-last technique. The latest technology allows port-hopping as all instruments are the same diameter including the camera thus facilitating access to difficult areas. The endo-wrist technology includes a slightly larger stapling device and one must remember that if there is loss of insufflation of the pleural cavity there will be significant movement of anatomy relative to the instruments in the chest.

## **The first UK experience with 4-arm surgical robots**

At the Freeman Hospital in Newcastle in 2013, a decision was made to assess the applicability of a surgical robot for multi-disciplinary teams, and so 5 groups of surgeons (ENT, gynaecology, thoracic, hepatobiliary and colorectal) started an evaluation exercise. In thoracic surgery, a 3-consultant, charge nurse and trainee team with experience in VATS and open lobectomy trained for 2 days at the École Européenne in Paris on a cadaveric model. Risk and clinical governance structures were subsequently devised to allow clinical procedures in Newcastle. We planned to prospectively collect all data from the robotic operations and to use video-recording as much as possible to enable a shorter learning curve. Case observation took place at Dr Melfi's unit in Pisa and straightforward procedures were chosen. We performed the first UK robotic-lobectomy with a da Vinci Si system under the guidance of our proctor in April 2014, with all 3 consultant surgeons and the original team present including the lead cardiothoracic robotic anaesthetist. We set aside a whole day and performed a relatively straight-forward operation (fissure grade 1) with 50ml



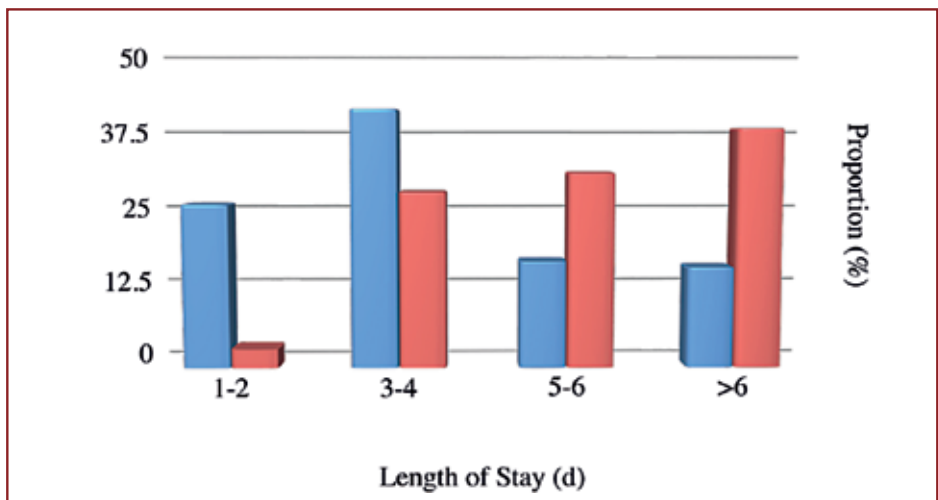
blood loss. This 77-year lady had an all-day operation, had a pain score of 1 out of 10, and went home on the 6th day. At the time, the conventional VATS lobectomy median post-operative length of stay was 4 days and the pain score was approximately 5 making for an encouraging initial experience of the technique. As the programme has matured, we have performed to date over 110 operations using the robotic platform. In year 2 we performed 44 robotic operations (0.84/week), and in year 3 we performed 1.6 per week.

## Lessons learned

What has become clear is that the complexity or grade of the operation that can be performed using the robot is far higher than that achieved by VATS. The 3D-HD vision and the fully articulating effector arms have allowed operations that would have been normally performed by an open technique to be undertaken by a totally endoscopic robot-assisted one. This means that patients who would have naturally had more pain and the complications of an open operation, and who would have stayed in hospital for on average 5-7 days, could go home earlier, with less pain, and with quicker rehabilitation. Some patients need adjuvant treatments and we have shown that a robotic technique confers a better ability to withstand the toxicities of these treatments.

## Complexity of operation

The robot platform should not only be used for simple cases that could potentially be done using a VATS technique, but more complex operations such as redo operations where the patient has had previous ipsilateral thoracic surgery leaving multiple adhesions that would preclude or hamper a VATS procedure. In these patients, the far superior vision and the articulation of the effector arms allows a robotic operation, with most able to go home within 3-4 days. Five percent of our patients have had redo operations and it is our impression that they have been discharged more quickly than open surgery due to less pain. Our readmission rate is less than 1%. Figure 3 shows that 25% of the Freeman patients who had robotic operations were discharged on days 1-2 in comparison to the VATS group who had a longer hospital stay.



*Figure 3: Length of hospital stay (days) for robotic and VATS lobectomy*

## Comparison of conversion rate to VATS lobectomy

Our data has shown that the robotic platform has allowed a 66% reduction in conversion rate compared to VATS. This in turn correlates with more patients having a shorter hospital stay, less pain, less analgesia and fewer complications.

## Day one pain scores and chronic neuropraxia

Pain scores are correlated to length of stay and post-hospital speed of recovery. Our first patient was kept in hospital for observation and had a pain score of 1 on day 1; three weeks later she could walk her grandson to school. Another example is of a patient riding their horse a week after surgery. This post-operative rapid rehabilitation is one key element of the use of the robotic platform that is an improvement over VATS operations. It is accepted that many VATS and most open patients will have some chronic neuropraxia due to intercostal space levering or opening. This type of chronic pain can lead to a slower recovery, and the need for chronic use of neuropathic analgesia. The incidence of this in our series was only 6%.

We pioneered a sub-xiphoid approach for lobectomy in 2015 to place endoscopic staplers and deliver often quite-significantly air-trapped lung specimens. This meant that no anterior utility port through an intercostal space was made and pain control was enhanced. The result from this was patients could more consistently be sent home on day 2.

## Costs

The amortised costs are shared between the different surgical teams using the robot, and the more the robot is used over its lifespan, the lower the cost per case. The disposable costs at the start of the programme were more than £1500 (Si system) and this has been reduced to about £1000 due to efficient use of drapes and equipment, and consistent use of only four robotic instruments. This figure can be offset against the reduction in length of stay. Further reductions in costs can be achieved by not requiring a high-dependency bed, physiotherapist input or blood cross-matching due to reduced blood loss.

## Intra-operative Bleeding

With the console surgeon being unscrubbed and remote from the patient, bleeding needs to be dealt with in an extremely efficient and logical way. Bleeding can be categorised into, i) that managed robotically without the need for a thoracotomy, ii) that managed by controlled conversion and iii) that managed by emergency conversion. In each situation, the team must be well-rehearsed as each involves a different method. Use of non-threaded swabs means that they can be sucked dry to white again and will not catch on a staple or clip reducing the possibility of bleeding.

In the first category of bleeding, a swab can be used to tamponade the bleeding vessel. If this is not effective, it may be necessary to use a suction-irrigation device whilst applying clips or suturing. Better than this is the use of the articulating suction-irrigation device controlled by the surgeon which is more precise and confers superior visualisation.

If haemostasis is not possible using these techniques, a controlled conversion is carried out. A swab is left on the bleeding point, the instruments are removed from the arms and the robot is undocked but the camera is kept in its port to keep vision while the robot cart is wheeled away. The scrub team then uses the camera, as in a VATS case,

whilst the surgeon performs the thoracotomy. In an emergency conversion, it is even more imperative for all the team members to know what their role is to ensure a safe transition to an open operation.

## Non-bleeding complications

Compared to open lobectomy, robotic surgery potentially shows a reduction in all types of complications. If a conversion to thoracotomy occurs, the outcomes are likely to be the same as for a planned open operation. There has been much discussion about the lack of tactile feedback with current surgical robot platforms and the potential for a more dangerous operation. Due to the excellent 3D-HD visualisation, the 'optical cortex experience' is heightened and the operating surgeon replaces haptic feedback with visual cues, thereby discerning the surgical plane between artery/vein and bronchus.

## The literature

There have been many case reports and cohort studies but only one propensity-matched study and few systematic analyses published in the literature. We review the literature for robotic lobectomy as compared to open and VATS lobectomy<sup>5-22</sup>.

Seven publications show that robotic lobectomy has similar or better mortality rates and similar or fewer complications, and a significantly shorter hospital length of stay when compared to open surgery<sup>10,13,14,15,20,21,22</sup>. Five studies show the same or fewer transfusions or blood loss<sup>13,15,20,21,22</sup>. The same five publications show longer operative times but state that this does not result in higher mortality or complication rates.

When it comes to a comparison of robotic versus VATS lobectomy, where documented, most of these show the same or lower mortality<sup>5-7,9-11,13-19</sup>, bleeding and transfusion rate<sup>7,9,11,13,15,17,19</sup>, length of stay<sup>5-19</sup> and conversion rate<sup>5,7,18,19</sup>. Most studies show longer operative times but with no increase in mortality<sup>5,6,8,11,13,14,17,18</sup>. A few studies conclude that the rate of intra-operative complications is higher in robotic than VATS<sup>5,6,16</sup> but only one found this statistically significant ( $p < 0.0001$ )<sup>16</sup> and mostly consists of iatrogenic bleeding, although there is no increase in mortality. Twelve out of 15 studies showed the same or fewer post-operative complications than VATS<sup>1,3,4,6-11,13-15</sup>. Of the three remaining studies, the increase in complication rate was not statistically significant in two.

There is one meta-analysis of robotic-assisted versus VATS lobectomy<sup>23</sup>. It concludes that there are similar outcomes between the two but the authors recognise that there are no randomised controlled trials, that the included studies involved older generation systems and that there were differing baseline characteristics, surgical abilities and technique.

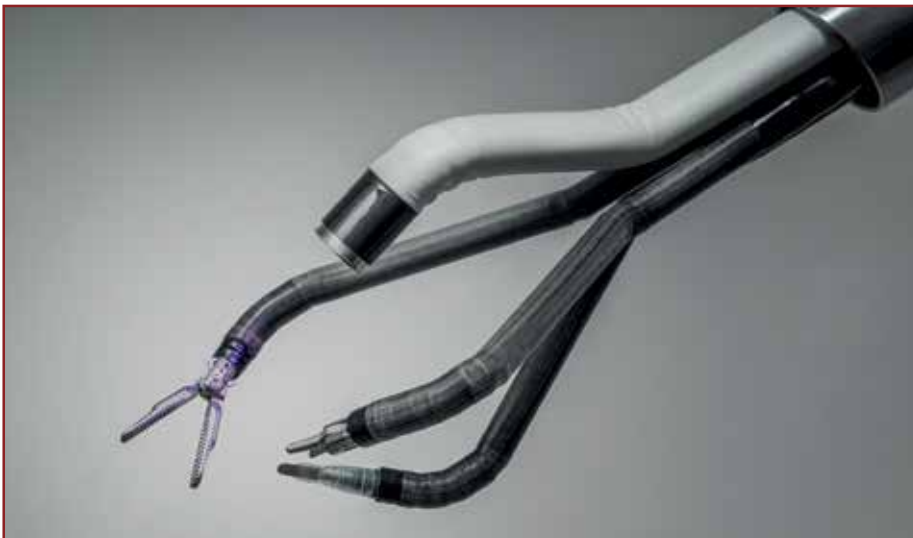The one paper using a propensity-matched analysis is a review of a large US database<sup>10</sup>. Of more than 30,000 patients in 8 states, approximately 20,000 had open, 12,000 VATS, and 400 robotic operations in a two-year period. There was a significant reduction in mortality (0.2% vs 2.0%,  $p = 0.016$ ), length of stay (5.9 vs 8.2 days,  $p < 0.0001$ ), and overall complication rates (43.8% vs 54.1%,  $p = 0.003$ ) when compared with thoracotomy. Robotic resection showed no significant difference in mortality (0.2% vs 1.1%,  $p = 0.12$ ), length of stay (5.9 days vs 6.3 days,  $p = 0.45$ ) and overall complication rates (43.8% vs 45.3%,  $p = 0.68$ ) when compared with VATS. There is evidence that significantly more lymph nodes can be excised robotically than by VATS, leading to more accurate staging and therefore better treatment and assessment of prognosis<sup>24</sup>.

## Training

A dedicated training pathway including simulation is vital and this is where a dual console system is extremely useful. It allows both the trainer and the trainee to see the same 3D-HD image of the operating field with the ability to place markers to guide the operative steps. The trainer can pass control of some or all of the robot arms to the surgeon on the second console. Training is significantly enhanced by recording operations and time spent reviewing the videos aids this process. Thus, surgeons who have not trained in VATS resection surgery have been able to perform minimally invasive procedures. The operative times for trainee robotic surgeons is not markedly different to consultant surgeons, showing that standardised operating leads to efficient outcomes.

## The future of robotic-assisted lobectomy

Several centres in the UK have started robotic thoracic programmes and there are more in the pipeline. Medical conglomerates and smaller companies have invested in robotic technology, as they see the benefits of robotic-assisted surgery and the vast expansion in this platform that is happening. This will bring competition to the medical robotic marketplace for the first time in over 10 years and will lead to more advances in this technology. In addition, it will drive down the costs, particularly those of the disposable equipment. There is a world-wide push for minimally invasive thoracic surgeons to perform uniportal surgery and this is on the near-horizon in the robotic platform (Figure 4). A European prospective database is on the way, and there is discussion about subsidiary UK robotic-thoracic interest group.



*Figure 4: Robotic instrumentation for single incision surgery*

## Financial Disclosure

SS is a proctor for Intuitive Surgical and receives fees and expenses when involved with training. He has had temporary contracts with Medtronic, Ethicon, and Medela.

## References

1. Melfi FM, Menconi GF, Mariani AM, et al. Early experience with robotic technology for thoracoscopic surgery. *Eur J Cardiothorac Surg*. 2002 May;21(5):864-8.
2. Melfi FM, Mussi A. Robotically assisted lobectomy: learning curve and complication. *Thorac Surg Clin* 2008;18:289-95.
3. Park BJ, Flores RM, Rusch VW. Robotic assistance for video-assisted thoracic surgical lobectomy: technique and initial results. *Thorac Cardiovasc Surg*. 2006 Jan;131(1):54-9.
4. Cerfolio RJ, Bryant AS, Minnich DJ. Starting a robotic program in general thoracic surgery: why, how, and lessons learned. *Ann Thorac Surg*. 2011 Jun;91(6):1729-36.
5. Augustin F, Bodner J, Maier H, et al. Robotic-assisted minimally invasive versus thoracoscopic lung lobectomy: comparison of perioperative results in a learning curve setting. *Langenbecks Arch Surg* 2013;398(6):895-901.
6. Bodner J, Schmid T, Augustin F. Minimally invasive approaches for lung lobectomy - From VATS to robotic and back. *European Surgery - Acta Chirurgica Austriaca* 2011;43(4): 224-228.
7. Jang HJ, Lee HS, Park SY, et al. Comparison of the early robot-assisted lobectomy experience to video-assisted thoracic surgery lobectomy for lung cancer: a single-institution case series matching study. *Innovations (Phila)* 2011; 6: 305-310.
8. Lee HS, Jang HJ. Thoracoscopic mediastinal lymph node dissection for lung cancer. *Semin Thorac Cardiovasc Surg*. 2012 Summer;24(2):131-41.
9. Louie BE, Farivar AS, Aye RW, et al. Early experience with robotic lung resection results in similar operative outcomes and morbidity when compared with matched video-assisted thoracoscopic surgery cases. *Ann Thorac Surg*. 2012 May;93(5):1598-604.
10. Kent M, Wang T, Whyte R, et al. Open, Video-Assisted Thoracic Surgery, and Robotic Lobectomy: Review of a National Database. *Ann Thorac Surg*. 2014 Jan;97(1):236-42.
11. Lee BE, Korst RJ, Kletsman E, et al. Transitioning from video-assisted thoracic surgical lobectomy to robotics for lung cancer: Are there outcomes advantages? *J Thorac Cardiovasc Surg*. 2014 Feb;147(2):724-9.
12. Swanson SJ, Miller DL, McKenna RJ Jr, et al. Comparing robot-assisted thoracic surgical lobectomy with conventional video-assisted thoracic surgical lobectomy and wedge resection: results from a multihospital database (Premier). *J Thorac Cardiovasc Surg*. 2014 Mar;147(3):929-37.
13. Adams RD, Bolton WD, Stephenson JE, et al. Initial Multicenter Community Robotic Lobectomy Experience: Comparisons to a National Database. *Ann Thorac Surg*. 2014 Jun;97(6):1893-8.
14. Deen SA, Wilson JL, Wilshire CL, et al. Defining the Cost of Care for Lobectomy and Segmentectomy: A Comparison of Open, Video-Assisted Thoracoscopic, and Robotic Approaches. *Ann Thorac Surg*. 2014 Mar;97(3):1000-7.
15. Farivar AS, Cerfolio RJ, Vallières E, et al. Comparing robotic lung resection with thoracotomy and video-assisted thoracoscopic surgery cases entered into the Society of Thoracic Surgeons database. *Innovations (Phila)*. 2014 Jan-Feb;9(1):10-5.
16. Paul S, Jalbert J, Isaacs AJ, et al. Comparative effectiveness of robotic-assisted vs thoracoscopic lobectomy. *Chest*. 2014 Dec;146(6):1505-12.
17. Spillane J, Brooks P. Developing a Robotic Program in Thoracic Surgery at Cape Code Hospital. *J Robot Surg*. 2014 Sep;8(3):213-20.
18. Lee BE, Shapiro M, Rutledge JR, et al. Nodal Upstaging in Robotic and Video Assisted Thoracic Surgery Lobectomy for Clinical N0 Lung Cancer. *Ann Thorac Surg*. 2015 Jul;100(1):229-33.

19. Mahieu J, Rinieri P, Bubenheim M, et al. Robot-Assisted Thoracoscopic Surgery versus Video-Assisted Thoracoscopic Surgery for Lung Lobectomy: Can a Robotic Approach Improve Short-Term Outcomes and Operative Safety? *Thorac Cardiovasc Surg.* 2016 Jun;64(4):354-62.
20. Cerfolio RJ, Bryant AS, Skylizard L, et al. Initial consecutive experience of completely portal robotic pulmonary resection with 4 arms. *J Thorac Cardiovasc Surg.* 2011 Oct;142(4):740-6.
21. Veronesi G, Galetta D, Maisonneuve P, et al. Four-arm robotic lobectomy for the treatment of early-stage lung cancer. *J Thorac Cardiovasc Surg.* 2010 Jul;140(1):19-25.
22. Oh DS, Cho I, Karamian B, et al. Early adoption of robotic pulmonary lobectomy: feasibility and initial outcomes. *Am Surg.* 2013 Oct;79(10):1075-80.
23. Zhang L, Gao S. Robot-assisted thoracic surgery versus open thoracic surgery for lung cancer: a system review and meta-analysis. *Int J Clin Exp.Med* 2015 Oct 15;8(10):17804-10.
24. Radkani P, Joshi D, Barot T, et al. Robotic video-assisted thoracoscopic lung resection for lung tumours: a community tertiary care centre experience over four years. *Surg Endosc* 2016 Feb;30(2):619-24.



---

# Postscriptum

---

*“Science cannot create a moral code unless truth becomes a belief instead of being a demonstration”*

*From: The old songs of wisdom*

---

This book, the second volume of ‘Perspectives in Cardiothoracic Surgery’ is the third publication by our Society. The two others were a monograph on the ‘Pericardial Heart Valve’ (2014) and the first volume of ‘Perspectives’ (2016).

This present volume comprises some of the outstanding presentations at the 2016 Annual University Meeting.

The Perspectives will be published yearly, thereby creating a series of volumes with high scientific educational content. This initiative is intended to enlarge the spectrum of education instruments directed towards a better and more complex support for the training of cardiothoracic surgeons. The evidence so far showed the usefulness of both the SCTS University and the publication of key presentations, edited in a scholarly format for the benefit of the cardiothoracic surgeon.

These ‘Perspectives’ will continue to be printed in the classical way.

I always believed that “*litera scripta manet*” and that the sublime marriage between form and function is embodied in writing and even more and better in the printed word.

These publications proved to be very useful also for those who could not make the yearly pilgrimage to the Annual Meeting of the SCTS, or could not attend the Universities.

The 15 chapters comprised in this volume were not meant to be exhaustive, they were specifically prepared to address some of the more recent developments in the respective sub-specialities. All chapters answered, in a scholarly way, the needs of the continuous high level educational programme of our Society.

The scientific aim continues to be the realisation of something more precious than ephemeral miracles, although, I personally have the continuous feeling that we could always do better. This thought, however, will transport us to the next year’s Annual Meeting and the preparations for the third volume of ‘Perspectives’.

In this respect, we all know that yesterday is but today’s memory and that tomorrow is today’s dream and that we should let today embrace the past with reverence and remembrance and the future with longing and hope.

I have been deeply impressed by the abundant indications of the toil and care which have been deployed by the authors of these chapters and the splendid work done by the guest editors under the guidance and with the experience of Mr. Paul Modi. Congratulations to all!!!

I am convinced that this second volume of the “Perspectives” will prove to be interesting and useful to all students of cardiothoracic surgery.

Having had myself the enormous privilege to walk in the footsteps of a scientific dream, I take the liberty to say to my younger colleagues that the way from Nadir to Zenith is very long and arduous. We could only try to “strive for perfection in everything we do, to take the best of that which exists and improve it and when it does not exist, to create it” as Sir Henry Royce counselled.

*Marian Ion IONESCU*

*January 2017*

*Zermatt*





Society for Cardiothoracic Surgery in Great Britain and Ireland