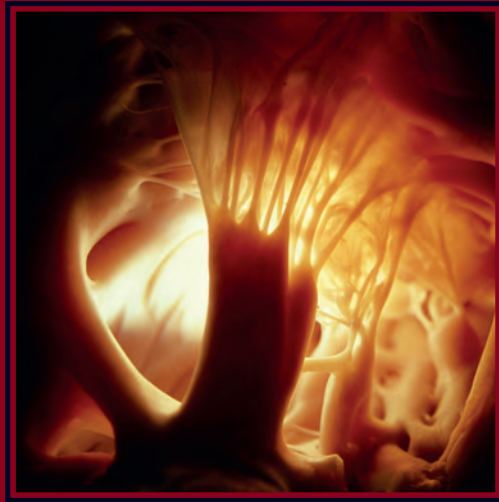




Society for Cardiothoracic Surgery in Great Britain and Ireland

Perspectives in Cardiothoracic Surgery

The SCTS Ionescu University
Volume I



Edited by
Paul Modi

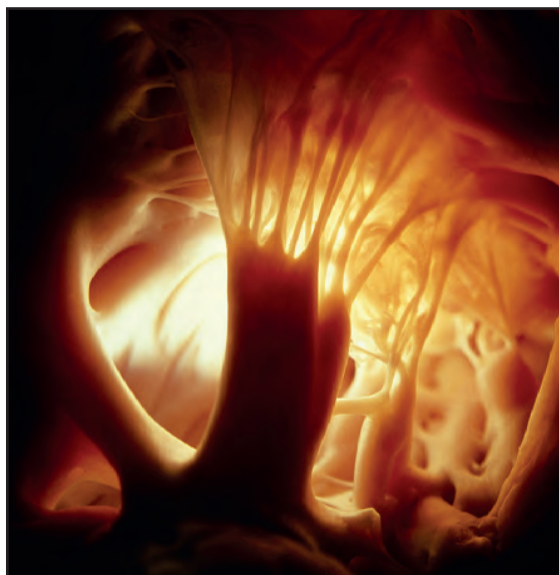
Invited Editor
Marian Ion Ionescu



Society for Cardiothoracic Surgery in Great Britain and Ireland

Perspectives in Cardiothoracic Surgery

The SCTS Ionescu University
Volume I



Edited by
Paul Modi

Invited Editor
Marian Ion Ionescu

Perspectives in Cardiothoracic Surgery: The SCTS-Ionescu University, Volume I

Copyright © 2016 Society for Cardiothoracic Surgery in Gt Britain and Ireland

ISBN 978-1-5262-0129-4

First published in Great Britain in 2016 by Society for Cardiothoracic Surgery in Great Britain and Ireland, SCTS 5th Floor, Royal College of Surgeons of England, 35-43 Lincoln's Inn Fields, London WC2A 3PE.

Tel: 0207 869 6893

Fax: 0207 869 6890

Email: sctsadmin@scts.org

Web: www.scst.org

All rights reserved. No part of this book may be reproduced or transmitted in any form or by any means, electronic or mechanical, including photocopying, recording or by any information storage and retrieval system, without written permission from the author, except for the inclusion of brief quotations in a review.

Cover photo by Lennart Nilsson

Designed, typeset and printed by CPL Associates, London, UK.

Perspectives in Cardiothoracic Surgery

The SCTS Ionescu University
Volume I

Edited by Paul Modi

Invited Editor Marian Ion Ionescu

Section I: Cardiac Surgery - Minimally Invasive Surgery
for the Mitral and Aortic Valves

Section II: Thoracic Surgery - The Treatment of Diseases
of the Pleura



Society for Cardiothoracic Surgery
in Great Britain and Ireland



Preface

Pliny leaves mankind this only alternative: Either of doing what deserves to be written or of writing what deserves to be read.

Caius Plinius Coecillius Secundus (the younger)

The SCTS University was conceived by Ian Wilson and first delivered in 2010 at the Annual Meeting in Liverpool. It initially consisted of four streams of contemporary postgraduate education in the specialty. From 2014, with the benefit of support from Mr Marian Ion Ionescu, the SCTS University has considerably expanded. On its fifth anniversary in 2015, the SCTS Ionescu University ran eleven streams across the breadth of the specialty. Four hundred and twenty delegates from the SCTS and the Association of Cardiothoracic Anaesthetists attended. The SCTS Ionescu University has now become an established day of the SCTS Annual Meeting.

The presentations from the SCTS Ionescu University are now available to a wider audience through the SCTS website (<http://www.scts.org/university/library.aspx>).

With the publication of ‘Perspectives in Cardiothoracic Surgery – The SCTS Ionescu University 2015’ we are pleased to be able to publish the key presentations edited in a more scholarly format for the benefit of the SCTS membership and the wider profession. These perspectives are up to date reviews of areas of clinical practice authored and edited by leading experts who have kindly contributed to this next phase of education from the SCTS Education Committee and Annual Meeting.

Tim R Grabam

President 2014-16

Graham Cooper

President 2016-18

Mike Lewis

Education secretary

Rajesh Shah

Education secretary

Contents

Preface	5
Contributors	6
Section 1	
1 Current Controversy – Technique of Aortic Occlusion: Endoaortic Balloon versus Transthoracic Clamp	13
2 Current Controversy: Antegrade versus retrograde arterial perfusion	25
3 Debate: Should the First-Line Treatment for Non-Complex Degenerative Mitral Valve Disease in the 21st Century be by Minimal Access Surgery?	41
4 Pearls and Pitfalls of Minimally Invasive Mitral Valve Surgery and the Loop Technique	57
5 Anaesthesia and Transoesophageal Echocardiography for Minimally Invasive Heart Valve Surgery	71
6 Transcatheter Mitral Valve Repair with The MitraClip – The Evidence and Current Indications	83
7 The Anterior Thoracotomy Approach for Aortic Valve Replacement:	95
8 Sutureless Valves and Minimal Access Surgery	101
9 Training in Minimally Invasive Surgery: The General Surgeons did this years ago, what can we learn?	111
Section 2	
10 Surgery for Pleural Sepsis	121
11 Management of Residual Pleural Space	131
12 Thoracoscopy under Local Anaesthesia and Medical Management of Pleural Disease	139
13 Current Oncological Options for the Treatment of Mesothelioma	149
14 Extended Pleurectomy Decortication: The new standard of care for Malignant Pleural Mesothelioma	157
15 Extrapleural Pneumonectomy for Mesothelioma	167
Postscriptum	174

Contributors

Enoch Akowuah FRCS (CTh)

Department of Cardiothoracic Surgery
James Cook University Hospital
Middlesbrough.

Omar Al-Rawi FRCA

Consultant Anaesthetist
Liverpool Heart and Chest Hospital
Liverpool.

Keng Ang PhD FRCS(CTh)

Specialty Trainee in Thoracic Surgery
Glenfield Hospital
University Hospitals of Leicester
Leicester.

Rizwan Q Attia MRCS PhD

Specialty Registrar in Cardiothoracic
Surgery
Kings College Hospital
London.

Jonathan Blackshaw FRCA

Specialty Registrar in Anaesthesia
Liverpool Heart and Chest Hospital
Liverpool.

Mamta H Buch MBChB PhD FRCP

Consultant Interventional Cardiologist
University Hospital of South Manchester
NHS Foundation Trust
Manchester.

Mohammed F Chowdhry MD FRCS(CTh)

Specialty Trainee in Thoracic Surgery
Glenfield Hospital
University Hospitals of Leicester
Leicester.

Piroze Davierwala MD

Department of Cardiac Surgery
Heart Centre Leipzig University
Leipzig, Germany.

Nicholas Denny BM BCH

Academic Foundation Trainee
Lancashire Teaching Hospitals
Preston.

Ranjit P Deshpande MBBS MS FRCS (CTh)

Consultant Cardiothoracic Surgeon
Kings College Hospital, Department of
Cardiothoracic Surgery
London.

Mattia Glauber MD

Centro Cardiotoracico Sant'Ambrogio
Istituto Clinico Sant'Ambrogio
Gruppo Ospedaliero San Donato
Milan, Italy.

Seray Hazer MD

Thoracic Surgery Department
Bingol State Hospital
Bingol, Turkey.

Sion Jones MD MRCS

Specialty Registrar
Liverpool Heart and Chest Hospital
Liverpool.

Antonio Lio MD

Centro Cardiotoracico Sant'Ambrogio
Istituto Clinico Sant'Ambrogio
Gruppo Ospedaliero San Donato
Milan, Italy.

Gilbert Massard MD

Consultant Thoracic Surgeon
Centre Hospitalier
Strasbourg, France.

Diego Marquez-Medina MD PhD

Medical Oncologist
Arnau de Vilanova University Hospital
Lleida, Spain.

Antonio Miceli MD PhD

Istituto Clinico Sant'Ambrogio
Gruppo Ospedaliero San Donato
Milan, Italy

Martin Misfeld MD PhD

Professor and Co-Director of Department
of Cardiac Surgery
Heart Centre Leipzig University
Leipzig, Germany.

Paul Modi MD FRCS(CTh)

Consultant Cardiac Surgeon
Liverpool Heart and Chest Hospital
Liverpool.

Friedrich W Mohr MD PhD

Professor and Chief
Heart Centre Leipzig University
Leipzig, Germany.

Roger W Motson MS FRCS

Professor of General Surgery
The ICENI Centre
Colchester University Hospital,
Colchester.

M Munavvar MD DNB FRCP (Lon) FRCP (Edin)

Consultant Chest Physician/ Interventional
Pulmonologist
Lancashire Teaching Hospitals
Preston.

Apostolos Nakas MD MRCS

Consultant Thoracic Surgeon
Glenfield Hospital
University Hospitals of Leicester
Leicester.

Thilo Noack MD

Department of Cardiac Surgery
Heart Centre Leipzig University
Leipzig, Germany.

Anne Olland MD

Department of Thoracic Surgery
Centre Hospitalier
Strasbourg, France.

Kenneth Palmer FRCA

Consultant Anaesthetist
Liverpool Heart and Chest Hospital
Liverpool.

Steffen Pfeiffer MD

Leitender Oberarzt
Universitätsklinik für Herzchirurgie
Paracelsus Medizinische Privatuniversität
Nürnberg, Germany.

Sanjay Papat BSc PhD FRCP

Consultant Medical Oncologist
Royal Marsden Hospital
London.

Sridhar Rathinam FRCSEd(CSiG) FRCSEd(CTh)

Consultant Thoracic Surgeon
Glenfield Hospital
University Hospitals of Leicester
Leicester.

Giuseppe Santarpino MD

Resident in Cardiac Surgery
Universitätsklinik für Herzchirurgie
Paracelsus Medizinische Privatuniversität
Nürnberg, Germany.

Vivek Srivastava FRCS (CTh)

Clinical Fellow
James Cook University Hospital
Middlesbrough.

Alper Toker MD

Consultant Thoracic Surgeon
Group Florence Nightingale Hospitals
Istanbul, Turkey.

Paul van Schil MD PhD

Consultant Thoracic Surgeon
University Hospital of Antwerp
Edegem (Antwerp), Belgium.

Francis C Wells FRCS

Consultant Cardiothoracic Surgeon
Papworth Hospital
Cambridge.

Section 1

Cardiac Surgery – Perspectives in Minimally Invasive Surgery of the Mitral and Aortic Valves

Paul Modi

*“Now understand me well. It is provided in the essence of things,
that from any fruition of success, no matter what, shall come
forth something to make a greater struggle necessary”*

Walt Whitman (1819-1892)

Minimally Invasive Mitral Valve Surgery

“Simplicity is not a goal, but one arrives at simplicity in spite of oneself, as one approaches the real meaning of things”

Constantin Brancusi (1876 – 1957)

Chapter 1

Current Controversy – Technique of Aortic Occlusion: Endoaortic Balloon versus Transthoracic Clamp

Endoaortic Balloon: *Rizwan Q Attia and Ranjit Deshpande*

Transthoracic Clamp: *Vivek Srivastava and Enoch Akowuah*

“Two elements are needed to form a truth, a fact and an abstraction”

Remy de Gourmont (1858-1915)

The Endoaortic Balloon

“A plausible impossibility is always preferable to an unconvincing possibility”

Introduction

The endoaortic balloon is a multifunctional device which is used to endoluminally occlude the ascending aorta during minimally invasive mitral valve surgery. It also vents the aortic root, monitors the pressure in both the root and the balloon, and delivers cardioplegia solution to the coronary arteries. A schematic representation of the IntraClude Aortic Catheter (Edwards Lifesciences, Irvine, Ca.) is shown in Figure. 1.

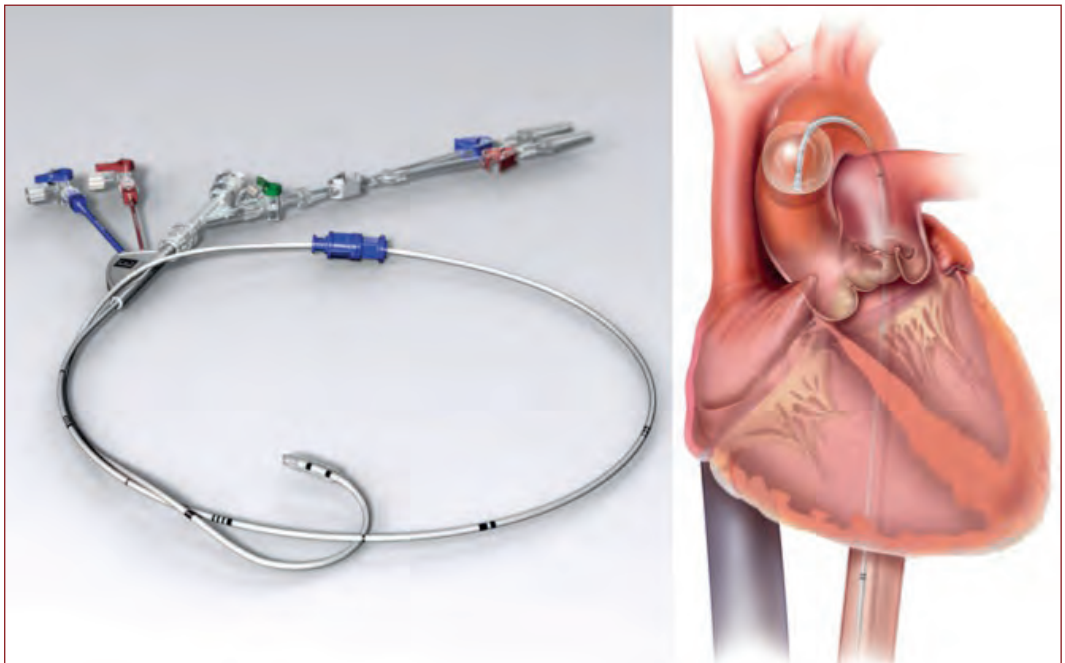


Fig 1: *IntraClude endoaortic occlusion device (left). Schematic representation of optimal placement of the endoaortic balloon in the ascending aorta above the aortic root (right).*

The IntraClude consists of a 10.5Fr wire-wound 65cm or 100cm long, triple lumen catheter with an elastomeric balloon at its tip. It is delivered via femoral arterial or direct aortic access through the side arm of an arterial cannula. The IntraClude is advanced over a guidewire towards the aortic root under transoesophageal echocardiographic guidance (Figure 2). The balloon can occlude aortas with internal diameters of 20 to 40mm. The central lumen of the catheter allows delivery of cardioplegia solution during occlusion and venting of the left cardiac chambers through the aortic root. The two remaining lumens are designed for balloon inflation and aortic root pressure monitoring. The balloon is placed just cranial

to the sinotubular junction and rapidly inflated until the aortic root pressure is seen to fall. The gradient between the aortic root pressure and the mean systemic arterial pressure is an indication of complete aortic occlusion.

History

The percutaneous myocardial protection system was proposed independently by Peters and by Stevens [1-3]. Dr Greg Ribakove from New York University (NYU), whilst on a sabbatical at Stanford University in 1994, began pre-clinical work with Stevens at the HeartPort Company (HeartPort Inc., Redwood City, Ca.), the Stanford research team and the NYU laboratories. These initial studies showed the feasibility of the anterior minithoracotomy approach for mitral valve surgery using balloon endoclamping.

The first human case using this technique was performed in

March 1996 in Malaysia by the Stanford team of Tom Burdeon and Mario Pompili [4-5]. This procedure was subsequently used by Professor Mohr's group in Leipzig [6]. In October 1996, Stevens and colleagues at Stanford University and Colvin and colleagues at NYU launched a Food and Drug Administration (FDA) Phase I study for the Port-Access system. This, along with the Port-Access multicentre registry, reported results which demonstrated the safety and effectiveness of this technique [7, 8]. Similar reports were published by Cosgrove and Navia [9] and Cohn *et al.* [10] of mitral valve surgery through a right parasternal approach with direct aortic clamping. These seminal experiences demonstrated that avoiding a sternotomy for cardiac surgical procedures was safe and effective and achieved reproducible results.

Technique and practical considerations

Endoaortic balloon insertion usually requires cannulation of the femoral artery with either a 21Fr or 23Fr cannula. Occasionally, the 21F cannula is too large for the femoral artery of a smaller patient and it is important to recognize this to avoid prolonged lower extremity ischemia. In this situation, in order to be able to use an endoaortic balloon, one should cannulate either both femoral arteries or the ascending aorta with the EndoDirect arterial cannula (Edwards Lifesciences, Irvine, Ca.).

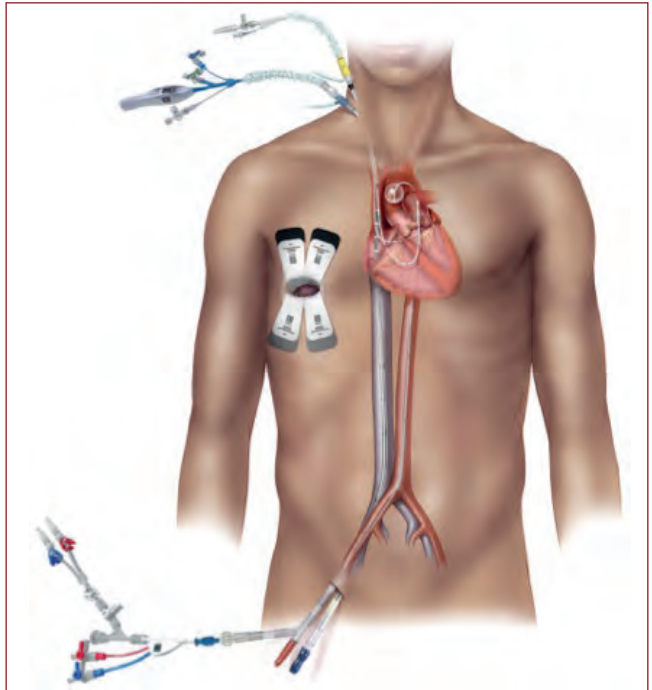


Figure 2: Schematic representation of the placement of the endoaortic balloon, femoral arterial cannulation, internal jugular venous cannula for assisted venous drainage during right mini-thoracotomy approach for minimally invasive mitral/tricuspid valve surgery.



Following proper positioning of the device just cranial to the sinotubular junction, cardiopulmonary bypass is instituted. Continuous transoesophageal echocardiography is used for monitoring the position of the balloon. Blood pressure is continuously monitored through bilateral radial arterial lines to detect distal migration of the balloon and occlusion of the innominate artery. Throughout the procedure the balloon pressure is maintained between 350-400mmHg. During cardiac arrest, the balloon pressure often falls by 10-20% due to changes in temperature and reduced aortic wall stiffness. Balloon positioning is a simple balance of forces – towards the aortic valve by the arterial flow from the pump, and towards the innominate artery by the aortic root pressure, by systolic cardiac ejection before complete cardiac arrest, by saline testing of the valve repair and by tension in the catheter of the endoballoon.

Transoesophageal echocardiography is used to assess balloon positioning, to identify the presence of air in the left heart and the aortic root, and to assess the function of the aortic valve. Indirect monitoring tools include non-invasive near-infrared spectroscopy (NIRS)-based cerebral oximetry devices (e.g. INVOS™, OxyPrem) or transcranial Doppler to assess functional reduction in cerebral blood flow caused by balloon migration [10,11,12]. Once the operation is completed the balloon is deflated and used to vent the aortic root for deairing. Once cardiopulmonary bypass is discontinued the device is removed through the side arm of the arterial cannula.

The catheter of the endoballoon reduces the cross-sectional area of the arterial cannula lumen (steric hindrance), therefore increasing the arterial line pressures with the potential risk of aortic dissection when the arterial line pressure is greater than 250mmHg. This might be the case in elastic or small femoral arteries encountered in young women or in elderly patients with atherosclerotic calcified arteries. When the line pressure is greater than 300mmHg during full flow cardiopulmonary bypass, the use of a contralateral arterial cannula (even a small size 18-19Fr) is advisable with a Y-connection in the arterial circuit to minimise this risk.

The IntraClude Aortic Catheter is the latest iteration of the endoballoon, the first being the EndoClamp (Edwards Lifesciences, Irvine, Ca.), and is designed to overcome some of the previous problems. This triple lumen catheter is only 9.5-10.5Fr size, creating less obstruction of the arterial cannula and therefore allowing increased blood flow at lower pressures with a reduction in blood shear stress. The balloon is wider with a cylindrical shape rather than spherical, thereby increasing the surface contact from 10mm to 18mm between the balloon and the aortic wall allowing for better sealing with improved adhesion between the balloon and the aortic wall. The shaft of the catheter is curved to facilitate its passage around the aortic arch and the cardioplegia tip is orientated towards the coronary ostia. The shape is also designed to avoid the slack effect that a straight catheter would have, with the potential advantage of limiting balloon migration towards the aortic valve. This is due to the tension generated by the catheter bending in the aortic arch. The IntraClude can be used for aortas with internal diameters of 20 to 40mm whilst the EndoClamp was effective only for aortas with internal diameters of 20 to 38mm. Balloon rupture can be prevented by reducing inflation volume and by echocardiographic monitoring to avoid malpositioning or accidental damage during the surgical procedure.

Results and Complications

There are numerous studies that demonstrate the safety and efficacy of this device. During minimally invasive mitral valve repair, endoaortic balloon occlusion has been demonstrated to be as effective as transthoracic aortic clamping with similar outcomes in each group [13-17]. The hospital mortality in all series is around 1% and mortality at 20 months approaches 2% [18-21]. In patients with a high atherosclerotic burden in the aorta, the overall mortality rate is higher [21].

Four published articles report aortic dissection rates of 1% [13,14,18,22], whilst in three other articles no aortic injuries were reported [17,23,24]. Access site complications may occur in the iliac and femoral vessels at the site of catheter insertion. Plaque embolization during catheter introduction or retrograde perfusion, pseudoaneurysm formation and aortic branch vessel obstruction due to balloon migration are among the recognized complications.

In five published reports analysing results in a total of 753 patients, stroke and transient ischaemia attacks (TIAs) occurred in 0.4% to 4.0% of patients [17, 18, 21,25,29]. Myocardial infarction has been reported in two patients in one series (2/151) and in one patient in another published report (1/306) [16,18]. The incidence of re-exploration for bleeding ranged from 2 to 10% in the reported series where endoaortic balloon occlusion was used [13,15,16,21,23-26]. There were no significant differences in the incidence of cardiac arrhythmias, chest infections, respiratory failure, renal failure or low cardiac output state between patients with endoaortic balloon occlusion or external aortic clamping

Contraindications

The contraindications for use of endoaortic balloon occlusion include the following: more than mild aortic regurgitation, extensive aortic calcification, presence of an aortic aneurysm and atheromatous plaques in the ascending aorta. A small-sized femoral artery (less than 6mm) may also represent a contraindication for femoral cannulation.

Conclusions

Various studies have shown no differences in clinical outcomes between endoaortic balloon occlusion and external aortic clamping. Endoaortic balloon occlusion allows expansion of the surgical repertoire for minimally invasive cardiac surgical operations, and is particularly useful in reoperative cardiac procedures and for truly totally thoracoscopic cardiac surgery.

References

1. Stevens JH, Burdon TA, Siegel LC, *et al.* Port-access coronary artery bypass with cardioplegic arrest: acute and chronic canine studies. *The Annals of Thoracic Surgery.* 1996 Jan 8;62(2):435-41.
2. Stevens JH, Burdon TA, Peters WS, *et al.* Port-access coronary artery bypass grafting: a proposed surgical method. *The Journal of Thoracic and Cardiovascular Surgery.* 1996 Mar;111(3):567-73.
3. Peters WS, Smith JA, Prevolos A, *et al.* Mitral valve replacement via a right mini-thoracotomy in the dog: use of carbon dioxide to reduce intracardiac air. *Eur J Cardiothorac Surg.* 1997 Jun;11(6):1067-73.
4. Pompili MF, Stevens JS, Burdon TA, *et al.* Port-access mitral valve replacement in dogs. *J Thorac Cardiovasc Surg.* 1996; 112:1268-1274.

5. Siegel LC, Goar FG, Stevens JH, *et al.* Monitoring Considerations for Port-Access Cardiac Surgery. *Circulation*. 1997; 96: 562-568.
6. Mohr FW, Falk V, Diegeler A, *et al.* Minimally invasive port-access mitral valve surgery. *The Journal of Thoracic and Cardiovascular Surgery*. 1998 Mar;115(3):567-74, discussion 574-6.
7. Spencer FC, Galloway AC, Grossi EA, *et al.* Recent developments and evolving techniques of mitral valve reconstruction. *The Annals of Thoracic Surgery*. 1998 Feb;65(2):307-13.
8. Glower DD, Siegel LC, Frischmeyer KJ, *et al.* Predictors of outcome in a multicenter port-access valve registry. *The Annals of Thoracic Surgery*. 2000 Sep;70(3):1054-9.
9. Navia JL, Cosgrove DM III. Minimally invasive mitral valve operations. *Annals of Thoracic Surgery*. 1996 Nov;62(5):1542-4.
10. Cohn LH, Adams DH, Couper GS, *et al.* Minimally invasive cardiac valve surgery improves patient satisfaction while reducing costs of cardiac valve replacement and repair. *Ann Surg*. 1997 Oct;226(4):421-6, discussion 427-8.
11. Schneider F, Falk V, Walther T, *et al.* Control of Endoaortic Clamp Position During Port-Access Mitral Valve Operations Using Transcranial Doppler Echography. *The Annals of Thoracic Surgery*. 1998 Jan 5;65(5):1481-2.
12. Colak Z, Borojevic M, Bogovic A, *et al.* Influence of intraoperative cerebral oximetry monitoring on neurocognitive function after coronary artery bypass surgery: a randomized, prospective study. *European Journal of Cardio-Thoracic Surgery*. 2015 Mar;47(3):447-54.
13. Marullo A, Irace FG, Vitulli P. Recent Developments in Minimally Invasive Cardiac Surgery: Evolution or Revolution? *Biomed Res Int*. 2015:483025. doi: 10.1155/2015/483025. Epub 2015 Oct 8.
14. Mazine A, Pellerin M, Lebon JS, *et al.* Minimally invasive mitral valve surgery: influence of aortic clamping technique on early outcomes. *Ann Thorac Surg*. 2013 Dec;96(6):2116-22.
15. Speziale G, Fattouch K, Romano V, *et al.* Minimally invasive mitral valve surgery: state-of-the-art and our experience. *European Heart Journal Suppl*. 2015; 17: A49-53.
16. Luca F, van Garsse L, Rao CM, *et al.* Minimally Invasive Mitral Valve Surgery: A Systematic Review. *Minimally Invasive Surgery*. Hindawi Publishing Corporation 2013 Mar 27;2013(1):1-10.
17. Colvin SB, Galloway AC, Ribakove G, *et al.* Port Access™ Mitral Valve Surgery. *Journal of Cardiac Surgery* 1998 Jul 1;13(4):286-9.
18. Murphy DA, Miller JS, Langford DA, *et al.* Endoscopic robotic mitral valve surgery. *The Journal of Thoracic and Cardiovascular Surgery*. 2006 Oct;132(4):776-81.
19. Casselman FP, Van Slycke S, Wellens F, *et al.* Mitral valve surgery can now routinely be performed endoscopically. *Circulation*. 2003 Sep 9;108 Suppl 1(90101): II48-54.
20. Bakir I, Casselman FP, Wellens F, *et al.* Minimally Invasive Versus Standard Approach Aortic Valve Replacement: A Study in 506 Patients. *The Annals of Thoracic Surgery*. 2006 May;81(5):1599-604.
21. Casselman FP, La Meir M, Jeanmart H, *et al.* Endoscopic mitral and tricuspid valve surgery after previous cardiac surgery. *Circulation*. 2007 Sep 11;116(11 Suppl): I270-5.
22. Zingone B, Gatti G, Rauber E, *et al.* Surgical management of the atherosclerotic ascending aorta: Is endoaortic balloon occlusion safe? *The Annals of Thoracic Surgery*. 2006 Nov;82(5):1709-14.
23. Vistarini N, Aiello M, Viganò M. Minimally invasive video-assisted cardiac surgery: operative techniques, application fields and clinical outcomes. *Future Cardiology*. 2011 Nov;7(6):775-87.

24. Aybek T, Doss M, Abdel-Rahman U, *et al.* Echocardiographic assessment in minimally invasive mitral valve surgery. *Med Sci Monit.* 2005 Apr;11(4):MT27-32. Epub 2005 Mar 24.
25. Reichenspurner H, Detter C, Deuse T, *et al.* Video and robotic-assisted minimally invasive mitral valve surgery: A comparison of the port-access and transthoracic clamp techniques. *The Annals of Thoracic Surgery.* 2005 Feb;79(2):485–91.
26. Ryan WH, Dewey TM, Mack MJ, *et al.* Mitral valve surgery using the classical “heartport” technique. *J Heart Valve Dis.* 2005 Nov;14(6):709–14–discussion714.
27. Gulielmos V, Wunderlich J, Dangel M, *et al.* Minimally invasive mitral valve surgery – clinical experiences with a Port Access system. *Eur J Cardiothorac Surg.* 1998 Oct 1;14(Supplement 1): S148–53.
28. Bentala M, Heuts S, Vos R, *et al.* Comparing the endo-aortic balloon and the external aortic clamp in minimally invasive mitral valve surgery. *Interact Cardiovasc Thorac Surg.* 2015 Sep;21(3):359–65.
29. Casselman F, Aramendi J, Bentala M, *et al.* Endoaortic Clamping Does Not Increase the Risk of Stroke in Minimal Access Mitral Valve Surgery: A Multicenter Experience. *The Annals of Thoracic Surgery.* 2015, 100(4):1334-1339.
30. Modi P, Hassan A, Chitwood WR. Minimally invasive mitral valve surgery: a systematic review and meta-analysis. *European Journal of Cardio-Thoracic Surgery.* 2008 Nov 1;34(5):943–52.

The Transthoracic Aortic Clamp

‘When you have eliminated the impossible, whatever remains, however improbable, must be the truth’

Introduction

The video-assisted right anterior minithoracotomy approach for open-heart surgery has become, progressively and rapidly, the preferred technique for many surgeons. The procedures commonly performed through this access include mitral valve repair or replacement, tricuspid valve repair or replacement, and closure of atrial septal defects (ASD). Some of the benefits this approach may offer are a shorter ICU and hospital stay and reduced blood loss [1]. From the patient’s perspective, it represents a certain cosmetic advantage, but more importantly, the recovery time and time to return to normal activities may be improved [2]. Some recent studies however have failed to substantiate these potential advantages. In a selected population group, there was shorter ICU stay but this did not translate into a shorter hospitalisation [3]. The disadvantage with this approach however remains the significantly longer durations of aortic cross-clamping and cardiopulmonary bypass (CPB), as well as a long learning curve [1].

However, with growing acceptance, an increasing number of surgeons are being trained in this approach and are adopting it into their daily practice. Although the core procedure and techniques remain similar to the median sternotomy approach, the minimal access procedure requires several technical modifications. Peripheral femoral arterial and venous cannulation have been used by the majority of surgeons for establishing cardiopulmonary bypass. The need to occlude the aorta and deliver cardioplegia led to the development of two very different alternative strategies and there remains disagreement and controversy around this issue.

Endoaortic Balloon Occlusion (EBO) - This consists of a triple lumen endovascular catheter having an inflatable balloon in order to occlude the aorta. Passed into the femoral arterial cannula through a side arm, it is positioned so that the balloon is in the ascending aorta. When inflated, it occludes the aorta internally and allows cardioplegia delivery through the central lumen.

The Transthoracic clamp (TTC) - This technique requires a special clamp on a long shaft which may be either rigid, as in the ‘*Chitwood clamp*’, flexible as in the ‘*Cosgrove clamp*’ or with combined features as in the ‘*Cygnets clamp*’ (Vitalitec, Plymouth, MA.). The Chitwood clamp is introduced into the chest cavity through a separate 5mm incision in the right axilla. Following aortic clamping, cardioplegia is delivered through a 29cm catheter inserted into the proximal ascending aorta.

Both methods have advantages and disadvantages and this has generated much debate about the superiority of one over the other. This section deals with the TTC and describes the advantages and disadvantages of this technique as compared with those of the endoballoon.

Advantages of the Transthoracic Clamp:

The biggest advantage of the TTC lies in its reusability. Being made of stainless steel, the clamp can be resterilised and this reduces the cost of disposable materials. The endoballoon is a single use device and costs in excess of €2000.

The learning curve is shorter as the TTC technique is akin to aortic clamping in cardiac surgical procedures via median sternotomy. This is a big advantage compared to the complex management protocols involved in the use of the endoballoon. The management of the endoballoon requires the concerted involvement of the perfusionist, the anaesthetist and the scrub nurse as well as the surgeon. This involves training and a steep learning curve. By contrast, the surgeon alone can manage the placement of the TTC and this reduces the dependence on other people. The learning curve is also much shorter and consequently many feel that it makes the procedure safer.

Disadvantages of the Transthoracic Clamp:

There is a risk of damage to the left atrial appendage and the pulmonary artery in inexperienced hands due to the anatomical proximity of these structures to the posterior tine of the clamp as it passes through the transverse sinus. However, visualisation of the entire circumference of the ascending aorta, and its manipulation prior to the precise placement of the clamp, is easily obtained by temporarily reducing the pump flow. This manoeuvre may help prevent such injuries. Obliteration of the transverse sinus with adhesions from prior surgery makes TTC use in reoperative cases difficult.


The need to place the cardioplegia catheter in the ascending aorta may occasionally cause troublesome bleeding after removal of the catheter. This may be difficult to control due to the distance of the aorta from the chest wall.

Evidence in favour of and against the Transthoracic Clamp

There are no randomised trials to prove with any certainty the superiority of one technique over the other. There are observational studies, however, that have provided comparison of outcomes which may help the surgeon make the best choice.

Reichenspurner *et al.* [4] studied 120 patients undergoing video-assisted mitral valve surgery. Sixty patients had endoaortic balloon occlusion (the Port Access approach) and in the other sixty the Transthoracic clamp was used. There were 6 re-explorations for bleeding and 2 reconstructions of the femoral artery necessary following femoral cannulation in the Port Access group of patients, whereas in the Transthoracic clamp group there was only one re-exploration for bleeding. The duration of the surgical procedure was shorter with the Transthoracic clamp (mean 4.5 ± 3.5 hrs vs. 4.1 ± 3.2 hrs; $p = 0.07$) including the duration of aortic cross-clamping (89 ± 69 min. vs. 78 ± 65 min; $p = 0.08$). There were no deaths, strokes or aortic dissections in either group.

As a subgroup analysis of 1178 patients undergoing minimally invasive video-assisted mitral valve surgery, Modi *et al.* [5] reported a comparison of 579 patients with the Transthoracic clamp to 479 patients with EBO. The duration of the surgical procedure was longer in the EBO group. Similarly, the cardiopulmonary bypass (CPB)



time (149.0 ± 53.2 min. vs. 142.2 ± 48.8 min., $p = 0.03$) as well as the aortic occlusion time (112.0 ± 43.8 min. vs. 99.4 ± 35.8 min., $p < 0.0001$) were longer in the EBO group of patients. The incidence of stroke with EBO and TTC was 2.7% and 1.2% respectively, $p = 0.08$. There were 7 (1.5%) aortic dissections with the endoballoon (Type A -4 patients and Type B -3 patients) and 2 (0.4%) with the TTC (both type A, $p = 0.09$). There was a significantly higher rate of conversion to sternotomy (2.9% vs. 0.9%, $p=0.01$) with EBO. Median hospital stay was 7 days with EBO versus 5 days with TTC ($p < 0.001$). Mortality was similar in both groups.

In two other large comparisons, both techniques have been shown to have equivalent complication rates and outcomes. Glower *et al.* [6] reported 436 patients with EBO and 225 patients with TTC. Aortic occlusion and CPB times were not related to the method of aortic occlusion and the durations of hospital stay were equivalent. No complications could be attributed to EBO itself. Krapf *et al.* [7] studied a variety of minimally invasive operations including CABG, atrial septal defect closure (ASD) and mitral valve procedures. They found a similar incidence of major complications (including aortic dissection, major vessel perforation, injury of intrapericardial structures, limb ischaemia, myocardial infarction and neurologic events) – 4% ($n=12$) of 307 EBO patients and 2.4% ($n=11$) of 460 TTC patients ($p = 0.23$). Minor complications (including femoral vessel injury, groin bleeding or lymphatic fistula) were also similar in both groups - 10.1% ($n=31$) of EBO patients and 7.6% ($n=35$) of TTC patients ($p = 0.23$).

One important consideration is the neurological outcomes with the two techniques. An early publication by Onnasch *et al.* [8] compared 226 TTC cases with 209 Port-Access (EBO) cases with endoballoon use. They found 17 (8.1%) cases with neurological complications (stroke, transient hemiplegia) in the Port Access group and 4 (1.8%) cases in the TTC group ($p<0.05$). However, they also reported a reduction in neurological events after implementation of transcranial Doppler monitoring for the detection of balloon migration. Transthoracic clamping has been shown to have a higher incidence of microembolic events [9, 10] but this has not statistically influenced the incidence of neurological complications in large series [5,7].

In conclusion, the intraoperative management of the TTC is less complex and involves a shorter learning curve. The shorter CPB and cross-clamp times translate into shorter overall operative times. Another advantage of the TTC which is making it more attractive in the current financial climate is the cost reduction through its reusability. A more accurate and scientific comparison of these two methods of minimally invasive heart valve surgery may be obtained through a randomised controlled trial. This now appears to be just over the horizon.

References

1. Cheng DC, Martin J, Lal A, *et al.* Minimally invasive versus conventional open mitral valve surgery: a meta-analysis and systematic review. *Innovations (Phila)* 2011; 6:84-103.
2. Walther T, Falk V, Metz S, *et al.* Pain and quality of life after minimally invasive versus conventional cardiac surgery. *Ann Thorac Surg* 1999; 67:1643-7.
3. Cao C, Gupta S, Chandrakumar D, *et al.* A meta-analysis of minimally invasive versus conventional mitral valve repair for patients with degenerative mitral disease. *Ann Cardiothorac Surg* 2013;2(6):693-703.

4. Reichenspurner H, Detter C, Deuse T, *et al.* Video and robotic-assisted minimally invasive mitral valve surgery: a comparison of the Port-Access and transthoracic clamp techniques. *Ann Thorac Surg* 2005 Feb;79(2):485-90; discussion 490-1.
5. Modi P, Rodriguez E, Hargrove WC 3rd, *et al.* Minimally invasive video-assisted mitral valve surgery: a 12-year, 2-center experience in 1178 patients. *J Thorac Cardiovasc Surg* 2009 Jun;137(6):1481-7.
6. Glower DD, Desai B. Transaortic endoclamp for mitral valve operation through right minithoracotomy in 369 patients. *Innovations (Phila)*. 2010 Nov;5(6):394-9.
7. Krapf C, Wohlrab P, Häußinger S, *et al.* Remote access perfusion for minimally invasive cardiac surgery: to clamp or to inflate? *Eur J Cardiothorac Surg*. 2013 Nov;44(5):898-904.
8. Onnasch JF, Schneider F, Falk V, *et al.* Minimally invasive approach for redo mitral valve surgery: a true benefit for the patient. *J Card Surg*. 2002 Jan-Feb;17(1):14-9.
9. Maselli D, Pizio R, Borelli G, *et al.* Endovascular balloon versus transthoracic aortic clamping for minimally invasive mitral valve surgery: impact on cerebral microemboli. *Interact Cardiovasc Thorac Surg*. 2006 Apr;5(2):183-6. Epub 2006 Feb 2.
10. Loforte A, Luzi G, Montalto A, *et al.* Video-assisted minimally invasive mitral valve surgery: external aortic clamp versus endoclamp techniques. *Innovations (Phila)*. 2010 Nov;5(6):413-8.

Chapter 2

Current Controversy: Antegrade versus Retrograde Arterial Perfusion

Antegrade perfusion *Antonio Lio, Antonio Miceli and
Mattia Glauber*

Retrograde perfusion *Siôn G Jones and Paul Modi*

*The greatest miracle is to believe that you could make one.
The rest is rather simple.*

Antegrade Arterial Perfusion

“To give a reason for anything is to breed a doubt of it”

William Hazlitt (1778 - 1830)

Introduction

Minimally invasive cardiac surgery (MICS) is being performed at an increasing number of institutions and has become an alternative to the standard sternotomy, providing improved morbidity outcomes [1-5]. Early descriptions in the literature of MICS predominantly involved peripheral arterial cannulation through the femoral artery with endoaortic balloon occlusion (EBO, Port-Access) [6].

Nowadays, the development of innovative arterial and venous cannulation techniques has allowed surgeons to perform minimally invasive procedures with two types of perfusion strategy: retrograde arterial perfusion (RAP) with femoral artery cannulation, or antegrade arterial perfusion (AAP) with direct ascending aorta or axillary artery cannulation. While the upper ministernotomy provides standard cannulation of the ascending aorta, a right lateral minithoracotomy allows limited access to the ascending aorta and therefore it is predominantly performed with femoro-femoral bypass.

Compared with standard median sternotomy, MICS has shown a similar mortality and less postoperative morbidity, especially in elderly and frail patients [1-3, 7-12]. Despite these benefits, some studies have reported a greater incidence of neurological complications with a minimally invasive approach [13-16]. In a retrospective analysis of the Society of Thoracic Surgeons (STS) Adult Cardiac Surgery Database, Gammie *et al.* compared 4,322

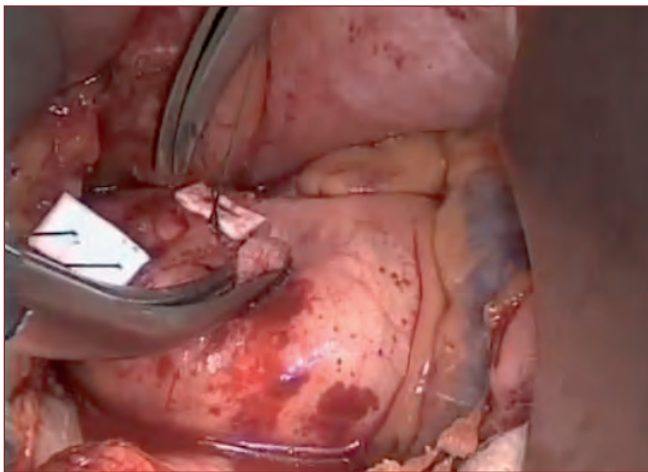


Fig 1: Purse-strings reinforced with two pledgets are placed on the antero-lateral aspect of the ascending aorta and the adventitia is prepared with scissors.

MICS operations with 23,821 standard sternotomy mitral surgical procedures and showed that “less invasive mitral valve surgery” was associated with a 2-fold increase in the risk of stroke [16].

In this setting, concerns have been raised regarding the best perfusion strategy to minimize the risk of neurological events [17-22]. Despite good results having been reported for both perfusion techniques [2,3,12], retrograde perfusion may be associated with local complications (infection, seroma), arterial wall dissection and/or pseudoaneurysm, and

distal limb ischemia [21]. Some retrospective studies have explored the possible association between RAP and cerebral complications. In this regard, in the presence of diffuse atherosclerotic disease, as well as in patients with aortic stenosis, the use of femoral artery perfusion is associated with the greatest risk for cerebral embolization [17-20, 22].

Antegrade perfusion has been advocated by certain groups in order to avoid these risks. This can be achieved by central aortic cannulation through the minithoracotomy incision or axillary artery cannulation with the

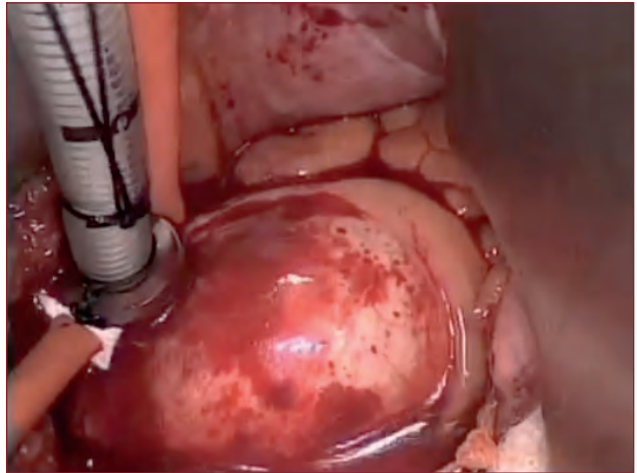


Fig 2: Aortic cannula is inserted and secured in place.

aim to respect physiological antegrade flow [17-20, 23-31]. In 1999, Glower *et al.* described a modification of the Port Access technique with direct aortic cannulation through a port in the first intercostal space in 52 patients and showed a significant reduction of EndoClamp migration and a lower incidence of stroke than in patients with femoral cannulation (4% vs 2%) [27, 28]. The group from New York University (NYU) Medical Center have published several interesting studies on this issue [17-19]. In 2010, a retrospective study on 905 reoperative mitral valve procedures performed either via median sternotomy (612 patients; 67.6%) or right thoracotomy (293 patients; 32.4%), confirmed that the incidence of stroke was associated with the perfusion strategy and not with the incisional approach [17]. In this series, 10.9% of patients with femoral artery perfusion sustained neurological complications whereas the rate of stroke in patients with aortic cannulation was 3.0%. On multivariate analysis, RAP was associated with a 4-fold increase in the risk of stroke.

The same authors presented an analysis of 3,180 isolated, non-reoperative mitral and aortic valve operations performed through a sternotomy (889 patients; 28%) or a minimally invasive approach (2291 patients; 72%) [18]. Antegrade perfusion was used in 2,646 (83.2%) cases, RAP was used in 534 (16.8%) cases. The overall rate of stroke was 2.2% with no differences between the two groups (2.1% vs 2.3%). However, in a multivariate analysis, retrograde perfusion was identified as a risk factor for death, any major complication and stroke. In a sub-analysis of patients younger than 50 years old, the perfusion strategy had no significant impact on neurological events (1.6% vs 1.1%, $p = 0.57$).

Finally, the same group performed a similar analysis in a more homogeneous subset of 1,282 patients who underwent first-time isolated mitral valve repair through a right anterior minithoracotomy over a 12-year period [19]. They again identified a clear association between the use of RAP and an increased risk of stroke (odd ratio, OR: 3.8, 95% confidence interval, CI: 1.7-8.1; $p = 0.001$) but only in those where retrograde arterial perfusion was considered a 'high-risk' procedure, such as patients with peripheral vascular disease, cerebrovascular disease, dialysis and significant aortic atherosclerosis.

Our group has performed an analysis of a large cohort of homogeneous patients showing that RAP was associated with a greater incidence of stroke and postoperative delirium when

compared with AAP, even after propensity matching [20]. The analysis was performed on 1280 consecutive patients undergoing primary minimally invasive mitral valve surgery of whom 167 (13%) had RAP and 1113 (87%) had AAP. Although the mortality rate of the two groups was similar, the negative impact of femoral perfusion was confirmed in the multivariate analysis where the use of RAP was an independent risk factor for neurological complications. Moreover, another important finding of the study was the higher incidence of perioperative aortic dissection in the RAP group related to use of the endoballoon [20].

Interestingly, in all these studies, the association of retrograde perfusion and neurologic complications was not significant in young patients. Moreover, the robotic mitral valve experience has also demonstrated a low incidence of stroke with peripheral cannulation [32-34]. A study by Nifong *et al.* of 540 consecutive robotic mitral valve repairs using a transthoracic clamp reported a stroke rate of 0.6% [32]; likewise, Murphy *et al.* demonstrated a stroke rate of 1.6% with use of the endoballoon [33]. These data suggest that selected low risk patients without comorbidities are good candidates for RAP with a risk of neurologic complications that is not different from that of patients treated with central aortic perfusion. In the presence of aortic and peripheral vascular disease, the use of femoral perfusion is associated with an increased risk of neurological events. This association is of particular interest in patients undergoing minimally invasive aortic valve replacement for aortic stenosis because of the older age and significant comorbidities of this population.

Axillary artery cannulation has emerged as an alternative site for cannulation during minimally invasive procedures. Compared to the femoral artery, the axillary artery allows antegrade perfusion and is generally free from atherosclerosis [29-31]. However, the limitations of this type of cannulation include a longer surgical procedure, especially in obese patients, and caution to avoid brachial plexus injury during the dissection. Experience with axillary artery cannulation in MICS is still limited and so the available data are inconclusive.

Central aortic cannulation in MICS: a 10-year experience

Our experience with the right minithoracotomy approach started with femoral arterial and venous perfusion and endoaortic balloon occlusion. After gaining familiarity with this approach, we developed a structured protocol to reduce the incidence of neurological complications in MICS. Our strategy now consists of avoiding RAP whenever possible, performing direct ascending aorta cannulation and transthoracic aortic clamping. Femoral artery cannulation is restricted to circumstances where direct cannulation of the ascending aorta is not suitable, such as redo-cases or adverse anatomical conditions.

Operative technique

The mitral valve procedure is carried out through a 5 cm lateral incision in the 4th intercostal space with the middle part of the incision positioned in the anterior axillary line. We started with a more anterior incision to allow the surgeon easier and safer manipulation of the ascending aorta during aortic cannula placement and removal. As our experience grew, we moved to a more lateral submammary incision in almost all patients, which gives better visualization of the field and perfect valve exposure. Once the minithoracotomy is performed, two axillary working ports are established - a 10.5mm working port is used for video assistance and for passing the pericardial stay sutures, and another 5.5mm port

is placed two intercostal spaces lower in the mid-axillary line for the cardiotomy vent, CO₂ insufflation and for other pericardial stay sutures.

In aortic valve procedures, the right minithoracotomy is made in the 2nd intercostal space without rib resection adjacent to the sternum. The pericardium is then opened, keeping the incision approximately 3–4 cm above the phrenic nerve and extending the incision upwards to expose the ascending aorta up to the origin of the innominate artery. It is very important to retract the pericardium to allow the ascending aorta to be adequately exposed. Two concentric 2-0 polyester purse-string sutures are placed on the anterolateral aspect of the ascending aorta with the second purse-string reinforced with two pledgets. During placement of the purse-string sutures, the aorta can be kept steady using locking forceps to reduce physiological motion (Figure 1). In mitral valve procedures, the cannulation site is generally chosen by identifying the transverse sinus as the landmark where the posterior tine of the aortic cross-clamp will be placed.



Before inserting the arterial cannula, we prefer to cannulate the femoral vein to allow the patient to be transfused if necessary. Following this, direct ascending aortic cannulation is performed under direct vision with pharmacologic induction of hypotension (systolic arterial pressure <90 mmHg). The lungs must be deflated prior to aortic cannulation. The adventitia is prepared with scissors and the aortic cannula is advanced into the aorta (Figure 2). We use two different cannulae for aortic cannulation based on the patient's body surface area, thoracic anatomy and surgeon's individual choice: EasyFlow aortic (Sorin Group, Saluggia, Italy) or the StraightShot aortic cannula (Edwards Lifesciences, Irvine, CA.).

At the end of the procedure, we first remove the arterial cannula under systemic hypotension whilst the femoral venous cannula is left in place to transfuse the patient's residual blood from the reservoir. If the cannulation site is particularly far from the thoracotomy, the purse-string can be knotted with the help of a knot-pusher. We prefer to snare the first purse-string immediately after cannula removal and knot the second purse-string. The first purse-string is then released and knotted.

Results

Since 2005 we have performed direct ascending aortic cannulation for both mitral and aortic valve procedures. A total of 1604 consecutive patients have undergone mitral valve surgery through a right minithoracotomy. Direct ascending aorta cannulation was achieved in 1325 (83%) patients; in 279 (17%) retrograde perfusion through the femoral artery was performed. Overall mortality was 1.1% (n=19) with no differences between the two groups (1.2% vs 1.1%, AAP versus RAP respectively, p=0.85). Stroke occurred in 2% (n=32) and RAP was associated with a significantly higher incidence of stroke than AAP group (4.3% vs. 1.5% respectively, p=0.002). No intraoperative aortic dissections were observed with antegrade perfusion and conversion to sternotomy to gain control of the cannulation site was necessary in two cases. Multivariate regression analysis revealed that the use of RAP was an independent risk factor for stroke (OR 4.28, 95% CI 1.73-10.43, p = 0.02) and postoperative delirium (OR 3.51, 95% CI 1.83-5.06, p=0.001).



For aortic valve disease, the right minithoracotomy approach was used in 593 patients. In 535 (90%) patients, we performed direct ascending aorta cannulation. A femoro-femoral platform was used in 58 patients (10%). Similarly, RAP was associated with a similar in-hospital mortality compared with AAP (1.1% vs. 1.2% respectively, $p=0.85$) but with a higher incidence of postoperative stroke (4.3% vs 1.5% respectively, $p=0.002$). In one patient in the AAP group, intraoperative conversion to sternotomy was necessary for bleeding at the cannulation site. No intraoperative aortic dissections occurred in the right minithoracotomy AVR patients.

Conclusions

Femoral artery cannulation with retrograde perfusion was the preferred method of perfusion in our early experience with minimally invasive cardiac surgery. Despite good results being reported, several studies have shown that an antegrade perfusion strategy is associated with a lower incidence of neurological complications. Ascending aortic cannulation with antegrade perfusion has several advantages when compared to femoral artery cannulation. It guarantees a more “physiological” perfusion, potentially reduces the risk of cerebral embolization of atheromatous debris (from the abdominal or descending thoracic aorta) or iatrogenic aortic dissection, and avoids complications related to groin incisions. Retrograde perfusion is associated with an increased risk of stroke, especially in older patients or those with significant aortic atherosclerosis, and in these patients preoperative evaluation of the aortoiliac axis is mandated.

In conclusion, despite central aortic cannulation being viewed as more challenging than femoral artery cannulation, it can be performed safely with a very low incidence of neurological and vascular complications.

References

1. McClure RS, Cohn LH, Wiegnerck E, *et al.* Early and late outcomes in minimally invasive mitral valve repair: an eleven-year experience in 707 patients. *J Thorac Cardiovasc Surg* 2009; 137:70–5.
2. Modi P, Rodriguez E, Hargrove WC III, *et al.* Minimally invasive video-assisted mitral valve surgery: a 12-year, 12-center experience in 1178 patients. *J Thorac Cardiovasc Surg* 2009; 137:1481–7.
3. Seeburger J, Borger MA, Falk V, *et al.* Minimal invasive mitral valve repair for mitral regurgitation: results of 1339 consecutive patients. *Eur J Cardiothorac Surg* 2008; 34:760–5.
4. Torracca L, Lapenna E, De Bonis M, *et al.* Minimally invasive mitral valve repair as a routine approach in selected patients. *J Cardiovasc Med* 2006; 7:57–60.
5. Tesler UF. Mitral valve repair: historical evolution and what lies ahead. *Tex Heart Inst J* 2012; 39:862–5.
6. Mohr FW, Falk V, Diegeler A, *et al.* Minimally invasive port-access mitral valve surgery. *J Thorac Cardiovasc Surg* 1998; 115:567–74.
7. Lamelas J, Sarria A, Santana O, *et al.* Outcomes of minimally invasive valve surgery versus median sternotomy in patients 75 years or greater. *Ann Thorac Surg* 2011; 91:79–84.
8. Santana O, Reyna J, Grana R, *et al.* Outcomes of minimally invasive valve surgery versus standard sternotomy in obese patients undergoing isolated valve surgery. *Ann Thorac Surg* 2011; 91:406–10.

9. Cohn LH, Adams DH, Couper GS, *et al.* Minimally invasive cardiac valve surgery improves patient satisfaction while reducing cost of cardiac valve replacement and repair. *Ann Surg* 1997; 226:421-8.
10. Svensson LG, Atik FA, Cosgrove DM, *et al.* Minimally invasive versus conventional mitral valve surgery: a propensity-matched comparison. *J Thorac Cardiovasc Surg* 2010; 139:926-32.
11. Iribarne A, Russo MJ, Easterwood R, *et al.* Minimally invasive versus sternotomy approach for mitral valve surgery: a propensity analysis. *Ann Thorac Surg* 2010; 90:1471-8.
12. Grossi EA, Galloway AC, LaPietra A, *et al.* Minimally invasive mitral valve surgery: a 6-year experience with 714 patients. *Ann Thorac Surg* 2002; 74:660-4.
13. Modi P, Hassan A, Chitwood WR. Minimally invasive mitral valve surgery: a systematic review and meta-analysis. *Eur J Cardiothorac Surg* 2008; 34:943-52.
14. Cheng DC, Martin J, Lal A, *et al.* Minimally invasive versus conventional open mitral valve surgery: a meta-analysis and systematic review. *Innovations* 2011; 6:84-103.
15. Svensson LG, Gillinov AM, Blackstone EH, *et al.* Does right thoracotomy increase the risk of mitral valve reoperation? *J Thorac Cardiovasc Surg* 2007; 134:677-82.
16. Gammie JS, Zhao Y, Peterson ED, *et al.* Less-invasive mitral valve operations: trends and outcomes from the Society of Thoracic Surgeons Adult Cardiac Surgery Database. *Ann Thorac Surg* 2010; 90:1401-8.
17. Crooke GA, Schwartz CF, Ribakove GH, *et al.* Retrograde arterial perfusion, not incision location, significantly increases the risk of stroke in reoperative mitral valve procedures. *Ann Thorac Surg* 2010; 89:723-30.
18. Grossi EA, Loulmet DF, Schwartz CF, *et al.* Minimally invasive valve surgery with antegrade perfusion strategy is not associated with increased neurological complications. *Ann Thorac Surg* 2011; 92:1346-50.
19. Grossi EA, Loulmet DF, Schwartz CF, *et al.* Evolution of operative techniques and perfusion strategies for minimally invasive mitral valve repair. *J Thorac Cardiovasc Surg* 2012;143(suppl): S68-70.
20. Murzi M, Cerillo AG, Miceli A, *et al.* Antegrade and retrograde arterial perfusion strategy in minimally invasive mitral-valve surgery: a propensity score analysis on 1280 patients. *Eur J Cardiothorac Surg* 2013;43: e167-72.
21. Cuenca J, Rodriguez-Delgadillo MA, Valle JV, *et al.* Is the femoral cannulation for minimally invasive aortic valve replacement necessary? *Eur J Cardiothorac Surg* 1998;14 Suppl 1: S111-4.
22. Chan EY, Lumbao DM, Iribarne A, *et al.* Evolution of cannulation techniques for minimally invasive cardiac surgery: a 10-year journey. *Innovations* 2012; 7:9-14.
23. Glauber M, Miceli A, Bevilacqua S, *et al.* Minimally invasive aortic valve replacement via right anterior minithoracotomy: early outcomes and midterm follow-up. *J Thorac Cardiovasc Surg* 2011; 142:1577-9.
24. Glauber M, Murzi M, Solinas M. Central aortic cannulation for minimally invasive mitral valve surgery through right minithoracotomy. *Ann Cardiothorac Surg* 2013; 2(6):839-40.
25. Murzi M, Glauber M. Central versus femoral cannulation during minimally invasive aortic valve replacement. *Ann Cardiothorac Surg* 2015; 4(1):59-61.
26. De Jong A, Popa BA, Karazanishvili L, *et al.* Perfusion techniques for minimally invasive valve procedures. *Perfusion* 2015; 30(4):270-6.
27. Glower DD, Clements FM, Debruijn NP, *et al.* Comparison of direct aortic and femoral cannulation for Port-Access cardiac operations. *Ann Thorac Surg* 1999; 68:1529-31.

28. Glower DD, Komtebedde J, Clements FM, *et al.* Direct aortic cannulation for Port-Access mitral or coronary artery bypass grafting. *Ann Thorac Surg* 1999; 68:1878-80.
29. Hysi I, Guesnier L, Gautier L, *et al.* Axillary artery cannulation for aortic valve replacement through right anterior minithoracotomy. *Int J Cardiol* 2014;177(2):664-5.
30. Kilo J, Ruttman-Ulmer E, Grimm M, *et al.* Minimally invasive mitral valve reconstruction on the fibrillating heart for high-risk patients. *J Heart Valve Dis.* 2013; 22(5):665-8.
31. Farivar RS, Fernandez JD. Use of axillary cannulation for simultaneous endo-occlusion and antegrade perfusion during minimally invasive surgery. *Innovations.* 2012; 7(3):201-3.
32. Nifong LW, Rodriguez E, Chitwood WR. 540 Consecutive robotic mitral valve repairs including concomitant atrial fibrillation cryoablation. *Ann Thorac Surg* 2012; 94:38-43.
33. Murphy DA, Miller JS, Langford DA, *et al.* Endoscopic robotic mitral valve surgery. *J Thorac Cardiovasc Surg* 2006; 132:776-81.
34. Mihaljevic T, Jarrett CM, Gillinov AM, *et al.* Robotic repair of posterior mitral valve prolapse versus conventional approaches: potential realized. *J Thorac Cardiovasc Surg* 2011; 141:72- 80.

Retrograde Femoral Arterial Perfusion

“Anyone who is practically acquainted with scientific work is aware that those who refuse to go beyond fact, rarely get as far as fact”

Thomas Henry Huxley (1825 - 1895)

Introduction

Conventional median sternotomy as a surgical approach to the mitral valve yields excellent short and long-term results and has set an extremely high standard [1]. More recently, less invasive approaches have been introduced, including the right anterolateral minithoracotomy (2-6cm), with or without robotic assistance, in order to reduce the surgical trauma and speed recovery. Compared to a sternotomy, it has been shown to be associated with comparable short and long-term mortality but reduced pain, blood loss and post-operative occurrence of atrial fibrillation (AF). The duration of ventilation, intensive care unit (ICU) and hospital stay are also shortened, and there are obviously fewer sternal complications [2]. However, perhaps the greatest benefit is one that is most difficult to measure and that is speed of recovery once the patient leaves hospital with return to normal activity in 3-4 weeks rather than 2 to 3 months with a sternotomy [3-5].

Limited intraoperative exposure requires extensive modification of the surgical technique. The standard set-up utilises retrograde arterial perfusion (RAP) through the femoral artery although several centres have evolved to central cannulation with antegrade aortic perfusion (AAP) due to concerns about the risk of stroke with RAP [6-8]. Central cannulation requires some modification of the incision location with a more anterior, superior (3rd intercostal space rather than 4th) and larger incision to facilitate cannulation. Critics claim that this may negate many of the benefits of the small non-rib spreading lateral minithoracotomy used in robotic and video-assisted approaches. Certainly, the ascending aorta is not readily accessible with these latter procedures.

Femoral cannulation and local complications

Femoral artery cannulation is performed with a 19-23F cannula in the majority of patients and this allows adequate flow together with passage of an endoaortic balloon if needed [9-10]. However, femoral access may be associated with site-specific complications such as groin wound infection, seroma and peripheral arterial injury. In an early series describing the use of femoral cannulation for a heterogeneous group of mitral valve and coronary artery bypass procedures, Glower *et al.* reported a femoral/groin complication rate of 10% of only 165 patients but did not detail the nature of these complications [11]. The combination of a group of patients undergoing mitral valve (MV) surgery with another group having coronary artery bypass surgery makes translation of these results to a purely mitral group difficult, as coronary artery disease has the same risk factors as peripheral arterial disease.


Two larger retrospective studies have described a lower incidence of peripheral arterial complications following femoral cannulation for minimally invasive cardiac surgery [9-10]. In the first series of 739 patients, no routine preoperative screening was utilised, but if the femoral pulse was weak or the artery was found to be calcified or diseased an alternative route was used. Additionally, a transoesophageal echo finding of severe atheromatous disease of the thoracic aorta was considered a contraindication to retrograde femoral perfusion. In this series femoral artery occlusion occurred in 0.68% of patients with aortic dissection in 0.27% [9]. In the second retrospective analysis from Hugo Vanermen's group, the incidence of peripheral vascular complications in 978 patients undergoing minimally mitral and/or tricuspid surgery was only 1% [10]. There were aortic complications in 0.9% of this cohort. Unlike the previous authors, this group visualised the iliofemoral arteries preoperatively, either at the time of coronary angiography or with MRI.

Concerns regarding higher stroke risk with retrograde arterial perfusion

In 2010, an analysis of 28,143 isolated primary MV operations for mitral regurgitation (MR) from the Society of Thoracic Surgeons (STS) Adult Cardiac Surgical Database (ACSD) over a 5-year period from 2004-2008 suggested that there was a 1.96-fold increase in the risk of stroke with less invasive mitral valve surgery (LIMV) despite a lower risk profile for these patients [12]. This was partly driven by a threefold increase in stroke with a beating or fibrillating heart although once these patients were excluded from the analysis, the risk of stroke still remained higher in the LIMV group although less so (1.52% vs 0.92%, LIMV vs sternotomy respectively, $p=0.0002$).

A number of caveats must be made when examining this data: the authors state that they used femoral arterial cannulation as a surrogate for LIMV surgery as there was no field on the STS database for incision type during this time period. An analysis of data from the previous dataset revealed that 5% of patients having femoral cannulation had a sternotomy incision. Secondly, a number of centres performing LIMV surgery operated on only a small number of patients per year, with only 66 (35%) of the 186 centres performing more than 5 LIMV cases in the final year of the analysis; the median number across all units was 3 cases a year. These data suggest that centres were at an early stage of their learning curve. We have learned from Prof Mohr's group in Leipzig that this is an operation with a long learning curve (75-125 cases) with better results achieved by surgeons who do more than one case per week [13]. Thus, on average, it would take only one surgeon in each unit a whole career to traverse the learning curve. Assessing results of a procedure performed by surgeons still in their learning curve will clearly bias the results.

Nevertheless, this was followed in 2011 by a consensus statement from the International Society for Minimally Invasive Cardiothoracic Surgery (ISMICS) based on a meta-analysis of 35 studies (only two of which were randomised trials) [2]. This documented a 1.79



times increase in the risk of stroke with a minimally invasive approach but on subgroup analysis this appeared driven by a higher stroke risk in those studies reporting endoaortic balloon occlusion (relative risk 1.72, $p=0.09$) and not transthoracic clamping (relative risk 0.80, $p=0.85$). This introduces another confounding variable in interpreting data from studies which include both external and endoaortic clamping. However, any meta-analysis is limited by the quality of the available studies

and for the analysis of stroke risk there were only 11 of 35 studies suitable for inclusion, five of these published prior to 2003 on data going back to 1996, that is, on data from the very beginning of the learning curve. And again we come back to the confounding variable of the learning curve for this operation. Clearly the writing committee were concerned about the data quality as they concluded that “the available evidence consists almost entirely of observational studies and must not be considered definitive until future RCTs address the risk of stroke”.

The New York University (NYU) group, who have moved from retrograde to antegrade perfusion, published three important papers in successive years from 2010. In the former, they reported on 905 high-risk reoperative mitral procedures, two-thirds of which had concomitant surgical procedures and half of which were older than 70 years of age [14]. The risk of stroke with retrograde arterial perfusion was 4.4 times higher than with antegrade perfusion for the whole cohort. However, this data needs to be interpreted in the knowledge that for isolated mitral valve reoperations there was no significant difference in the stroke rate and in the conference discussion that followed the authors accepted that these were very high-risk atherosclerotic patients and that it is only in these patients that retrograde perfusion carried an increased risk.

The following year, the same group looked at a heterogeneous group of 3,180 primary isolated minimally invasive mitral and aortic operations and noted a 3.4 times increase in the risk of stroke with RAP [15]. This is lower than their figures in the previous publication, presumably because reoperations were excluded from the analysis. Importantly there was no difference in patients under 50 years of age presumably due to less atherosclerosis burden. Thus, one begins to appreciate from all these papers reporting stroke risk that the common mechanism is the *burden of atherosclerosis* of the study population.

Glauber’s group in Massa, Italy, have recently documented a 4.28 times increase in stroke risk with RAP in 1280 patients undergoing primary minimally invasive mitral valve surgery [8]. Retrograde perfusion was used at the start of their learning curve and one-third of these had endoaortic balloon occlusion, whereas all patients who were perfused antegradely had external aortic clamping. The ISMICS meta-analysis suggested that the majority of strokes occurred in patients described in studies using endoaortic cross-clamping [2]. Thus, we come back again to confounding variables, in this case the learning curve and aortic occlusion technique.

However, for every study that reports a higher stroke risk with MIMVS, there are studies reporting no difference in the stroke risk. Another meta-analysis on this subject published in 2008 concluded that of six eligible studies, there was no significant difference in the neurological event rate (odds ratio 0.66, 95% confidence interval (CI) 0.23-1.93, $p=0.45$) [5]. The following year, the combined Chitwood/Hargrove series of almost 1200 patients undergoing non-robotic MIMVS reported a stroke rate of only 1.2% for transthoracic clamping [16]. Also from the Chitwood group, the stroke rate was only 0.6% in 540 consecutive robotic MV repairs and this was without pre-operative aortic CT screening [17]. In comparison, the data from all units in the UK from 2004-8 where over 95% of isolated mitral valve operations are still performed through a sternotomy, revealed a stroke rate of 1.4% (www.bluebook.scts.org). Three propensity matched studies from high-volume institutions (Cleveland, Leipzig, Mayo/UPenn) have all shown no difference in stroke risk with RAP compared to antegrade perfusion [18-20], as has the more recent propensity matched study from the Inova Heart and Vascular Institute which compared RAP and ventricular fibrillatory arrest with traditional open mitral valve surgery [21].

How can we make sense of this conflicting data?

Two recent studies have shed some light. Firstly, the NYU group finally looked at a much more homogenous group of 1280 patients undergoing primary isolated MIMV repair and concluded that the only significant risk factor for neurological events was the use of retrograde perfusion in high-risk patients with aortic disease (odds ratio 8.5, $p=0.04$) [6]. Aortic disease was defined on the basis of grade IV or V atheroma in the arch or descending aorta on intraoperative transoesophageal echo. Thus, it would seem likely that it is the characteristics of the NYU patient populations and their decreasing tendency to aortic atherosclerosis in each of their three consecutive manuscripts from the years 2010 (reoperations), 2011 (primary AV and MV) and 2012 (isolated primary MV repair) that explains their observation of a reduction in the odds ratio for stroke risk with each successive published article. This simply demonstrates that the risk factors for degenerative mitral valve disease are very different from those associated with aortic atherosclerosis or aortic valve disease, with the exception of age.

The second study is from the Cleveland Clinic group [22] who screened 141 low-risk patients being worked up for robotic MV surgery with contrast-enhanced multidetector CT (MDCT) of the chest, abdomen and pelvis, and found that 1 in 5 patients had significant subclinical aorto-iliac atherosclerosis where the term 'significant' was defined on the basis of circumferentiality and thickness, not grading as used in the previous paper. Multivariate logistic regression analysis found that significant atherosclerosis and age were associated with a change in operative strategy away from RAP to antegrade perfusion through a complete/partial sternotomy. One patient who was screened did have an embolic event and as there was no control group the authors did not demonstrate any association between avoidance of stroke and CT screening. Nevertheless, it would seem that omitting aortic screening may potentially miss subclinical aortoiliac disease in 1 in 5 patients and we know that RAP in the presence of 'severe' aortic atherosclerosis is a risk factor for stroke.

A further study by Youssef *et al.* adds to the evidence of an undetected burden of aortic atheroma which may increase the risk of retrograde perfusion [23]. These authors examined the role of CT angiography in the pre-operative assessment of patients considered for minimally invasive surgery (valvular procedures, AF surgery, atrial septal defect closure and myxoma excision). Exclusion criteria for minimally invasive surgery used by this group were: dilated ascending aorta, moderate or severe calcific or atheromatous disease of the aorta (at any point from root to bifurcation) as well as evidence of tortuous iliac arteries. Of the 111 patients considered for minimally invasive procedures, 35 (32%) were deemed unsuitable due to the findings of the arterial imaging.

A single surgeon experience reporting 73 consecutive minimally invasive mitral procedures with retrograde femoral perfusion and endoaortic balloon occlusion, who all underwent pre-operative aortoiliac screening with either CT or magnetic resonance (MR) angiographic imaging, reported no cases of mortality, strokes or peripheral vascular complications [24].



If we now consider the Chamberlain Memorial paper by Gammie *et al.* in light of all this data, we see that there is no data on peripheral vascular disease (PVD) or its extent and it seems unlikely that the LIMV patients were screened for aortic atheroma during that time period [12]. Similarly, in the ISMICS

Consensus Statement, only one of the 11 studies included in the stroke analysis either gives data on the incidence of PVD or the use of pre-op aortic screening [2]. Occult aortoiliac atherosclerosis and lack of assessment of the whole aortoiliac system, because the most common location for disease is at the abdominal aortic bifurcation, may explain the observations of a higher stroke risk with RAP.

There are clearly other considerations when assessing stroke risk with MIMVS compared to sternotomy, such as longer CPB times and adequacy of removing air from the heart chambers. However, parity in operative times is achieved with experience and, when CO₂ insufflation is utilised, there is evidence that there is no difference in cerebral microembolic rate as detected using transcranial Doppler even with endoaortic balloon occlusion [25]. Flooding the pleural cavity and the heart with several hundred litres of CO₂ during a procedure displaces all the air making air embolisation less of an issue.

Conclusions

Studies reporting higher stroke rates with RAP have multiple confounding factors that need to be borne in mind when interpreting the data. These include imprecise definitions of MIMVS, the effect of the substantial learning curve for the procedure in historic data, retrospective comparisons of small cohorts with baseline differences and differing risk profiles for atherosclerosis, different methods of aortic occlusion and lack of reporting of PVD / aortic assessment in patient populations.

In patients with severe arch / ascending / descending thoracic aortic atherosclerosis, RAP has clearly been shown to be associated with an increase in the risk of cerebral embolic complications. If grade IV or V atheroma in the arch has been shown to be associated with cerebral vascular accidents (CVA), then it would be reasonable to assume that grades IV/V atheroma anywhere along the aorto-iliac axis (from femoral cannulation site to carotid arteries) would also be associated with the same risk. Hence it is important to understand the atherosclerotic burden in patients being considered for RAP during MIMVS and it would therefore seem prudent to screen patients at risk of severe atherosclerosis. Screening all patients on the basis of Moodley *et al* [22] cannot be recommended as no association between a reduction in stroke risk and screening was demonstrated. Whether lesser grades of disease, such as II or III, are associated with a higher risk of stroke remains to be seen. Contrast-enhanced MDCT assesses both the quality of the vessel wall and luminal stenosis, and when combined with TOE provides a thorough assessment of the whole aortoiliac axis. Whether ultrasound scanning of the abdominal aorta and iliac system would provide the same data but without the radiation/contrast exposure remains to be seen. In these litigious times, assessment of atheroma burden in patients at risk of severe aortoiliac atherosclerosis would seem prudent.

References

1. Braunberger E, Deloche A, Berrebi A, *et al*. Very long-term results (more than 20 years) of valve repair with Carpentier's techniques in non-rheumatic mitral valve insufficiency. *Circulation*. 2001 Sep 18; 104(12 Suppl 1): I8-11.
2. Cheng DC, Martin J, Lal A, *et al*. Minimally invasive versus conventional open mitral valve surgery: a meta-analysis and systematic review. *Innovations* (Philadelphia, Pa.) 2011 Mar; 6(2):84-103.
3. Glower DD, Landolfo KP, Clements F, *et al*. Mitral valve operation via Port Access versus median sternotomy. *Eur J Cardiothorac Surg*. 1998 Oct; 14 Suppl 1: S143-7.

4. Casselman FP, Van Slycke S, Wellens F, *et al.* Mitral valve surgery can now routinely be performed endoscopically. *Circulation*. 2003 Sep 9;108 Suppl 1: II48-54.
5. Modi P, Hassan A, Chitwood WR, Jr. Minimally invasive mitral valve surgery: a systematic review and meta-analysis. *Eur J Cardiothorac Surg*. 2008;34(5):943-52.
6. Grossi EA, Loulmet DF, Schwartz CF, *et al.* Evolution of operative techniques and perfusion strategies for minimally invasive mitral valve repair. *The Journal of thoracic and cardiovascular surgery*. 2012 Apr;143(4 Suppl): S68-70.
7. Chan EY, Lumbao DM, Iribarne A, *et al.* Evolution of cannulation techniques for minimally invasive cardiac surgery: a 10-year journey. *Innovations (Philadelphia, Pa)*. 2012 Jan-Feb; 7(1): 9-14.
8. Murzi M, Cerillo AG, Miceli A, *et al.* Antegrade and retrograde arterial perfusion strategy in minimally invasive mitral-valve surgery: a propensity score analysis on 1280 patients. *Eur J Cardiothorac Surg*. 2013 Jun;43(6): e167-72.
9. Muhs BE, Galloway AC, Lombino M, *et al.* Arterial injuries from femoral artery cannulation with port access cardiac surgery. *Vasc Endovasc surg* 2005;39:153-158.
10. Jeanmart H, Casselman FP, De Grieck Y, *et al.* Avoiding vascular complications during minimally invasive, totally endoscopic intracardiac surgery. *J Thorac Cardiovasc Surg* 2007; 133: 1066-1070.
11. Glower DD, Clements FM, Debruijn NP, *et al.* Comparison of direct aortic and femoral cannulation for port-access cardiac operations. *Ann Thorac Surg* 1999; 68:1529-1531.
12. Gammie JS, Zhao Y, Peterson ED, *et al.* J. Maxwell Chamberlain Memorial Paper for adult cardiac surgery. Less-invasive mitral valve operations: trends and outcomes from the Society of Thoracic Surgeons Adult Cardiac Surgery Database. *The Annals of thoracic surgery*. 2010 Nov;90(5):1401-8, 10 e1; discussion 8-10.
13. Holzhey DM, Seeburger J, Misfeld M, *et al.* Learning minimally invasive mitral valve surgery: a cumulative sum sequential probability analysis of 3895 operations from a single high-volume center. *Circulation*. 2013 Jul 30;128(5):483-91.
14. Crooke GA, Schwartz CF, Ribakove GH, *et al.* Retrograde arterial perfusion, not incision location, significantly increases the risk of stroke in reoperative mitral valve procedures. *The Annals of thoracic surgery*. 2010 Mar;89(3):723-9; discussion 9-30.
15. Grossi EA, Loulmet DF, Schwartz CF, *et al.* Minimally invasive valve surgery with antegrade perfusion strategy is not associated with increased neurologic complications. *The Annals of thoracic surgery*. 2011 Oct;92(4):1346-9; discussion 9-50.
16. Modi P, Rodriguez E, Hargrove WC, *et al.* Minimally invasive video-assisted mitral valve surgery: a 12-year, 2-center experience in 1178 patients. *The Journal of thoracic and cardiovascular surgery*. 2009 Jun;137(6):1481-7.
17. Nifong LW, Rodriguez E, Chitwood WR, Jr. 540 consecutive robotic mitral valve repairs including concomitant atrial fibrillation cryoablation. *The Annals of thoracic surgery*. 2012 Jul;94(1):38-42; discussion 3.
18. Mihaljevic T, Jarrett CM, Gillinov AM, *et al.* Robotic repair of posterior mitral valve prolapse versus conventional approaches: potential realized. *The Journal of thoracic and cardiovascular surgery*. 2011 Jan;141(1):72-80 e1-4.
19. Holzhey DM, Shi W, Borger MA, *et al.* Minimally invasive versus sternotomy approach for mitral valve surgery in patients greater than 70 years old: a propensity-matched comparison. *The Annals of thoracic surgery*. 2011 Feb;91(2):401-5.

20. Suri RM, Schaff HV, Meyer SR, *et al.* Thoracoscopic versus open mitral valve repair: a propensity score analysis of early outcomes. *The Annals of thoracic surgery*. 2009 Oct;88(4):1185-90.
21. Ad N, Holmes SD, Shuman DJ, *et al.* Minimally invasive mitral valve surgery without aortic cross-clamping and with femoral cannulation is not associated with increased risk of stroke compared with traditional mitral valve surgery: a propensity score-matched analysis. *Eur J Cardiothorac Surg* 2015; doi:10.1093/ejcts/ezv017.
22. Moodley S, Schoenhagen P, Gillinov AM, *et al.* Preoperative multidetector computed tomography angiography for planning of minimally invasive robotic mitral valve surgery: impact on decision making. *The Journal of thoracic and cardiovascular surgery*. 2013 Aug;146(2):262-8 e1.
23. Youssef SJ, Millan JA, Youssef GM, *et al.* The role of computed tomography angiography in patients undergoing evaluation for minimally invasive cardiac surgery: an early program experience. *Innovations* 2015; 10:33-38.
24. Rosu C, Bouchard D, Pellerin M, *et al.* Preoperative vascular imaging for predicting intraoperative modification of peripheral arterial cannulation during minimally invasive mitral valve surgery. *Innovations* 2015; 10:39-43.
25. Schneider F, Onnasch JF, Falk V, *et al.* Cerebral microemboli during minimally invasive and conventional mitral valve operations. *The Annals of thoracic surgery*. 2000 Sep;70(3):1094-7.

Chapter 3

Debate: Should the First-Line Treatment for Non-Complex Degenerative Mitral Valve Disease in the 21st Century be by Minimal Access Surgery?

In favour: *Thilo Noack and Friedrich W Mohr*

Against: *Francis C Wells*

“Any system which is without its paradoxes is, by the same token, as suspicious as an exact correspondence of several witnesses in a trial at The Old Bailey”

Samuel Palmer (1805 -1881)

In Favour of Minimal Access Surgery

“Time wears out the error and polishes the truth”

Francois-Gaston de Levis (1720 - 1787)

Introduction

Moderate to severe mitral valve regurgitation (MR) has a prevalence of 10% in patients aged 75 years and older and a further increase can be expected in future due to aging of the population [1, 2]. Although in many instances MR may remain silent for a long period of time, its presence generally contributes to an impaired prognosis for the patient and therefore represents an important target for surgical and interventional treatment [3-6]. In Europe, MR is the second most frequent valve disease requiring surgical treatment [7].

In assessing the patient with MR, it is critical to distinguish between degenerative MR (DMR) and functional MR (FMR) [8]. In DMR, pathology of more than one of the components of the valve (leaflets, chordae tendinae, papillary muscles, annulus) causes valvular incompetence [8]. The most common dysfunction associated with DMR in developed countries is MV prolapse. Younger populations often present with severe myxomatous degeneration of the leaflets and chordae (aetiology: Barlow's valve). Alternatively, the most common aetiology in older patients is fibroelastic deficiency with a lack of connective tissue, which leads to chordal rupture. Other less common causes of MR include infective endocarditis, connective tissue disorders, rheumatic heart disease, cleft MV and radiation-induced valvular disease. In the untreated asymptomatic and symptomatic patients with MR, the chronic volume loading of the LV leads to myocardial damage, heart failure and eventual death [9, 10]. Therefore, the early diagnosis and correction of MR is important and in most cases curative [11].

The anatomic lesions of DMR are multiple and well described by Carpentier's functional classification. Approximately 50% of all DMR cases are non-complex DMR. The type of dysfunction is essential for surgical decision making in DMR. Surgical mitral valve repair (MVR) represents the therapy of choice for the treatment of DMR due to superior outcomes compared to valve replacement [8, 11]. Furthermore, minimally invasive mitral valve surgery (MIMVS) is already established as an alternative to MV surgery via a median sternotomy. In particular, decreased postoperative morbidity, length of hospital stay, lower healthcare costs, improved cosmesis and faster return to normal activity has led to a significant increase in MIMVS in Europe [12-14].

The present review article summarises the current published literature on MIMVS focussing on patient selection, indications, procedural success and outcomes.

History and development

Minimally invasive mitral valve surgery began in the mid-1990s and has grown to be an integral part of modern cardiac surgery over the last two decades in Western countries

[12]. In 1996, Alain Carpentier performed the first video-assisted mitral valve repair through a mini-thoracotomy under ventricular fibrillation [15]. Chitwood established transthoracic aortic clamping in 1997 [16, 17] followed by Mohr with the development of video-assisted port-access technology in 1998 that reduced the cardiopulmonary bypass and cross-clamp times and allowed better visualization of the valve [18]. Parallel to the developments in Europe, Cosgrove and Cohn established the lower hemisternotomy and the right parasternal incision as new minimally invasive approaches to the MV in North America [13, 19]. Finally, the use of robotic MVR has become an attractive technique, first performed by Carpentier and Mohr in 1998 using an early prototype of the da Vinci™ surgical system (Intuitive Surgical Inc., Sunnyvale, CA., USA) [20, 21]. Subsequently many changes have occurred and each technique has evolved. However, the most important thing to consider in any of these minimally invasive approaches is that each must yield results equal to or better than the sternotomy approach that it might replace [22].



Over the last two decades, MIMVS has emerged as routine practice and is well described in the literature [23-30]. In Germany, 47% of all isolated mitral valve surgery is performed using minimally invasive techniques [12]. At the Leipzig Heart Centre, MIMVS has grown to be the standard approach in up to 90% of cases of isolated MV surgery.

Approaches and Techniques

Currently, there are a number of different approaches and techniques which are used worldwide in the application of MIMVS [22]. The most often used techniques include: right lateral mini-thoracotomy, partial sternotomy and robotic MV surgery. The pros and cons of the different approaches are shown in detail in Table 1 overleaf.

Right mini-thoracotomy

Surgical access is through a small right lateral thoracotomy in the fourth or fifth intercostal space (ICS) in the inframammary groove using a soft tissue retractor and/or rib spreader. Cardiopulmonary bypass is established by either open or percutaneous femoral cannulation. A transthoracic cross-clamp (Chitwood clamp) is inserted through an axillary stab incision (third ICS) and the patient is cooled to 34°C [29]. Alternatively, an endoaortic balloon can be used to occlude the ascending aorta [28]. An atrial retractor improves MV exposure and is placed through the fourth ICS just to the right of the sternum. A cardioplegia needle is then inserted into the ascending aorta to deliver cardioplegia and to vent the root [17]. Alternatively, the operation can be performed without cross-clamping the aorta under hypothermic fibrillatory arrest (28°C) using a pacing Swan Ganz catheter to trigger ventricular fibrillation [28]. This technique requires that the aortic valve is competent and avoids myocardial ischemia. The operation can be performed under direct vision and/or with video assistance through an axillary port (2nd intercostal space).

In general, this approach is aided by shafted instruments [18, 31]. Additional procedures such as concomitant tricuspid valve repair, atrial septal defect (ASD) closure, left atrial appendage occlusion and ablation procedures for atrial fibrillation (AF) can also be performed using this approach.

Mini-sternotomy

This technique has been previously described [32, 33]. The mini-sternotomy is performed through the sternum from below upwards to the level of the second intercostal space on the right. The ascending aorta and superior vena cava are cannulated for cardiopulmonary bypass. This approach allows MVR, concomitant procedures such as ASD closure, left atrial appendage closure, cryoablation and aortic valve surgery.

Robotic surgery

Robotic MV surgery can be performed totally endoscopically through a non-rib spreading mini-thoracotomy using either of the two clamping technique [34-36]. The set-up is similar to a video-assisted 'mini mitral' with the right chest elevated by 30°, followed by bicaval venous cannulation (internal jugular, femoral) [36]. A 2-4cm working port incision is made in the fourth ICS anterior to the anterior axillary line (AAL). Trocars are placed in the fifth ICS at the AAL for the right arm, the third ICS anterior to the AAL for the left arm, and the final in the fourth ICS two finger breadths lateral to the mid-clavicular line for the dynamic atrial retractor. If transthoracic clamping is used, a cardioplegia needle is placed in the ascending aorta. Robotic MV surgery allows non-complex and complex MVR with limited triangular or quadrangular resection, folding valvuloplasty, chordal shortening, chordal translocation, papillary muscle folding, neochordae implantation and rarely a leaflet sliding plasty [36]. Additional procedures such as ASD closure, left atrial appendage closure and ablation can also be performed [36].

The Leipzig Mitral Valve Repair Technique

Surgical MVR is the first-line treatment of severe degenerative MR and recommended in the current ESC/EACTS guidelines [11]. Non-complex degenerative MR represents approximately 50% of all surgical cases and valve repair should be carried out according to three basic principles, introduced by Carpentier: (i) preserve or restore free leaflet motion,

Table 1: Pros and cons of different approaches for minimally invasive mitral valve surgery.

	Median sternotomy	Right mini thoracotomy	Mini sternotomy	Robotic surgery
Mitral valve surgery				
Exposure	++	++	++	++
Non-complex MVR	++	++	++	++
Complex MVR	++	++	-	+
MV replacement	++	++	++	-
Concomitant procedures				
TV repair	++	++	-	-
TV replacement	++	++	-	-
AF ablation	++	++	+	+
ASD closure	++	++	++	++
AV replacement	++	-	++	-

AF = atrial fibrillation; ASD = atrial septal defect; AV = aortic valve; MV = mitral valve; MVR = mitral valve repair; TV = tricuspid valve.

(ii) create a large surface of coaptation, and (iii) remodel the annulus [37]. Adopted from these principles, MV repair should generally be performed with leaflet resection and/or implantation of neochordae, combined with ring annuloplasty [30]. A ring annuloplasty is necessary to achieve a durable repair [38]. The choice of type and size of annuloplasty ring, number and length of neochordae and/or leaflet resection depends on the MV pathology.

Type and size of annuloplasty ring

In the majority of cases, we use a closed annuloplasty ring for annular remodelling. Annular remodelling should be performed in all patients with DMR for prevention and correction of annular enlargement and correct sizing is critical [39]. We recommend ring sizing according to the true size of the valve calculated by the intertrigonal distance and the anterior leaflet length. Patients with Carpentier's dysfunction type I and II MR should be treated with a closed saddle-shaped ring such as the Carpentier-Edwards Physio II ring (Edwards Lifesciences, Irvine, CA.). In patients with a restricted posterior leaflet secondary to ischemia (Carpentier functional class type IIIb), we perform either an annular remodelling with the IMR ETlogix ring (Edwards Lifesciences, Irvine, CA.) to increase coaptation length especially in the P3 segment, or a chord-sparing valve replacement.

Neochordae and/or leaflet resection

We favour the implantation of neochordae with the "loop technique" according to the principle "respect rather than resect" in non-complex and complex MVR. The "loop technique" has been well described previously [40, 41]. The implantation of neochordae leads to an imitation of native MV anatomy and physiological leaflet function. This results in an increase of mitral orifice area, an increase of coaptation length, an implantation of larger annuloplasty rings and higher freedom from reoperation compared to leaflet resection [42, 43]. The correct length of neochordae is essential in order to achieve the best functional result which is defined by the distance between the papillary muscle and the free margin of the non-prolapsing leaflet [41, 44]. There is no significant difference in long-term survival between these techniques [43].

Indication and patient selection

Minimally invasive mitral valve surgery has been applied to a wide spectrum of degenerative (primary) and functional (secondary) MR pathologies. Current patient selection criteria are based on clinical patient characteristics, echocardiographic findings and MV pathology (Table 2).

Current ESC/EACTS guidelines for the treatment of primary MR recommend valvular repair as the preferred technique when it is expected to be durable (Class I, level C) in symptomatic patients with a left ventricular ejection fraction (LVEF) $>30\%$ and left ventricular end-systolic diameter (LVESD) <55 mm (Class I, level B) [11]. Surgery is also indicated in patients with left ventricular (LV) dysfunction (LVESD ≥ 45 mm and/or LVEF $\leq 60\%$) (Class I). Surgery should also be considered in symptomatic and asymptomatic patients with new onset of AF, left atrial enlargement, and/or pulmonary hypertension (Table 2).




Table 2: Patient selection criteria for minimally invasive mitral valve surgery in non-complex degenerative mitral valve regurgitation [11].

Clinical criteria	<p>MVR should be the preferred technique when it is expected to be durable in:</p> <ul style="list-style-type: none"> * Symptomatic patients with LVEF >30% and LVESD <55 mm * Asymptomatic patients with: <ul style="list-style-type: none"> * LV dysfunction (LVESD ≥45 mm and/or LVEF ≤60%) and/or * New onset of AF or SPAP >50 mmHg and/or * High likelihood of long-lasting repair, low surgical risk, and presence of risk factors (flail leaflet and LVESD ≥40 mm; LA volume ≥60 ml/m² BSA and sinus rhythm; or SPAP ≥60 mmHg on exercise)
Anatomical criteria	<p>Annular dilatation and/or:</p> <ul style="list-style-type: none"> * Single segmental prolapse * Pliable leaflets * LVEDD <60 mm
Surgical criteria	<p>Suitable for isolated MV repair or replacement</p> <p>Concomitant procedures:</p> <ul style="list-style-type: none"> * Tricuspid valve repair or replacement * ASD closure * Ablation * Myectomy for HOCM

AF = atrial fibrillation; ASD = atrial septal defect; HOCM = hypertrophic obstructive cardiomyopathy; LVEDD = left ventricular end-diastolic diameter; LVEF = left ventricular ejection fraction; LVESD = left ventricular end-systolic diameter; MVR = mitral valve repair; SPAP = systolic pulmonary arterial pressure.

The surgical treatment of all non-complex DMR can be performed by the minimally invasive approach with MV repair or replacement. Concomitant procedures such as tricuspid valve surgery, AF ablation, ASD closure, myectomy for hypertrophic obstructive cardiomyopathy, and MV surgery post-sternotomy can also be performed using these minimally invasive techniques. The distance between the MV and the right chest wall must be taken into account for surgical planning due to the limited length of the shafted instruments. Obesity and chest wall deformities like pectus excavatum increase the level of difficulty and need to be evaluated by preoperative computer tomography (CT) scans [25].

There are several contraindications to using MIMVS which can be divided into absolute and relative (Table 3). The absolute contraindications are: previous right thoracotomy, heavily calcified MV annulus and aortic regurgitation more than mild. The relative contraindications are: redo-procedures, complex MV repair for non-experienced MVR surgeons, obese female with large breasts, MV endocarditis, descending aorta pathologies, chest wall abnormalities and unsuitable femoral vessels.

Outcomes and clinical events

The outcomes of MV surgery with the minimally invasive approach have been described in several single and multi-centre cohort studies [25, 27, 29, 30, 45-47]. MIMVS can be

performed with an overall successful repair rate of 80% and higher, which includes aetiologies such as infective endocarditis, rheumatic valvular disease or ischemic MR with severe restriction of leaflets [25, 27, 30, 47]. It is widely accepted that the repair rate increases with the decrease of the complexity of MVR. This leads to an increase of successful repair rates in patients with non-complex single leaflet prolapse to 91% for anterior mitral leaflet (AML) prolapse and to 97% for posterior mitral leaflet (PML) prolapse [48]. This is similar to the repair rate of 98% in patients undergoing MVR through a lower hemi-sternotomy [47]. Such a high repair rate is evidence enough that the outcome of MIMVS is more influenced by the valve pathology rather than the surgical approach [25].



Mini-mitral surgery in non-complex MR can be performed safely with a very low 30-day mortality of 1.2% to 2.6% [27, 48]. Furthermore, the national report of the German Society for Thoracic and Cardiovascular Surgery (GSTCS) showed a significantly lower 30-day mortality for isolated MIMVS of 1.6% when compared with the results of median sternotomy (6.4%) [12]. Excellent long-term outcomes can also be achieved with MIMVS as shown in several studies reporting a cumulative survival at 5 and 10 years of >85% and >74%, respectively [24, 25, 49, 50]. Long-term freedom from reoperation is reported as 96% and 92% after 5 years for MIMVS in PML prolapse and AML prolapse, respectively [48]. All reports have demonstrated that MIMVS can be performed with very favourable late outcomes when compared with those following sternotomy [12, 47].

Current evidence shows that, when compared with the sternotomy approach, MIMVS is associated with decreased bleeding and blood product transfusion. Atrial fibrillation and wound infection occur less often. The durations of ventilation as well as intensive care unit stay and hospitalisation are shorter. The time taken by patients to return to normal activities is also reduced and there is greater cosmetic satisfaction [23, 45, 51].

The rate of conversion to sternotomy following MIMVS is reported to be as low as 1.4% [25]. Unpublished analysis of our experience has shown that intraoperative bleeding (53%), pulmonary adhesions (18%) and iatrogenic aortic dissection type A (15%) are the most frequent causes for conversion to sternotomy. A reported stroke rate of 1.3% to 2% is the subject of continuing discussion in the comparison of MIMVS and sternotomy [27, 30,

Table 3: Absolute and relative contraindications for minimally invasive mitral valve repair.

Absolute contraindication	Previous right thoracotomy Severe MV annulus calcification Aortic regurgitation >grade I
Relative contraindication	Reoperative surgery Complex MVR for non-experienced MVR surgeons Obese female with large breasts MV endocarditis Pathology of the descending aorta Chest deformation and/or abnormalities Unsuitable femoral vessels for cardiopulmonary bypass

MV = mitral valve; MVR = mitral valve repair

46]. The latest data demonstrate that MIMVS is not associated with an increased risk for stroke compared to sternotomy [46].

Training and Learning Curves

It is known that MIMVS is associated with a long learning curve [52]. Although the number of operations required to gain proficiency is substantial, marked variation exists between individual surgeons. Furthermore, experienced MVR surgeons demonstrate in reported single-surgeon experiences outstanding results with a near 100% repair rate in non-complex MR and excellent short-term and long-term survival [24, 50, 53]. In addition, these results suggest that the adoption of MIMVS should be restricted to centres with a large volume of mitral valve procedures [52].

Conclusion

Minimally invasive mitral valve surgery can be safely and effectively performed with excellent short and long-term outcomes in patients with non-complex degenerative MR. It is associated with very low rates of conversion to sternotomy. The failure rate of repairs is extremely low, especially in the hands of experienced surgeons. Minimally invasive mitral valve surgery has blood product, ventilation time, intensive care unit stay, hospital length of stay, respiratory, pain and cosmetic advantages over conventional surgery. It should only be performed by experienced mitral surgeons trained in the technique in high volume centres.

References

1. Nkomo VT, Gardin JM, Skelton TN, *et al.* Burden of valvular heart diseases: a population-based study. *Lancet*. 2006;368(9540):1005-11.
2. Meinertz T, Diegeler A, Stiller B, *et al.* German Heart Report 2013. *Thorac Cardiovasc Surg*. 2015;63(2):86-96.
3. Avierinos JF, Gersh BJ, Melton LJ, 3rd, *et al.* Natural history of asymptomatic mitral valve prolapse in the community. *Circulation*. 2002;106(11):1355-61.
4. Bursi F, Enriquez-Sarano M, Nkomo VT, *et al.* Heart failure and death after myocardial infarction in the community: the emerging role of mitral regurgitation. *Circulation*. 2005;111(3):295-301.
5. Gaemperli O, Corti R. MitraClip for the treatment of mitral regurgitation. *Cardiovascular Medicine*. 2012;15(10):276-86.
6. Grigioni F, Enriquez-Sarano M, Zehr KJ, *et al.* Ischemic mitral regurgitation: long-term outcome and prognostic implications with quantitative Doppler assessment. *Circulation*. 2001;103(13):1759-64.
7. Jung B, Baron G, Butchart EG, *et al.* A prospective survey of patients with valvular heart disease in Europe: The Euro Heart Survey on Valvular Heart Disease. *Eur Heart J*. 2003;24(13):1231-43.
8. Nishimura RA, Otto CM, Bonow RO, *et al.* 2014 AHA/ACC guideline for the management of patients with valvular heart disease: executive summary: a report of the American College of Cardiology/American Heart Association Task Force on Practice Guidelines. *J Am Coll Cardiol*. 2014;63(22):2438-88.
9. Enriquez-Sarano M, Avierinos JF, Messika-Zeitoun D, *et al.* Quantitative determinants of the outcome of asymptomatic mitral regurgitation. *N Engl J Med*. 2005;352(9):875-83.
10. Rosenhek R, Rader F, Klaar U, *et al.* Outcome of watchful waiting in asymptomatic severe mitral regurgitation. *Circulation*. 2006;113(18):2238-44.

11. Vahanian A, Alfieri O, Andreotti F, *et al.* Guidelines on the management of valvular heart disease (version 2012): The Joint Task Force on the Management of Valvular Heart Disease of the European Society of Cardiology (ESC) and the European Association for Cardio-Thoracic Surgery (EACTS). *Eur J Cardiothorac Surg.* 2012;42(4): S1-44.
12. Beckmann A, Funkat AK, Lewandowski J, *et al.* Cardiac Surgery in Germany during 2014: A Report on Behalf of the German Society for Thoracic and Cardiovascular Surgery. *Thorac Cardiovasc Surg.* 2015;63(4):258-69.
13. Cohn LH, Adams DH, Couper GS, *et al.* Minimally invasive cardiac valve surgery improves patient satisfaction while reducing costs of cardiac valve replacement and repair. *Ann Surg.* 1997;226(4):421-6; discussion 7-8.
14. Walther T, Falk V, Metz S, *et al.* Pain and quality of life after minimally invasive versus conventional cardiac surgery. *Ann Thorac Surg.* 1999;67(6):1643-7.
15. Carpentier A, Loulmet D, Carpentier A, *et al.* First open heart operation (mitral valvuloplasty) under videosurgery through a minithoracotomy. *C R Acad Sci III.* 1996;319(3):219-23.
16. Chitwood WR, Jr., Elbeery JR, Chapman WH, *et al.* Video-assisted minimally invasive mitral valve surgery: the "micro-mitral" operation. *J Thorac Cardiovasc Surg.* 1997;113(2):413-4.
17. Chitwood WR, Jr., Elbeery JR, Moran JF. Minimally invasive mitral valve repair using transthoracic aortic occlusion. *Ann Thorac Surg.* 1997;63(5):1477-9.
18. Mohr FW, Falk V, Diegeler A, *et al.* Minimally invasive port-access mitral valve surgery. *J Thorac Cardiovasc Surg.* 1998;115(3):567-74; discussion 74-6.
19. Cosgrove DM, 3rd, Sabik JF, Navia JL. Minimally invasive valve operations. *Ann Thorac Surg.* 1998;65(6):1535-8; discussion 8-9.
20. Carpentier A, Loulmet D, Aupeple B, *et al.* Computer assisted open heart surgery. First case operated on with success. *C R Acad Sci III.* 1998;321(5):437-42.
21. Autschbach R, Onnasch JF, Falk V, *et al.* The Leipzig experience with robotic valve surgery. *J Card Surg.* 2000;15(1):82-7.
22. Cohn LH, Byrne JG. Minimally invasive mitral valve surgery: current status. *Tex Heart Inst J.* 2013;40(5):575-6.
23. Cheng DC, Martin J, Lal A, *et al.* Minimally invasive versus conventional open mitral valve surgery: a meta-analysis and systematic review. *Innovations (Phila).* 2011;6(2):84-103.
24. David TE, Armstrong S, McCrindle BW, *et al.* Late outcomes of mitral valve repair for mitral regurgitation due to degenerative disease. *Circulation.* 2013;127(14):1485-92.
25. Davierwala PM, Seeburger J, Pfannmueller B, *et al.* Minimally invasive mitral valve surgery: "The Leipzig experience". *Ann Cardiothorac Surg.* 2013;2(6):744-50.
26. Di Bardino DJ, El Bardissi AW, McClure RS, *et al.* Four decades of experience with mitral valve repair: analysis of differential indications, technical evolution, and long-term outcome. *J Thorac Cardiovasc Surg.* 2010;139(1):76-83; discussion 4.
27. Modi P, Hassan A, Chitwood WR, Jr. Minimally invasive mitral valve surgery: a systematic review and meta-analysis. *Eur J Cardiothorac Surg.* 2008;34(5):943-52.
28. Petracek MR, Leacche M, Solenkova N, *et al.* Minimally invasive mitral valve surgery expands the surgical options for high-risks patients. *Ann Surg.* 2011;254(4):606-11.
29. Reser D, van Hemelrijck M, Pavicevic J, *et al.* Repair rate and durability of video assisted minimally invasive mitral valve surgery. *J Card Surg.* 2014;29(6):766-71.
30. Seeburger J, Borger MA, Falk V, *et al.* Minimal invasive mitral valve repair for mitral regurgitation: results of 1339 consecutive patients. *Eur J Cardiothorac Surg.* 2008;34(4):760-5.

31. Vanermen H, Farhat F, Wellens F, *et al.* Minimally invasive video-assisted mitral valve surgery: from Port-Access towards a totally endoscopic procedure. *J Card Surg.* 2000;15(1):51-60.
32. Aklog L, Adams DH, Couper GS, *et al.* Techniques and results of direct-access minimally invasive mitral valve surgery: a paradigm for the future. *J Thorac Cardiovasc Surg.* 1998;116(5):705-15.
33. Gillinov AM, Cosgrove DM. Minimally invasive mitral valve surgery: mini-sternotomy with extended trans-septal approach. *Semin Thorac Cardiovasc Surg.* 1999;11(3):206-11.
34. Chitwood WR, Jr. Current status of endoscopic and robotic mitral valve surgery. *Ann Thorac Surg.* 2005;79(6): S2248-53.
35. Nifong LW, Chitwood WR, Pappas PS, *et al.* Robotic mitral valve surgery: A United States multicenter trial. *J Thorac Cardiovasc Surg.* 2005;129(6):1395-404.
36. Bush B, Nifong LW, Alwair H, *et al.* Robotic mitral valve surgery-current status and future directions. *Ann Cardiothorac Surg.* 2013;2(6):814-7.
37. Carpentier A. Cardiac valve surgery--the "French correction". *J Thorac Cardiovasc Surg.* 1983;86(3):323-37.
38. Gillinov AM, Tantiwongkosri K, Blackstone EH, *et al.* Is prosthetic annuloplasty necessary for durable mitral valve repair? *Ann Thorac Surg.* 2009;88(1):76-82.
39. Bothe W, Miller DC, Doenst T. Sizing for mitral annuloplasty: where does science stop and voodoo begin? *Ann Thorac Surg.* 2013;95(4):1475-83.
40. Seeburger J, Noack T, Winkfein M, *et al.* Loop technique. *Multimed Man Cardiothorac Surg.* 2010;2010(809): mmcts 2010 004523.
41. von Oppell UO, Mohr FW. Chordal replacement for both minimally invasive and conventional mitral valve surgery using premeasured Gore-Tex loops. *Ann Thorac Surg.* 2000;70(6):2166-8.
42. Falk V, Seeburger J, Czesla M, *et al.* How does the use of polytetrafluoroethylene neochordae for posterior mitral valve prolapse (loop technique) compare with leaflet resection? A prospective randomized trial. *J Thorac Cardiovasc Surg.* 2008;136(5):1205; discussion -6.
43. Seeburger J, Falk V, Borger MA, *et al.* Chordae replacement versus resection for repair of isolated posterior mitral leaflet prolapse: a *égalité*. *Ann Thorac Surg.* 2009;87(6):1715-20.
44. Gillinov AM, Banbury MK. Pre-measured artificial chordae for mitral valve repair. *Ann Thorac Surg.* 2007;84(6):2127-9.
45. Svensson LG, Atik FA, Cosgrove DM, *et al.* Minimally invasive versus conventional mitral valve surgery: a propensity-matched comparison. *J Thorac Cardiovasc Surg.* 2010;139(4):926-32 e1-2.
46. Ad N, Holmes SD, Shuman DJ, *et al.* Minimally invasive mitral valve surgery without aortic cross-clamping and with femoral cannulation is not associated with increased risk of stroke compared with traditional mitral valve surgery: a propensity score-matched analysis. *Eur J Cardiothorac Surg.* 2015; 48: 868-872.
47. McClure RS, Athanasopoulos IV, McGurk S, *et al.* One thousand minimally invasive mitral valve operations: early outcomes, late outcomes, and echocardiographic follow-up. *J Thorac Cardiovasc Surg.* 2013;145(5):1199-206.
48. Seeburger J, Borger MA, Doll N, *et al.* Comparison of outcomes of minimally invasive mitral valve surgery for posterior, anterior and bileaflet prolapse. *Eur J Cardiothorac Surg.* 2009;36(3):532-8.
49. Castillo JG, Anyanwu AC, El-Eshmawi A, *et al.* All anterior and bileaflet mitral valve prolapses are repairable in the modern era of reconstructive surgery. *Eur J Cardiothorac Surg.* 2014;45(1):139-45; discussion 45.
50. D'Alfonso A, Capestro F, Zingaro C, *et al.* Ten years' follow-up of single-surgeon minimally invasive reparative surgery for degenerative mitral valve disease. *Innovations (Phila).* 2012;7(4):270-3.

51. Richardson L, Richardson M, Hunter S. Is a port-access mitral valve repair superior to the sternotomy approach in accelerating postoperative recovery? *Interact Cardiovasc Thorac Surg*. 2008;7(4):678-83.
52. Holzhey DM, Seeburger J, Misfeld M, *et al*. Learning minimally invasive mitral valve surgery: a cumulative sum sequential probability analysis of 3895 operations from a single high-volume center. *Circulation*. 2013;128(5):483-91.
53. Castillo JG, Anyanwu AC, Fuster V, *et al*. A near 100% repair rate for mitral valve prolapse is achievable in a reference center: implications for future guidelines. *J Thorac Cardiovasc Surg*. 2012;144(2):30812.

Against Minimal Access Surgery

“One has sown the word ‘tomorrow’; it has not grown”

Arabian Proverb

“There is no such thing as Art, there are only Artists”. Thus begins an opening chapter in one of the best loved books on the history of art by the internationally acclaimed art historian E. H. Gombrich. The point that he is making and that I wish to enlarge upon is that although we think of Art as a definable cultural entity, it is in fact a grouping of an infinite number of creative activities that may or not appeal to the observer; that Art is created by the artist and it is the individual producing the work that is what really matters.

So it is with surgery. It can be argued that there is no such thing as surgery but that there are only surgeons. By this I mean that whatever the branch of surgery we wish to consider, the quality of the outcome is inevitably defined by the surgeon performing the task. The definable qualities of any surgeon will include knowledge, experience, decision-making and reflective thought as well as the all-important technical ability and manual dexterity. All of these qualities are necessary in the development and the undertaking of any modification in surgical technique over well-established procedures. This none more so if the modification is simply for claimed improved cosmetics. This is the case in the development of minimal access mitral valve surgery.

I wish to state at the outset of this brief discussion that as the author of these words I have no personal prejudice against the implementation of these procedures but wish to point out potential pitfalls for both the surgeon and the patient in the rush to embrace this development.

Perhaps we should begin by clarifying the title of this piece as given to me by the commissioning editors. This procedure is per se not a treatment. It is simply an approach to the mitral valve through alternative incisions, which necessitate a change in access to the circulation as well as the valve. It can be stated quite unequivocally that the gold standard approach for safe reconstructive surgery on the Mitral valve is via a median sternotomy incision. It allows for surgery with almost no mortality (contemporary audited data from all centers carrying out significant amounts of these procedures) and with almost all valves being repairable (in excess of 95% in most centers). Complication rates and length of stay on a like for like patient basis are at least as good as those quoted for minimal access patients. The incision gives complete control of the circulation, the most easily controllable protection of the heart and the best access for removing air from the heart at the end of the procedure.

Most importantly this level of control allows surgeons of varying ability to complete the procedure safely with minimal harm to each of the patients being treated.

If we ask ourselves what this operation of Mitral valve surgery is really all about it surely is the following. It is about maintaining standards; it is about safely repairing/replacing the Mitral valve



with minimum morbidity and mortality. It is also about longevity of the surgical procedure and the patient. It should be done neatly and expeditiously leaving the patient with the minimum of scarring. All of this can be achieved through a mid-line approach. In all of this the experience of the surgeon in procedures on the mitral valve is paramount.

Secondary considerations are the length of the scar, the duration of the surgical procedure, the length of stay in hospital, cost and efficiency of throughput. Whilst these issues have their own importance each can be addressed with standard access surgery if the same rigour is applied to those patients being treated in the conventional way as in the minimal access method. What tends to happen most often is that procedures become lax with familiarity resulting in a lowering of standards in the conventional approach as the opening and closing of the chest is frequently devolved to the most junior member of the surgical team in the absence of proper supervision. This should not be allowed to happen.

What these procedures must not be about is the fame and fortune of the surgeon or the unit providing the facility. Nor should it be about advertising, marketing or least of all surgical bravado. There is evidence of all of these aspects creeping into this area of surgery. Quoting the Royal College of Surgeons publication 'Good surgical practice', "Surgeons must demonstrate probity in all aspects of their professional practice and ensure that they do not abuse their patient's trust in them or the public's trust in the profession". There are examples of where this trust has been abused in the development of these procedures and whilst small in number they serve to undermine public trust in surgery in general and not least in the practice of cardiac surgery. Claims are made for the outcome of minimal access mitral valve surgery (MAMVS) that are not substantiated in robust trial data. Every patient wants the minimal of surgical trauma with the best possible outcome. Exaggerating claims in this direction is clinical deception and as such is unacceptable.

It ought not to need saying but in the context of the adoption of these practices in the hands of some it does bear repeating the following. We must not make unreasonable claims, we must ensure that our names or practice are not used inappropriately in the promotion of personal commercial advantage and we should ensure that patients know that a technique is new before seeking consent, particularly at the beginning of a programme.

There are the three great ages of cardiac surgery, which are the breaking of new ground, defining procedures and establishing standards and the maintenance of standards and safety. Minimal access surgery has developed to the point where it can be achieved safely in the correct hands and MAY have something tangible to offer, but what has not happened is the conduct of well-constructed and appropriately sized randomised prospective studies to clearly demonstrate its role and outcomes compared with conventional techniques.

Here I rush to add that this has not even been properly achieved in open mitral valve surgery and there are significant numbers of surgeons carrying out mitral valve surgery with very small experience and inadequate outcome analysis. The worst possible scenario is such an inexperienced surgeon then embarking upon a minimal access programme!

The midline sternotomy performed properly is not a painful incision when compared with a thoracotomy or laparotomy. It allows for excellent control and the exposure to allow any other procedures that may be necessary. The increased recognition of the importance of untreated tricuspid regurgitation is causing a significant increase in the addition of tricuspid valve repair in patients with left sided problems. Relatively few surgeons feel competent or safe to add tricuspid valve surgery to mitral valve procedures when carried out through

a minimal access route. It can be strongly argued that this will lead to compromise of outcome in the mid to long-term for these patients. This is not the case with open access surgery.

If the opening and closing of the sternotomy is managed with the same care as the mitral reconstruction, as it should be, then the cosmetic and comfort results are excellent. I do not sit in my outpatient's clinic and hear a litany of complaints from patients about their sternotomy scar. Indeed, the opposite is true. When

asked, as I regularly do, very few comment negatively on the impact of the wound to their recovery. Most say that it just has not been a problem and several say that they have been pain free. In addition, this level of care over the incision and exposure, ensuring that the wound is dry enough to close before commencing cardio-pulmonary bypass renders surgery with very low, indeed almost no post-operative blood loss, a central claim for minimal access procedures.

What then of the published data comparing the two routes of access. As stated above so far there are no randomised prospective studies; all rely on retrospective review, some are propensity matched. Despite this there are significant differences in the reference groups.

The most common variables that are compared are cosmetics, cost, hospital length of stay, morbidity, pain, blood loss and post-operative respiratory function. All of the claimed superiority of MAMVS in these variables can be challenged on the quality of the data currently available.

Taking the Cleveland clinic study [1] quoting 2,124 MAMVS patients versus 1,047 open cases in almost every variable category the open patients were less well with a difference of up to $p=0.0001$! They had a worse NYHA score, greater number of ischaemic and rheumatic patients and worse left ventricular function and more tricuspid regurgitation. There were more hypertensive and diabetic patients, and more with chronic obstructive airways disease. There were less mitral valve repairs and more tricuspid valve operations in the open group again suggesting a different category of patient. Despite this there were more strokes, more myocardial infarctions and interestingly more deep wound infections in the MAMVS group! There were less blood transfusions but more anaemia on discharge in that group. There was reduced lung function up to day three in the MAMVS group but this equalised after day 3. By day 3 post-operatively the pain scores had equalised and by day 7 those with a sternotomy were complaining of less pain.

In a paper from the Leipzig group there was an average of 11.9 days in hospital compared with a personal series of open mitral repair with an average length of stay of 6.8 days [2]. They reported a stroke rate of over 2%, re-operation for bleeding rate of around 5% and a 30-day mortality of around 2%, all significantly higher than for currently acceptable open sternotomy surgical practices.

A particularly worrying complication with the endoballoon method of aortic occlusion is that of aortic dissection, an almost never occurring complication in open cannulation. This devastating complication has caused a number of deaths around the world with the MAMVS procedure using this style of aortic occlusion. This has caused a move towards more traditional methods of clamping nonetheless these injuries are still occurring.

Having dealt with some of the potential harmful effects of this style of access on the patient I would like to turn to the potential harmful effects on the aspiring surgeon. Inadequately



prepared and experienced surgeons can find themselves in dire difficulties with this technique very quickly. Indeed, this continues to be the case with otherwise safe adequate surgeons causing the harm or even death to their patient, which results in the restriction or curtailment of their own career. A devastating occurrence for any professional but one that is particularly difficult to recover from in a surgeon.

In comparing the costs of the two approaches, the absence of true randomised data renders this an impossible task. The closer one inspects the extant data the more the shortcomings of the minimal access approach become clear. Claimed cost savings over open procedures rely principally on length of stay and reduced blood loss, neither of which have been properly tested and indeed examination of my own data reveals these claims to be seriously lacking in cogency. The proper way forward should be a well-constructed prospective trial. Randomisation could be between expert surgeons in expert units with high volume MAMVS entering patients with the same characteristics as another group operated upon by expert open surgeons. Only with this kind of data can a true conclusion be drawn.

It is my contention therefore that the median sternotomy approach remains the gold standard approach for mitral valve surgery, not minimal access. That whilst the more minimalist incision may well have something to offer patients the evidence is not yet in the public domain and whilst that is so surgeons should council patients in the acquiring of informed consent of their shortcomings in true in-depth knowledge of the comparative outcomes of these two routes of access (for that is all they are) in the performance of mitral valve surgery.

References

1. Svensson LG, Atik FA, Cosgrove DM, *et al.* Minimally invasive versus conventional mitral valve surgery: a propensity-matched comparison. *J Thorac Cardiovasc Surg* 2010 Apr;139(4):926-32.
2. Seeburger J, Borger MA, Doll N, *et al.* Comparison of outcomes of minimally invasive mitral valve surgery for posterior, anterior and bileaflet prolapse. *Eur J Cardiothorac Surg*. 2009 Sep;36(3):532-8.

Chapter 4

Pearls and Pitfalls of Minimally Invasive Mitral Valve Surgery and the Loop Technique

Martin Misfeld, Piroze Davierwala and Friedrich W Mobr

“Though a good deal is too strange to be believed, nothing is too strange to have happened”

Godfrey Harold Hardy (1877 - 1947)

Introduction

“Minimally invasive surgery is an efficient way to transfer the pain of the operation from the patient to the surgeon”

(Anonymous)

This statement may still be true for some, however minimally invasive mitral valve surgery (MIMVS) has become increasingly popular within the last few years although it has still not been adopted by the majority of cardiac surgeons. Data from the Annual Report of the German Society of Cardiac, Thoracic and Vascular Surgery demonstrates, that in 2014, the overall number of isolated mitral valve operations still increased with the majority of valves being repaired (n=3887) rather than replaced (n=2026) [1]. This is related to the fact that the underlying pathology in Western countries is mainly degenerative mitral valve disease. The minimally invasive approach was used in only 47.2% of procedures and although approximately 80% (n=63) of German centers perform MIMVS, the percentage of isolated mitral valve procedures performed using these techniques varied from 3% to 98%. The Annual Report further shows that for isolated mitral valve repair, MIMVS had a mortality rate of 0.9% compared to 2.7% for conventional sternotomy. This is most likely due to patient selection but surgical expertise at centers performing MIMVS may also contribute to better outcomes with a minimally invasive approach.

Ever since the first description of MIMVS by Alain Carpentier in 1996 [2] and its implementation into everyday practice by the Leipzig group [3], MIMVS has become routine practice in many specialized centers worldwide [4]. Totally endoscopic surgery is used as a routine approach by us and others [5-9] and this is even less invasive for the patient, but requires different surgical skills.

Over the years, MIMVS has been shown to have several advantages compared to conventional sternotomy such as decreased surgical trauma, less postoperative pain, improved cosmesis, reduced blood loss and, most importantly, quicker recovery. Besides these benefits, MIMVS does not increase patient risk when compared to the conventional sternotomy approach [10-19]. The goals of MIMVS are to achieve high repair rates with a safety profile similar to the conventional approach, with the additional advantage of minimal access and optimal visualization of the valve, which is the most important prerequisite to perform a perfect mitral valve repair.

It has been demonstrated that MIMVS requires specific surgical skills for the use of new instruments and technology. Expertise in echocardiography, skills in the use of wire techniques for peripheral vascular cannulation as well as specific perfusion strategies mandate a well harmonized team approach. To overcome the relatively steep learning curve which exists, surgeons who aim to start a MIMVS programme need to be aware of the potential pitfalls of this innovative operative technique [20-22]. This not only enables young surgeons to execute MIMVS safely, but also gives them insight and the confidence to perform additional combined procedures such as tricuspid valve surgery, ablation therapy, atrial septal defect/patent foramen ovale closure, as well as myectomy for hypertrophic obstructive cardiomyopathy. MIMVS may also be a



beneficial approach in patients who require a reoperation following a previous sternotomy [23-30]. The current chapter focuses on our experience with the potential pitfalls of MIMVS.

Table 1: Indications, relative and absolute contraindications for MIMVS at the Leipzig Heart Center

Indications	Contraindications	
	Relative	Absolute
isolated MV repair	redo-procedures	previous right thoracotomy with severe adhesions
isolated MV replacement	obese female patients with large breasts	heavily calcified MV annulus
MV surgery with concomitant procedures: TV surgery surgery for AF PFO / ASD repair myectomy for HOCM	MV endocarditis chest wall abnormalities unsuitable femoral arteries	severe abscess formation of the MV annulus
MV surgery post-sternotomy	Pathologies of the descending aorta	AV regurgitation > 1+

*AF = atrial fibrillation, MV = mitral valve, TV = tricuspid valve,
PFO = patent foramen ovale, ASD = atrial septal defect,
HOCM = hypertrophic obstructive cardiomyopathy, AV = aortic valve.*

Patient selection

In order to reduce complications and increase safety of any procedure, it is extremely important for a surgeon to be aware of the absolute and relative contraindications of a particular procedure. Presence of severe mitral annular calcification or a significant periannular abscess secondary to mitral valve endocarditis are absolute contraindications to perform MIMVS. We still prefer to operate on such patients through a sternotomy as extensive reconstructive procedures may be required. Additionally, we avoid minimal access surgery in patients with more than mild aortic regurgitation due to the risk of inadequate myocardial protection, as well as in those who have undergone a prior right thoracotomy due to the presence of dense adhesions obliterating the pleural cavity.

As the decision to perform MIMVS remains an individual, patient-based decision, relative contraindications do exist. These are reoperative procedures, obese females with large breasts and chest wall abnormalities with the heart being shifted to the left side (e.g. pectus excavatum), mitral valve endocarditis, diseases of the descending aorta such as severe calcification or thrombus impregnated aneurysms with the associated risk of thromboembolism, dilated ascending aorta (>40 mm) due to the higher possibility of producing an iatrogenic dissection, and diseased femoral arteries unsuitable for cannulation. Table 1 summarizes indications as

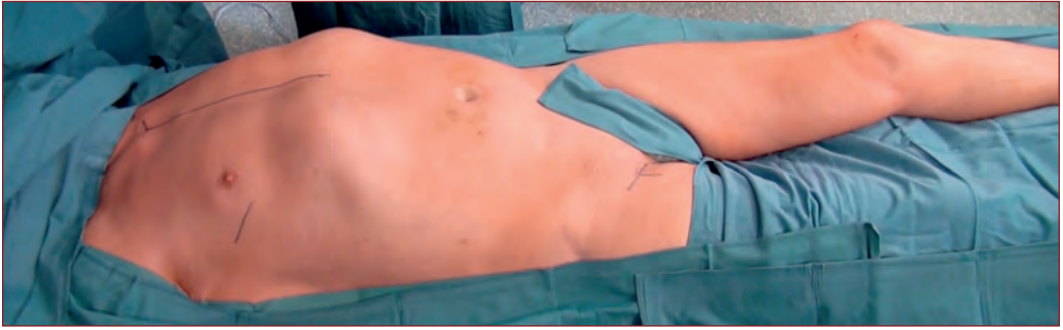

Fig1: Patient positioning

well as the relative and absolute contraindications for MIMVS at the Leipzig Heart Center.

Preoperative diagnostics

There are no specific additional diagnostic investigations required. Each patient undergoes routine coronary angiography to exclude additional coronary artery disease (we accept an ECG-gated cardiac computed tomography (CT) scan in younger patients without cardiovascular risk factors). If angiography is performed immediately before surgery, left-sided femoral or radial artery access should be used to perform this investigation. Angiography further delineates the size and position of the circumflex artery, which is important to avoid potential injury during annuloplasty suture placement. Other routine preoperative investigations such as a chest X-ray, transthoracic echocardiography, carotid doppler, pulmonary function and blood tests are also performed. The role of clinical examination should not be undermined as it provides important clues regarding the cannulation and chest access sites.

In severely obese patients or those with chest wall abnormalities, a preoperative CT scan of the thorax helps to assess not only the distance between the mitral valve and right chest wall, but also the position of mitral valve in relation to the cardiac and other thoracic structures. If long enough instruments are not available, the surgeon can perform the operation through a sternotomy. Additionally, the skin incision is made slightly longer than usual in such patients, whose procedures are performed only by experienced minimally invasive surgeons in our institution.

Potential pitfalls: Mitral annular calcification or abscess formation, chest wall abnormalities, right-sided diaphragmatic elevation, obese patients, large breasts in women.

Patient positioning

Patients are positioned supine with a 30° elevation with a small bolster placed under the right scapula. The right arm is positioned at a level lower than the right side of the chest so as to have enough space for introducing the transthoracic aortic clamp (Figure 1). Following prepping and draping, the sternal midline is marked with a pen which ensures a midline incision in the event of a conversion, especially in women, as the incise drape often distorts the actual midline on the skin as it is used to pull the breast cranially and towards the left. In obese women with large breasts, it can sometimes be easier to push the breast caudally and make an incision above the mammary gland. Although this access is cosmetically less attractive for women, potential risks of wound healing problems with incisions in the submammary fold can be avoided in such patients.

Potential pitfalls: Improper patient positioning with inadequate elevation of the right chest and not enough space on the lateral aspect of the right chest. Unmarked skin incisions or the sternal midline before application of an incise drape. Inadequate cranial and leftward traction on the right breast in women.

Peripheral cannulation

The right femoral artery and femoral vein are the standard cannulation site for establishing cardiopulmonary bypass (CPB) in MIMVS. Either percutaneous cannulation or direct cannulation utilizing a Seldinger technique can be used. In the open surgical technique, following an oblique skin incision, the femoral vessels are exposed only superficially. Care has to be taken to push the lymph nodes medially to avoid the risk of injury to lymphatic channels that result in the development of a postoperative seroma. We prefer the open technique, as the risk of vascular complications is rare and overrides the potential risk and morbidity of a groin seroma. If the femoral artery is unsuitable, axillary cannulation or direct cannulation of the ascending aorta through a slightly larger thoracotomy may be required.

At this stage, heparin is administered and, following insertion of 4/0 polypropylene purse-string sutures on the femoral vein and artery, cannulation is performed using a Seldinger technique and TOE guidance. We usually cannulate the femoral vein first as the vein often lies posterior to the femoral artery. At this stage, echocardiographic guidance is of utmost importance as it confirms the correct intraluminal position of the guide wires in the superior vena cava and the descending thoracic aorta (Figure 2).

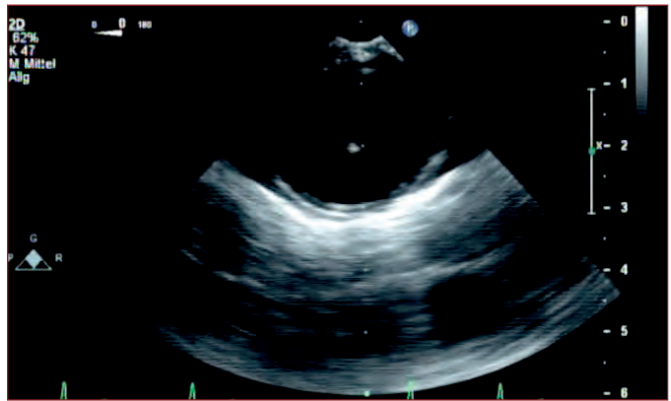


Fig 2: Guidewire for arterial cannulation in the descending aorta as seen on transoesophageal echo

Following venous cannula insertion, its correct position in the superior vena cava (SVC) should be confirmed by echocardiography (Figure 3). If the tip of the venous cannula is not positioned in the SVC, inadequate venous drainage and SVC inflow obstruction can occur when the left atrium is retracted. One may encounter some resistance during insertion of the guidewire or cannula in patients who are dehydrated. A reverse Trendelenburg position may help dilate the inferior vena

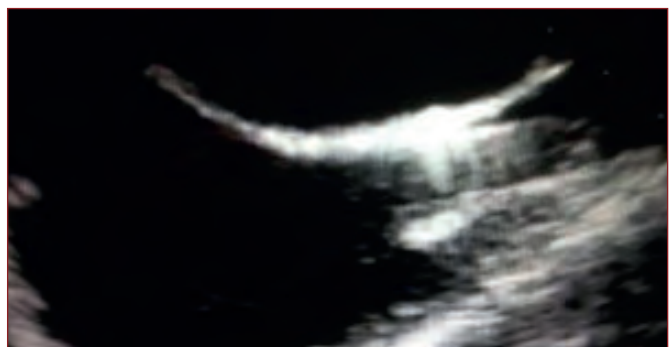


Fig 3: Venous cannula in superior vena cava as seen on bicaudal view of transoesophageal echo

cava in such situations, thus enabling easier passage of the wire or cannula. Under no circumstances should undue force be used to insert the cannula. Different venous cannula designs and snaring the SVC and IVC are used in some centers on a routine basis.

In patients weighing more than 75 kg and in those requiring additional right-sided procedures, it is preferable to use a second venous cannula inserted by the anaesthetist following induction of anesthesia through the right internal jugular vein under echocardiographic guidance. The potential risk of perforation of the superior vena cava can be minimized by echo-controlled insertion of the guidewire and cannula. A bubble test is used to confirm proper wire positioning. Adequate venous drainage on cardiopulmonary bypass (CPB) is always maintained through vacuum assistance. In rare cases, where venous drainage appears to be inadequate during surgery or in cases where the operation has to be unexpectedly extended to the right atrium, a right-angled venous cannula can be inserted into the SVC through an additional skin incision or through the thoracotomy itself.

We have not experienced malperfusion of the lower limb during MIMVS. It is important to note that the position of the arterial cannula should be secured by an additional suture to the skin. The setup of groin cannulation is depicted in Figure 4.

Potential pitfalls: Incorrect position of guidewires in the SVC and descending aorta with malposition of cannulas and, therefore, risk of damage to cardiac structures such as the right atrial appendage, right ventricular wall, atrial septum or even left atrial appendage; development of a retroperitoneal hematoma or aortic dissection. Inadequate insertion of the tip of the venous cannula into the superior vena cava. Malperfusion of the leg during arterial cannulation requiring an additional distal perfusion cannula through the side arm of the arterial cannula.

Surgical access and exposure of the mitral valve

Following institution of femoro-femoral CPB, a right mini-thoracotomy is performed and the lungs are disconnected from the ventilator to expose the pericardium. It now becomes clear that there is no need to use a double lumen endotracheal tube. However, during the learning curve, it may be advisable to use a double lumen tube so that the thoracotomy can be performed prior to establishment of CPB, thus reducing pump time.

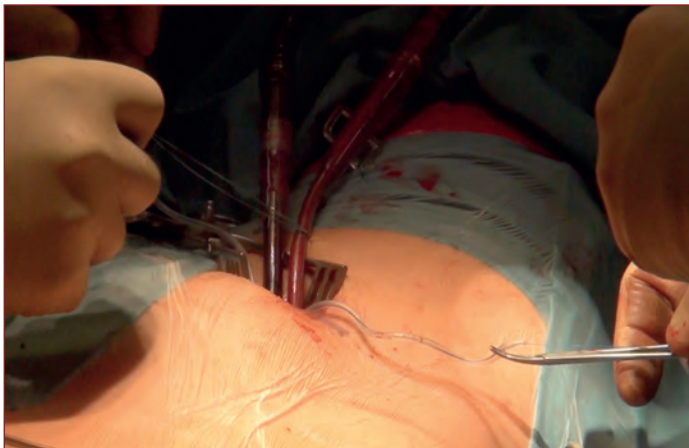

Fig 4: Groin cannulation

It cannot be emphasized enough that adequate exposure and visualization of the mitral valve is of utmost importance to perform mitral valve surgery. The chest is entered in the majority of cases through the fourth intercostal space. The approximate level of the diaphragm can be assessed from the preoperative chest X-ray. The midpoint between the costal margin and the clavicle is a good landmark for the thoracotomy. In

women, the correct point of entry into the thorax is usually one intercostal space higher than one expects it to be. As the cosmetic result is of importance in women, the skin incision should be made directly in the inframammary fold, which should be marked before the incise drape is applied. Initially, only a small opening is made in the intercostal space and the left index finger is used to palpate the

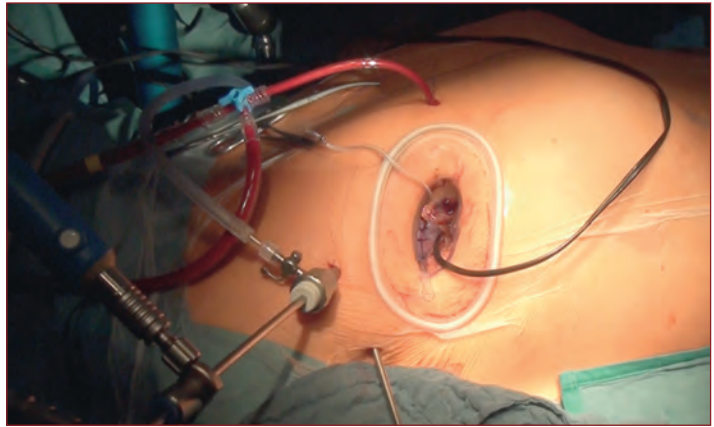


Figure 5: Example of operative setup for MIMVS

diaphragm through it. If the diaphragm is palpable immediately caudal to this opening, it indicates that a higher intercostal space should be used as the entry site into the thorax. The incision should ideally correspond to the midline of the left atrium. At this stage, a soft tissue retractor is inserted and may itself provide adequate visualisation and access to the left atrium. However, if the bulge of the diaphragm still obstructs the vision, a malleable retractor may be placed between the rib spreader and the upper margin of the lower rib. This obviously requires the use of a rib spreader. Alternatively, an additional suture may be placed through the central tendon of the diaphragm and brought out caudally through the incision to pull the diaphragm inferiorly. However, there is a potential risk of liver injury and therefore this retraction suture needs to be superficial and wide. This suture should be tied as small vessels on the diaphragm are a potential source of bleeding, especially when the suture is removed without tying.

As the patient is already on CPB, it is easy to enter the pericardium with an empty heart. Although there are different ways to perform the pericardial incision, it is advisable to incise the pericardium more anteriorly well away from the phrenic nerve and curve it posteriorly toward the inferior vena cava at the level of the diaphragm so as to reduce or eliminate the possibility of phrenic nerve injury (U-shape incision). Resection of the pericardial fatty tissue may be required to improve visualization but this can be a source of bleeding. Pericardial retraction sutures may or may not be used and can be brought out through the skin at the right lower lateral side of the chest.

The oblique sinus can be opened using the tip of the Yankeur suction catheter. A pledgetted or non-pledgetted 3/0 or 4/0 polypropylene purse-string suture is used for the introduction of the cardioplegia root needle into the proximal ascending aorta and is connected to the cardioplegia line. This can be brought out of the chest either through the thoracotomy under the soft tissue retractor or through the same incision as the LA retractor.

We routinely use the Chitwood transthoracic clamp but other aortic clamp types may be used. We believe that the Chitwood clamp saves time, is safe and easy to apply and does not need constant monitoring of its position in comparison to endoaortic balloon occlusion (EBO). Additionally, being reusable, it is also cost-effective. However, EBO is useful in reoperative cases as no dissection around the ascending aorta is necessary. Optimal placement of the endoballoon requires practice and if it going to be used, it should be used routinely and not only in challenging redo cases.




Fig 6: "Leipzig Loop Technique" - premanufactured GoreTex neochords.

The transthoracic clamp is inserted through a 5mm axillary incision in the same or one intercostal space higher than the thoracotomy. It is important to avoid inadvertently jarring the clamp and the aorta after it has been applied. While applying the clamp, bypass flows are reduced and ventricular fibrillation can be electrically induced. The clamp can be positioned with its curvature towards or away from the left atrial appendage (LAA). As the LAA can be potentially injured during clamping, the cardiotomy suction catheter is

introduced through the transverse sinus to push the LAA away from the clamp. The wall-suction cannula should not be used for this manoeuvre as it can cause a suction injury to the tip of the LAA.

Some surgeons dissect Waterson's groove and then the LA is opened whilst the cardioplegia is being administered. An additional traction suture is inserted into the tissue of Waterson's groove and brought out anteriorly through a 5mm parasternal incision, through which the LA retractor is also introduced after cardioplegia delivery. Care must be taken when making this incision to avoid injury to the right internal mammary vessels. This suture helps to lift up the anterior edge of the left atrial incision, which is especially helpful later on when the LA is being closed. A vent is positioned into the left superior pulmonary vein. This vent can also be brought out under or through the soft tissue retractor so as to avoid obstruction of the surgical view.

After cardioplegic arrest, we briefly suck on the aortic root vent to make sure that the clamp is occlusive. The LA retractor with an appropriately sized blade is now introduced. The trocar for the thoracoscope with a CO₂ side port is introduced one intercostal space above the chest incision. It is important that the thoracoscope does not conflict with the aortic clamp. We use either a 5mm 0° 2D or 10mm 0° 3D version. An example of the operative setup is given in Figure 5.

Potential pitfalls: Inadequate access to the chest. Bleeding from the diaphragmatic retraction sutures. Bleeding from pericardial fatty tissue. Phrenic nerve injury following pericardial incision / excessive retraction. Inappropriate position of thoracoscope and/or clamp; conflict with each other, left atrial appendage injury during application of the clamp, incomplete occlusion of the ascending aorta with the cross-clamp, inadvertent opening of the right atrium during left atrial incision, injury to the right internal mammary vessels during introduction of the left atrial retractor arm, inadequate venous drainage.

Reconstructive techniques (the Leipzig loop technique)

Basically, almost all surgical techniques can be applied during MIMVS if the surgeon is familiar with the technique itself and the use of shafted surgical instruments. As the most common pathology at our centre is degenerative mitral valve disease, we follow the “respect rather than resect” principle advocated by Perrier and colleagues [31]. To achieve this, we predominantly use Gore-Tex neochords which have been used for chordal replacement since the late 1980s by Dr Tirone David and others [32-35]. Numerous techniques to achieve an appropriate neochordal length have been proposed. In 2000, von Oppel and Mohr introduced the use of premeasured Gore-Tex loops and this has now come to be known as the “Leipzig loop technique” [36]. This technique has several advantages as it is precise and reproducible and avoids the need to tie air knots with a knot pusher, which is especially challenging during MIMV repair.

Initially, these Gore-Tex loops were prepared on the table during surgery after the measurement was performed. However, these loops are now commercially available in different lengths for replacement of both anterior and posterior leaflet chords (Figure 6). Each set of neochords has four loops which are attached to a small Teflon pledget. These loops are attached to the corresponding papillary muscle and are reinforced with a second pledget. The loops are then attached to the free edge of the prolapsing segment of the mitral leaflet by another 4/0 or 5/0 Gore-Tex suture by passing it through the loop and then through the leaflet.

The number of loops which can be attached to the prolapsing segment can vary between one and four, as two or more loops can be grasped by one suture depending on the number of neochords that are required. The distance at which the neochords are attached to the leaflet should be approximately every 5mm. The appropriate length is calculated by means of a sliding calliper which measures the distance between the body of the papillary muscle where one intends to fix the base of the loops to the free margin of the leaflet taking into account the length of the prolapsing segment (Figure 7). The average length of loops used for the posterior leaflet is 12–14mm and that for the anterior leaflet is 22–24mm. It is of utmost importance that the loops originating from the corresponding papillary muscle do not cross the midline of the anterior or posterior leaflets.

With the loop technique, we have demonstrated similar results to resectional

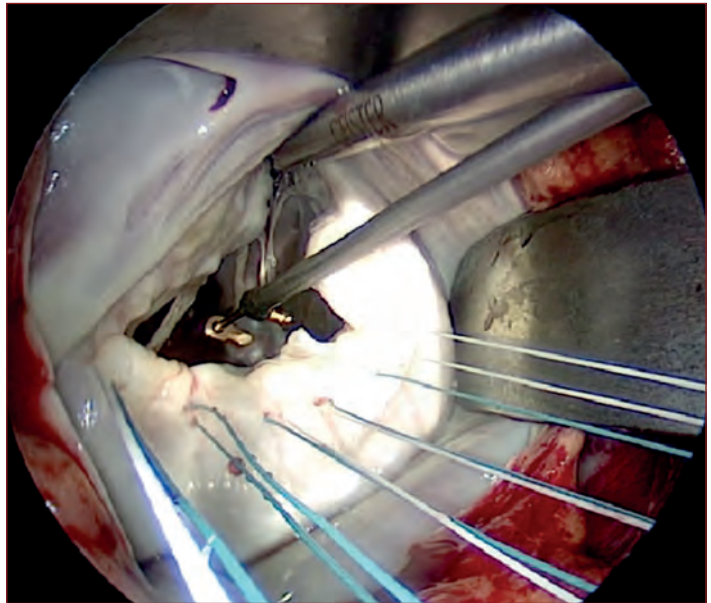


Fig 7: Measurement of neochord length for the Leipzig Loop Technique. From the body of the papillary muscle to the free margin of coaptation.

techniques [38, 39]. In a prospective randomized trial comparing these techniques, we demonstrated that the coaptation depth was significantly greater and a larger annuloplasty ring could be used with the loop technique (38). The overall repair rates and freedom from reoperation for anterior, posterior and bileaflet prolapse are similar in our experience with this technique.

We still perform resection in certain pathologies such as Barlow's disease characterised by excessive tissue in order to avoid systolic anterior motion (SAM). The surgeon's expertise in mitral valve repair is, therefore, still of major importance. However, the loop technique has made mitral valve repair much simpler and more reproducible in our experience.

Weaning from cardiopulmonary bypass and chest closure

Following mitral valve repair and left atrial closure, a pacing wire is placed before the clamp is released due to the ease of exposing the anterior or inferior right ventricular walls on an arrested heart. This wire is brought out through the same parasternal incision used for the left atrial retractor and is then tunnelled subcutaneously and secured to the skin. De-airing is performed by volume loading the heart and ventilating the lungs whilst venting the aortic root with the clamp in situ, as well as rotating the table. After emptying the heart and stopping ventilation, CPB is temporarily stopped and the clamp is released whilst suction is applied to the aortic root vent. Following a brief period of reperfusion, the patient is temporarily weaned from CPB to assess the mitral valve repair by TOE.


If the surgical result is satisfactory, CPB is reinitiated and the aortic root vent is removed and oversewn. The pericardium is partly or completely closed and the patient is then finally weaned from CPB. Following decannulation of the femoral vessels, all port sites are inspected from within the chest cavity with the thoracoscope to ensure haemostasis. Thereafter, one or two chest tubes are introduced into the right chest through the incisions for the thoracoscope and the clamp. Finally, the chest is closed in layers, making sure that all potential bleeding sites from the musculature and fatty tissue of the chest wall (especially in women) are cauterized to avoid a chest wall hematoma.

Infiltration of a local anaesthetic agent or the insertion of catheters for intercostal / paravertebral nerve blocks may be used to minimize postoperative pain. If no rib retractor is used, postoperative pain is usually not an issue.

Potential pitfalls: Injury to the ascending aorta during insertion of the cardioplegia root needle or application of the clamp, inappropriate length of neochords (loops), crossing of the leaflet midline with neochords, inadequate deairing manoeuvres, injury to the ascending aorta during release of the clamp. Bleeding at the site of insertion of the aortic root needle, bleeding from the chest wall musculature, improper positioning of the chest tubes with inadequate drainage, seroma of groin incision.

Intraoperative echocardiography

Intraoperative transoesophageal echo-cardiography (TOE) is very important in MIMVS. It is not only useful for assessing the mitral valve and therefore planning the repair, but also guides the surgeon during femoro-femoral cannulation confirming the correct position of the guidewires in the SVC and descending aorta, as well as appropriate positioning of the tip of the femoral venous cannula. Assessment of the mitral valve repair,



detection of new regional wall motion abnormalities, adequacy of deairing and evaluation of the flow in the circumflex artery are also important.

Postoperative treatment

Postoperative management of patients undergoing MIMVS is the same as for standard mitral valve surgery. At our centre, we follow the fast-track system and the majority of patients are sent to the post-operative anesthesia care unit (PACU) if the operative course is uncomplicated and if the patient does not have preoperative hemodynamic and/or cardiac parameters or comorbidities that warrant intensive care unit management. In PACU, they are extubated within a mean time postoperatively of 90 minutes [40]. They are then transferred to a step-down unit for the night of surgery and are usually moved to the ward on the first postoperative day where the advantages of faster recovery become evident.

General considerations

Centers which aim to start a MIMVS program should take specific steps to facilitate the learning curve which is evident with this procedure [20-22]. It is important to become familiar with the shafted instruments, which can be used during conventional mitral valve surgery, especially in obese patients. Visiting training courses and centers with expertise in this technique may accelerate the training process. During the first few procedures it is advisable to have a proctor in attendance, who guides the surgeon through the procedure and helps avoid potential pitfalls [41].

Conclusions

MIMVS has been shown to be as safe as conventional mitral valve surgery with the benefit of faster recovery, improved cosmesis and excellent outcomes if performed by an experienced team on a regular basis. However, the surgeon should be aware of the specific contraindications and potential pitfalls. Knowledge of these pitfalls and standardizing the surgical technique will enable centers to enlarge their spectrum of operative techniques for the benefit of patients.

References

1. Beckmann A, Funkat AK, Lewandowski J, *et al.* Cardiac Surgery in Germany during 2014: A Report on Behalf of the German Society for Thoracic and Cardiovascular Surgery. *Thorac Cardiovasc Surg.* 2015 Jun;63:258-69.
2. Carpentier A, Loulmet D, Carpentier A, *et al.* Chirurgie à cœur ouvert par vidéo-chirurgie et mini-thoracotomie. Premier cas (valvuloplastie mitrale) opéré avec succès. First open heart operation (mitral valvuloplasty) under videosurgery through a minithoracotomy. *C R Acad Sci Paris* 1996; 319:219-23.
3. Onnasch JF, Schneider F, Falk V, *et al.* Five years of less invasive mitral valve surgery: from experimental to routine approach. *Heart Surg Forum* 2002;5:132-5.
4. Seeburger J, Borger MA, Doll N, *et al.* Comparison of outcomes of minimally invasive mitral valve surgery for posterior, anterior and bileaflet prolapse. *Eur J Cardiothorac Surg* 2009;36:532-8.
5. Casselman FP, Van Slycke S, Wellens F, *et al.* Mitral valve surgery can now routinely be performed endoscopically. *Circulation* 2003;108 Suppl 1: II48-54.
6. Perier P, Hohenberger W, Lakew F, *et al.* Rate of repair in minimally invasive mitral valve surgery. *Ann Cardiothorac Surg* 2013;2:751-7.

7. Schroeyers P, Wellens F, De Geest R, *et al.* Minimally invasive video-assisted mitral valve repair: short and mid-term results. *J Heart Valve Dis* 2001;10:579-83.
8. Schroeyers P, Wellens F, De Geest R, *et al.* Minimally invasive video-assisted mitral valve surgery: our lessons after a 4-year experience. *Ann Thorac Surg* 2001;72: S1050-4.
9. Chitwood WR Jr, Wixon CL, Elbeery JR, *et al.* Video-assisted minimally invasive mitral valve surgery. *J Thorac Cardiovasc Surg* 1997;114:773-80.
10. Cao C, Gupta S, Chandrakumar D, *et al.* A meta-analysis of minimally invasive versus conventional mitral valve repair for patients with degenerative mitral disease. *Ann Cardiothorac Surg* 2013;2:693-703.
11. Modi P, Rodriguez E, Hargrove WC 3rd, *et al.* Minimally invasive video-assisted mitral valve surgery: a 12-year, 2-center experience in 1178 patients. *J Thorac Cardiovasc Surg* 2009;137:1481-7.
12. Vollroth M, Seeburger J, Garbade J, *et al.* Minimally invasive mitral valve surgery is a very safe procedure with very low rates of conversion to full sternotomy. *Eur J Cardiothorac Surg* 2012;42: e13-5.
13. Gasparovic H. Outcomes of minimally invasive valve surgery compared to conventional valve surgery in the elderly. *Ann Thorac Surg* 2011;92:1155.
14. Mohr FW, Falk V, Diegeler A, *et al.* Minimally invasive port-access mitral valve surgery. *J Thorac Cardiovasc Surg* 1998;115:567-74.
15. Seeburger J, Borger MA, Falk V, *et al.* Minimal invasive mitral valve repair for mitral regurgitation: results of 1339 consecutive patients. *Eur J Cardiothorac Surg* 2008;34:760-5.
16. Pfannmüller B, Seeburger J, Misfeld M, *et al.* Minimally invasive mitral valve repair for anterior leaflet prolapse. *J Thorac Cardiovasc Surg* 2013;146:109-13.
17. Raanani E, Spiegelstein D, Sternik L, *et al.* Quality of mitral valve repair: median sternotomy versus port-access approach. *J Thorac Cardiovasc Surg* 2010;140:86-90.
18. Suri RM, Schaff HV, Meyer SR, *et al.* Thoracoscopic versus open mitral valve repair: a propensity score analysis of early outcomes. *Ann Thorac Surg* 2009;88:1185-90.
19. Grossi EA, LaPietra A, Ribakove GH, *et al.* Minimally invasive versus sternotomy approaches for mitral reconstruction: comparison of intermediate-term results. *J Thorac Cardiovasc Surg* 2001;121:708-13.
20. Holzhey DM, Seeburger J, Misfeld M, *et al.* Learning minimally invasive mitral valve surgery: a cumulative sum sequential probability analysis of 3895 operations from a single high-volume center. *Circulation* 2013;128:483-91.
21. Murzi M, Miceli A, Cerillo AG, *et al.* Training surgeons in minimally invasive mitral valve repair: a single institution experience. *Ann Thorac Surg* 2014;98:884-9.
22. Czesla M, Götte J, Weimar T, *et al.* Safeguards and pitfalls in minimally invasive mitral valve surgery. *Ann Cardiothorac Surg* 2013;2:849-52.
23. Vallabhajosyula P, Wallen T, Pulsipher A, *et al.* Minimally Invasive Port Access Approach for Reoperations on the Mitral Valve. *Ann Thorac Surg* 2015; 100:68-73.
24. Murzi M, Miceli A, Di Stefano G, *et al.* Minimally invasive right thoracotomy approach for mitral valve surgery in patients with previous sternotomy: a single institution experience with 173 patients. *J Thorac Cardiovasc Surg* 2014;148:2763-8
25. Botta L, Cannata A, Bruschi G, *et al.* Minimally invasive approach for redo mitral valve surgery. *J Thorac Dis* 2013;5 (Suppl 6): S686-93.

26. Arcidi JM Jr, Rodriguez E, Elbeery JR, *et al.* Fifteen-year experience with minimally invasive approach for reoperations involving the mitral valve. *J Thorac Cardiovasc Surg* 2012;143:1062-8.
27. Goksel OS, Tireli E. Minimally invasive mitral valve surgery after previous sternotomy. *Ann Thorac Surg* 2009;88:1384
28. Murzi M, Solinas M, Glauber M. Is a minimally invasive approach for re-operative mitral valve surgery superior to standard re-sternotomy? *Interact Cardiovasc Thorac Surg* 2009;9:327-32.
29. Seeburger J, Borger MA, Falk V, *et al.* Minimally invasive mitral valve surgery after previous sternotomy: experience in 181 patients. *Ann Thorac Surg* 2009;87:709-14.
30. Casselman FP, La Meir M, Jeanmart H, *et al.* Endoscopic mitral and tricuspid valve surgery after previous cardiac surgery. *Circulation* 2007;116(Suppl): 1270-5.
31. Perier P, Hohenberger W, Lakew F, *et al.* Toward a new paradigm for the reconstruction of posterior leaflet prolapse: midterm results of the "respect rather than resect" approach. *Ann Thorac Surg* 2008;86:718-25.
32. David TE. Replacement of chordae tendinae with expanded polytetrafluoroethylene sutures. *J Card Surg* 1989; 4:286-90.
33. David TE, Bos J, Rakowski H. Mitral valve repair by replacement of chordae tendinae with polytetrafluoroethylene sutures. *J Thorac Cardiovasc Surg* 1991; 101:495-501.
34. Zussa C, Frater RW, Polesel E, *et al.* Artificial mitral valve chordae: experimental and clinical experience. *Ann Thorac Surg* 1990; 50:367-73.
35. David TE, Armstrong S, Ivanov J. Chordal replacement with polytetrafluoroethylene sutures for mitral valve repair: a 25-year experience. *J Thorac Cardiovasc Surg* 2013; 145:1563-9.
36. von Oppel U, Mohr FW. Chordal replacement for both minimally invasive and conventional mitral valve surgery using premeasured Gore-Tex loops. *Ann Thorac Surg* 2000; 70:2166-8.
37. Seeburger J, Borger MA, Falk V, *et al.* Gore-Tex loop implantation for mitral valve prolapse: The Leipzig Loop Technique. *Operative Techniques in Thoracic and Cardiovascular Surgery* 2008; 13:83-90.
38. Falk V, Seeburger J, Czesla M, *et al.* How does the use of polytetrafluoroethylene neochordae for posterior mitral valve prolapse (loop technique) compare with leaflet resection? A prospective randomized trial. *J Thorac Cardiovasc Surg* 2008; 136:1205.
39. Seeburger J, Falk V, Borger MA, *et al.* Chordae replacement versus resection for repair of isolated posterior mitral leaflet prolapse: à égalité. *Ann Thorac Surg* 2009;87:1715-2.
40. Ender J, Borger MA, Scholz M, *et al.* Cardiac surgery fast-track treatment in a post-anesthetic care unit: six-month results of the Leipzig fast-track concept. *Anesthesiology* 2008;109:61-6.
41. Misfeld M, Borger M, Byrne JG, *et al.* Cross-sectional survey on minimally invasive mitral valve surgery. *Ann Cardiothorac Surg* 2013;2:733-8.

Chapter 5

Anaesthesia and Transoesophageal Echocardiography for Minimally Invasive Heart Valve Surgery

Jonathan Blackshaw, Kenneth Palmer and Omar Al-Rawi

“Nature is full of infinite causes that have never occurred in experience”

Leonardo Da Vinci (1452 - 1519)

Introduction

The advancement in many cardiac surgeries towards less invasive approaches presents new challenges to safe and effective anaesthetic practice. Limited surgical access dictates a greater reliance on alternative approaches to many conventional aspects of management. There must be accurate pre-operative assessment of the presenting lesion and confirmation that a minimal access approach is both appropriate and safe. Anaesthetic assistance is often required to facilitate vascular access and clamping techniques as well as to achieve surgical access for certain procedures. Reduced access also dictates reconsideration of ways to provide emergency interventions such as pacing and defibrillation.

Although some minimally invasive procedures, e.g. transcatheter aortic valve implantation (TAVI), are now routinely conducted under local anaesthesia, the anaesthetist does not have a dwindling role in the conduct of minimally invasive cardiac surgery (MICS). General anaesthesia remains a mainstay for transthoracic approaches used in the repair of mitral valve lesions, atrial septal defects (ASDs), for atrial myxoma excision and for MIDCAB surgery (minimally invasive direct coronary artery bypass). Some approaches require significant modification to the standard anaesthetic technique used for a median sternotomy. The advent of minimally invasive mitral valve surgery (MIMVS), for example, is facilitated by one-lung anaesthesia (OLA). Limited surgical access also necessitates a reliance on high quality live imaging, especially transoesophageal echocardiography (TOE), which is increasingly practiced by the cardiothoracic anaesthetist. These factors have extended the involvement of the anaesthetist well beyond simply the safe provision of anaesthesia and analgesia.

The aim of this chapter is to outline the extended role of the cardiac anaesthetist in minimally invasive approaches to the mitral and aortic valves and to highlight the key differences from traditional open techniques. The authors acknowledge that this is not an exhaustive guide to the conduct of cardiac anaesthesia for these procedures but that it should hopefully serve to highlight the salient points.

Preparation and Induction

Whilst patient selection for surgery is ordinarily determined by the surgical team, a good understanding of the issues related to the case and a thorough review of the investigations should form part of any anaesthetic pre-operative assessment. As with all cardiac surgery, consideration of co-morbid disease, the physiological implications of the primary lesion and the effects of anaesthetic drugs should contribute to the formulation of an anaesthetic strategy. When considering one-lung ventilation (OLV) with a double lumen tube, particular attention should be paid to assessment of the airway and to the patient's cardiorespiratory fitness to manage on OLV (discussed later in detail).

Peripheral arterial cannulation for continuous blood pressure (BP) monitoring should be performed prior to induction in line with the well-established anaesthetic setup for cardiac surgical cases. Where endoaortic balloon occlusion (EBO) is planned, bilateral radial artery lines are indicated as this will allow detection of balloon migration distally towards the innominate artery. As this is essential, brachial artery cannulation may occasionally be required if radial access is troublesome. Adequate peripheral venous access should be achieved, with ideally at least one 14G cannula to allow for rapid fluid resuscitation, as central access sites are often utilised for other purposes.

A limitation of MICS is the inability to place internal defibrillator paddles in the event of dysrhythmias. External defibrillator pads must therefore be placed pre-operatively and

connected to the defibrillator. Appropriate pad positioning should be confirmed by the surgical team so as not to interfere with surgical access, but ordinarily they are placed slightly anterior to the left mid-axillary line over the apex of the heart, and over the right scapula. One should bear in mind the increased thoracic impedance which results from carbon dioxide insufflation of the right hemithorax. This can be overcome by re-inflation of the right lung in the event of unsuccessful defibrillation [1].



Minimally invasive mitral valve surgery employs supine positioning with 30° elevation of the right hemithorax. Care should be taken to avoid pressure injury to elevated areas by appropriate cushioning and a slight leftward head turn will prevent injury to the brachial plexus. In the event of a major complication, removal of the bolster allows the patient to be quickly repositioned for a sternotomy. Following placement of the surgical equipment and cushioning of the right arm, access to this side of the patient is extremely limited, making left-sided peripheral venous cannulation preferable where possible. The requirement for TOE, fibre-optic bronchoscopy and neck lines in addition to the standard arrangement of lines, ventilator tubes and monitors makes access to the patient's head also difficult. This can be particularly hazardous during OLV, where arterial oxygen desaturation may require prompt adjustment of the position of the double-lumen tube. A plan for emergency access to the patient should be established pre-operatively during the set-up phase.

A major benefit of minimal access cardiac surgery is speed of recovery, including a reduced time to extubation and length of stay on the intensive care unit which can potentially be hampered by postoperative hypothermia [2]. A combination of an underbody warming mattress, forced hot air blankets, perioperative thermal hats and fluid warmers is highly recommended.

Venous cannulation

For MIMVS, no more than three separate cannulae can be inserted into the right internal jugular vein (RIJV) at any one time. Ultrasonic assessment of the diameter of the RIJV is important to assess the size of the superior vena cava (SVC) drainage cannula (17 or 19 Fr) and to exclude aberrant anatomy. The size, type and number of catheters is dependent on several factors, including the size of the patient, the quality of peripheral venous access, the need for retrograde cardioplegia and whether there is a requirement to vent the pulmonary artery. Other than standard central venous catheters (CVCs), these cannulae require placement in the right internal jugular vein as they are virtually impossible to position correctly from the left. Commonly used options include:

- 11cm quad-lumen CVC for routine central venous access,
- Introducer sheaths:
 - 6 Fr for transvenous pacing wires,
 - 8.5 Fr sheath for:
 - Pulmonary artery vent, or
 - Pulmonary artery flotation catheter
with or without pacing functionality,

- Multi-access catheters - these combine a high-flow CVC with a Swann sheath and provide a useful means of sparing neck space for additional lines,
- Coronary sinus catheter which requires an 11F introducer,
- Superior vena cava drainage cannula, commonly 17F or 19F.

Bypass cannulae

Peripheral insertion of venous bypass cannulae can be achieved using either a single femoral venous cannula (two stage or multi stage) into the SVC, or by separate cannulation of the femoral and internal jugular veins. Body surface area (BSA) offers a good estimate of metabolically active body mass, and hence cardiac output, so is useful in determining the need for bicaval cannulation. The authors are unaware of any data regarding absolute values but strongly recommend bicaval cannulation with BSA >2m² (some suggest weight >75kg), and frequently use it as a preference with much lower BSA to ensure maximal cerebral drainage and a bloodless surgical field. Similarly, for surgery to the right side of the heart, bicaval cannulation will be required. We advocate the use of a 17F SVC cannula for smaller internal jugular veins and 19F where possible (Fig 1). In brief, correct sizing should balance the risk of trauma from over-sized cannulae against the risk of superior vena cava syndrome (high SVC pressure and reduced cerebral perfusion pressure) from under-sized cannulae.

Considering the size of the cannula involved, the use of neck ultrasound and TOE to ensure perfect guidewire positioning prior to dilatation and cannula insertion is mandatory. Transoesophageal echo guidance will guide the IVC cannula tip to sit at the cavoatrial junction on the bicaval view.

Coronary sinus cannulation for retrograde cardioplegia

Accessing the coronary sinus via an 11F internal jugular sheath provides a valuable additional cardioplegia strategy for minimal access surgeries. This becomes all the more imperative as the degree of aortic insufficiency increases but is occasionally technically very difficult as a consequence of variable coronary sinus orifice size and anatomy. Insertion requires a skilled TOE assistant and a great deal of patience. Should insertion prove impossible via the internal jugular vein, a steerable surgical cannula (MiRCSP cannula, Medtronic, Minneapolis, MN) is available but this will also require accurate TOE guidance.

Transoesophageal Echo (TOE)

With advances in MICS, there comes an increased requirement for high quality imaging beyond that required in traditional procedures. In most centres, perioperative transoesophageal echocardiography (TOE) has developed as an important extended role of the cardiac anaesthetist and is important in MICS. Where TOE is contraindicated or technically not possible (e.g. oesophageal pathologies), serious consideration should be given as to whether a minimal access approach is appropriate. The role of TOE extends well beyond the analysis of myocardial function and valve pathology, with additional information required to exclude contra-indications to minimally invasive surgery: verification of intraluminal positioning of venous and arterial guidewires, monitoring endoaortic balloon positioning, safe de-airing of cardiac chambers and to provide a rapid assessment of the surgical repair prior to the removal of cannulae.

Anatomical assessment

Assessment begins with acquisition of the standard views that are common to any formative TOE examination as set out by the American Society of Anaesthesiologists / European Association of Echocardiography / Echo Committee of the European Association of Cardiothoracic Anaesthesiologists guidelines [3]. Comparison of these images with other pre-operative imaging enables the team to confirm the diagnosis, plan the repair / replacement strategy and identify co-existing myocardial pathologies that may be amenable to concomitant repair.

Specific attention should be placed on ensuring that there are no contraindications to a minimal access approach. Aortic valve incompetence (AI) is rarely a problem when trivial, but when mild or greater the adequacy of antegrade cardioplegia and myocardial protection are of increasing concern.

Retrograde cardioplegia via a coronary sinus catheter is certainly useful in this instance. To quantify AI, we recommend colour flow Doppler in the mid-oesophageal long axis view to assess regurgitant jet velocity and width. The mid-oesophageal short axis view allows estimation of the regurgitant area of the valve, but ideally a deep transgastric view will be required for continuous wave (CW) Doppler measurement of AI pressure half-time.

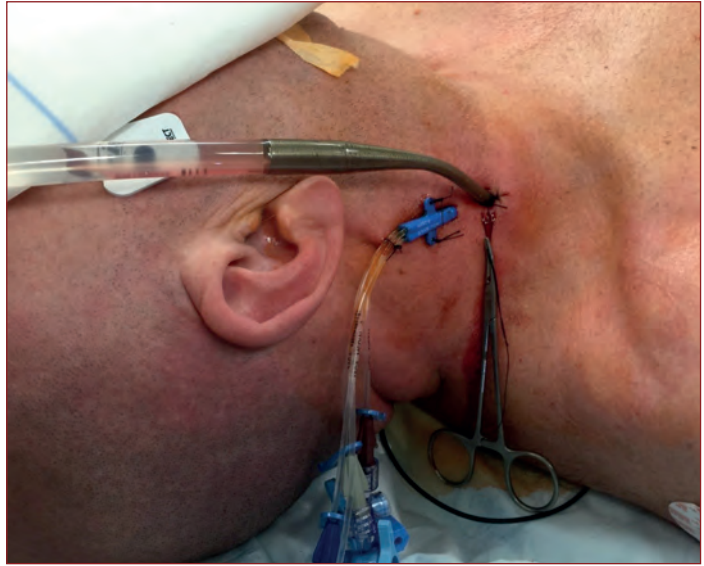


Fig 1: Superior vena cava cannulation with 19F Biomedicus (Medtronic, Minneapolis, MN) and standard 11cm quad lumen central venous catheter in right internal jugular vein.

Grade IV and V atheroma of the aorta significantly increases the risk of cerebral embolic complications during retrograde femoral arterial perfusion [4]. Mid-oesophageal long and short axis views of the aorta are used to screen for aortic disease prior to peripheral cannula insertion. These views are also used for detecting correct intraluminal placement of the arterial guidewire prior to arterial cannulation and the descending thoracic aorta should be monitored when going on bypass to exclude an iatrogenic retrograde aortic dissection. In certain patients, cannulation of the right axillary artery or direct aortic cannulation are alternatives.

Systolic anterior motion of the mitral valve (SAM) is a well-described complication following mitral valve repair surgery. Despite improvements in repair techniques, the incidence of SAM remains between 2-16% [5]. Systolic anterior motion results in the displacement of the anterior leaflet of the mitral valve into the left ventricular outflow tract (LVOT) leading to left ventricular outflow tract obstruction (LVOTO) and mitral regurgitation. Specific care and attention must be given to the preoperative risk stratification of SAM by TOE, especially in moderate to high risk cases, as this will influence the repair technique. Complex

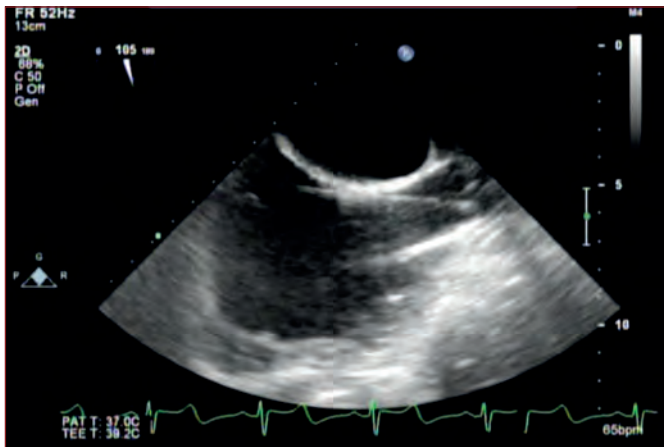


Fig 2: Inferior vena cava guidewire passing into the SVC.

40-120° combined with pulsed wave (PW) doppler and / or colour flow (CF) Doppler will aid detection of thrombus. The tricuspid valve should also be closely scrutinised with its diastolic annular diameter measured in a lower oesophageal 4-chamber view. An annulus greater than 40mm (or 21mm/m² BSA) or > 2+ TR merits concomitant tricuspid annuloplasty. It is important that an atrial septal defect (ASD) or a patent foramen ovale (PFO) are detected as IVC cannulation can be more challenging in this circumstance as the guidewire has a tendency to cross the atrial septum into the LA rather than pass into the SVC.

Guidewire and cannula positioning

During peripheral venous cannulation, the bicaval view facilitates identification of the correct position of the guidewire and subsequently the cannula. This is visualised emerging inferiorly from the IVC in the case of femoral drainage (Figure 2), or from the SVC in the case of jugular cannulation (Figure 3).

Either the bicaval view or a lower oesophageal 4-chamber view is used to guide coronary sinus cannulation for retrograde cardioplegia. This is frequently extremely time consuming but is essential in cases with more than mild AI. A second pair of experienced hands to steer the TOE is often invaluable.

For visualisation of the pulmonary artery and placement of catheters for venting or haemodynamic monitoring, the RV inflow/outflow view is commonly used.

The IntraClude (Edwards Lifesciences, Irvine, CA.) endoaortic balloon occlusion system has been a significant development in the field of MIMVS and internally occludes the ascending aorta for antegrade delivery of cardioplegia without the need for an external aortic clamp. Accurate positioning is imperative for this to be safe. This requires a combination of bilateral radial cannulation (observing for a change in the right radial trace indicating distal migration of the IntraClude towards the innominate artery) and TOE (mid-oesophageal long-axis view) to monitor the position of the guidewire / catheter and balloon position in the proximal ascending aorta (Figure 4). As migration of the IntraClude balloon can occur, particularly during delivery of antegrade cardioplegia, continuous monitoring of its position is important prior to opening of the left atrium.

measurements and scoring systems are available but in accordance with Varghese *et al.*, we specifically look for small left ventricles, tall posterior mitral leaflets, an aorto-mitral angle <120° and basal septal hypertrophy as these factors, especially when in combination, multiply the risk [6].

Additional considerations in MIMVS include the assessment of the left atrial appendage (LAA) which is imperative with any history of atrial fibrillation.

Mid-oesophageal views from

3D Transoesophageal Echo

3D TOE has become increasingly popular and particularly lends itself to minimally invasive mitral valve surgery. By no means is it imperative for these cases but the superior quality of imaging greatly aids in planning the repair strategy and localising any tiny residual leaks after valve repair which can then be addressed.

One-Lung Anaesthesia

Although not an absolute requirement, right lung isolation offers an effective means of achieving optimal surgical visualisation. This is, however, not without risk and careful consideration should be given to patient selection, choice of technique and the management of any subsequent deleterious physiological effects.

It is important to assess cardiorespiratory fitness for one-lung anaesthesia prior to surgery. Patients with severe respiratory disease may lack the pulmonary reserve to compensate for the loss of functional lung capacity during one-lung ventilation (OLV) and may encounter complications post-operatively. Details relating to smoking history, exercise tolerance, use of bronchodilator and steroid therapy, susceptibility to respiratory infection and the need for hospital admission should be sought and supported by careful examination of the respiratory system. Pulmonary function tests, arterial blood gas analysis and pulmonary imaging provide important information regarding respiratory reserve.

One must also consider the effects of OLV on the cardiovascular system. Increases in pulmonary vascular resistance secondary to collapse of the pulmonary vascular bed, high inspiratory pressures, hypoxia or hypercapnia may be poorly tolerated by patients with sequelae of mitral valve disease including pulmonary hypertension, right heart failure or tricuspid disease. The arrhythmogenic effects of hypoxia and hypercapnia may be poorly tolerated by patients with impaired ventricular function [7].

Although right lung isolation can be achieved by advancing a standard single-lumen endotracheal tube into the left main bronchus under fibre-optic bronchoscopic guidance,

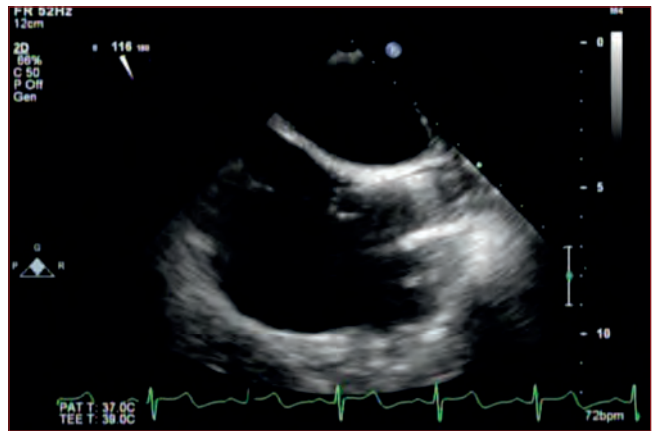


Fig 3: Superior vena cava guidewire (J-tip) is arrowed).

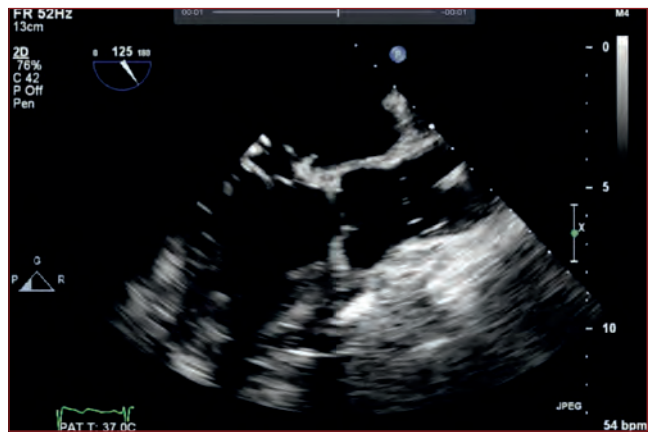


Fig 4: Intraclade device inflated in ideal position in ascending aorta

the use of either a left-sided double-lumen tube or an endobronchial blocker is generally preferred owing to specific advantages of each technique. Double-lumen tubes (DLTs) provide the greatest control in alternating between one and two-lung ventilation at various stages of the procedure. They will also permit direct bronchoscopy, suctioning or the application of continuous positive airways pressure (CPAP) to be applied to an individual lung field. Double-lumen tubes tend to be more difficult



to insert as a consequence of significantly larger external diameters and construction from a less flexible material than standard endotracheal tubes. Furthermore, in patients who require ongoing ventilation postoperatively in the critical care setting, DLTs must be exchanged for a single-lumen tube which can be achieved by direct laryngoscopy or over an exchange catheter. A detailed pre-operative airway assessment is imperative and for patients identified as being at high risk of a difficult intubation, alternatives should be considered.

Endobronchial blockers, such as the Arndt or Cohen devices (Cook Medical, Bloomington, IN.), are inserted through the lumen of a single-lumen endotracheal tube. They are ideal for patients anticipated to be difficult to intubate and in those with a tracheostomy in situ. For right-sided lung isolation, the blocker is steered into the right main bronchus where the cuff is inflated immediately proximal to the orifice of the right upper lobe bronchus. Right lung isolation can therefore prove difficult in patients with a very proximal (carinal) right upper lobe orifice. Furthermore, blockers offer little control beyond the cuff, making alternating between one- and two- lung ventilation frequently slow and awkward. A narrow central port allows adaptors to be added for suctioning (to aid lung collapse) or attachment to oxygen for insufflation to minimise shunt. At the end of the case the blocker can simply be removed, leaving the single lumen tube ready for transfer to the critical care area.

Thoracic surgery involving OLV is performed in the lateral decubitus position, where the lower and upper lungs are termed dependent and non-dependent respectively. Following lung isolation, significant shunting of blood through the unventilated, non-dependent lung occurs, with consequent arterial desaturation. Over time, hypoxic pulmonary vasoconstriction (HPV) in the non-dependent lung diverts blood back to the ventilated lung thus improving mismatching of ventilation and perfusion. The exact mechanism for HPV is not fully understood but is likely to relate to a direct response of the pulmonary vasculature to regional hypoxia or to the triggered release of vasoactive substances [8]. In the lateral position, compression of the dependent lung by the weight of the mediastinum, the cephalad movement of the diaphragm and reduced compliance of the dependent chest wall results in atelectasis and a reduction in the effective capacity of the dependent lung. Theoretically, when compared with the lateral decubitus position, the partial elevation of the right hemithorax for MIMVS may increase the fraction of blood shunted to the non-ventilated lung owing to the reduced effects of gravity and consequently worsen hypoxia. This will be partially offset by the reduced compression and improved ventilation of the ventilated lung in this position.

Serious injury of the deflated lung is a well-recognised complication of one-lung anaesthesia which, although rare, carries a high mortality. It is characterised by alveolar infiltration of inflammatory mediators, increased vascular permeability and worsening PaO₂/FiO₂ gradient, and hence is often referred to as unilateral adult respiratory distress syndrome

(ARDS) or unilateral pulmonary oedema. The aetiology is likely multifactorial and remains the subject of ongoing research but an ischaemia-reperfusion injury is the likely aetiology [9,10]. Potential prophylactic measures aimed to improve perfusion of the pulmonary parenchyma on bypass include the use of low level PEEP to the deflated lung, limiting the elevation of the hemithorax above the level of the heart, a higher mean arterial pressure, minimising cross-clamp time and lowering the systemic temperature.

Post-operative care and analgesia

Irrespective of surgical approach, the focus of the multi-disciplinary team in the post-operative period will be the avoidance of complications and the facilitation of return to a normal functional state. There is a growing recognition that preparation for recovery begins in the pre-operative period through optimisation of chronic disease states and patient education. Fastidious intra-operative attention to maintaining homeostatic parameters such as temperature, acid-base balance, coagulation, oxygenation and cardiovascular indices will enable an early extubation strategy. Minimal access surgery confers the benefit of significantly less tissue /sternal trauma which, permitting the procedure has progressed without complication and physiological factors allow, enables patients to be considered for on-table extubation [11].

Effective analgesia minimises the stress response to surgery and postoperatively allows early extubation, mobilisation and effective respiratory physiotherapy, all of which confer a reduced risk of pulmonary complications. A multi-modal analgesic regimen combining systemic analgesics and regional anaesthesia should be considered. Regular paracetamol is an effective and low-risk option used in most systemic analgesic strategies. Non-steroidal anti-inflammatory drugs (NSAIDs) have proven benefit in the treatment of pain after cardiothoracic surgery [12] but consideration should be given to the appropriateness of their use in patients with renal dysfunction or a history of peptic ulcer disease. Extra care must be taken when timing NSAID use following CPB, in terms of platelet dysfunction / bleeding risk and renal dysfunction.

The use of local anaesthetics is imperative for the early extubation and successful early recovery of minimal access mitral cases. Learning from more established thoracic practices in our institution, we have adopted thoracic paravertebral blocks, either as a stat block with longer acting agents, or the thoracoscopic insertion of a paravertebral catheter in the T3-4 region. This confers excellent chest wall analgesia whilst avoiding the serious risks and side effects associated with epidural blockade [13]. This can be combined with intercostal nerve blockade and direct wound infiltration, although care must be taken not to exceed the recommended maximum dose of local anaesthetic to prevent toxicity. The preferences, skills and experience of the team members will determine whether these blocks are performed by the surgeon under direct vision or by the anaesthetist using either landmark or ultrasound-guided techniques. Systemic anticoagulation for CPB increases the risk of nerve injury from haematoma formation or haemorrhage from inadvertent vascular puncture; consideration should therefore be given to the timing of the block in relation to administration and reversal of anticoagulation.

Minimally Invasive Aortic Valve Surgery

Modified sternal incisions and avoidance of thoracotomy negate the need OLV. Arterial cannulation can usually be achieved centrally whilst venous cannulation will be either central or peripheral (percutaneous femoral venous). Reduced surgical access does limit

certain interventions such as the placement of pacing wires and internal defibrillator paddles. There is also a greater reliance upon TOE for dynamic intra-operative assessment, aortic annular measurements and venous guidewire placement.

External defibrillator pads and a transvenous pacing wire are placed pre-operatively. Swan-Ganz bipolar pacing catheters (Edwards Lifesciences, Irvine, CA.) are commonly inserted via the right internal jugular vein using a 6 Fr introducer for right ventricular endocardial pacing. Electrocardiographic confirmation of ventricular pacing can be supported by TOE visualisation of wire placement. Access to the coronary sinus for retrograde cardioplegia remains limited and becomes heavily reliant on TOE guidance. As discussed previously, the lower oesophageal and bicaval views offer the best images to facilitate this.

The reduced tissue trauma and improved sternal stability afforded by minimally invasive aortic valve surgery benefits post-operative recovery; however, most of this benefit is observed in the days to weeks following hospital discharge. In the immediate post-operative period, patients still experience discomfort similar to that from a median sternotomy. Analgesic strategy for these procedures therefore mirrors that used for traditional valve surgery.

References

1. Hatton KW, Kilinski LC, Ramaiah C, *et al.* Multiple failed external defibrillation attempts during robot-assisted internal mammary harvest for myocardial revascularization. *Anesth Analg* 2006; 103:1113-4.
2. Modi P, Hassan A, Chitwood WR. Minimally invasive mitral valve surgery: a systematic review and meta-analysis. *Eur J Cardiothorac Surg.* 2008; 34:943-952.
3. Flachskampf FA, Badano L, Daniel WG, *et al.* Recommendations for transoesophageal echocardiography: update 2010. *European Journal of Echocardiography* 2010; 11:557-576.
4. Gravlee GP, Davis RF, Stammers AH, *et al.* Cardiopulmonary Bypass – Principles and Practice. 3rd Edition.
5. Maslow A, Regan M, Haering J, *et al.* Echocardiographic predictors of left ventricular outflow obstruction and systolic anterior motion of the mitral valve after mitral valve reconstruction for myxomatous mitral valve disease. *J Am Coll Cardiol.* 1999; 34(7):2096-2104.
6. Varghese R, Itagaki S, Anelechi C, *et al.* Predicting systolic anterior motion after mitral valve reconstruction: using intraoperative transoesophageal echocardiography to identify those at greatest risk. *Eur J Cardiothorac Surg.* 2014 Jan; 45(1):132-7; discussion 137-8.
7. Vernick WJ, Woo JY. Anaesthetic considerations during minimally invasive mitral valve surgery. *Seminars in Cardiothoracic and Vascular Anaesthesia.* 2012; 16(1): 11-24.
8. Sommer N, Dietrich A, Schermuly RT, *et al.* Regulation of hypoxic pulmonary vasoconstriction: basic mechanisms. *Eur Respir J.* 2008; 32(6): 1639-51.
9. Gothard J. Lung injury after thoracic surgery and one-lung ventilation. *Curr Opin Anaesthesiol.* 2006; 19(1): 5-10.
10. Eichenbaum KD, Neustein S. Acute lung injury after thoracic surgery. *J Cardiothorac Vasc Anesth.* 2010; 24(4): 681-90.
11. Lynch JJ, Mauermann WJ, Pulido JN, *et al.* Use of paravertebral blockade to facilitate early extubation after minimally invasive cardiac surgery. *Semin Cardiothorac Vasc Anesth.* 2010; 14(1): 47-8.

12. Bainbridge B. NSAID analgesia, pain control and morbidity in cardiothoracic surgery. *Can J Anaesth.* 2006; 53(1): 46-59.
13. Davies R, Myles P, Graham J. A comparison of the analgesic efficacy and side-effects of paravertebral vs epidural blockade for thoracotomy – a systematic review and meta-analysis of randomised controlled trials. *British Journal of Anaesthesia.* 2006; 96(4): 418-426.

Chapter 6

Transcatheter Mitral Valve Repair with The MitraClip – The Evidence and Current Indications

Mamta Buch

“Beware of the first movements; they are almost always good”

Charles Maurice de Talleyrand-Perigord (1754 - 1838)

Background

Mitral regurgitation (MR) affects 24% of adults with valvular heart disease and is present in 7% of the population over the age of 75 years [1,2]. It is increasingly prevalent in developed countries and represents a significant cause of morbidity and mortality.

Surgeons have led and advanced the treatment of mitral valve disease over the past 30 years and surgical mitral valve repair or replacement remains the treatment of choice for symptomatic, severe mitral regurgitation [3]. The development of percutaneous mitral valve procedures as an alternative to mitral valve surgery provides options for patients deemed too high risk for surgery.

The MitraClip percutaneous mitral valve repair system (Abbott Vascular Inc, Santa Clara, CA.) is the most established repair technique. The aim of this chapter is to review the evidence and current indications for MitraClip repair.

Introduction

There has been a transformation throughout the surgical world from “big surgery” to minimally invasive approaches. The drive in transcatheter innovation for acquired structural heart disease over the past 10-15 years pursues the ideals of delivering improved survival and quality of life whilst minimising procedural risk, recovery time and maintaining cost-effectiveness.

Indications for surgical mitral valve intervention

Current American Heart Association (AHA) / American College of Cardiology (ACC) and European Society of Cardiology (ESC) / European Association of CardioThoracic Surgery (EACTS) guidelines recommend that surgical repair or replacement be performed (class I) for symptomatic patients with severe MR due to a primary valvular abnormality or asymptomatic patients with severe MR and LV dysfunction or enlargement [3,4]. Surgery may also be considered (class IIb) as an option for symptomatic patients with secondary (functional) MR. Mitral valve repair, when feasible, is almost universally regarded as the preferred method of MR correction (in non-rheumatic valves) over mitral valve replacement due to the advantages of even partial preservation of sub-valvular chordae [5-8]. Surgical repair techniques are defined by the aetiology and lesions of MR and provide a tailored approach to restoring normal mitral valve function [9,10]. Surgical repair results for primary or degenerative mitral regurgitation are excellent in experienced centres with high procedural volumes. Mortality rates <1% and freedom from re-operation of 93% at 10 years have been achieved [11].

Unlike primary MR, secondary or functional MR (FMR) remains a surgical challenge and a contentious area. It is often treated with implantation of an undersized annuloplasty ring,

or chord-sparing valve replacement particularly in cases of end-stage MR with LV remodelling [12]. Data have failed to clearly demonstrate a survival benefit in patients with significant MR due to LV dysfunction [13]. The durability of these repairs is suboptimal, with reported recurrence rates of greater than 2+ MR of 15–60% [14, 15]. Only a third of patients with functional MR are therefore referred for surgery, and FMR is present in 90% of patients who are denied surgery [16,17]. This reflects



the complex pathophysiology of FMR and the underlying ventricular nature of the problem in a high risk population. Treatment of FMR has come into sharper focus as a target for intervention with the development of less invasive percutaneous strategies.

Severe MR is a complex condition and it leads to slow progressive deterioration if left untreated. Up to 50% of patients with criteria for surgical intervention are not referred for surgery largely due to advanced age, significant co-morbidities and the presence of LV dysfunction [16,18]. This clinical unmet need has fuelled innovation in transcatheter approaches for the mitral valve.

Challenges of transcatheter mitral valve techniques

The first case of percutaneous mitral valve repair was performed in 2003 [19]. The clinical application of this approach, however, has been more demanding compared to aortic valve stenosis, which has seen a remarkable development in the high risk population [20]. Trials evaluating intermediate risk patients might lead to expansion in indications for aortic valve technology. Mitral valve functional anatomy and the pathophysiological mechanisms of MR are considerably more complex and the patient population more heterogeneous for age and co-morbidities [21]. This presents greater challenges for the transcatheter approach, device development and indeed, trial design. Devices have suffered from limited early clinical success, the need for modifications and some with early promise having to be discontinued.

Transcatheter mitral valve repair: MitraClip

Transcatheter approaches for mitral valve repair address specific components of the functional anatomy of the mitral valve complex and may be broadly divided into three groups: coronary sinus and annular approaches [22-24], leaflet repair [25] and subvalvular chamber remodelling [26,27]. The majority of experience thus far is in coronary sinus annuloplasty and leaflet repair. The MitraClip (Abbott Vascular Inc, CA., USA) is the most established percutaneous mitral valve repair technique and has been clinically applied in 25,000 cases worldwide [28].

The MitraClip repair system is based on the surgical procedure pioneered by Ottavio Alfieri in the early 1990s [29]. This technique creates a competent double orifice valve by suturing the middle segment of the anterior leaflet (A2) to the middle segment of the posterior leaflet (P2). To improve the durability of results, the Alfieri repair is typically combined with implantation of a band or complete annuloplasty ring, except in cases with a severely calcified mitral annulus [30].

The MitraClip is made of a cobalt–chromium alloy and covered with polypropylene fabric to promote tissue in-growth [31,32]. It is a single-size clip device that has been used to treat patients with functional, mixed and degenerative MR. The MitraClip has a two arm structure, with grippers above the arms to assist with capture of the mitral valve leaflets and their approximation while the heart is beating.

The procedure

The approach is via the femoral vein and standard trans-septal access permits delivery of the catheter-based MitraClip device into the left atrium (LA). All manoeuvres are performed under transoesophageal echocardiographic (TOE) visualisation including real-time 3D-TOE. The device is positioned directly above the regurgitant jet and advanced across

the mitral valve into the LV, with the two arms of the Clip perpendicular to the valve leaflets. The Clip is then retracted toward the mitral valve leaflets, so it can engage the appropriate segments of the mitral valve. The arms and grippers of the Clip are closed and if the leaflet insertion is judged acceptable by TOE, the degree of residual MR is assessed. If reduction is inadequate, the Clip can be released and repositioned or a second clip may be implanted. The addition of Clips is guided by, amongst other factors, transmitral diastolic gradient as a surrogate measure for potential development of mitral stenosis. After the Clip(s) are deployed and the delivery catheter is removed from the patient, manual compression, use of a temporary subcutaneous suture or placement of a percutaneous closure device may be used to close the femoral vein access site.

The unique features of this procedure are: 1) the clip is repositionable, 2) real time echocardiographic assessment of MR reduction is obtained, 3) it produces vertical coaptation of leaflets, 4) surgical options may be preserved.

Current evidence

MitraClip is the first percutaneous device to be compared to surgery in a randomised controlled trial (RCT). Positive safety and mid-term durability results were reported from the initial Endovascular Valve Edge-to-Edge Repair Study (EVEREST) cohort [33]. This comprised patients enrolled in the EVEREST I [34] and the roll-in phase of the EVEREST II clinical trial. The pivotal EVEREST II phase II RCT comprising 279 patients was completed in 2008 [35]. The EVEREST trial is a first in the standard applied to evaluate mitral valve intervention for MR, with pre-specified mandatory clinical and echocardiographic follow-up at 1-year intervals for 5 years in both arms of the study, and echocardiographic images reviewed and adjudicated by a central core laboratory. It compared the MitraClip directly to mitral valve surgery and included patients with both degenerative and functional MR, but predominantly DMR (70%).

Surgery was found to be superior for the primary outcome of freedom from death, surgery for mitral valve dysfunction, or $\geq 3+$ MR. MitraClip was found to be very safe, with only 15% of patients that underwent MitraClip experiencing a major adverse event compared with 48% of surgical patients (largely composed of transfusion ≥ 2 units of blood). The degree of MR reduction was greater in the surgical patients, however important clinical indicators including New York Heart Association (NYHA) functional status, ejection fraction, LV dimensions and quality of life (QoL) improved in both groups. Nearly 80% of patients were free from 3+ or 4+ MR after Clip placement and thus avoided surgery in 12-month follow-up. The subset of patients with functional MR appeared to have had comparable outcomes with the percutaneous procedure compared with surgery at 1 year. There were no incidences of clinically significant cases of mitral stenosis in the MitraClip group.

Four-year follow-up of patients in the EVEREST II trial has shown no increase in late MR recurrence compared with surgery [36]. Those who achieved a good immediate result with MitraClip showed excellent durability of the repair at 4 years. The clinical benefits of improved NYHA class were sustained and mortality rates were not different between the treatment arms at 1 year or 4 years.

The majority of MitraClip-treated patients who require an additional procedure do so within the first 6 months after initial treatment [35]. The rates of reoperation or additional MitraClip procedures are no different between the 2 treatment groups after the first year.

Previous experience with mitral valve surgical repair raises concern that the greater post-procedural residual MR in the MitraClip group might lead to more subsequent cross-over to surgery over time, or that lesser degrees of residual MR (2+) would result in subsequent deterioration of the 1-year results. There does not appear to be significant change in MR grade, ventricular function or dimensions during follow-up, however longer-term follow-up of the subset of patients with MR grade 2+ is ongoing.

Mitral valve intervention at a late stage is known to adversely affect both early and late outcomes. A review by Buzzatti *et al.* of a single centre experience over 5½ years compared MitraClip to surgery in octogenarians with DMR [37]. MitraClip was safer, despite being applied in an older and more symptomatic population with a higher burden of comorbidities. Reduction of MR was not as effective as surgery but provided reduction in symptoms. This improvement in quality of life, with greater procedural safety and quicker recovery compared to surgery, is of key relevance in the elderly population and would appear feasible with MitraClip.

In Europe, the CE mark was received in March 2008, whilst US Food and Drug Administration (FDA) approval has been more challenging and only finally granted in 2013. Efficacy was not felt to be convincingly demonstrated due in part to the heterogeneity of MR in these studies. Approval in the USA has been limited to patients with degenerative MR that are considered to be too high risk for conventional mitral valve surgery [38]. Most of the commercial experience to date is thus from Europe and further experience has been obtained from the REALISM high risk registry (HRR) arm of the EVEREST II study [39]. These patients were of higher risk and had predominantly functional MR.

ACCESS-EU is a post-marketing registry of MitraClip patients. A retrospective evaluation of 567 patients in this registry was performed by Maisano *et al.* [40]. Several key differences in the real-world application of the MitraClip compared with those in the EVEREST II trial were found. These patients were more elderly and higher surgical risk candidates than those evaluated in the EVEREST II trial. More patients had functional MR and the anatomical characteristics of the mitral valve in 70–80% of these patients were outside the inclusion criteria stated in the EVEREST II trial [41]. In spite of this higher risk group of patients, positive clinical outcomes with the Clip were demonstrated at one year with improvements in the degree of MR, NYHA class, quality of life (QoL) and 6-minute walk test results. In a subgroup analysis of the EVEREST II trial, MitraClip was equivalent to surgery in older patients (≥ 70 years) and those with functional MR [35]. Outside the USA, at least in Europe, this is currently the group of patients most commonly receiving MitraClip repair.



Systematic reviews of MitraClip versus surgery confirm that whilst MitraClip is not as effective as surgery in reducing MR, it can provide clinical benefits. Munkholm-Larsen *et al.* identified MitraClip implantation as an option in managing selected high surgical risk patients with severe MR, but noted the lack of mid- to long-term data in high risk groups [42]. In a meta-analysis by Wan *et al.*, despite a higher risk profile in the MitraClip patients compared to surgical intervention, the clinical outcomes were similar although surgery was more effective in reducing MR in the early post procedure period [43].

Guidelines

The ESC guidelines for the diagnosis and treatment of heart failure 2012 [44] provide a class IIb (level of evidence C) indication for MitraClip in patients with both degenerative and functional MR in order to improve symptoms. Patients must be judged inoperable or at unacceptably high surgical risk and have a life expectancy of greater than one year. Controversy, however, exists particularly with respect to heart failure patients with FMR due to the limited data from the EVEREST II RCT [34] and extrapolation from uncontrolled registry data [45].

Patient selection

The complex nature of mitral valve disease and heterogeneity of the target population requires multidisciplinary expertise and careful patient selection in order to achieve optimal outcomes. A heart team comprised of a cardiac surgeon, heart failure specialist, echocardiologist and interventional cardiologist is critical to determining the most appropriate patients for intervention with MitraClip therapy.

Anatomical characteristics

The EVEREST trial included stringent anatomical criteria that focused on the middle, A2-P2, segment of the valve [35]. The European experience suggests technical feasibility in a more complex group of patients can be achieved with increasing experience [40]. There are, however, adverse anatomical features which signify less reliable and predictable outcomes. In particular, commissural pathology, bileaflet flail or bileaflet prolapse, lack of both primary and secondary chordal support and presence of calcification in the grasping zone present challenges for an effective MitraClip outcome.

Functional MR – an emerging indication?

The patient populations that are potentially treatable with MitraClip are diverse and quite distinct. Whilst indications for intervention for MR in primary or degenerative MR are well understood, and a role in the higher risk group may be recognised, the FMR group is more controversial and complex. MR in heart failure confers a worse prognosis [46-48] but it has not been clear whether MR is simply a marker of underlying left ventricular muscle disease, or a target for intervention.

The EVEREST II HRR [39] and ACCESS-EU [40] studies have supported the hypothesis that reducing MR can be beneficial, with improvements in NYHA functional class and quality of life. The MitraClip experience illustrates how technology can outpace data and influence clinical practice. A low risk minimally invasive procedure that affords symptom relief and reduces hospitalisations has potential not only to improve quality of life but reduce burden on health services. There have not been any clinical studies to date, however, directly comparing MitraClip to medical therapy in patients with heart failure and MR. Currently three such trials are underway, one in the USA (COAPT) [49], and three in Europe (RESHAPE-HF, MITRA-FR and MATTERHORN) [50-52] that are attempting to address this issue.

These prospective, randomised trials that compare heart failure patients treated with the MitraClip one-to-one with standard medical therapy will be of great importance in guiding MitraClip implantation in FMR. There is a paucity of data in surgical patients to support mitral valve surgery in FMR to improve symptoms over time or life expectancy [3]. The

results may therefore help address whether FMR can be improved, and provide clinical benefits, with mitral valve intervention of any kind. This discussion requires a nuanced approach when one considers the aims in patients with a prognosis often worse than many malignancies. This is the group that, at present, is largely being treated with MitraClip. If FMR can be improved, however, it will be important to evaluate the optimal impact point and timing of intervention. Studies that offer insight into whether the vicious circle of worsening LV remodelling and MR can be reversed or arrested with valve therapy through early intervention will be of great interest. Mitral valve repair or replacement for functional MR as a concomitant procedure when undergoing another open-heart surgery may also be more supported by a positive result in the randomised trials.

MitraClip in England

Although the technology has been commercially available in Europe since 2008, NHS England has only commissioned this technology in 2014 for evaluation. The Commissioning through Evaluation (CtE) programme is a new approach to the introduction of new technology in England. It supports a small number of procedures to be funded within a limited number of selected centres, and within a limited time-frame. This is linked to data collection for evidence on the relative clinical and cost effectiveness of the procedure. The percutaneous mitral valve leaflet repair for MR with MitraClip registry is managed by NICOR (National Institute for Cardiovascular Outcomes Research) and collects data on all procedures performed in the UK since the introduction of the technique. The National Institute for Health and Care Excellence (NICE) is supporting NHS England in the evaluation of the scheme.

Three centres in England have been selected to deliver this therapy: Royal Brompton and Harefield Hospitals, University Hospitals Bristol and the University Hospital of South Manchester NHS Trusts. They are currently commissioned to each treat 40 patients per year.

Summary

At present, surgery remains the gold standard for treatment of mitral regurgitation, and high surgical risk or inoperable patients are referred for consideration of MitraClip therapy. MitraClip would appear to offer a safe and effective percutaneous strategy for these patients. Detailed pre-procedural assessment is critical to achieving optimal outcomes. Systemic issues such as frailty, severe lung disease and multi-organ decline should be recognised as key limitations in achieving positive outcomes from any such intervention. An appreciation of patient selection factors, pathophysiology and technique will be vital to understanding non-response and improving application of this technology. Registry data have raised the potential of FMR being a target for intervention. Randomised clinical trials will be crucial to determining whether this expansion in indication is supported for mitral valve therapies of any kind. There may be a role for risk stratification tools to guide patient selection. The importance of timely intervention before an irreversible decline in LV remodelling and pulmonary hypertension ensues may focus attention on earlier intervention if safe and effective outcomes are shown to be durable beyond 5 years.

Percutaneous strategies presently limit repair options to a single point of intervention. Whilst the benefits of the Alfieri technique are realised in combination with an annuloplasty ring, MR reduction and clinical improvements are observed with MitraClip alone. This may reflect the advantages of the vertical coaptation produced with the MitraClip, much as with

the Alfieri repair. Nevertheless, longer follow-up of patients with residual grade 2+ MR will be important. Combination with percutaneous direct annuloplasty technologies might offer the potential to enhance long-term outcomes.

Conclusions

Transcatheter valve strategies herald dramatic advancements in device development. We are observing the beginning of an era of innovation before the full potential of such technologies is realised. The broadening of available options for MR should be welcomed. There is a clear patient preference towards, and clinical advantages to, minimally invasive approaches. Transcatheter mitral valve interventions should be viewed as complementary strategies to help achieve the goal of more safe and effective therapies for patients. Surgical repair will be the standard for many years, certainly in low risk DMR, and there are important lessons to be learned from the surgical experience. Responsible diffusion of technology by all stakeholders is crucial to preserving optimal outcomes for our patients. Randomised trials that challenge and enhance our understanding of new technologies are vital and will guide the risk-benefit analysis of different approaches. This will permit more tailored care according to an individual patient profile. Multidisciplinary and collaborative practice is essential to achieving optimal standard of care. The interface between structural interventionist and cardiac surgeon will thus only strengthen further as we organise ourselves with a more disease orientated approach to our work. We may see a niche area of cardiac surgery developing with hybrid skills in minimally invasive surgery and transcatheter interventions. This is an exciting time for all those involved in the field of valvular heart disease. The cardiac surgeon has a pivotal role in the management of MR and embracing a collaborative approach from the outset is essential to improving options for our patients and optimising long-term outcomes.

References

1. Nkomo VT, Gardin JM, Skelton TN, *et al.* Burden of valvular heart disease: a population-based study. *Lancet* 2006; 368:1005-11.
2. Jung B, Baron G, Butchart EG, *et al.* A prospective survey of patients with valvular heart disease in Europe: The Euro Heart Survey on Valvular Heart Disease. *Eur Heart J* 2003; 24:1231-43.
3. Nishimura RA, Otto CM, Bonow RO, *et al.* 2014 AHA/ACC guideline for the management of patients with valvular heart disease: a report of the American College of Cardiology/American Heart Association Task Force on practice guidelines. *Circulation* 2014;129(23): e521-e643.
4. Vahanian A, Alfieri O, Andreotti F, *et al.* Guidelines on the management of valvular heart disease (version 2012): The Joint Task Force on the Management of Valvular Heart Disease of the European Society of Cardiology (ESC) and the European Association for Cardio-Thoracic Surgery (EACTS). *Eur Heart J.* 2012 Oct. 33(19):2451-96.
5. Jokinen JJ, Hippelainen MJ, Pitkanen OA, *et al.* Mitral valve replacement versus repair: propensity-adjusted survival and quality-of-life analysis. *Ann Thorac Surg* 2007; 84:451-458.
6. Enriquez-Sarano M, Schaff HV, Orszulak TA, *et al.* Valve repair improves the outcome of surgery for mitral regurgitation: a multivariate analysis. *Circulation* 1995; 91: 1022-1028.
7. Horskotte D, Schulte HD, Bircks W, *et al.* The effect of chordal preservation on late outcome after mitral valve replacement: a randomized study. *J Heart Valve Dis* 1993; 2:150-8.
8. David TE, Uden DE, Strauss HD. The importance of the mitral apparatus in left ventricular function after correction of mitral regurgitation. *Circulation* 1983; 68(suppl II): II-176 – II-82.

9. De Bonis M, Lorusso R, Lapenna E, *et al.* Similar long-term results of mitral valve repair for anterior compared with posterior leaflet prolapsed. *J Thorac Cardiovasc Surg* 2006; 131: 364-370.
10. Gillinov AM, Cosgrove DM, Blackstone EH, *et al.* Durability of mitral valve repair for degenerative disease. *J Thorac Cardiovasc Surg* 1998; 116: 734-743.
11. Gillinov AM, Cosgrove DM. Mitral valve repair for degenerative disease. *J Heart Valve Dis* 2002;11; (Suppl 1): S15-S20.
12. Bolling SF, Pagani FD, Deeb GM, *et al.* Intermediate-Term Outcome of Mitral Reconstruction in Cardiomyopathy. *J Thorac Cardiovasc Surg* 1998 115:381-8.
13. Wu AH, Aaronson KD, Bolling SF, *et al.* Impact of Mitral Valve Annuloplasty on Mortality Risk in Patients with Mitral Regurgitation and Left Ventricular Systolic Dysfunction. *JACC* 2005; 45:381-7.
14. Lee AP, Acker M, Kubo SH, *et al.* Mechanisms of Recurrent Mitral Regurgitation After Mitral Valve Repair in Nonischemic Dilated Cardiomyopathy. *Circulation* 2009;119:2606-14.
15. McGee EC, Gillinov AM, Blackstone EH, *et al.* Recurrent mitral regurgitation after annuloplasty for functional ischemic mitral regurgitation. *J Thorac Cardiovasc Surg* 2004; 128: 916-924.
16. Mirabel M, Iung B, Baron G, *et al.* What are the characteristics of patients with severe, symptomatic, mitral regurgitation who are denied surgery? *Eur Heart J* 2007; 28:1358-1365.
17. O'Brien SM, Shahian DM, Filardo G, *et al.* The Society of Thoracic Surgeons 2008 cardiac surgery risk models: part 2—isolated valve surgery. *Ann Thorac Surg* 2009; 88(Suppl. 1): S23-S42.
18. Iung B, Baron G, Butchart EG, *et al.* A prospective survey of patients with valvular heart disease in Europe: The Euro Heart Survey on Valvular Heart Disease. *Eur Heart J.* 2003 Jul;24(13):1231-43.
19. Webb JG, Harken J, Munt BI, *et al.* Percutaneous transvenous mitral annuloplasty: initial human experience with device implantation in the coronary sinus. *Circulation* 2006; 113: 851-855.
20. Leon MB, Smith CR, Mack M, *et al.* PARTNER Trial Investigators. Transcatheter aortic-valve implantation for aortic stenosis in patients who cannot undergo surgery. *N Engl J Med* 2010; 363: 1597-1607.
21. Quill JL, Hill AJ, Laski TG, *et al.* "Mitral leaflet anatomy revisited," *Journal of Thoracic and Cardiovascular Surgery* 2009;137 (5):1077-1081.
22. Webb JG, Harken J, Munt BI, *et al.* Percutaneous transvenous mitral annuloplasty: initial human experience with device implantation in the coronary sinus. *Circulation* 2006; 113: 851-855.
23. Rogers JH, Maciak JA, Rader DA, *et al.* Percutaneous septal sinus shortening: A novel procedure for the treatment of functional mitral regurgitation. *Circulation* 2006; 113:2329-2334.
24. Liddicoat JR, Mac Neill BD, Gillinov AM, *et al.* Percutaneous mitral valve repair: A feasibility study in an ovine model of acute ischemic mitral regurgitation. *Catheter Cardiovasc Intern* 2003; 60:410-16.
25. Feldman T, Wasserman HS, Herrmann HC, *et al.* Percutaneous mitral valve repair using the edge-to-edge technique: six-month results of the EVEREST Phase I Clinical Trial. *J Am Coll Cardiol* 2005; 46: 2134-2140.
26. Grossi EA, Saunders PC, Woo J, *et al.* Intraoperative effects of the Coapsys annuloplasty system in a randomized evaluation (RESTOR-MV) of functional ischemic mitral regurgitation. *Ann Thorac Surg.* 2005;80: 1706-1711.
27. Pedersen WR, Block P, Feldman T. The iCoapsys repair system for the percutaneous treatment of functional mitral insufficiency. *Eurointervention.* 2006;1(suppl A): A44-A48.

28. MitraClip®. Percutaneous mitral valve repair. www.abbottvascular.com/us/mitraclip.html.
29. Alfieri O, Maisano F, De Bonis M, *et al.*: The double-orifice technique in mitral valve repair. A simple solution for complex problem. *J Thorac Cardiovasc Surg* 2001, 122:674–681.
30. De Bonis M1, Lapenna E, La Canna G, *et al.* Mitral valve repair for functional mitral regurgitation in end-stage dilated cardiomyopathy: role of the “edge-to-edge” technique. *Circulation*. 2005 Aug 30;112(9 Suppl): I402-8.
31. St Goar FG, Fann JI, Komtebedde J, *et al.* Endovascular edge-to-edge mitral valve repair: short-term results in a porcine model. *Circulation* 2003; 108:1990–1993.
32. Herrmann HC, Feldman T. Percutaneous mitral valve edge-to-edge repair with the Evalve Mitraclip system: rationale and phase I results. *EuroIntervention*. 2006;1(suppl A): A36 –A39.
33. Feldman T, Kar S, Rinaldi M, *et al.* Percutaneous mitral repair with the MitraClip system: safety and midterm durability in the initial EVEREST (Endovascular Valve Edge-to-Edge Repair Study) cohort. *J Am Coll Cardiol* 2009, 54:686–694.
34. Feldman T, Wasserman HS, Herrmann HC, *et al.* Percutaneous mitral valve repair using the edge-to-edge technique: six month results of the EVEREST Phase I Clinical Trial. *J Am Coll Cardiol* 2005; 46: 2134–2140.
35. Feldman T, Foster E, Glower DD, *et al.* Percutaneous repair or surgery for mitral regurgitation. *N Engl Med*. 364, 1395–1406 (2011).
36. Mauri L, Foster E, Glower DD, *et al.* 4-year results of a randomized controlled trial of percutaneous repair versus surgery for mitral regurgitation. *J. Am. Coll. Cardiol*. 62, 317–328 (2013).
37. Buzzatti N, Maisano F, Latib A, *et al.* Comparison of outcomes of percutaneous MitraClip versus surgical repair or replacement for degenerative mitral regurgitation in octogenarians. *Am J Cardiol*. 2015 Feb 15;115(4):487-92.
38. MitraClip® Delivery System – P100009. www.fda.gov/MedicalDevices/ProductsandMedicalProcedures/DeviceApprovalsandClearances/Recently-ApprovedDevices/ucm375149.htm.
39. Lim DS, Reynolds MR, Feldman T, *et al.* Improved functional status and quality of life in prohibitive surgical risk patients with degenerative mitral regurgitation following transcatheter mitral valve repair with the MitraClip System. *J. Am. Coll. Cardiol*. 2014; 64, 182–192.
40. Maisano F, Franzen O, Baldus S, *et al.* Percutaneous mitral valve interventions in the real world. Early and 1-year results from the ACCESS-EU, a prospective, multicenter, nonrandomized post-approval study of the MitraClip® therapy in Europe. *J. Am. Coll. Cardiol*. 2013; 62, 1052–1061.
41. Schillinger W, Athanasiou T, Weicken N, *et al.* Impact of the learning curve on outcomes after percutaneous mitral valve repair with MitraClip® and lessons learned after the first 75 consecutive patients. *Eur. J. Heart Fail*. 2011; 13, 1331–1339.
42. Munkholm-Larsen S, Wan B, Tian DH, *et al.* A systematic review on the safety and efficacy of percutaneous edge-to-edge mitral valve repair with the MitraClip system for high surgical risk candidates. *Heart*. 2014 Mar; 100(6):473-8.
43. Wan B, Rahnavardi M, Tian DH, *et al.* A meta-analysis of MitraClip system versus surgery for treatment of severe mitral regurgitation. *Ann Cardiothorac Surg*. 2013 Nov; 2(6):683-92.
44. The Task Force for the Diagnosis and Treatment of Acute and Chronic Heart Failure 2012 of the European Society of Cardiology. Developed in collaboration with the Heart Failure Association (HFA) of the ESC. *Eur Heart J* 2012; 33:1787–847.
45. Coats AJ, Shewan LG. Inconsistencies in the development of the ESC Clinical Practice Guidelines for Heart Failure. *Int J Cardiol*. 2013;168(3):1724-7.

46. Junker A, Thayssen P, Nielsen B, *et al.* The hemodynamic and prognostic significance of Echo-Doppler-proven mitral regurgitation in patients with dilated cardiomyopathy. *Cardiology* 1993; 83:14-20.
47. Conti JB, Mills RM Jr. Mitral regurgitation and death while awaiting cardiac transplantation. *Am J Cardiol* 1993; 71:617-8.
48. Blondheim DS, Jacobs LE, Kotler MN, *et al.* Dilated cardiomyopathy with mitral regurgitation: decreased survival despite a low frequency of left ventricular thrombus. *Am Heart J* 1991; 122:763-71.
49. Cardiovascular Outcomes Assessment of the MitraClip Percutaneous Therapy for High Surgical Risk Patients (COAPT). <http://www.clinicaltrials.gov/ct2/show/NCT01626079>
50. A Randomised Study of the MitraClip Device in Heart Failure Patients with Clinically Significant Mitral Regurgitation (RESHAPE-HF). <http://www.clinicaltrials.gov/ct2/show/NCT01772108>.
51. Multicentre Study of Percutaneous Mitral Valve Repair MitraClip Device in Patients with Severe Secondary Mitral Regurgitation (MITRA-FR). <http://www.clinicaltrials.gov/ct2/show/NCT01920698>.
52. A Multicenter, Randomized, Controlled Study to Assess Mitral vAlve reconsTrucTion for advancEd Insufficiency of Functional or iscHemic ORigin (MATTERHORN). <http://www.clinicaltrials.gov/ct2/show/NCT02371512>.

Minimally Invasive Aortic Valve Surgery

“I will not listen to reason Reason, always means what someone else has got to say”

Elizabeth Clegham Stevenson, Dame Gaskell (1810 - 1865)

Chapter 7

The Anterior Thoracotomy Approach for Aortic Valve Replacement:

Tips, Tricks and Our Technique.

Antonio Miceli, Antonio Lio and Mattia Glauber

“One faultless sonnet is worth a long poem”

Introduction

The term “Minimally invasive aortic valve replacement” (MIAVR) refers to a small chest wall incision that does not include standard median sternotomy [1]. In the last few years, MIAVR has gained popularity

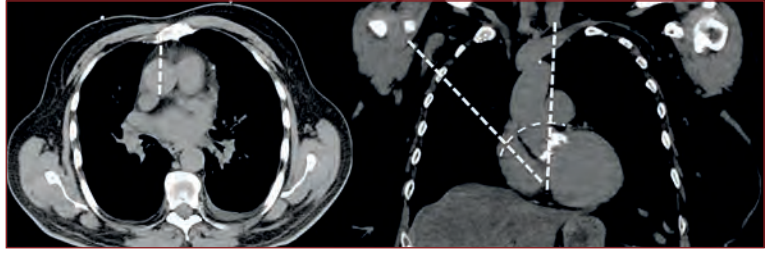


Fig 1: CT criteria for right minithoracotomy approach

amongst surgeons and now has become a valid alternative to the standard sternotomy [2]. Compared with conventional surgery, MIAVR has been shown to reduce postoperative morbidity, providing better cosmetic results, shorter hospital stays and faster recovery [3-5]. The most common MIAVR approach is the upper hemisternotomy, followed by the right anterior minithoracotomy approach (RT). Recently, we reported our experience with MIAVR through a RT and showed excellent mortality, morbidity and patients satisfaction [6-7]. Our RT program started in 2004 and now, after the introduction of sutureless valves, it has become our first-line approach for patients with aortic valve disease.

Preoperative planning and exclusion criteria

All patients undergoing an isolated aortic valve procedure undergo imaging with a non-contrast computed tomography (CT) scan. It is important that during this, the patient's arms are adducted, recreating the normal patient position on the operating table. Images are viewed in the coronal and sagittal planes and then a 3D reconstruction is performed to evaluate the relationship between the intercostal spaces, ribs, sternum, ascending aorta and aortic valve. Areas of aortic calcification are recognised to identify the correct location for aortic cannulation. Patients are candidates for a RT approach if:

- at the level of pulmonary artery, the ascending aorta is rightward (more than half is located to the right of the right sternal border) (Figure 1, left panel),
- the distance from the ascending aorta to the sternum does not exceed 10 cm,
- the angle between the ascending aorta and the patient's midline should be more than 45° (Figure 1, right panel).

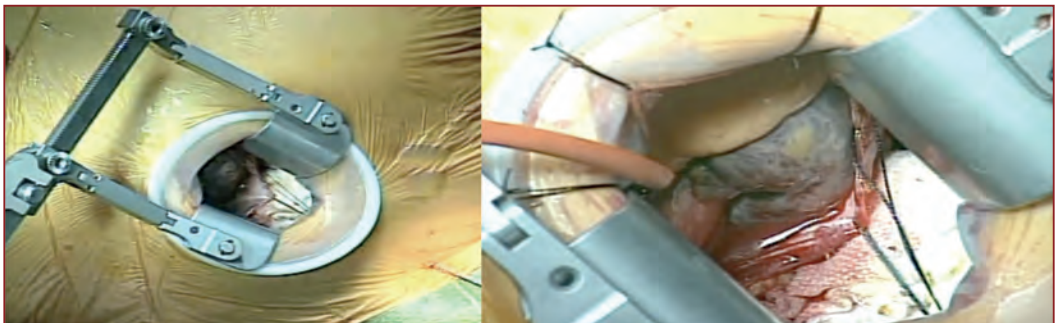


Fig 2: Operative exposure.

If these criteria are not met, the patient is not suitable for a RT approach and undergoes a ministernotomy. Other exclusion criteria are previous right sided chest surgery, a history of right-sided pleuritis (due to the risk of adhesions), severe chest wall malformation, severe pulmonary bullous disease and the presence of an ascending aortic aneurysm.

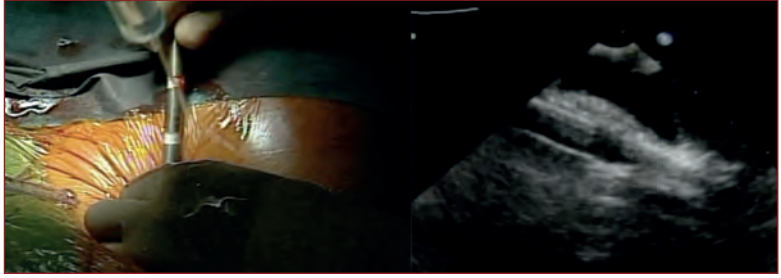


Fig 3: Percutaneous femoral venous cannulation

Surgical technique and valve implantation

Anaesthesia is provided according the standard protocol for conventional aortic valve replacement. The patient is positioned in a supine position and two defibrillator pads are placed across the chest wall. A single lumen endotracheal tube and a right internal jugular central venous catheter are used.

A right anterior minithoracotomy is performed through a 5-7 cm incision at the level of the second intercostal space starting at the right border of sternum. The right internal mammary artery (RIMA) is often sacrificed in order to achieve better valve exposure and avoid bleeding from tearing of the pedicle. A soft tissue retractor is inserted into the thoracotomy and a rib retractor is used to spread the intercostal space. Once the lungs are deflated, the phrenic nerve is identified and the thymus is excised up to the left brachiocephalic vein. The pericardium is opened 4-5 cm anterior to the phrenic nerve immediately adjacent to the ascending aorta and pericardial stay sutures are placed on the right pericardial edge in order to optimise exposure of the aorta and identify the right upper pulmonary vein for LV vent insertion (Figure 2).

The ascending aorta is exposed and two concentric purse strings are positioned just below the level of the left brachiocephalic vein at the level of the pericardial reflection. Heparin is then administered and percutaneous femoral venous cannulation using a Seldinger technique and TOE guidance is performed prior to aortic cannulation, positioning the tip of the cannula in the SVC (Figure 3).




Fig 4: Aortic cannulation and clamping using a Glauber clamp.

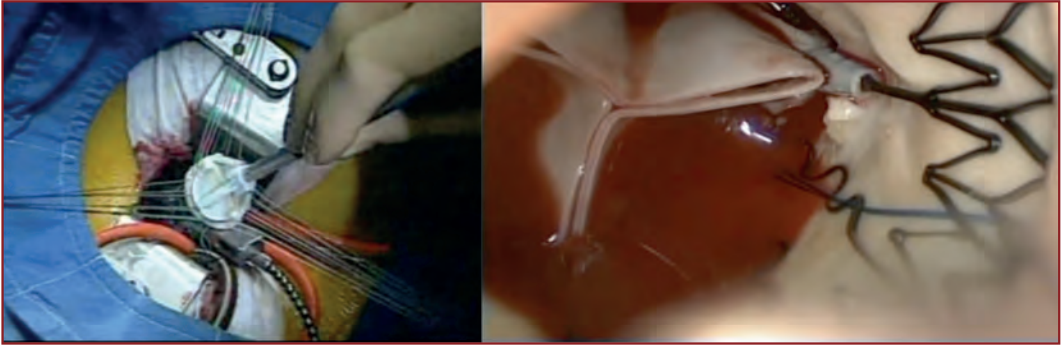


Fig 5: Valve implantation (sutured, left panel; sutureless, right panel)

Direct aortic cannulation is then performed and cardiopulmonary bypass (CPB) with vacuum-assisted drainage (-40 to -60 mmHg) is established and a left ventricular vent is inserted through the right upper pulmonary vein. A vent/cardioplegia line is positioned into the ascending aorta and the aorta is clamped using a minimally invasive detachable clamp (Glauber clamp, Sorin, Saluggia, Italy) (Figure 4). Antegrade cardioplegia is administered into the aortic root (or later selectively into the coronary ostia in the presence of aortic incompetence). Once the heart is arrested, the aortotomy is performed and the operative field is flooded with CO₂ at a flow of 0.5 l/min. The aortotomy is performed differently depending on the type of prosthesis used, i.e. sutured or sutureless.

Sutured valve

The aortotomy is performed in either a transverse or oblique fashion, in exactly same way as for a median sternotomy. Our philosophy is to reproduce all the surgical steps we usually perform through a full sternotomy in order to make the procedure reproducible. The diseased valve is analysed and the three calcified leaflets are excised. Decalcification of the aortic annulus is performed taking care not to injure the aortomitral continuity. It is recommended to use shafted minimally invasive instruments. Three sutures are placed at the level of the commissures in order to expose the aortic annulus. Once the annulus is sized, sutures are passed through the aortic annulus in the following order to position the valve in the supra-annular position: left coronary, non-coronary and right coronary sinus. This sequence is because the right coronary sinus is more difficult to expose and we recommend placing the sutures after exposing the annulus. Once the sutures are passed through the prosthesis, the valve is parachuted down into position (Figure 5, left panel). We advise not to tie the sutures with a knot pusher as digital tactile feedback is very important to control the tension in the knots. The valve is inspected for areas of potential paravalvular leakage and then the aortotomy is closed using a continuous 4-0 polypropylene suture.

Sutureless Perceval S valves (Sorin Group, Saluggia, Italy)

A transverse aortotomy is performed approximately 2-3 cm higher than a conventional aortotomy. The reference point is the inferior margin of the Concato preaortic bundle. Similar to the implantation of a sutured valve, the native diseased valve is excised and the annulus is decalcified. This is a key point for the implantation of a sutureless valve as an incomplete decalcification may be responsible for paravalvular leakage and central aortic regurgitation due to leaflet malcoaptation. Three guiding 4-0 polypropylene sutures on an RB-1 needle are placed below the nadir of each sinus to act as reference points for

accurate alignment of the inflow portion of the prosthesis into the aortic annulus. The sutures are placed in the following order: right coronary sinus, non-coronary sinus and the left coronary sinus. The aortic annulus is then sized using dedicated valve sizers. The valve sizer is designed so that the intra-annular head of the sizer (yellow) has the same external diameter as the supra-annular head of the smaller sizer. The valve is collapsed and is then parachuted down into the aortic annulus using the three guiding sutures which are connected to the prosthesis through three holes in the mid-part of the inflow ring. Once the valve is deployed, it is correctly positioned if the inflow ring of the valve covers the whole annulus and the coaptation of the three new leaflets replicates the Mercedes-Benz sign (Figure 5, right panel). The three guiding sutures are removed and the aortotomy is closed. The patient is weaned from cardiopulmonary bypass and TOE is used to assess for paravalvular regurgitation. The aortic cannula is removed, the patient is transfused using the venous cannula and, after protamine administration, the venous cannula is removed.

Comments

Minimally invasive AVR (MIAVR) through a right anterior minithoracotomy is safe and associated with low mortality and morbidity, high patient satisfaction, and offers more rapid recovery and shorter hospital stay compared to a median sternotomy. We described our first experience in late 2011, reporting 192 consecutive patients who underwent isolated MIAVR through a RT from January 2005 and June 2010 using stented valves [6]. Overall mortality was 1.6% and the rate of conversion to sternotomy was 1.6%. Interestingly, although the cross-clamp and cardiopulmonary bypass times were longer than in the standard approach, the incidence of postoperative atrial fibrillation and blood transfusion were 18% and 16%, respectively. The median length of stay was 5 days and 90% of patients were discharged home. Finally, 96% of patients believed they had an aesthetically pleasing scar and 95% were back to their normal activities within 4 weeks. These outcomes were demonstrated in our data comparing patients undergoing a RT-AVR to those having a median sternotomy or hemisternotomy [8, 9].

The longer operative times suggest that this is more challenging than the conventional approach. However, the use of sutureless devices (since April 2011) has facilitated this approach, reducing the operative times by 40% [10-12]. As a consequence of the introduction of sutureless devices, the number of MIAVR performed through a RT in our institution have increased in the last 4 years [7]. In a ten-year experience, we have implanted 291 sutured and 302 sutureless valves, providing excellent postoperative outcomes especially in high risk patients [7,10]. In light of these outstanding results, we believe that MIAVR via RT with a sutureless prosthesis may be considered as an “alternative” to transcatheter aortic valve implantation (TAVI) for high-risk patients judged to be still operable by the Heart Team. We have recently demonstrated that high-risk patients undergoing MIAVR through a RT using sutureless valves are associated with a trend to better early outcomes and mid-term survival than TAVI [13]. Specifically, in a small but matched population, the in-hospital mortality was 8.1% in the TAVI group and 0% in the RT group ($p=0.25$), and stroke occurred in 5.4% versus 0% in the TAVI and RT groups respectively ($p = 0.3$). In the TAVI group, 37.8% and 27% had mild and moderate paravalvular regurgitation (PVR), whereas 2.7% had mild PVR in the RT group ($p < 0.001$). Finally, one- and two-year survival rates were 91.6% vs 78.6% and 91.6% vs 66.2% in patients undergoing RT with the Perceval S sutureless valve compared to those undergoing TAVI, respectively ($p=0.1$). Despite these interesting results, a prospective randomized trial with a larger sample size is required to confirm our data.

Conclusions

Minimally invasive aortic valve replacement is safe with low perioperative morbidity and good long-term survival. Sutureless prostheses facilitate the minimally invasive approach and reduce the operative times. The combination of a sutureless valve and a MIAVR approach might be the realistic alternative to a TAVI procedure in the treatment of high-risk patients with severe aortic valve stenosis and be associated with better outcomes.

References

1. Rosengart TK, Feldman T, Borger MA, *et al.* Percutaneous and minimally invasive valve procedure: a scientific statement from the American Heart Association council on cardiovascular surgery and anaesthesia, council on clinical cardiology, functional genomics and translational biology interdisciplinary working group, and quality of care and outcomes research interdisciplinary working group. *Circulation*. 2008; 117:1750-67.
2. Schitto JS, Mokashi SA, Cohn LH. Minimally invasive valve surgery. *J Am Col Cardiol* 2010; 56:455-62.
3. Brown ML, McKellar SH, Sundt TM, *et al.* Ministernotomy versus conventional sternotomy for aortic valve replacement: a systematic review and meta-analysis. *J Thorac Cardiovascular Surg*. 2009; 137:670-9.
4. Murtuza B, Pepper JR, Stanbridge RD, *et al.* Minimal access aortic valve replacement: is it worth it? *Ann Thorac Surg*. 2008; 85:1121-31.
5. Gilmanov D, Bevilacqua S, Murzi M, *et al.* Minimally invasive and conventional aortic valve replacement: a propensity score analysis. *Ann Thorac Surg* 2013; 96:873-43.
6. Glauber M, Miceli A, Bevilacqua S, *et al.* Minimally invasive aortic valve replacement via right anterior minithoracotomy: early and midterm follow-up. *J Thorac Cardiovasc Surg* 2011; 142:1577-9.
7. Glauber M, Gilmanov D, Farneti PA, *et al.* Right anterior minithoracotomy for aortic valve replacement: 10-year experience of a single center. *J Thorac Cardiovasc Surg* 2015; 150:548-56.
8. Glauber M, Miceli A, Gilmanov D, *et al.* Right anterior minithoracotomy versus conventional aortic valve replacement: a propensity score matched study. *J Thoracic Cardiovasc Surg* 2013; 145:1222-6.
9. Miceli A, Murzi M, Gilmanov D, *et al.* Minimally invasive aortic valve replacement using right minithoracotomy is associated with better outcomes than ministernotomy. *J Thoracic Cardiovasc Surg* 2014; 148:133-7.
10. Miceli A, Santarpino G, Pfeiffer S, *et al.* minimally invasive aortic valve replacement with Perceval S sutureless valve: early outcomes and one-year survival from two European centers. *J Thoracic Cardiovasc Surg* 2014; 148:2838-43.
11. Gilmanov D, Miceli A, Bvilacqua S, *et al.* sutureless implantation of the Perceval S aortic valve prosthesis through right anterior minithoracotomy. *Ann Thorac Surg* 2013; 96:2101-8.
12. Gilmanov D, Miceli A, Ferrarini M, *et al.* Aortic valve replacement through right anterior minithoracotomy: can sutureless technology improve clinical outcomes? *Ann Thorac Surg* 2014;98:1585-92.
13. Miceli A, Gilmanov D, Murzi M, *et al.* Minimally invasive aortic valve replacement with a sutureless valve through a right anterior minithoracotomy versus transcatheter aortic valve implantation in high risk patients. *Eur J Cardiothorac Surg*. 2015 Jun 25. pii: ezv210. [Epub ahead of print].

Chapter 8

Sutureless Valves and Minimal Access Surgery

Stefan Pfeiffer and Giuseppe Santarpino

“Who needs fire takes it with his own hands”

Introduction

Guidelines published by the Joint Task Force on the Management of Valvular Heart Disease of the European Society of Cardiology (ESC) and the European Association for Cardio-Thoracic Surgery (EACTS) in 2012 recommend that aortic valve replacement (AVR) is the main treatment option for aortic stenosis [1]. Surgical AVR has a perioperative mortality of approximately 1-3% in patients younger than 70 years undergoing isolated AVR, increasing to 4-8% when combined with coronary artery bypass grafting [1]. However, not all patients are suitable for surgery, with several factors affecting a patient's suitability for surgery. In a 2005 European Heart Survey on valvular heart disease, surgery was denied in 33% of elderly patients with severe, symptomatic AS [2]. Older age, LV impairment and neurological dysfunction were the most striking characteristics of patients who were denied surgery.

Although AVR is considered the only curative treatment known to improve symptoms and survival in patients with severe symptomatic aortic stenosis, perioperative mortality increases among high-risk patients (due to older age and comorbidities). Transcatheter aortic valve implantation (TAVI) is an emerging, catheter-based technology that allows for implantation of a prosthetic valve without open-heart surgery and without removing the diseased valve [2]. TAVI is currently reserved for patients considered inoperable or very high risk for conventional AVR surgery. This is due in part to the complications which can follow a TAVI procedure.

There is a growing interest in minimally invasive access for aortic valve surgery, which reduces surgical trauma and pain to the patient and potentially allows a faster recovery [3]. The upper hemi-sternotomy provides good aortic valve exposure, with numerous possible advantages. Nevertheless, some surgeons remain sceptical about limited-access surgery because it is technically more demanding. In this regard, the recently published study of Semsroth *et al.* is of great interest [4]. They described the historical evolution of the surgical technique used at their institution. Surgical access for AVR was initially achieved through a median sternotomy, later abandoned in favour of a right anterolateral minithoracotomy (RT) and then again changed to partial upper hemisternotomy (HS). The RT technique was found to be associated with more perioperative adverse events, whereas the HS approach proved an excellent surgical approach to be considered by every staff surgeon in the daily routine.

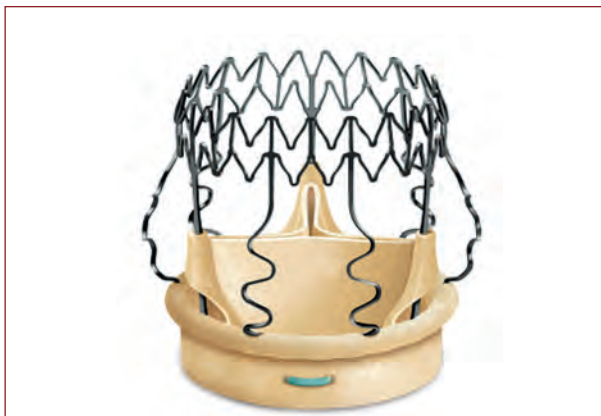

Fig 1: Perceval Valve (Sorin Group, Saluggia, Italy).

We strongly agree with these observations; the authors of the study have expertise with the three techniques that were used by all staff surgeons and their findings were derived from a multi-surgeon experience. As surgeons, we have to deliver a procedure which is as safe as possible as an alternative to TAVI. If a technique is limited by ischemic times significantly longer than those of HS along with the risk of more complications, even in the most experienced hands, then it is in our opinion not suited to challenge TAVI.

In addition, can RT be safely performed by any surgeon? After a few cases, Semsroth *et al.* had to change their technique and retrograde perfusion via femoral artery cannulation was established as a routine. Different from the HS approach, a groin incision is required for femoral access when the RT technique is adopted which may result in access site complications. Are small thoracic and groin incisions any less invasive than a small sternal midline incision?

We deem these considerations necessary in order to compete with current interventional approaches; cardiac surgery should evolve towards more physiological techniques (e.g., antegrade arterial perfusion) that are easier (e.g. incision and cannulation as for full sternotomy) and faster to perform (e.g. use of sutureless aortic bioprostheses) [5]. The achievement of these goals would counterbalance the need for cardiopulmonary bypass, which represents a major disadvantage in the cardiologist's opinion.

Sutureless Solutions in AVR

The sutureless or rapid deployment aortic valve is a stent-mounted aortic valve prosthesis that can be placed in a sutureless fashion with a conventional surgical technique [6]. This technology includes application of cardiopulmonary bypass, cross-clamping of the aorta and an aortotomy, allowing complete removal of the diseased native valve. However, sutureless implantation of heart valves has a significant advantage over the classic technique of suturing the valve in place because it shortens the aortic cross-clamp time.

Until May 2015, there were three sutureless bioprostheses on the market. Two (3f Enable, Medtronic Inc., Minneapolis, Minnesota, USA, and Perceval, Sorin Group, Saluggia, Italy) are characterized by being based on stentless tissue valves, and the third one (INTUITY, Edwards Lifesciences, Irvine, California, USA) being a sutureless stented bioprosthesis. As of that date, Medtronic withdrew their product from the market due to "... limited commercial adoption ..." as stated in an urgent field safety notice dated May 8th, 2015.

The Perceval sutureless valve is a bioprosthetic valve manufactured from bovine pericardium (Figure 1, Table 1). It is based on Sorin's stentless Freedom Solo valve mounted in a Nickel-Titanium (Ni-Ti) alloy frame. The stent fits the anatomy of the aortic root and follows its movement during the entire cardiac cycle. It is designed to distribute the stresses in order to minimize the risk of damage to the aortic root. No sutures are required to fix the valve in place. This potentially reduces the risk of damage to the aorta, reduces the operation time and facilitates faster recovery [7]. Before implantation, the valve is collapsed onto a dedicated holder (Figure 2). It is deployed in two steps after positioning the device intra-annularly with the aid of guiding sutures. The reduced diameter enhances visibility and control for the surgeon during implantation. The valve can be removed during each step of the implantation, although this is not recommended by the company.

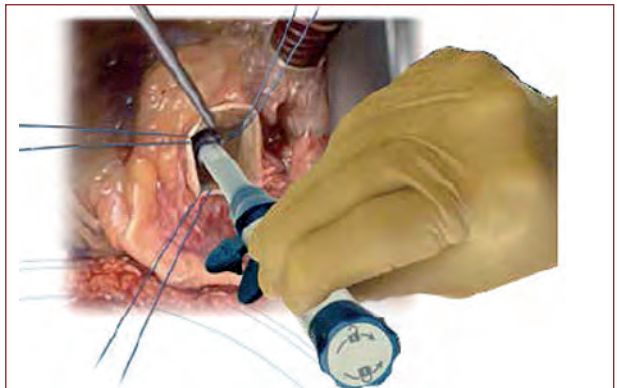


Fig 2: Perceval implantation: Valve profile is reduced by means of a collapsing procedure to facilitate the positioning

Intuity Valve (Edwards Lifesciences, Irvine, CA., USA)

The Intuity and Intuity Elite (second generation) rapid deployment devices (Figure 3) are based on the stented Perimount Magna Ease bioprosthesis (Table 1). They are manufactured from bovine pericardium mounted on a cobalt-chromium alloy stent. The device is anchored in the annulus by a balloon expandable, stainless steel stent, which is expanded with a balloon during implantation. Once deployed, it can only be removed by destroying the steel skirt, which means the device is not reusable. Once the prosthesis has been positioned with the aid of three guiding sutures, the balloon is inflated to dilate the stent in the annulus. The three guiding sutures have to be left in place and tied according to the manufacturer.

Outcomes following the use of the Perceval valve

The published literature with sutureless devices, although limited, is encouraging. Shrestha *et al.* [7] were the first to evaluate the feasibility of implantation of the Perceval S valve and report their outcomes. Between April and September 2007, 16 high-risk patients (13 females, median age 81 years, interquartile range 76-88 years) were operated on via a median sternotomy, using cardiopulmonary bypass (CPB) and cardioplegia (EuroSCORE 17). All patients had significant aortic valve disease and seven of these patients had concomitant coronary artery disease. Cardiopulmonary bypass time was 60 (41-130) minutes and aortic cross-clamp time was 36 (22-79) minutes. Intraoperative as well as postoperative echocardiography revealed neither aortic insufficiency nor paravalvular leakage in any of the patients. One patient died during their hospital stay for unknown reasons. Autopsy revealed no valve-related pathologies. This feasibility study validated that sutureless valve replacement was a technically simple alternative to conventional AVR in high-risk patients and offered the potential of a less invasive approach. It appeared especially useful in patients with severe calcification of the aortic root. Cardiopulmonary bypass and cross-clamp times were markedly reduced compared with patients who underwent conventional operations.

The Perceval valve was implanted in a multicentre trial of 30 consecutive high-risk patients [8]. One patient died of sudden cardiac death in hospital; however, no valvular pathology was detected. Follow-up mortality at 12 months was 10%. For isolated AVR, mean CPB and aortic cross-clamp times were 46.4 and 29 minutes, respectively. At 12-month follow-up, mild PVL was detected in two patients and NYHA classes I and II were observed in 57% and 39%, respectively.

Flameng *et al.* conducted a prospective study of 32 high-risk patients undergoing sutureless AVR [6]. They reported no operative

Table 1: Characteristics of Perceval and Intuity

	Perceval	Intuity
Annular sizes covered (mm)	S (19-21), M (21-23),	19,21,23,25,27
Tissue type	Bovine pericardium	Bovine pericardium
Anti-calcification	Yes	Yes
Tissue fixation	Glutaraldehyde	Glutaraldehyde
Frame material	Superelastic Ni-Ti stent	Cobalt-chromium alloy, stainless steel skirt
Permanent sutures	0	3
CE mark	2011	2012

S, small; M, medium; L, large; XL, extra-large; Ni-Ti, nickel-titanium

mortality and three deaths during follow-up, all of non-cardiac causes. In isolated AVR, the median CPB time was 35 minutes and the median aortic cross-clamp time was 17 minutes. Postoperative complications included prosthetic valve endocarditis requiring reoperation in one patient, atrioventricular block requiring permanent pacemaker in one patient, temporary renal support in one patient and re-exploration for bleeding in one patient. Mild PVL was observed in 16% both at discharge and at 6-month follow-up, and in 6% at 12-month follow-up. Moderate PVL was observed in only 3% at 6-month follow-up. Mean and peak pressure gradients were 11 and 22 mmHg at discharge, 10 and 18 mmHg at 6 months, and 9 and 19 mmHg at 12 months, respectively. NYHA classes I and II were both observed in 48% at 12-month follow-up.

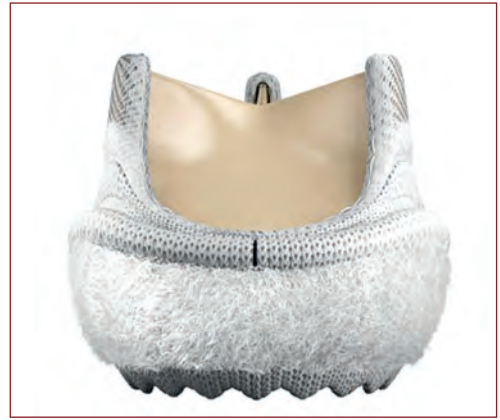

Fig 3: Intuity, Edwards Lifesciences Inc., Irvine, CA., USA.

Folliguet *et al.* have recently published their experience of sutureless AVR with the Perceval valve in 208 high-risk patients operated on in two different institutions and with the longest follow-up of 4 years [9]. In this series, conventional and minimally invasive approaches were used to implant the sutureless prosthesis, and compared. This series included isolated sutureless AVR or sutureless AVR along with coronary artery bypass grafting. Their findings indicate that mean aortic cross-clamp time was around 33 minutes, with a mean total CPB time ranging from 50 to 67 minutes depending on the type of surgical approach or procedure performed. In-hospital mortality was 2.4% (n=5). No displacement of the valves was found during follow-up. Pacemaker implantation was required in 7% of the patients (n=16). Nine patients experienced immediate PVL, which, in two cases, required the implantation of a stented prosthesis. During follow-up, nine patients (4%) showed PVL which required reoperation (seven early and two late, one due to acute endocarditis). Minor PVL not requiring reoperation was found in five patients. No increase in aortic insufficiency was recorded during follow-up. Mean aortic gradient was 10.4 mmHg and mean effective orifice area was 1.4 cm².

Our group has recently published 1-year follow-up of a single centre experience of 83 patients who received the Perceval valve as part of a pre-marketing multicentre study (Cavalier Trial) [3,10]. The patients received a size Small (n=4), Medium (n=38), or Large (n=41) prosthesis, either as isolated (n=57) or combined procedures (n=26). Mean logistic EuroSCORE was $10 \pm 7.5\%$ and mean aortic cross-clamp time was 43.8 ± 20.8 minutes (36 ± 12.7 minutes for isolated procedures). Mean implantation time was 8 ± 3.8 minutes (range 4-28 minutes). In-hospital mortality was 2.4% (one patient died of multi-organ failure and one of hepatic failure); mean hospital stay was 11.5 ± 4.4 days (range 2-28 days). We recorded five pacemaker implantations (6%). At follow-up, we had two deaths (one patient with congestive cardiac failure and one of gastrointestinal bleeding). At 1 year, mean NYHA functional class was 1.0 ± 0.6 . Mean trans-prosthetic gradients were 13.4 ± 2.8 mmHg (immediately post-op), 12.6 ± 2.3 mmHg (6 months), and 10.8 ± 1.3 mmHg (12 months) postoperatively. This study validated the safety and efficacy of the Perceval valve.

The largest Perceval series is the Cavalier trial, which is a prospective, non-randomized trial with 25 European centers involved [11,12]. More than 700 patients were closely followed up to 5 years (mean follow up 1 year). Overall morbidity and mortality were very favourable and the device offered very good hemodynamic performance throughout the time followed with no signs of structural valve deterioration. In a cohort where 43.1% of patients were older than 80 years, early all-cause mortality rate was 3.4% and 1.6 % of patients suffered a stroke. The occurrence of a major paravalvular leak was 1.4 % and 1.4 % of implants had to be removed early which was classified as the early learning curve. No case of valve thrombosis or late valve migration were reported. The overall occurrence of new third degree atrioventricular block was 6% but different in different centers. The percentage of patients needing a permanent pacemaker (PPM) was higher (11.6%), but 4.9% had pre-existing cardiac rhythm disturbances predisposing to the need for postoperative PPM implantation.

Outcomes following the use of the Intuity valve

The Triton study is the largest report of patients receiving the Intuity valve [13]. It was implanted successfully in 146 patients (implantation success 96.1%) in 6 participating European centres. Aortic cross-clamp time was 41.1 ± 10.6 minutes and shorter compared to traditional implants. After 3 months and 1 year, mean transvalvular gradients were 8.8 ± 3.0 mmHg and 8.4 ± 3.4 mmHg with an effective orifice area of 1.7 ± 0.2 cm² and 1.7 ± 0.2 cm², respectively. The paravalvular leak rate > 1+ was 0.9% (n=1) at late follow up. A total of 10 patients needed early PPM implantation and 7 (5%) were adjudicated as study valve-related. The surgical access in this study was full sternotomy (69.9%), hemi sternotomy (29.5%) and right anterior thoracotomy (RT) (0.7%).

In 2014, Haverich *et al.* [14] reported a total of 287 Triton patients followed up to 3 years (mean follow up 1.8 ± 0.9 years) with continuously stable performance of the device. The effective orifice area remained stable with significantly decreased pressure gradients (9.0 ± 3.4 vs. 8.7 ± 4.1 mmHg, 3 months vs 3 years, respectively, $p < 0.0001$) and left ventricular mass indices (16% reduction at 3 years compared to discharge, $p < 0.0001$) indicating reverse remodelling of the left ventricle.

Data from the subsequent Foundation trial, a real world single arm study initiated to prospectively follow patients after Intuity implantation, have not yet been published. More than 540 patients have been enrolled in this trial and a comparison of three access routes (full sternotomy, partial sternotomy and right anterior thoracotomy) was presented at the 2015 annual meeting of the ISMICS (International Society for Minimally Invasive Cardiothoracic Surgery) in Berlin. The authors found that aortic cross-clamp and CPB times in full sternotomy (47 min, 67 min) were shorter than with partial sternotomy (51 min, 79 min) and RT (73 min, 104 min). There were no significant differences in clinical outcomes and morbidities comparing the three access routes. During the study, the adoption of minimally invasive access was 49.6% and exceeded the numbers reported in the German Registry for Aortic Valve Surgery (GARY) (2013: 23%, 2010: 10%). They concluded that the use of a rapid deployment device mitigated the differences in cross-clamp and CPB times between sternotomy and MICS.



Minimally invasive surgery and sutureless valves

An attractive indication for sutureless AVR is its use in combination with minimally invasive surgery (MIS). During MIS, the reduction in the working space for the passage of prosthetic sutures can be technically challenging and this issue can be easily addressed with the use of a sutureless prosthesis. In patients with a critically small annulus, the valve allows maximization of the bioprosthetic diameter. In addition, it may reduce the rate of paravalvular leakage, which is commonly related to suboptimal suturing of the bioprosthesis sewing ring in this clinical setting. We have recently reported outcomes for Perceval implantation through a minimally invasive approach where, between March 2010 and December 2011, 51 patients received a Perceval bioprosthesis through a 'J' sternotomy [15].

Most of the currently available data regarding the use of sutureless valves combined with MIS are based on observational studies. There is one small prospective randomized series comparing upper hemisternotomy combined with rapid deployment valve implantation (RDAVR) and full sternotomy combined with traditional AVR (FS-AVR) [16]. Despite the minimal access, RDAVR had shorter cross-clamp times (41.3 ± 20.3 minutes vs. 54.0 ± 20.3 minutes). The RDAVR patients had lower mean transvalvular pressure gradients (8.5 mmHg vs. 10.3 mmHg) and were less prone to have patient-prosthesis mismatch (0 vs 15%). Nevertheless, this did not result in better early clinical outcomes for the minimally invasive treated patients. The authors concluded that rapid deployment valves facilitate the performance of MIS-AVR.

In a recently published literature review about sutureless valves, Phan *et al.* identified 12 studies which were eligible for further analysis (7 Perceval, 3 Enable, 1 Intuity, 1 other) [17]. All studies showed a dramatic drop in cross-clamp and CPB times, which are independent risk factors for perioperative morbidity and mortality [18]. A subgroup analysis revealed that cross-clamp times in minimal access surgery were comparable to full sternotomy and concluded that sutureless valves facilitate MIS-AVR. All studies proved that sutureless devices, although mainly followed for the short term, were very favourable with regards to hemodynamic performance. These findings were comparable with the ones from the Cavalier trial [12]. For isolated AVR, CPB and cross-clamp times were 50.8 ± 19.5 minutes and 30.8 ± 10.8 minutes in full sternotomy, and 64.4 ± 19.2 minutes and 37.6 ± 12.0 minutes for MIS AVR, respectively, but not statistically compared. Longer term follow-up after partial J-sternotomy showed good clinical outcomes and function of the Perceval valve [19]. Survival rates remained high (96%) and the quality-of-life was improved in a large percentage of patients in this study suggesting no disadvantage of the MIS approach for sutureless valves.

Comparison between different available devices

There are currently no studies with direct comparisons of the three commercially available sutureless aortic valves. For the purpose of comparison, we chose the three largest studies reporting outcomes for Perceval [9], 3f ENABLE (Medtronic Inc., Minneapolis, Minnesota, USA) [20], and INTUITY (Edwards Lifesciences, Irvine, CA, USA) [13]. Using the reported outcomes from these three studies, they can be interpreted that Perceval is faster to deploy compared with the other two sutureless valves, both for isolated and concomitant procedures. Regarding the two available implants on the market, haemodynamic performance and durability of the devices up to date are very promising.

Comparison with transcatheter aortic valve implantation

D'Onofrio *et al.* have recently published a propensity matched analysis of two groups of 38 patients, each submitted to transapical TAVI or sutureless AVR from an initial series of 468 TAVI and 51 sutureless AVR with the Perceval valve [21]. Preoperative characteristics of the two groups were comparable. In-hospital mortality was 5.3% and 0% in the transapical TAVI and sutureless AVR group, respectively ($P = 0.49$). No strokes or acute myocardial infarctions were observed in either group. Permanent pacemaker implantation was needed in two patients in each group (5.3%, $p = 1.0$). Dialysis was required in two patients (5.3%) in the sutureless AVR group and in one patient (2.7%) in the transapical TAVI group ($p = 1.0$). Pre-discharge echocardiographic data showed that the incidence of (at least mild) PVL was higher in the transapical TAVI group (44.7% vs 15.8%, $p = .001$), but no differences in mean trans-prosthetic gradient was detected (10.3 ± 5 mmHg vs 11 ± 3.7 mmHg, $p = 0.59$).

Although TAVI represents a well-established technique for the treatment of severe symptomatic aortic stenosis in high-risk patients, it is associated with a noticeable rate of PVL. A recently published update of the PARTNER trial shows that the incidence of PVL is significantly higher after TAVI than after sutureless AVR at both 1 year and 2 years [22]. Paravalvular leak has a major impact on patient outcome. In the PARTNER trial, the presence of paravalvular aortic regurgitation after TAVI was associated with an increased rate of late mortality and the effect of aortic regurgitation on mortality was proportional to the severity of regurgitation; even mild aortic regurgitation was associated with an increased rate of late deaths [23]. Furthermore, post-procedural PVL was identified as an independent predictor of late mortality after TAVI (hazard ratio 3.79) [24,25]. In this scenario, the finding of a low PVL rate after sutureless AVR using the Perceval S valve is of great importance in the decision-making process for the choice of valve substitute particularly for patients who are in the "grey zone" that includes patients who are at high risk for surgical AVR but who are not inoperable [22]. Moreover, the feasibility of valve-in-valve procedures for redo patients creates a risk for patient-prosthesis mismatch that can be avoided using the Perceval valve [26].

Conclusions

Currently available evidence suggests that the sutureless valves are efficient and well-functioning devices which are at least comparable to traditional aortic valve prostheses. In addition, they offer the opportunity to considerably shorten myocardial ischemic times during surgical aortic valve replacement. The valves will be particularly advantageous in patients undergoing complex operations, such as concomitant mitral/tricuspid surgery and coronary revascularization, especially in compromised ventricles or otherwise sensitive to prolonged periods of myocardial ischemia. In addition, patients with small or calcified aortic roots as well as endocarditis, who are neither candidates for TAVI and will usually require complex procedures such as root replacement, could also benefit from the sutureless valve technology. Finally, apart from being faster to implant than the traditional hand-sewn valve replacement devices, the most attractive feature of the sutureless valves is that they should be easier to implant through a minimally invasive incision.

Isolated aortic valve implantation through a median sternotomy is safe with an operative mortality approaching 1% in many large centres. However, this approach can be perceived as overly aggressive by patients and referring cardiologists. The minimally invasive upper

sternotomy approach is certainly perceived by patients as more attractive, and thus the challenge for cardiac surgeons in the years ahead will be to develop a new platform to replace the aortic valve through smaller incisions, while maintaining a low operative mortality and morbidity rate and functionally perfect results. At the same time, there is a need for vigorous validation of the performance of these newly introduced devices compared to traditionally implanted surgical AVR and TAVI in rigorous multicentre randomized controlled trials with long-term follow-up.

References

1. The Joint Task Force on the Management of Valvular Heart Disease of the European Society of Cardiology and the European Association for Cardio-Thoracic Surgery Guidelines on the management of valvular heart disease (Version 2012) *Eur Heart J*. 2012 Oct;33(19):2451-96.
2. Iung B, Cachier A, Baron G, *et al*. Decision-making in elderly patients with severe AS: why are so many denied surgery? *European Heart Journal* 2005; 26:2714-20.
3. Santarpino G, Pfeiffer S, Schmidt J, *et al*. Sutureless aortic valve replacement: first-year single-center experience. *Ann Thorac Surg* 2012; 94:504-8.
4. Semsroth S, Matteucci-Gothé R, Heinz A, *et al*. Comparison of Anterolateral Minithoracotomy Versus Partial Upper Hemisternotomy in Aortic Valve Replacement. *Ann Thorac Surg*. 2015; 100:868-73.
5. Pfeiffer S, Fischlein T, Vogt F, *et al*. Superior vena cava cannulation in aortic valve surgery: an alternative strategy for a hemisternotomy approach. *Interact Cardiovasc Thorac Surg*. 2015; 20:863-5.
6. Flameng W, Herregods M, Hermans H, *et al*. Effect of sutureless implantation of the Perceval S aortic valve bioprosthesis on intraoperative and early post-operative outcomes. *J Thorac Cardiovasc Surg* 2011; 142:1453-7.
7. Shrestha M, Khaladj N, Bara C, *et al*. A staged approach towards interventional aortic valve implantation with a sutureless valve: initial human implants. *Thorac Cardiovasc Surg* 2008; 56:398-400.
8. Shrestha M, Folliguet T, Meuris B, *et al*. Sutureless Perceval S aortic valve replacement: a multicentre prospective pilot trial. *J Heart Valve Dis* 2009; 18:698-702.
9. Folliguet TA, Laborde F, Zannis K, *et al*. Sutureless Perceval aortic valve replacement: results of two European centers. *Ann Thorac Surg* 2012; 93:1483-8.
10. Santarpino G, Pfeiffer S, Concistrè G, *et al*. Perceval sutureless aortic valve prosthesis: easy, fast, and safe. *Innovations (Phila)* 2011; 6:378-81.
11. Laborde F, Fischlein T, Hakim-Meibodi K, *et al*. Clinical and haemodynamic outcomes in 658 patients receiving the Perceval sutureless aortic valve: early results from a prospective European multicentre study (the Cavalier trial). *Eur J Cardiothorac Surg* 2015; doi:10.1093/ejcts/ezv257.
12. Shrestha M, Fischlein T, Meuris B, *et al*. European multicentre experience with the sutureless Perceval valve: clinical outcomes up to 5 years in over 700 patients. *Eur J Cardiothorac Surg* 2016 Jan;49(1):234-41.
13. Kocher A, Laufer G, Haverich A, *et al*. One-year outcomes of the Surgical Treatment of Aortic Stenosis with a Next Generation Surgical Aortic Valve (TRITON) trial: a prospective multicenter study of rapid-deployment aortic valve replacement with the EDWARDS INTUITY Valve System. *J Thorac Cardiovasc Surg* 2013; 145:110-5.

14. Haverich A, Wahlers T, Borger M, *et al.* Three-year hemodynamic performance, left ventricular mass regression, and prosthetic-patient mismatch after rapid deployment aortic valve replacement in 287 patients. *J Thorac Cardiovasc Surg* 2014; 148:2854-61.
15. Santarpino G, Pfeiffer S, Concistrè G, *et al.* Perceval S aortic valve implantation in mini-invasive surgery: the simple sutureless solution. *Interact Cardiovasc Thorac Surg* 2012; 15:357-60.
16. Borger M, Moustafine V, Conradi L, *et al.* A randomized multicenter trial of minimally invasive rapid deployment versus conventional full sternotomy aortic valve replacement. *Ann Thorac Surg* 2015; 99:17-25.
17. Phan K, Tsai Y, Niranjana N, *et al.* Sutureless aortic valve replacement: a systematic review and meta-analysis. *Ann Cardiothorac Surg* 2015; 4:100-11.
18. Al-Sarraf N, Thalib L., Hughes A, *et al.* Cross-clamp time is an independent predictor of mortality and morbidity in low- and high-risk cardiac patients. *International Journal of Surgery* 2011; 9:104-9.
19. Fischlein T, Pfeiffer S, Pollari F, *et al.* Sutureless valve implantation via mini j-sternotomy: a single center experience with 2 years mean follow-up. *Thorac Cardiovasc Surg* 2015; 6:467-71.
20. Martens S, Sadowski J, Eckstein F, *et al.* Clinical experience with the ATS 3f Enable sutureless bioprosthesis. *Eur J Cardiothorac Surg* 2011; 40:749-55.
21. D'Onofrio A, Messina A, Lorusso R, *et al.* Sutureless aortic valve replacement as an alternative treatment for patients belonging to the "gray zone" between transcatheter aortic valve implantation and conventional surgery: a propensity-matched, multicenter analysis. *J Thorac Cardiovasc Surg* 2012; 144:1010-6.
22. Santarpino G, Pfeiffer S, Jessl J, *et al.* Sutureless replacement versus transcatheter valve implantation in aortic valve stenosis: a propensity-matched analysis of 2 strategies in high-risk patients. *J Thorac Cardiovasc Surg.* 2014; 147:561-7.
23. Kodali SK, Williams MR, Smith CR, *et al.* PARTNER Trial Investigators. Two-year outcomes after transcatheter or surgical aortic-valve replacement. *N Engl J Med* 2012; 366:1686-95.
24. Tamburino C, Capodanno D, Ramondo A, *et al.* Incidence and predictors of early and late mortality after transcatheter aortic valve implantation in 663 patients with severe aortic stenosis. *Circulation* 2011; 123:299-30.
25. Sinning JM, Hammerstingl C, Vasa-Nicotera M, *et al.* Aortic regurgitation index defines severity of peri-prosthetic regurgitation and predicts outcome in patients after transcatheter aortic valve implantation. *J Am Coll Cardiol* 2012; 59:1134-41.
26. Santarpino G, Pfeiffer S, Fischlein T. Sutureless aortic valve replacement to prevent patient-prosthesis mismatch in the era of valve-in-valve implantation. *J Thorac Cardiovasc Surg* 2012; 144:279-80.

Chapter 9

Training in Minimally Invasive Surgery: The General Surgeons did this Years ago, What Can we Learn?

Roger Motson

“A wise man sees as much as he ought, not as much as he can”

Michel Eyquem Montaigne (1533 - 1592)

Introduction

As many good ideas do, the idea for a national training programme in laparoscopic surgery came about over a beer in a bar at a surgical meeting. Both Robin Kennedy of St. Mark's Hospital, London, and myself were hugely frustrated at the slow rate of increase in laparoscopic colorectal surgery. To us it seemed obvious that this was the right way to treat our patients when the trials had shown similar outcomes of open and laparoscopic groups, despite a high conversion rate in the laparoscopic group. At that time only 5% of elective resections in the UK were laparoscopic and the two of us probably accounted for 2 of the 5%. The open colorectal resection majority took the result of the trials as justification not to change their practice, but as one of my patients said "if the morbidity, mortality and complications are the same why would I choose the operation with a big incision?"

We came up with the idea that we should train existing consultants and get the Department of Health (DoH) to pay for it. The views of our immediate colleagues were that "pigs might fly", "do you really think consultants will be trainees again?", "the Department of Health paying – no chance!" and several others that are unprintable. After two years of meetings with the Department of Health and with the support of the cancer czar, Prof Mike Richards, the DoH agreed to spend £5 million on the programme with the aim of having laparoscopic colonic resection available in every hospital by the time of the London Olympics in 2012.

The first step was to recruit trainers and training centres by formal application with the principle criteria of sufficient experience (approximately 100 cases) and sufficient anticipated case volume to allow training of visiting consultant trainees without damaging existing specialist registrar training. It was named the LAPCO programme. We had originally been keen on a model in which the consultant trainee would bring his own cases to the trainer's hospital but this proved difficult to arrange with the limitations of admission deadlines for cancer cases so the majority of training took place on the trainer's patients (in-reach training). There was the provision for some or all of the training to be at the trainee's hospital (out-reach training), particularly towards the end of training, but we felt the optimum training venue was the trainer's own hospital with an experienced theatre team and anaesthetist. This avoided the distractions of trying to train in an unfamiliar theatre with a team not used to the particular requirements for laparoscopic colorectal surgery.

The programme was intended to teach right, left and sigmoid colectomy and not to tackle the technically more difficult rectal resections. We guessed that training of the trainee consultants who had already trained in general laparoscopy as well as colorectal surgery would be about 20 cases and that proved to be about right. They were also required to have observed at least 10 laparoscopic colorectal cases, either on personal visits to another centre or live broadcasts at surgical conferences. In addition, there had to be a written undertaking from the consultant trainee's chief executive that resources would be put in place, particularly new laparoscopes, high quality monitors, budget for disposables, etc. to ensure that the training would not be wasted.

The concept of a mentored programme, rather than just learning by observation of an expert, was supported by research which was part of the programme showing that the incidence of conversion, complications, leaks and post-operative mortality was identical regardless of whether the operating surgeon was the trainer or trainee [1]. Other key aspects of the programme were a structured assessment of progress by means of a global assessment (GAS) form (Figure 1) and a blinded assessment prior to signing off a trainee

at the end of the programme. This comprised video review of a left/ sigmoid and right hemicolectomy by two trainers. If there was disagreement between the two reviewers, a further review would be performed by one of the more senior trainers. The trainees were either classified as satisfactory or that further training was needed. It was felt important that 'pass' and 'fail', particularly the latter, would not be helpful [2]. Another novel aspect of the programme was the assessment of the trainer's teaching by the trainees throughout their period of training [3]. An educational and research programme based at Imperial College under the leadership of Professor George Hanna was a key part of the programme.

GAS FORM EXAMPLE

A: SURGION / PATIENT

A1 Training Centre A2 Trainee A3 Patient identification number A4 Operating date

B. ASSESSMENT

- 1 Not performed, step had to be done by trainer
- 2 Partly performed, step had to be partly done by trainer
- 3 Performed, with substantial verbal support
- 4 Performed with minor verbal support
- 5 Competent performance, safe (without guidance)
- 6 Proficient performance, couldn't be better

EXPOSURE

D1 Correct theatre setup D2 Appropriate patient position

VASCULAR

D3 Safe dissection of vascular pedicle D4 Dissection of mesorectum D5 Identification of ureter or ductum

MOBILISATION

D6 Dissection of hepatic splenic flexure D7 Mesocolic dissection (left/ right) D8 Safe dissection of bowel

ANASTOMOSES

Fig1: Global Assessment form for laparoscopic colorectal training.

A CUSUM analysis of the pooled results of the trainees showed, unsurprisingly, that satisfactory performance of the easier aspects of training (theatre set up, anastomosis and exposure) was attained after relatively few cases, whereas the more difficult steps such as dissection of the vascular pedicle and mobilisation of the splenic flexure took longer to gain adequate proficiency [4] (Figure 2).

The training programme for consultants ran in parallel to a pre-existing fellowship programme for senior colorectal trainees near the end of their specialist training. The surgical trainees realised long before their seniors that laparoscopic resection was the future but there were very few opportunities for training with the small number of experienced laparoscopic colorectal surgeons in the UK. Training was also hampered by the rules of the CLASICC trial, which required that all cases entered in the trial had to be performed by the consultant and not by a supervised trainee. During the last year of the CLASICC trial, a single fellowship post for UK trainees supported by Ethicon EndoSurgery was set up in conjunction with Professor Mehran Anvari in Hamilton, Ontario, and then repatriated to Colchester when the trial was over. Ethicon expanded the programme to a total of eight centres at its peak resulting in 16 fellows trained each year. Since it began in 2004, over 150 fellows will have been trained by the end of the programme in 2016. Colorectal surgery in the UK owes an enormous

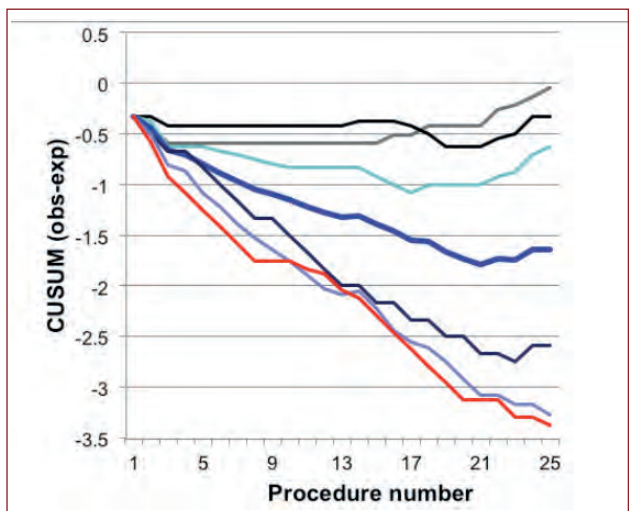


Fig 2: Proficiency gain CUSUM analysis of pooled results of trainees.

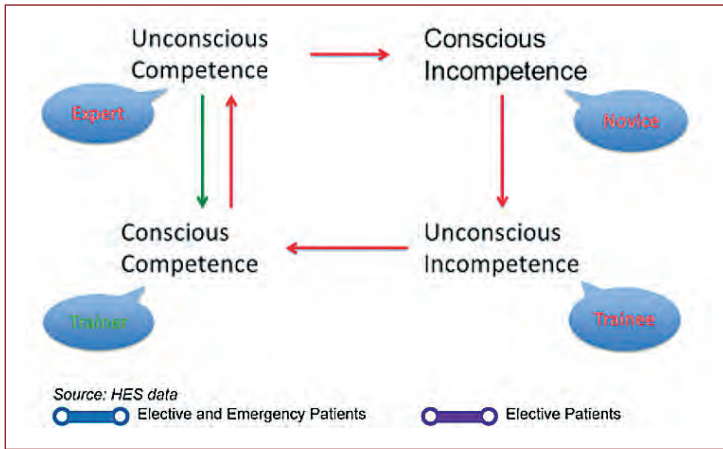


Fig 3: The stages of competence - The novice knows he cannot do the procedure, the trainee may well think he is competent before he actually is, the expert working almost automatically cannot train but needs to step back to 'conscious competence' where he can deconstruct and explain each step of the procedure

amount to Ethicon for their support for this training. In addition, there were a number of other fellowships, either supported by surgical departments or other medical device companies, such as Covidien.

Another interesting part of the LAPCO programme was the development of a 'train the trainers' course, developed with the help of Roland Valori who had pioneered such a programme for trainers in colonoscopy. Just because a surgeon is expert at laparoscopic colorectal surgery, it does not necessarily mean that he/

she will be a good trainer. Key to this is for the trainer to step back from the unconscious competence of an expert to be able to deconstruct what they do in order to teach a trainee – so called conscious competence (Figure 3). The two-day course is faculty-intensive with four faculty for 6-8 delegates. The first day is devoted to the principles involved in learning and a series of exercises in the skills laboratory. On the second day each delegate supervises a colorectal trainee for 20 minute periods with their performance observed by the faculty and remainder of the delegates. After each episode there is a debrief and critique of their

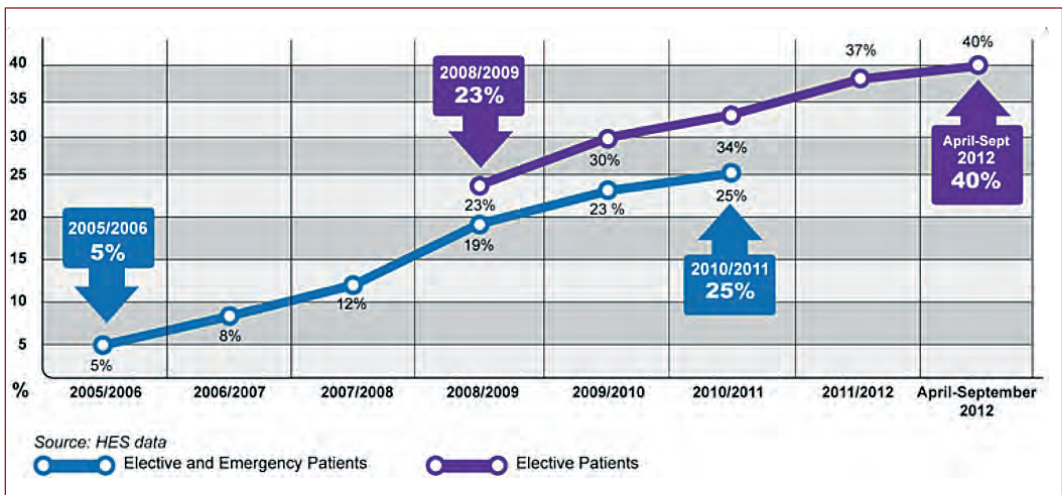


Fig 4: Hospital Episode Statistics (HES) Data for laparoscopic colorectal resection 2012.

Fig 5: Criteria for risk prediction and the weighting applied to the individual

Risk Factor	Categories	Odds Ratio (OR)	p	Points in Risk Prediction Score
Gender	Female	Intercept	<0.001	0
	Male	2.686		2
BMI	<25	Intercept	<0.003	0
	25-27.5	1.289		1
	27.5 – 30	1.338		1
	>30	2.349		2
ASA grade	1/2	Intercept	0.018	0
	3/4	1.642		1
Prior surgery	No	Intercept	<0.001	0
	Yes	2.109		2
Resection	Right	Intercept	<0.001	0
	Left	2.405		2
	High AR	2.223		2
	Low AR	2.827		3
	Other	3.607		3

performance. The great majority of the trainers in the LAPCO programme completed the 'train the trainer' course (5).

What has the programme achieved? There have been over 3,000 training episodes in the consultant training programme and 7,500 in the specialty registrar's fellowship programme. It has been shown to be safe with the clinical outcome data for consultant trainees to be the same as for their trainers, as predicted by the initial research on mentoring. Laparoscopic colorectal surgery is now available in every sizeable hospital in the UK and was just about achieved by

the time of the London Olympics in 2012. In 2012, the laparoscopic resection rate was 50% and rising and the conversion to open surgery rate was 8% (Figure 4). Currently elective laparoscopic colorectal surgery is in excess of 60%. It has been the most successful surgical training programme for existing consultants in the world, primarily because there has been no other programme addressing the needs of fully trained surgeons. It has developed a training faculty of approximately 300 consultants (130 LAPCO trained consultants, 150 Ethicon fellows and 30 or more other fellows) who will be able to train future trainees as part of their normal in-service training.

What has the programme not achieved? The DoH went on to fund a programme of training for the open surgical treatment of low rectal cancer (LOREC). It has been disappointing that we have not been able to build on the foundation of the LAPCO to develop a programme of consultant training for laparoscopic anterior resection and laparoscopic abdomino-perineal resection for rectal cancer. This surgery is unquestionably more difficult and it is counter-intuitive for surgeons to proceed on to this self-taught without further mentored training.

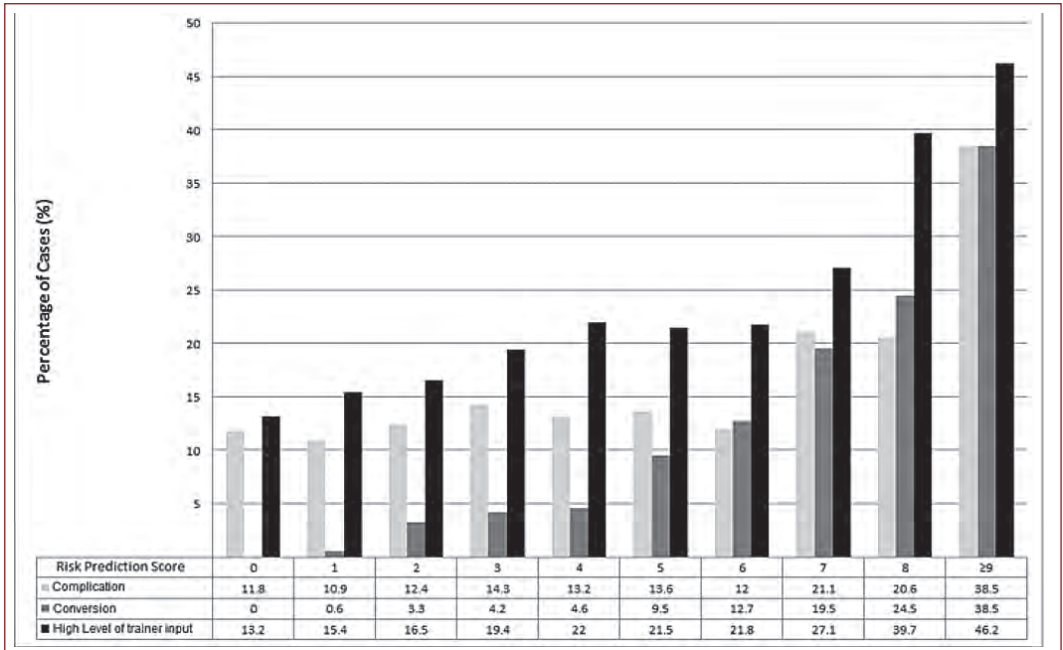


Fig 6: Relationship between conversion, complications and poor training experience.

Most recently the research programme has focussed on the prediction of operative risk and the choice of suitable cases for training. Analysis of cases from the programme demonstrated that male gender, a high body mass index, high ASA (American Society of Anesthesiologists) grade, previous surgery and a rectal resection increased the risk of complications and significantly affected outcome and mortality [6]. When these criteria (Figure 5) were applied to possible training cases there was a close correlation with a poor training episode (Figure 6). This has led to the development of an iPhone application to forecast whether a case is likely to be good for training or not (Figure 7).

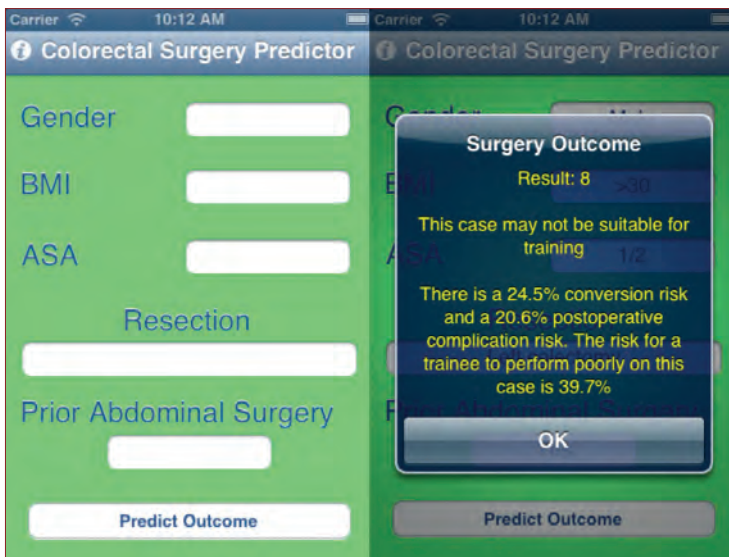


Fig7: Risk prediction App for suitability as a training case for laparoscopic colorectal surgery.

The end result of these novel programmes of training for established consultants in LAPCO and senior trainees in fellowships has, in the space of five years for consultants, and ten years for fellows, established laparoscopic colorectal surgery throughout the country and developed a substantial cohort of trained trainers to teach both laparoscopic colorectal surgery and any new developments in the future in a structured and proven manner. I have no doubt that the same type of programme and teaching techniques could be applied to minimally invasive cardiothoracic surgery.

References

1. Miskovic D, Wyles SM, Carter F, *et al.* Development, validation and implementation of a monitoring tool for training in laparoscopic colorectal surgery in the English National Training Program. *Surg Endosc.* 2011, 25:1136-42.
2. Miskovic D, Ni M, Wyles SM, *et al.* National Training Programme in Laparoscopic Colorectal Surgery in England. Is competency assessment at the specialist level achievable? A study for the national training programme in laparoscopic colorectal surgery in England. *Ann Surg.* 2013, 257:476-82.
3. Wyles SM, Miskovic D, Ni Z, *et al.* Development and implementation of the Structured Training Trainer Assessment Report (STTAR) in the English National Training Programme for laparoscopic colorectal surgery. *Surg Endosc.* 2015 Jun 24. [Epub ahead of print].
4. Miskovic D, Wyles SM, Carter F, *et al.* Development, validation and implementation of a monitoring tool for training in laparoscopic colorectal surgery in the English National Training Program. *Surg Endosc.* 2011, 25:1136-42.
5. Mackenzie H, Cuming T, Miskovic D, *et al.* Design, delivery, and validation of a trainer curriculum for the national laparoscopic colorectal training program in England. *Ann Surg.* 2015, 261:149-56.
6. Mackenzie H, Miskovic D, Ni M, *et al.* Risk prediction score in laparoscopic colorectal surgery training: experience from the English National Training Program. *Ann Surg.* 2015, 261:338-44.

Section 2

Thoracic Surgery

Perspectives on the Treatment of Diseases of the Pleura

“And that, doubtless, is why the history of the living world can be summarised as the elaboration of ever more perfect eyes within a cosmos in which there is always something more to be seen.”

Pierre Teilhard de Chardin (1881-1955)

Chapter 10

Surgery for Pleural Sepsis

Alper Toker, Seray Hazer and Sridhar Rathinam

*“The history of thought can be summarized in these words:
It is absurd by what it seeks, great by what it finds”*

Paul Valery (1871-1945)

Introduction

Pleural sepsis is a life threatening condition with mortality rates of 10% to 20% [1-3]. The aetiology is mostly post-pneumonic, followed by iatrogenic and traumatic. The timing of intervention and selection of treatment modalities remains one of the debatable issues in modern thoracic surgery [4]. The population in North America and Europe shows an increasing incidence of parapneumonic pleural empyema, which is possibly the result of an aging population with associated comorbidities [5, 6]. The data from the United Kingdom shows that the incidence of community-acquired pneumonia (CAP) increases with age with the incidence seven times higher in patients who are 85-89 years old than those 65-69 years old [7]. Currently, it is known that lower respiratory tract infections are the fourth most common cause of death globally [8]. Advanced age and the presence of comorbid conditions (chronic heart, renal, liver or respiratory disease), including chronic alcoholism and smoking, are linked to the increase of CAP [9]. Moreover, these conditions also cause a higher risk for parapneumonic pleural empyema. In the US, hospitalization for the treatment of empyema has increased from 3.04 to 5.98 per 100,000 population from 1996 to 2008 [6]. This situation is one of the important healthcare problems today and will likely remain so for the next decade.

Clinical Conditions

The common cause of pleural sepsis is pneumonia which may be community-acquired or hospital-acquired. A large prospective observational study showed that the development of pleural sepsis is multifactorial in patients with community-acquired pneumonia. The associated factors are low serum albumin, low sodium levels, elevated C-reactive protein, increased platelet count, intravenous drug use and chronic alcohol abuse [10]. Comorbid conditions may be valuable in predicting the development of complicated parapneumonic pleural effusion or empyema.

Hospital-acquired empyema can be further classified as pleural sepsis due to pneumonic or non-pneumonic aetiology; however, there is no significant difference in outcomes between these groups [11]. The most common causes for non-pneumonic hospital-acquired

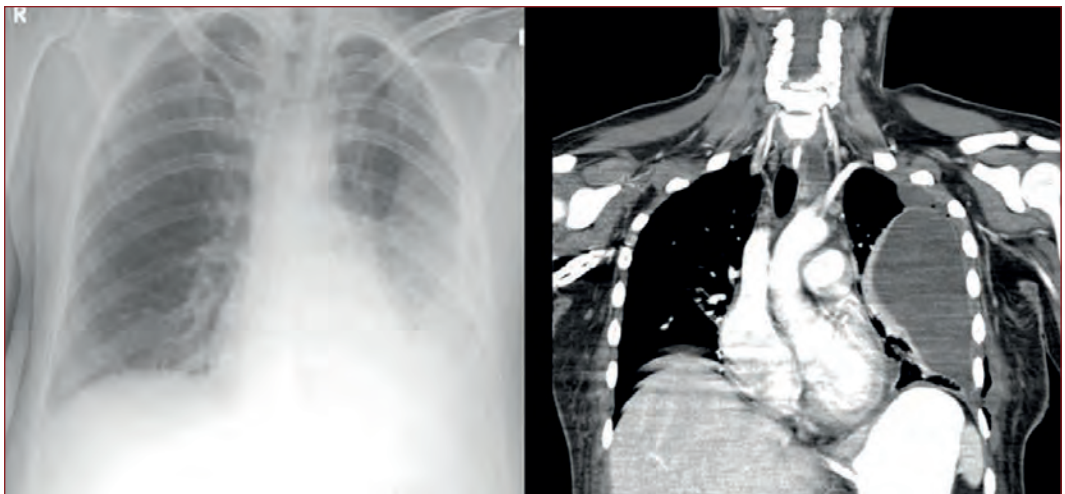


Fig 1: Chest radiograph and CT scan demonstrating left sided empyema. The CT highlights the empyema collection as well the cortex.

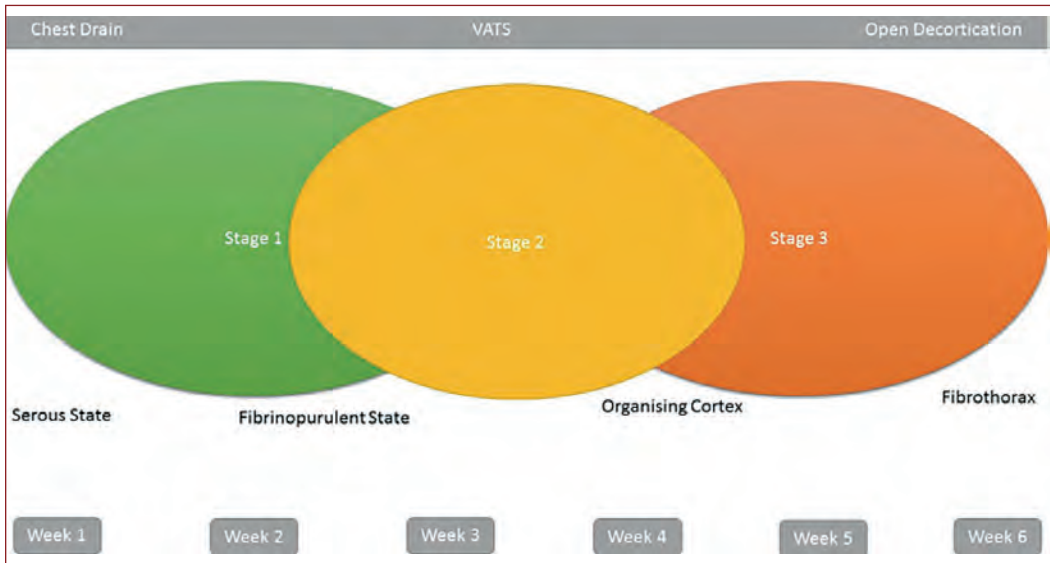


Fig 2: Stages of empyema

pleural sepsis are drain-related infections, hepato-biliary tract infections, septic emboli and post-lobectomy/pneumonectomy sepsis [12]. A prospective multi-centre observational trial indicated the incidence of empyema was 26.8% among patients with post-traumatic retained haemothorax [13].

An untreated empyema may cause fibrosis of the lung, contraction of the hemithorax, spontaneous drainage of pus through the chest wall (empyema necessitans) or into the bronchial tree (bronchopleural fistula), pericarditis, cerebral abscess and distant infection (e.g. osteomyelitis).

Aetiology and Microbiology

Parapneumonic or post-pneumonic effusions, tuberculous effusions, malignant effusions, surgical trauma, lung resections and chest trauma may be underlying factors in the development of pleural sepsis. The most common form of empyema thoracis is parapneumonic (40-60%) followed by post-surgical (30%) [14].

The aetiological agents of community and hospital-acquired empyemas are different. Community-acquired infections are usually Gram-positive organisms with *Streptococcus milleri* being the most common. Anaerobic organisms occur in about 15% of cases usually associated with poor dentition and aspiration due to alcoholism. The Multicenter Intrapleural Sepsis Trial-1 (MIST-1) confirmed that in community-acquired pneumonia, the most prevalent organisms were Streptococcal species (*S. milleri* and *S. pneumoniae*) followed by anaerobes and Staphylococci [15]. The incidence of empyema caused by these organisms increases in older adults with underlying comorbid conditions [16].

On the other hand, more than half of the patients with culture positive hospital-acquired infections are due to Staphylococci, of which methicillin-resistant *Staphylococcus aureus* (MRSA) accounts for about two thirds according to the British Thoracic Society Guidelines [17]. Gram negative aerobes and anaerobes are other pathogens causing hospital-acquired pneumonia.

Diagnosis

Symptoms include cough, fever, shortness of breath and chest pain. Loss of chest wall movement, dullness on percussion with elevated leukocyte count and raised C-reactive protein are common findings. Chest x-ray may demonstrate an effusion, air-fluid levels or pleural thickening. Chest radiography performed after complete drainage of a pleural effusion will aid in defining entrapment of the lung and may give an impression of a thickened visceral cortex. Computed tomography (CT) is the gold standard to define the status of an empyema and it also clarifies the underlying pathology such as an obstructing tumour or parenchymal lung abscess. Contrast-enhanced CT can identify parietal pleural thickening and effusions (Figure 1). However, it is not possible to estimate the thickness of the visceral cortex as this can be confounded by the overlying exudate and debris. Ultrasound is better for staging the empyema and is also commonly used to identify the site for drain insertion. It can differentiate empyema and haemorrhagic effusions by echogenicity and septation [18].

Currently, the gold standard to diagnose an infected effusion is thoracentesis with the following findings:

1. purulent fluid,
2. microbiology: organism identified on Gram staining and culture,
3. biochemistry: high protein (i.e. exudate) >30 mg/dl, pH <7.2, lactate dehydrogenase greater than 1000 IU/litre,
4. glucose <50 mg/dl.

Stages of Empyema

The progression of post-pneumonic effusion to organized empyema manifests in a phased manner over a 3 to 6-week period (Figure 2). This was stratified by the American Thoracic Society into three stages: stage 1 is defined as the exudative stage, stage 2 is the fibrinopurulent and loculated stage, and stage 3 is the chronic organising cortical stage. The progression of an untreated empyema leads to trapping of the lung and restriction of chest wall movements. If left untreated, some empyemas eventually lead to a thick fibrinous layer encasing the lung and chest wall eventually leading to a fibrothorax.

Treatment

Pleural space infection is associated with a high morbidity and mortality rate in all ages, even with early aggressive use of broad-spectrum antibiotics [19]. The selection of the best treatment option depends on the aetiology of the empyema, the stage of the empyema and the general condition of the patient. The basic principles of treatment are evacuation and control of sepsis, and re-expansion and restoration of lung parenchymal function with re-establishment of chest wall mechanics. This is achieved by several means:

1. systemic treatment of infection with antibiotics,
2. evacuation of infected fluid and deloculation of the separate collections,
3. decortication of the pleural space,
4. full re-expansion of the lung, or obliteration of the space,
5. improvement of the patient's general nutritional status.

Of these principles, the obliteration of space is the most important and the rest are means to achieve it. Although it is possible to treat a patient with pleural sepsis by medical means alone, surgical intervention is usually unavoidable especially in complex pleural sepsis [20]. The primary treatment of complicated pleural effusions is early drainage, either by intercostal tube drainage or a decolucation procedure performed with video-assisted techniques [21, 22]. Video-assisted thoracic surgery (VATS) has been shown to cause less postoperative discomfort and reduced postoperative hospital stay when compared to patients who have either a thoracotomy as a primary procedure or fibrinolytic therapy. VATS has a success rate of 75% in all patients with empyema regardless of stage [23].

Fibrinolytic therapy

Fibrinolytic therapy is an effective alternative option to VATS for patients with multi-loculated effusions who are not fit enough for surgery. **The Multicentre Intrapleural Sepsis Trial (MIST)** did not show any benefit with fibrinolysis with streptokinase [15], however the **Second Multicenter Intrapleural Sepsis Trial (MIST-2)** showed that combining tissue plasminogen activator (TPA) and DNase improved the drainage of empyema and reduced the length of hospital stay and the need for surgery [24]. However, in clinical practice, surgeons almost always consider VATS treatment as the first option in fit patients with pleural sepsis when chest tube drainage and antibiotic treatment have failed to achieve resolution of the infection [17].

Principles of Surgical Intervention

The two main components of surgical intervention are:

1. **Deloculation and debridement** where the loculations are broken down and evacuation of necrotic material from the pleural space is performed to control sepsis. This also includes thorough debridement of the chest cavity. It will only be successful if there is complete re-expansion of the lung after the procedure without any entrapment.
2. **Decortication** – this is surgical peeling of the organized cortex covering the visceral pleura to allow complete lung re-expansion, thus releasing the trapped lung and obliterating the empyema cavity. Parietal pleurectomy enables removal of infected tissue from the empyema cavity and restores chest expansion. Decortication also frees the diaphragm from thickened pleura and improves chest wall mechanics.

VATS Debridement

Chest drainage and VATS play the most important role in the first two stages of the empyema (exudative and fibrinopurulent stages). There is no consensus which surgical option should be the first choice; however, recent studies have shown that VATS decortication offers better outcomes when compared with tube thoracostomy and similar results in terms of resolution of disease when compared with open surgery [25]. It decreases the length of hospital stay, postoperative complications and morbidity and should be performed before an open procedure in patients with chronic empyema. There are reports of single port thoracoscopy to provide better cosmetic results and less postoperative pain with equivalent therapeutic results [26]. VATS is also the optimum procedure for the initial treatment of post-traumatic retained haemothorax which offers video-assisted exploration of the thoracic cavity to evacuate the retained haemothorax as well as to evaluate associated injuries, especially diaphragmatic trauma.

Open Decortication

Open surgical decortication is performed in stage III empyema or fibrothorax. It remains a valuable technique in the management of empyema to increase the cure rate from pleural sepsis as a first intervention particularly in the developing world. Shin *et al.* reported the impact of surgical decortication for empyema in 111 patients, of which 27 underwent surgical decortication as the first intervention [27]. Surgical decortication was more effective (96.3%, 26/27 patients) compared with simple drainage (58.3%, 49/84 patients; $p < 0.0001$). After propensity-scored matching, decortication resulted in a better outcome (95%, 19/20 patients) than drainage (56.7%, 17/30 patients; $p = 0.003$). Surgical decortication as the first-line treatment for empyema was the best predictor of treatment success after adjustment for confounding factors (odds ratio 14.5; 95% confidence interval, 1.7-123.1, $p = 0.014$).

Empyema in Children

In early stage empyema, chest tube drainage, antibiotics and fibrinolytic drugs are recommended. Fibrinolysis may pose less risk of acute clinical deterioration and may be recommended as the first-line therapy for children with empyema. However, the failure of these treatments usually leads to surgical intervention.

A recent report indicated that VATS has a very effective role in the paediatric population when compared to fibrinolytic therapy [29] and plays a significant therapeutic role in the fibrinopurulent stage of empyema, in which loculated fluid cannot often be adequately drained by chest tubes and fibrinolytic drugs alone. It is also an important treatment modality in the organizing phase.

Open Window Thoracostomy (OWT)

If the patient is medically unstable (patients in intensive care who are mechanically ventilated with high inspiratory pressures and receiving vasoactive medications), the evacuation of pus and debridement may be performed using alternative strategies. In such patients, the pleural sepsis can be managed by an Open Window Thoracostomy (OWT) procedure (Eloesser or Clagett procedure). The main advantage of an OWT is creating anatomical access to mechanically clean and debride the cavity to avoid retention of pus in the cavity. It has been reported that a specific advantage of OWT may be allowing successful closure of bronchopleural fistulae which may be associated with the empyema [12].

The differences between the Eloesser flap and a Clagett window is that the latter is larger and was intended as a temporary measure to provide decontamination of the pleural space with a subsequent repair. In contrast, the Eloesser flap is designed as a permanent open window into the pleural space. A rib resection and drain insertion should be considered if the patient is moribund to evacuate the sepsis.

Recent Innovative Approaches to Pleural Sepsis: VAC Therapy

More recently, VAC (vacuum-assisted closure) therapy, which has provided good results in mediastinal wound infections following cardiac surgery, has been used in complicated or complex pleural empyema (e.g. post-resectional or parapneumonic empyema). A recent best evidence topic review reported VAC therapy decreases morbidity rate, hospital stay,

length of treatment and can make the condition manageable in an outpatient setting [29].

The recommended surgical technique for VAC is similar to its use in mediastinal wound infections. Polyurethane foam is used to fill the cavity and negative pressure is initially applied in the range of -25 to -75 mmHg over the foam. This promotes angiogenesis and fibroblastic activity. The negative pressure can be gradually increased to 125 mmHg if there is no mediastinal shift. The interval of dressing change is about 2 to 5 days.

A retrospective cohort study of 19 patients showed that the average duration of OWT in a group of patients with VAC was 39 ± 17 days and in those without VAC was 933 ± 1422 days [30]. The presence of a bronchopleural fistula (BPF) is not a contraindication to VAC therapy [31]. Recent studies have shown that closure of the fistula with muscle flaps or endobronchial stents enables the use of VAC therapy in post-pneumonectomy empyema [32].

Mini-VAC and Mini-VAC-Instill therapies aid in the removal of infected material from the wound site without an OWT. In Mini-VAC therapy, an OWT with rib resection is avoided and the debridement is performed through a small minithoracotomy. This minithoracotomy is closed during the same admission after a series of VAC dressing changes when the cavity is sterile. Additional intrapleural rinsing with antiseptics (Mini-VAC-Instill) is useful in cases of culture-proven pleural sepsis. The additional benefits conferred by VAC therapy include increased tissue oxygen tension, increased blood flow and increased granulation tissue formation. The presence of a broncho-pleural fistula is not a contraindication to Mini VAC, since small broncho-pleural fistulae close spontaneously [33].



Conclusions

Pleural sepsis is a life-threatening condition which requires optimum and timely management. The principles of management include evacuation of sepsis, treatment with appropriate antibiotics, re-expansion of the lung and restoration of chest wall mechanics. The surgical strategy to manage the problem depends on the stage of the empyema, the fitness of the patient and the timing of intervention which determines whether either thoracoscopic or open decortication is used.

References

1. Davies CW, Kearney SE, Gleeson FV, *et al.* Predictors of outcome and long-term survival in patients with pleural infection. *Am J Respir Crit Care Med* 1999; 160:1682-1687.
2. Galea JL, De Souza A, Beggs D, *et al.* The surgical management of empyema thoracis. *J R Coll Surg Edinb* 1997; 42(1):15-18.
3. Brims FJ, Lansley SM, Waterer GW, *et al.* Empyema thoracis: new insights into an old disease. *Eur Respir Rev* 2010; 19:220-228.
4. Rosenstengel A. Pleural infection- current diagnosis and management. *J Thorac Dis* 2012; 4:186-193.
5. Farjah F, Symons RG, Krishnadasan B, *et al.* Management of pleural space infections: a population-based analysis. *J Thorac Cardiovasc Surg* 2007; 133:346-51.

6. Grijalva CG, Zhu Y, Nuorti JP, *et al.* Emergence of parapneumonic empyema in the USA. *Thorax* 2011; 66:663-668.
7. Millett ER, Quint JK, Smeeth L, *et al.* Incidence of community-acquired lower respiratory tract infections and pneumonia among older adults in the United Kingdom: a population-based study. *PLoS One* 2013 Sep 11;8(9):e75131.
8. Lozano R, Naghavi M, Foreman K, *et al.* Global and regional mortality from 235 causes of death for 20 age groups in 1990 and 2010: a systematic analysis for the global burden of disease study 2010. *Lancet* 2012; 15; 380:2095-2128.
9. Torres A, Peetermans WE, Viegi G, *et al.* Risk factors for community-acquired pneumonia in adults in Europe: a literature review. *Thorax* 2013; 68:1057-1065.
10. Chalmers JD, Singanayagam A, Murray MP, *et al.* Risk factors for complicated parapneumonic effusion and empyema on presentation to hospital with community-acquired pneumonia. *Thorax* 2009; 64:592-597.
11. Chen W, Lin YC, Liang SJ, *et al.* Hospital- acquired thoracic empyema in adults: A 5-year study. *South Med J* 2009; 102:909-914.
12. Hofmann HS. Modern management of Empyema Thoracis. *Seminars in Thoracic and Cardiovascular Surgery* 2014; 25:287-291.
13. DuBose J, Inaba K, Okoye O, *et al.* Development of posttraumatic empyema in patients with retained hemothorax: Results of a prospective, observational AAST study. *J Trauma Acute Care Surg* 2012; 73:752-757.
14. Molnar TF. Current surgical treatment of thoracic empyema in adults. *Eur J Cardiothorac Surg* 2007; 32:422-430.
15. Maskell NA, Davies CW, Nunn AJ, *et al.*; First Multicenter Intrapleural Sepsis Trial (MIST1) Group. U.K. Controlled trial of intrapleural streptokinase for pleural infection. *N Engl J Med.* 2005 Mar 3; 352(9):865-74.
16. Burgos J, Falco V, Pahissa A: The increasing incidence of empyema. *Curr Opin Pulm Med* 2013; 19:350-356.
17. Davies HE, Davies RJ, Davies CW. BTS Pleural Disease Guideline Group. Management of pleural infection in adults: British Thoracic Society Pleural Disease Guideline 2010. *Thorax.* 2010 Aug; 65 Suppl 2:ii41-53.
18. Rathinam S, Waller DA. Pleurectomy decortication in the treatment of the “trapped lung” in benign and malignant pleural effusions. *Thorac Surg Clin.* 2013 Feb; 23(1):51-61.
19. Muskett A, Burton NA, Karwande SV, *et al.* Management of refractory empyema with early decortication. *Am J Surg* 1988; 156:529-532.
20. Lemmer JH, Botham MJ, Orringer MB. Modern management of adult thoracic empyema. *J Thorac Cardiovasc Surg* 1985; 90:849-55.
21. Lackner RP, Huges R, Anerson A, *et al.* Video-assisted evacuation of empyema is the preferred procedure for management of pleural space Infections. *Am J Surg* 2000; 179:27-30.
22. Waller DA, Rengarajan A. Thoracoscopic decortication: a role for video-assisted surgery in chronic postpneumonic pleural empyema. *Ann Thorac Surg* 2001; 71:1813-1816.
23. Anyanwu AC, Jaiswal P, Treasure T. Surgical Treatment of Thoracic Empyema. In: Treasure T, Keogh B, Hunt I, Pagano D, Eds. The evidence for cardiothoracic surgery. Shrewsbury: TFM Publishing, 2005.

24. Rahman NM, Phil N, Maskell NA, *et al*. Intrapleural use of tissue plasminogen activator and DNase in pleural infections. *N Eng J Med* 2011; 365:518-526.
25. Chambers A, Routledge T, Dunning J, *et al*. Is video-assisted thoracoscopic surgical decortication superior to open surgery in the management of adults with primary empyema? *Interac Cardiovasc Thorac Surg* 2010; 11: 171–177.
26. Martinez- Ferro M, Duarte S, Laje P. Single port thoracoscopy for the treatment of pleural empyema in children. *J Pediatr Surg* 2004; 39, 1194-1198.
27. Shin JA, Chang YS, Kim TH, *et al*. Surgical decortication as the first-line treatment for pleural empyema. *J Thorac Cardiovasc Surg* 2013; 145:933-9.
28. Bishay M, Short M, Shah K, *et al*. Efficacy of video-assisted thoracoscopic surgery in managing childhood empyema: a large single-centre study. *J Pediatr Surg* 2009; 44, 337–342.
29. Haghshenasskashani A, Rahnavardia M, Yana TD, *et al*. Intrathoracic application of a vacuum-assisted closure device in managing pleural space infection after lung resection: is it an option? *Interact Cardiovasc Thorac Surg*. 2011; 13:168-174.
30. Palmén M, van Breugel HN, Geskes GG, *et al*. Open window thoracostomy treatment of empyema is accelerated by vacuum-assisted closure. *Ann Thorac Surg*. 2009; 88:1131-1136.
31. Sziklavari Z, Grosser C, Neu R, *et al*. Complex pleural empyema can be safely treated with vacuum-assisted closure. *J Cardiothorac Surg*. 2011; 6:130.
32. Rocco G, Cecere C, La Rocca A, *et al*. Caveats in using vacuum-assisted closure for post-pneumonectomy empyema. *Eur J Cardiothorac Surg*. 2012; 41:1069-1071.33.
33. Sziklavari Z, Groosser C, Neu R, *et al*. Minimally invasive vacuum-assisted closure therapy in the management of complex pleural empyema. *Interac Cardiovasc Thorac Surg*. 2013; 17: 49–53.

Chapter 11

Management of Residual Pleural Space

Keng Ang, Anne Olland and Gilbert Massard

“Thinking is more interesting than knowing, but less interesting than looking”

Johann Wolfgang Goethe (1749-1832)

Introduction

Space management is a challenging aspect of thoracic surgical practice. After partial lung resection, the normal process is progressive obliteration of the remaining pleural space. This is achieved by several mechanisms: the remaining lung expands, the diaphragm elevates (even if the phrenic nerve has not been injured), the mediastinum shifts towards the operated side, the intercostal spaces narrow and there is a mild exudate of pleural fluid (Figure 1).

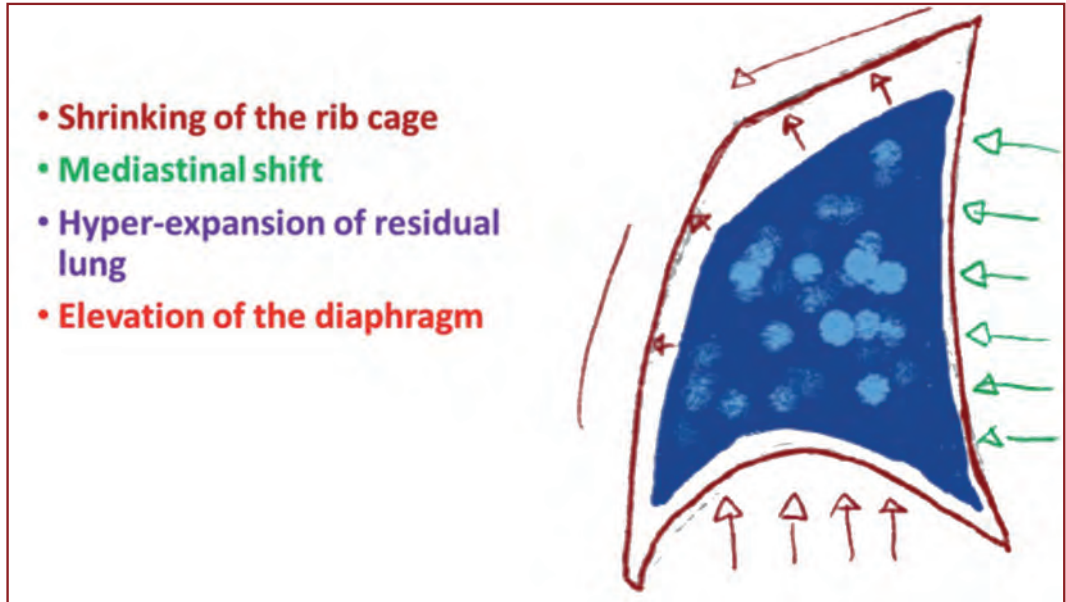


Fig 1: Pleural space readjustment after lung resection

Post-operative residual space can occur due to one or more of the following factors:

1. An unsealed air leak.
2. Reduced pulmonary compliance that may inhibit adequate re-expansion - this may be due to fibrosis, suppurative or granulomatous lung disease, or more simply to a pleural peel which has not been adequately removed.
3. Excessive loss of volume, as observed after bi-lobectomy or lobectomy extended to a segment of the adjacent lobe – this leaves a relatively small residual lung with reference to the size of the pleural cavity,
4. Stiff diaphragm or a rigid mediastinum which oppose the natural reduction of the volume of the hemithorax - this may happen after previous surgery including simple pleurodesis, trauma and empyema,
5. Poor technique during removal of chest drain can also introduce air into the pleural space.

Evaluation and Implications of Residual Pleural Space

Before deciding on a strategy for management of a residual space, it must be ascertained whether there is an ongoing air leak and whether the patient is symptomatic. The former is obvious in presence of a functioning chest tube, but more difficult to determine when the chest tube has been removed. Barker *et al.* [1] and Coryllos *et al.* [2] have elegantly

Table 1: Pressure measurements and gas analysis in open and closed pleural spaces.

	Peripheral fistula	'Closed' space
Pressure measurements	Restores to baseline	Stable
Gas analysis:		
oxygen (%) at end of expiration / end of inspiration	10 / 18	4
carbon dioxide (%) at end of expiration / end of inspiration	6 / 2.5	7

demonstrated the physiological difference between a 'closed' space and one with an on-going air leak due to a parenchymal or bronchiolar fistula. Essentially, a pleural space with an on-going air leak has fluctuating pressure changes while pressures are stable in a closed space. Gas analysis of oxygen (O₂) and carbon dioxide (CO₂) in a closed space shows a static level during the respiratory cycle, characterized by a high CO₂ / low O₂ profile. In an open space, there is an inspiratory-expiratory fluctuation that resembles the profile of alveolar gases (Table 1).

The other important part of the evaluation is to assess its clinical and radiological features. Barker *et al.* have suggested classifying residual pleural space into 'benign' and 'malignant' based on clinical and radiological features (Table 2).

Briefly, a benign pleural space is characterized by the absence of symptoms; it is thin-walled on radiography and contains no fluid. On the other hand, a malignant space is associated with fever, illness and sometimes purulent sputum, with a high leukocyte count and elevated inflammatory markers. Chest x-ray of a malignant space demonstrates a thickened visceral pleura and an air-fluid level.

Management of "Benign" Pleural Space

Benign pleural space is normally self-limiting and its management depends on whether there is an on-going air leak and whether the chest drain is still in-situ. Smaller spaces occurring after chest drain removal can normally be managed without repeat drainage if close initial follow-up shows no progression of the pleural space; otherwise, reinsertion of a chest tube is recommended. In case of benign pleural space with no air leak on chest drainage, the chest tube can be safely removed. If the surgeon is anxious or the patient at high risk, an intermediate step is to use a Heimlich valve or Flutter bag until the space regresses [3].

Table 2: Clinical and radiological classification of residual pleural space.

	Benign space	Malignant space
Clinical findings	No fever	Fever, illness
	No sputum	Purulent sputum
Haematology	Normal leukocyte count	Elevated leukocyte count
Radiology	Regression	Progression
	Thin-walled	Thick pleural peel
	No fluid	Increasing air-fluid level

Table 3: Indications for thoracoplasty

Parenchymal	Excavated tuberculosis Aspergilloma / unfit for resection
Pleural = apical space	e.g. lobectomy for TB or its sequelae
Empyema after pneumonectomy	Isolated With bronchial fistula With oesophageal fistula (rare)

In cases with an ongoing air leak, patients will need prolonged drainage until the air leak has settled, preferably using a Heimlich valve. This is preferred as it offers a better pressure gradient for an air leak compared with underwater sealed systems [4]. The excessive compliance of a water seal shifts the intrapleural pressure towards atmospheric pressure, whereas the Heimlich valve favours a shift towards physiological intrapleural pressure levels. Reoperation for prolonged air leak is a debatable issue.

Management of “Malignant” Residual Pleural Space

Malignant residual pleural space is associated with underlying pleural infection and can be difficult to treat. The principles of its management are identical to those of empyema. The pleural space needs to be first evacuated and cleaned of any infected material, and ultimately to be obliterated.

The different means to clean the pleural space include tube drainage, intrapleural fibrinolysis, surgical debridement and even thoracostomy. The next aim is to obliterate the residual space, mainly by re-expansion of the lung. Spontaneous re-expansion of the lung after simple cleaning of the pleural space or decortication depends on the quantity of lung that is left and its compliance. Any residual space that persists after pleural sanitation may need further intervention in the form of thoracoplasty or muscle plompage.

There are some important factors to consider in deciding the choice of intervention. Chronic infectious diseases such as tuberculosis or aspergilloma are associated with poor compliance of the remaining lung. Possibilities for myoplasty are reduced in patients with malnutrition and following a non-muscle sparing thoracotomy. It is also very important to diagnose any chronic fistulae as alveolar and bronchial fistulae are common. Oesophageal fistulae should be actively screened for when culture reveals a mixed microbiological flora including yeast. Fistulae involving the bowel, biliary ducts or pancreas are uncommon.

Thoracoplasty is usually indicated in residual space after tuberculosis or its sequelae, refractory infections such as aspergilloma, and empyema after pneumonectomy. Current indications for thoracoplasty are listed in Table 3.

Thoracoplasty is performed in a lateral decubitus position via a paravertebral incision midway between the spine and scapula starting at the level of the upper border of the scapula; at the level of the tip of the scapula, it bends anteriorly in the way of a posterolateral thoracotomy. The trapezius and rhomboid muscles are divided posteriorly; the posterior half of the latissimus dorsi is divided while the serratus anterior may be preserved. Next, the scapula is elevated to expose the ribs; this manoeuvre involves detaching the digitations of the serratus muscle. Now the operative field is ready for rib resection. The level of the lowest rib to be resected is easily determined on a plain antero-posterior chest film. The ribs are

Table 4: *Tips and tricks for thoracoplasty*

Start with the lowest (most often 4th or 5th) rib
Elevate the scapula with the chest retractor
Use dedicated rib shears for the first 2 ribs
Remove the first rib
6th rib : watch the scapula
Leave the 9th rib
Drain pleural + parietal space

resected from below upwards to include the first rib. A sub-periosteal rib resection is used to allow some bone regeneration, which can provide some stability in the medium term.

Posteriorly the costotransverse and costovertebral joints are disarticulated to resect the rib flush with the transverse process to avoid any paravertebral residual space. Usually, the first two ribs are completely resected while decreasing parts are taken from the third rib downwards leaving increasing anterior segments. The stumps of the ribs should ideally draw a horizontal line. Removal of the 6th rib is usually complicated by impaction of the scapula and requires resection of the subspinal part of the scapula. The 9th rib should always be left to preserve the costochondral junction with the sternum. It appears safe to leave a chest tube in the pleural space, however management of the perithoracic space is controversial. The authors prefer to drain this with large bore chest tubes whilst others prefer no drainage, with the thought that the post-operative hematoma improves the collapse determined by the thoracoplasty. Postoperatively, the mediastinum can be unstable and the deossified chest wall is prone to paradoxical movement similar to flail chest. This area needs to be packed with compressive dressings. The patient should receive physiotherapy with emphasis to avoid a stiff shoulder and scoliosis. Table 4 summarises some of the tricks for performing thoracoplasty.

The other option to fill a residual space is to use myoplasty. Available muscle flaps that are easy to mobilize are the latissimus dorsi, serratus and pectoralis major muscles. Both latissimus and pectoralis offer the advantage of being combined as a cutaneous flap if required. Lower areas of the chest can also be filled with the rectus abdominis muscle. A more sophisticated option is a free transfer of the contralateral latissimus dorsi with microsurgical vascular anastomoses. In very complex situations, the greater omentum may offer an alternative.

The decision for a myoplasty depends on the size of the space to fill and the quality of the available muscles. Poor nutrition in chronically ill patients and previous thoracotomy are contraindications. Multiple muscle flaps have some detrimental effects on shoulder motion, and a winged scapula invariably follows use of the serratus muscle.

Prevention and Management of Air Leaks

An air leak is a major contributing factor to the development of residual pleural space and it is therefore vital to prevent and minimise these. Risk factors for prolonged air leak are outlined in Table 5. Recognition of these risk factors will help us to plan our operation to minimise air leaks.

Table 5: Causes of prolonged air leak

Risk Factor	Level of evidence*
Chronic obstructive pulmonary disease	B
Lung volume reduction surgery	B
Upper lobectomy / bilobectomy	B
Large volume leak	B
Pneumothorax	B
Reduced transfer factor (TLCO)	C
Preoperative steroids	C
Pleural adhesions	C
Elevated peak airway pressure	C
Diabetes	C

* A - data derived from multiple randomized clinical trials or meta-analyses; B – data derived from a single randomized clinical trial or large non-randomized studies; C – consensus of opinion of the experts and/or small studies, retrospective studies, registries


Intraoperative strategies to minimise air leaks in those cases at risk include: pleurodesis, pleural tent, pneumoperitoneum, Lyman-Brewer manoeuvre, phrenic crush and thoracoplasty [4]. Pleurodesis by pleural abrasion or pleurectomy will not jeopardize a subsequent operation including lung transplantation in patients with emphysema or cystic fibrosis. The pleural tent technique, which requires dissection of the apical pleura extrapleurally to bring it down to the visceral pleura, may lead to an extrapleural residual space. The Lyman Brewer manoeuvre consists of incising the diaphragm intrapericardially on a sagittal line, medial to the insertion of the phrenic nerve, to fill basal space. A phrenic crush has been described together with right lower and middle lobectomy but may have a poor functional outcome. We do not favour immediate thoracoplasty and prefer to leave the possibility for a spontaneously benign outcome.

In addition, there are commercial adjuncts currently available to reduce air leaks such as sealants (biological, synthetic), buttressing (animal, vegetable & synthetic) and sponges. The efficacy of these adjuncts is not universally proven. In a meta-analysis by Malapert *et al.*, it was reported that the use of surgical sealants and buttressing reduced the risk of prolonged air leakage and postoperative arrhythmias after pulmonary resection [5]. However, given the possibility of publication bias, the conclusions should be interpreted with caution. In the most comprehensive review to date of the randomised clinical trials of surgical sealants, it was not possible to generalise the efficacy of the sealants investigated. Hence, the reviewers recommended against indiscriminant and non-selective use of sealants.

In a Cochrane Database Systematic Review in 2010, it was reported that though there was a reduction in post-operative air leak and time to chest drain removal, it was not associated with a reduction in length of post-operative hospital stay [6]. Therefore, systematic use of surgical sealants with the objective of reducing hospital stay cannot be recommended. This was mirrored in the recommendations by Singhal and Shrager [7]. In the same review, buttressing of staple lines is recommended for lung volume reduction surgery (class I, level

B) and reasonable in anatomic pulmonary resections in patients with severe emphysema with FEV1 < 50% predicted (class IIa, level B).

In the management of air leaks, there is on-going debate as to whether the use of suction is necessary. The current recommendation is against the use of thoracic suction routinely in patients with severe emphysema. If suction is required for these patients, the minimum amount of suction that achieves the desired effect of lung expansion should be used. Other situations whereby suction is indicated are in patients with large air leaks or pneumothorax (level B), and moderate to severe restrictive lung disease (level C). In patients without severe emphysema, either reduced suction with underwater seal, or digital suction are reasonable. Patients on low pressure suction need to be monitored closely in the presence of an ongoing air leak to make sure there is no clinical deterioration.



When the air leak is prolonged, treatment options can be conservative (such as regular outpatient review of chest drainage using a Heimlich valve, autologous blood patch or chemical pleurodesis) or invasive (such as VATS reoperation, pneumoperitoneum or endobronchial valve placement). Watchful waiting in the outpatient setting with a Heimlich valve is reasonable in most situations when the air leak is small and the residual space is stable. It is reasonable to cover these patients with antibiotics for skin flora.

Conclusions

The management of residual pleural space after lung resection depends upon its aetiology, the state of the residual lung, the patient's overall condition and the response to the initial treatment strategy. Postoperative air leaks and residual pleural space are closely related and strategies to manage them have to be defined on an individual patient basis. While guidelines offer some evidence-based arguments, management of complex clinical scenarios often relies on the experience of the clinician.

References

1. Barker WL, Langston HT, Noffah P. Postresectional thoracic spaces. *Ann Thorac Surg* 1966; 2:299-310.
2. Coryllos PN, Birnbaum E. Studies on gas exchanges in atelectasis and pneumothorax. *Amer J Med Sci.* 1932; 33:317.
3. Cerfolio RJ, Bass CS, Pask AH, *et al.* Predictors and treatment of persistent air leaks. *Ann Thorac Surg.* 2002 Jun; 73(6):1727-30; discussion 1730-1.
4. Waller DA, Edwards JG, Rajesh PB. A physiological comparison of flutter valve drainage bags and underwater seal systems for postoperative air leaks. *Thorax* 1999; 54:442-443
5. Malapert G, Hanna HA, Pages PB, *et al.* Surgical sealant for the prevention of prolonged air leak after lung resection: meta-analysis. *Ann Thorac Surg* 2010, 90:1779-1785.
6. Belda-Sanchís J, Serra-Mitjans M, *et al.* Surgical sealant for preventing air leaks after pulmonary resections in patients with lung cancer. *Cochrane Database of Systematic Reviews* 2010, Issue 1. Art. No.: CD003051. DOI: 10.1002/14651858.CD003051.pub3.
7. Singhal S, Shrager JB. Should buttresses and sealants be used to manage pulmonary parenchymal air leaks? *J Thorac Cardiovasc Surg* 2010; 140 (6): 1220–1225.

Chapter 12

Thoracoscopy under Local Anaesthesia and Medical Management of Pleural Disease

Nicholas Denny and Mohamed Munavvar

“Daring ideas are like chessmen moved forward, they may be beaten but they may start a winning game”

Johann Wolfgang Goethe (1749 - 1832)

History of thoracoscopy

In 1910, Hans-Christian Jacobaeus, the father of thoracoscopy, published the first article describing the clinical application of this technique [1]. 'Über die Möglichkeit die Zystoskopie bei Untersuchung seröser Höhlungen anzuwenden' (on the possibility of using a cystoscope to examine the serous cavities) detailed the exploration of the pleural cavity in 2 patients with tuberculous pleural effusions. Inspired by the 'vast potential' of the method, Jacobaeus employed thoracoscopy enthusiastically for both diagnostic and therapeutic purposes in pleural effusions, empyema and pneumothorax [2, 3, 4]. Over the next 30 years, intrapleural thoracoscopic lysis quickly became the most common application of thoracoscopy but, following the discovery and use of anti-tuberculous chemotherapy in the 1950s, interventions with thoracoscopy were less commonly utilised. In spite of this, a number of European centres continued to practice intrapleural thoracoscopic lysis and in doing so kept thoracoscopy within the domain of the chest physician.

Thoracoscopy, to this point, had been performed solely using the rigid scope. This provided good optics and size of biopsies but often required a second port of entry to allow instrumentation. In contrast to bronchoscopy, these instruments were unfamiliar to the majority of chest physicians outside of established units. Therefore, in 1973, Oldenburg and Newhouse attempted to compare thoracoscopy using a flexible bronchoscope with a rigid thoracoscope [5]. Unfortunately, the diagnostic accuracy of the flexible bronchoscope was inadequate and the technique was discontinued. This experience and that of others demonstrated that a degree of rigidity was necessary to enable operators to navigate within the pleural space. As a result, in 1997, the first semi-flexible thoracoscope, which combined the flexibility of the bronchoscope with the rigidity of the conventional thoracoscope, was developed by Olympus. In a small study of 24 patients with pleural effusion of unknown cause, the semi-flexible thoracoscope was found to have a sensitivity of 81% [6]. However, the small diameter of the instrument channel restricted the size of the biopsies that could be obtained and consequently rigid thoracoscopy remained the superior technique. The next generation of semirigid thoracoscope, the XLTF-240, was developed by Olympus in 2002. This has a larger working channel of 2.8mm, compares favourably with rigid thoracoscopy and is widely used for a range of pleural conditions.

The Current State of Thoracoscopy

Since the development of the semi-rigid thoracoscope, the practice of medical thoracoscopy has expanded further. Medical thoracoscopy is also known as pleuroscopy or local anaesthetic thoracoscopy. This is in contrast to minimally invasive or video assisted thoracoscopic surgery (VATS). This procedure, developed in the 1990s by thoracic surgeons, built on the success of minimally invasive abdominal surgery and was applied to pleuropulmonary disorders. Although VATS can replace medical thoracoscopy, the technique requires general anaesthesia, single lung ventilation and an operating theatre. Consequently, medical thoracoscopy is less invasive, cheaper and preferred to VATS as a diagnostic tool for a number of indications.

The British Thoracic Society (BTS) guidelines set the standard of care for thoracoscopy in the UK [7]. These guidelines outline the main indications for medical thoracoscopy, which are the investigation of a pleural effusion of unknown aetiology (PEUE) following non-diagnostic pleural aspiration, and treatment of recurrent pleural effusion with talc poudrage. At present, most medical thoracoscopy in the UK is predominantly restricted

to these indications but the BTS acknowledges a number of other conditions in which thoracoscopy may be employed, including empyema and pneumothorax [7].

Local Anaesthetic Thoracoscopy and Diagnosis

Diagnostic pleural aspiration is the primary means of assessing pleural fluid and its findings are used to guide further investigation. Despite the biochemical, microbiological and cytological evaluation of pleural fluid, the aetiology of the pleural effusion remains unknown in approximately 40-60% of cases and repeat sampling does not increase diagnostic yield substantially [8, 9].

Traditionally, the next step to investigate a PEUE has been blind pleural biopsy. However, this procedure also has a poor sensitivity for PEUE and a number of studies have shown that for unselected pleural disease, the sensitivity of blind pleural biopsy alone is between 38%-68%. [10-15]. In addition to poor performance characteristics, blind pleural biopsy is also associated with a complication rate in excess of 10%, with pneumothorax being a relatively frequent occurrence [9, 15]. Therefore, alternative procedures such as image-guided closed pleural biopsy, thoracoscopy or VATS are preferred. Today, the role of blind pleural biopsy has been relegated to 'further investigation of pleural disease' in the resource-limited setting in which neither image guidance nor thoracoscopy are available [16].

Comparison of Image-Assisted Closed Pleural Biopsy and Local Anaesthetic Thoracoscopy

The ability to intervene with talc poudrage or other therapy is one of the main advantages of medical thoracoscopy compared to image-guided closed pleural biopsy. Imaging techniques to guide pleural biopsy include computed tomography (CT) and transthoracic ultrasonography. Several studies have shown that, with an experienced interventional radiologist, CT-guided pleural biopsy in unselected pleural effusions has a sensitivity of approximately 87% and specificity of 100% [10, 17, 18, 19]. However, many of these studies [10, 17] reported a lower sensitivity, between 75-82%, for CT-guided pleural biopsy in cases in which the pleural thickness was less than 1cm or for certain conditions, such as mesothelioma [17]. In contrast, medical thoracoscopy had an overall sensitivity of 94% and specificity of 100% for unselected pleural effusion when compared directly with CT-guided pleural biopsy [17]. It was also more sensitive for the diagnosis of mesothelioma and where the pleural thickness was less than 1cm.

Medical thoracoscopy is also a safe procedure in the majority of patients. Combined data from over 4700 cases of medical thoracoscopy showed a mortality rate of 0.34% [7]. However, 9 out of the 16 deaths that occurred involved the use of non-graded talc poudrage in a single study from the USA [20]. If this unusual study is excluded, the mortality rate of medical thoracoscopy is 0.16% or less than 1/500. Major complications, such as empyema, pneumothorax, haemorrhage and pneumonia, occur in 1.8% of cases and minor complications, such as subcutaneous emphysema, post-procedure fever and skin infection occur in 7.3% [7]. These complication rates are similar to less invasive techniques, such as CT-guided biopsy and a direct comparison demonstrated no significant difference across a range of potential complications [17]. Therefore, in comparison to image-guided closed pleural biopsy, medical thoracoscopy demonstrates a similar safety profile and a trend towards a more accurate diagnosis. It also affords the ability to introduce therapy, such as talc poudrage, amongst other interventions.

Comparison of Semi-Rigid and Rigid Thoracoscopy under Local Anaesthesia

Recently, two head-to-head randomized controlled trials comparing semi-rigid thoracoscopy and rigid thoracoscopy under local anaesthetic and conscious sedation have been carried out [21, 22]. The first of these trials, conducted in a single centre in Slovenia, randomized 84 patients with PEUE to either rigid or semi-rigid thoracoscopy [21]. Pathologists were blinded to the procedure performed and reported on the quality and size of the biopsy as well as the diagnosis. Although the average size of the biopsy specimens obtained in semi-rigid thoracoscopy was significantly smaller compared to rigid thoracoscopy, there was no significant difference in the quality of the specimens. More importantly, the overall diagnostic accuracy of semi-rigid thoracoscopy was 97.6%, showing that for diagnostic purposes, semi-rigid thoracoscopy is not inferior to rigid thoracoscopy [21].

This was further confirmed in a second trial, conducted in a single centre in India that randomised 90 patients with PEUE to either rigid or semi-rigid thoracoscopy [22]. In contrast to the first trial, several chest physicians with a range of experience carried out the procedures.

Again, the biopsy size was significantly smaller for semi-rigid thoracoscopy but the overall diagnostic accuracy in a post-hoc analysis was 94.3% and not significantly different to rigid thoracoscopy. Yet, unlike the previous trial in which patients with extensive pleural adhesions were excluded [21], dense adhesions meant that 10 patients initially randomised to semi-rigid thoracoscopy eventually required a rigid thoracoscopy. This is because the semi-rigid thoracoscope was only used for pleural biopsy and not for adhesiolysis in this study [22]. Therefore, in the intention-to-treat analysis, the diagnostic accuracy of semi-rigid thoracoscopy was only 73.3%, significantly lower than rigid thoracoscopy. However, in this trial, almost two thirds of the cases were tuberculous effusions or fibrinous pleuritis many of which presented late in the course of their illness [22]. This is in contrast to the previous trial in which over half of the cases were malignant effusions. The difference in the disease burden and operator skill between the two studies is likely to account for the relatively poor sensitivity of the flexible procedure in the intention-to-treat analysis.

These two studies have also demonstrated that, when performed under local anaesthesia and conscious sedation, both rigid and semi-rigid thoracoscopy have comparable diagnostic accuracy with no procedure-related mortality and similar rates of major and minor complications of 7.7% and 13.6% respectively [21, 22]. In this context, the advantage of semi-rigid thoracoscopy is its similarity to the flexible bronchoscope, which makes it more appealing to chest physicians.

Diagnostic Advances in Local Anaesthetic Thoracoscopy: Narrow Band Imaging, Autofluorescence Imaging and Novel Biopsy Techniques

Thoracoscopy has a further advantage over image-guided closed pleural biopsy because it permits direct visualisation of the pleura (Figure 1) and the application of novel imaging and biopsy techniques. New techniques to better identify early cancerous changes and enhance diagnostic yield have been practised in bronchoscopy for the last decade [23]. These techniques include auto-fluorescence imaging (AFI) and narrow band imaging (NBI)

(Figure 2). To date, there are only a few studies that explore the use of either AFI or NBI in medical thoracoscopy [24, 25, 26, 27].

A recent pilot study compared the use of AFI to standard white light medical thoracoscopy in 37 patients with PEUE [24]. In this trial, patients were initially subject to white light medical thoracoscopy and then subsequently to AFI medical thoracoscopy. Auto-fluorescence imaging identified malignant lesions in an additional 5 cases that were missed with white light and the diagnostic sensitivity of AFI for the detection of pleural disease was 100%, which was significantly better than white light medical thoracoscopy [24]. Moreover, there was no significant difference between the specificity of the two procedures.

One study published in 2009 compared the diagnostic performance of white light and NBI for the detection of irregular vascular patterns, a surrogate marker of malignant disease. This demonstrated that NBI had a much higher diagnostic accuracy compared to white light for the detection of abnormal vasculature, in particular for flat pleural lesions [27]. However, high definition white light video imaging has similar operating characteristics and has, at present, superseded the use of NBI. In summary, there are a number of promising enhanced imaging techniques being applied in medical thoracoscopy but further well-designed prospective randomised controlled trials of their diagnostic performance are required before recommendations can be made.

One of the main disadvantages of semi-rigid thoracoscopy compared to its rigid counterpart is the size of the biopsy obtained. As previously discussed, the diagnostic performance of both techniques is not significantly different. Nevertheless, the diagnostic yield of rigid thoracoscopy shows a non-significant trend

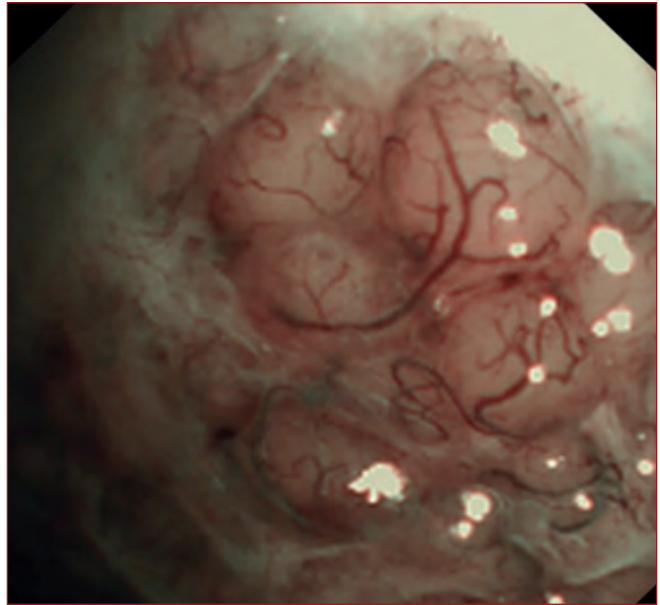


Fig 1: Thoracoscopic image of pleural nodules (White light)

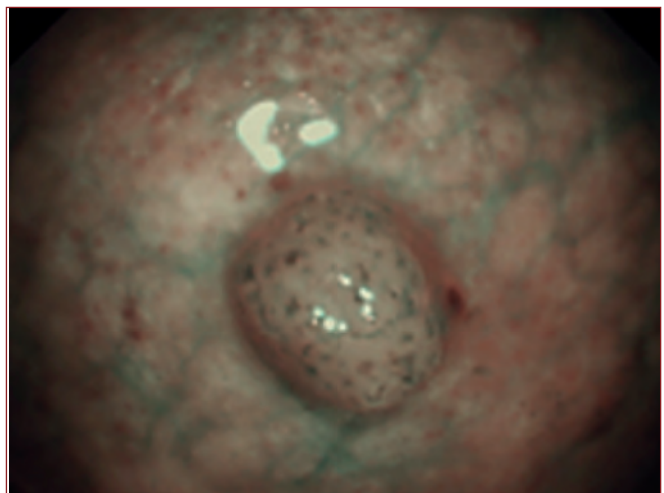


Fig 2: Thoracoscopic image of pleural nodule (Narrow band imaging)

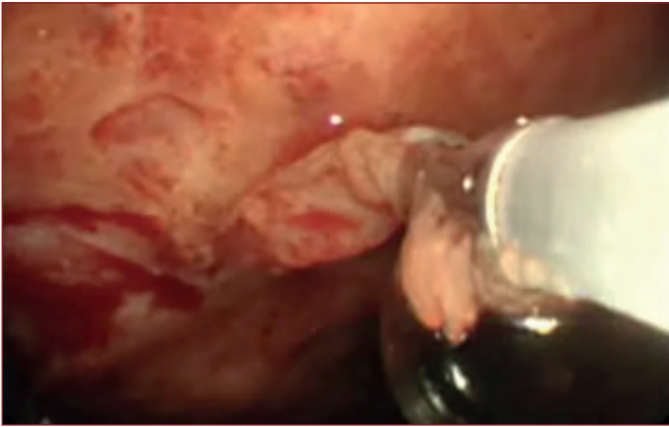


Fig 3: Biopsy performed through a semi-rigid thoracoscope

forceps biopsy [29]. Moreover, cryobiopsy was very safe with no significant difference in complication rate compared to flexible forceps biopsy. However, more studies are necessary before these biopsy techniques are adopted widely.

towards superiority. Novel biopsy techniques, including insulated tip diathermic knife and cryobiopsy, have recently been developed and, in early pilot studies, demonstrate better quality and larger size biopsy samples compared to standard flexible forceps [28, 29] (Figure 3). For example, in a recent study on the safety and feasibility of cryobiopsy in medical thoracoscopy, the median biopsy size was 10mm following cryobiopsy and only 4mm following flexible

Local Anaesthetic Thoracoscopy and Therapeutic Applications

Talc poudrage for malignant pleural effusion

Management of a symptomatic malignant pleural effusion usually requires further intervention in the form of pleurodesis. Originally this could be achieved by instillation of talc slurry via a chest drain or by VATS pleurodesis. Talc slurry pleurodesis has a 70-80% initial success rate [20, 30, 31], however, this gradually falls to 69.6% at 90 days and 62.2% long term [31]. Talc can also be administered during medical thoracoscopy in cases of presumed malignant pleural effusion [30]. There are few adequately designed comparative studies of talc slurry pleurodesis and thoracoscopic talc poudrage (Figure 4)

A non-randomised review [31] demonstrated a clear benefit to talc poudrage at 90 days but talc slurry was only administered in patients whose performance status made them unsuitable for thoracoscopy. In contrast, a large randomised trial [20] showed no overall difference between talc slurry and thoracoscopic poudrage at 30 days. However, more than 40% of patients dropped out of this trial before the 30-day end point and follow up to 90 days was not recorded. Therefore, it is currently unclear whether talc poudrage is more effective than talc slurry and the most recent BTS guidelines on the management of malignant effusion recommend either [30]. A UK-based randomised controlled trial is currently underway to establish if talc slurry and poudrage are equivalent in outcome or if one is superior [33].

Currently, the main benefit of talc poudrage by medical thoracoscopy over the other available methods for pleurodesis is that diagnosis and therapy can be carried out in the same sitting. This minimises the burden to the patient in terms of waiting time, days spent in hospital and invasive procedures. Moreover, it reduces the number of thoracic procedures, which may be important in mesothelioma because recurrent intervention can increase the risk of malignant seeding.

Empyema and pneumothorax

In contrast to Europe, the role of medical thoracoscopy in other therapeutic contexts, such as treatment of pneumothorax and empyema, remains limited in the UK [7]. However, there is some evidence to support medical thoracoscopy in these settings, although there is currently no direct comparison with the current gold standard of VATS.

A number of retrospective cohort studies have evaluated the efficacy of medical thoracoscopy in the treatment of empyema [33, 34, 35]. In the largest of these studies [33], over 120 patients with a diagnosis of multiloculated empyema confirmed by pleural fluid analysis and ultrasonography were reviewed. In over 80% of the cohort, the empyema was parapneumonic and a microbiological diagnosis was obtained in almost 50% of cases, with the majority being due to Gram positive or mixed infections. Medical thoracoscopy was successful without requirement for further intervention in 115 of the 127 cases and there were no deaths or related chronic morbidity highlighting that medical thoracoscopy has a role to play in the treatment of empyema [33]. This finding has been replicated in 2 smaller retrospective cohort studies with success rates of between 80-85% for treatment of empyema without further intervention [34, 35].

Local anaesthetic thoracoscopy has also been proven to be effective in the treatment of primary spontaneous pneumothorax (PSP). A single randomised controlled trial comparing talcage by medical thoracoscopy and intercostal tube drainage in 108 patients with PSP showed that thoracoscopic talcage was more effective both during the hospital admission and over 5-year follow up [36]. Over 30% of patients who underwent intercostal tube drainage had another episode of pneumothorax within 5 years, whereas only 5% of those undergoing thoracoscopic talcage suffered a recurrence. Complication rates, pain control with opiates and cost-effectiveness for the initial hospital admission were similar for the two groups but, in the long term, thoracoscopic talcage was more cost effective because there were fewer recurrences.

There are currently no randomised clinical trials comparing local anaesthetic thoracoscopy with the gold standard of VATS for empyema or PSP. This technique enables more detailed exploration of the pleural cavity, manipulation of the visceral pleura and resection of unhealthy lung tissue. Moreover, VATS is generally safe with an excellent outcome. Therefore, at present, the BTS only recommends the use of medical thoracoscopy in patients in whom surgery is deemed unsuitable [7].

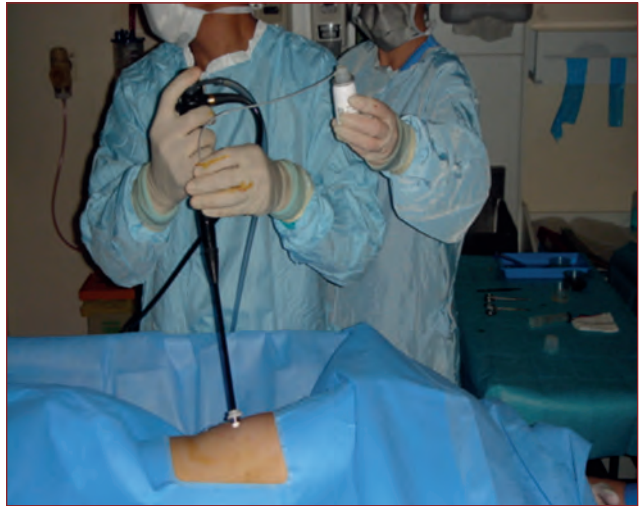

Fig 4: Semi-rigid thoracoscope in operation. Talc poudrage being performed.

Conclusions

Medical thoracoscopy has been practised for almost 150 years but it is only the last 20 years that have engendered the same pioneering spirit and excitement of its early development under Hans-Christian Jacobaeus. A number of studies have demonstrated that semi-rigid thoracoscopy is an accurate and safe diagnostic procedure for pleural disease and compares favourably with rigid thoracoscopy in randomised controlled trials. Novel imaging and biopsy techniques are likely to further enhance the diagnostic performance of semi-rigid thoracoscopy and, when combined with rapid on site pathological evaluation, will result in a highly accurate and efficient procedure. Just as the therapeutic application of medical thoracoscopy burgeoned under Jacobaeus, the therapeutic role for modern medical thoracoscopy is also expanding. Talc poudrage for malignant pleural effusion is extremely effective in preventing recurrence for at least 3 months or longer and is also a very safe procedure. Moreover, other therapeutic applications of medical thoracoscopy are likely to become more widespread following successful randomised controlled trials comparing this technique to current gold standard alternatives. In conclusion, like the early 20th century, the next decade represents another exciting period in medical thoracoscopy with the opportunity for innovation, exploration and crossing boundaries.

References

1. Jacobaeus HC. Über die Möglichkeit die Zystoskopie bei Untersuchung seröser Höhlungen anzuwenden. *Münch Med Woch* 1910; 57: 2090–2092.
2. Jacobaeus HC. Kurze Übersicht über meine Erfahrungen der Laparo-Thorakoskopie. *Münch Med Woch* 1911; 58: 2017–2019.
3. Jacobaeus HC. Endopleural operations by means of a thoracoscope. *Beitr Klin Tuberk* 1915; 35: 1–9.
4. Jacobaeus HC. The cauterization of adhesions in artificial pneumothorax therapy of tuberculosis. *Amer Rev Tuberc* 1922; 6: 871–897.
5. Oldenberg FA, Newhouse M. A safe and accurate diagnostic procedure using the rigid thoracoscope and local anaesthesia. *Chest* 1979; 75:45-50.
6. McClean AN, Bicknell SR, McAlpine LG, *et al.* Investigation of pleural effusion: an evaluation of the new Olympus LTF semi-flexible thoracofibroscope and comparison with Abram's needle biopsy. *Chest* 1998; 114(1):150-153.
7. Rahman NM, Ali NJ, Brown G, *et al.* British Thoracic Society Pleural Disease Guideline Group. Local anaesthetic thoracoscopy: British Thoracic Society Pleural Disease Guideline 2010. *Thorax*. 2010 Aug; 65 Suppl 2:ii54-60. doi: 10.1136/thx.2010.137018.
8. Maskell NA, Butland RJ. BTS guidelines for the investigation of a unilateral pleural effusion in adults. *Thorax* 2003; 58(Suppl 2):ii8e17. (4).
9. Chakrabarti B, Ryland I, Sheard J, *et al.* The role of Abrams percutaneous pleural biopsy in the investigation of exudative effusions. *Chest* 2006 Jun; 129(6):1549-55.
10. Maskell NA, Gleeson FV, Davies RJO. Standard pleural biopsy versus CT-guided cutting-needle biopsy for diagnosis of malignant disease in pleural effusion: a randomized controlled trial. *Lancet*. 2003; 361: 1326-30.
11. Prakash UB, Reiman HM. Comparison of needle biopsy with cytologic analysis for the evaluation of pleural effusion: analysis of 414 cases. *Mayo Clin Proc*. 1985 Mar; 60(3):158-64.

12. Nance KV, Shermer RW, Askin FB. Diagnostic efficacy of pleural biopsy as compared with that of pleural fluid examination. *Mod Pathol* 1991; 4: 320–24.
13. McLean AN, Bicknell SR, McAlpine LG, *et al.* Investigation of pleural effusion: an evaluation of the new Olympus LTF semiflexible thoracofibroscope and comparison with Abram's needle biopsy. *Chest*. 1998 Jul; 114(1):150-3.
14. Poe RH, Israel RH, Utell MJ, *et al.* Sensitivity, specificity, and predictive values of closed pleural biopsy. *Arch Intern Med*. 1984 Feb; 144(2):325-8.
15. Haridas N, Chetambath R. Medical Thoracoscopy vs Closed Pleural Biopsy in Pleural Effusion: A Randomised Controlled Study. *J Clin Diagn Res*. 2014 May; 8(5):MC01-4.
16. Bhattacharya S, Bairagya TD, Das A, *et al.* Closed pleural biopsy is still useful in the evaluation of malignant effusion. *J Lab Physicians*. 2012 Jan; 4(1):35-8.
17. Metintas M, Ak G, Dundar E, *et al.* Medical thoracoscopy vs CT scan-guided Abrams pleural needle biopsy for diagnosis of patients with pleural effusions: a randomized, controlled trial. *Chest* 2010; 137: 1362–8.
18. Niu XK, Bhetuwal A, Yang HF. CT-guided core needle biopsy of pleural lesions: evaluating diagnostic yield and associated complications. *Korean J Radiol*. 2015 Jan-Feb; 16(1):206-12.
19. Cao YY, Fan N, Xing F, Xu LY *et al.* Computed tomography-guided cutting needle pleural biopsy: Accuracy and complications. *Exp Ther Med*. 2015 Jan; 9(1):262-266. Epub 2014 Nov 18.
20. Dresler CM, Olak J, Herndon JE, *et al.* Phase III intergroup study of talc poudrage vs talc slurry sclerosis for malignant pleural effusion. *Chest* 2005; 127:909e15. (1L).
21. Rozman A, Camlek L, Marc-Malovrh M, *et al.* Rigid versus semi-rigid thoracoscopy for the diagnosis of pleural disease: a randomized pilot study. *Respirology*. 2013 May; 18(4):704-10.
22. Dhooria S, Singh N, Aggarwal AN *et al.* A randomized trial comparing the diagnostic yield of rigid and semirigid thoracoscopy in undiagnosed pleural effusions. *Respir Care*. 2014 May; 59(5):756-64.
23. Zaric B, Stojisic V, Sarcevic T, *et al.* Advanced bronchoscopic techniques in diagnosis and staging of lung cancer. *J Thorac Dis*. 2013 Sep; 5 Suppl 4:S359-70.
24. Wang F, Wang Z, Tong Z, *et al.* A Pilot Study of Autofluorescence in Diagnosis of Pleural Disease. *Chest*. 2014 Nov 20. doi: 10.1378/chest.14-1351.
25. Pikin O, Filonenko E, Mironenko D, *et al.* Fluorescence thoracoscopy in the detection of pleural malignancy. *Eur J Cardiothorac Surg*. 2012 Mar; 41(3):649-52.
26. Liman ST, Elicora A, Topcu S, *et al.* Value of autofluorescence in video-assisted thoracoscopic surgery in pleural diseases. *Thorac Cardiovasc Surg*. 2013 Jun; 61(4):350-6.
27. Ishida A, Ishikawa F, Nakamura M, *et al.* Narrow band imaging applied to pleuroscopy for the assessment of vascular patterns of the pleura. *Respiration*. 2009;78(4):432-9.
28. Sasada S, Kawahara K, Kusunoki Y, *et al.* A new electrocautery pleural biopsy technique using an insulated-tip diathermic knife during semirigid pleuroscopy. *Surg Endosc*. 2009 Aug;23(8):1901-7.
29. Thomas R, Karunarathne S, Jennings B, *et al.* Pleuroscopic cryoprobe biopsies of the pleura: a feasibility and safety study. *Respirology*. 2015 Feb; 20(2):327-32.
30. Roberts ME, Neville E, Berrisford RG, *et al.* BTS Pleural Disease Guideline Group. Management of a malignant pleural effusion: British Thoracic Society Pleural Disease Guideline 2010. *Thorax*. 2010 Aug; 65 Suppl 2:ii32-40.

31. Stefani A, Natali P, Casali C, *et al.* Talc poudrage versus talc slurry in the treatment of malignant pleural effusion. A prospective comparative study. *Eur J Cardiothorac Surg.* 2006 Dec; 30(6):827-32.
32. Bhatnagar R, Laskawiec-Szkonter M, Piotrowska HE, *et al.* Evaluating the efficacy of thoracoscopy and talc poudrage versus pleurodesis using talc slurry (TAPPS trial): protocol of an open-label randomised controlled trial. *BMJ Open* 2014;4:e007045 doi: 10.1136/bmjopen-2014-007045.
33. Brutsche MH, Tassi GF, Györik S, *et al.* Treatment of sonographically stratified multiloculated thoracic empyema by medical thoracoscopy. *Chest.* 2005 Nov; 128(5):3303-9.
34. Ravaglia C, Gurioli C, Tomassetti S, *et al.* Is Medical Thoracoscopy Efficient in the Management of Multiloculated and Organized Thoracic Empyema? *Respiration.* 2012; 84(3):219-24.
35. Ohuchi M, Inoue S, Ozaki Y, *et al.* Single-trocar thoracoscopy under local anesthesia for pleural space infection. *Gen Thorac Cardiovasc Surg.* 2014 Aug; 62(8):503-10.
36. Tschopp JM, Boutin C, Astoul P, *et al.* ESMEVAT team. (European Study on Medical Video-Assisted Thoracoscopy). Talcage by medical thoracoscopy for primary spontaneous pneumothorax is more cost-effective than drainage: a randomised study. *Eur Respir J.* 2002 Oct; 20(4):1003-9.]

Chapter 13

Current Oncological Options for the Treatment of Mesothelioma

Diego Marquez-Medina and Sanjay Popat

The real world is just a special case of the theoretical

Current Systemic Therapy Options

Malignant mesothelioma (MM) is a relatively rare and geographically dependent malignancy with a rising incidence, usually in association with previous asbestos exposure. Over the past 20 years, many small phase 2 trials have confirmed the activity of and benefit from chemotherapy in terms of symptom control, response rate and survival. Chemotherapy is currently the standard of care and the only modality proven to improve survival in a randomized trial with response rates of around 10% and 25% for anthracycline- and platinum-based regimes, respectively [1].

Since the use of chemotherapy has become established for MM, several questions around its use have been investigated. The role of early versus delayed chemotherapy was investigated in the MED Trial [2]. Forty-three patients were randomized to receive either immediate chemotherapy with mitomycin, vinblastine, and platinum (MVP) or best supportive care with delayed chemotherapy at symptomatic progression. Whilst all patients in the “immediate” arm received chemotherapy, only 77% of patients in the “delayed” arm received it for a variety of reasons, including clinical deterioration. Time to symptom progression favoured immediate chemotherapy, as did median overall survival (14 months vs. 10 months, $p=0.1$), although not statistically significant likely due to the small sample size. Thus, when indicated, chemotherapy should ideally be administered early rather than later.

In the modern era, platinum plus pemetrexed was established as the standard chemotherapy regime for pleural MM based on the phase 3 JMCH Trial [3]. In this, Vogelzang *et al.* randomized 452 patients to receive first-line cisplatin versus cisplatin plus pemetrexed, a third-generation anti-folate. The addition of pemetrexed significantly increased the overall response rate from 16.7% to 41.3% and the median survival from 9.3 to 12.1 months in comparison to cisplatin alone (HR=0.77, $p=0.02$). This was also associated with a superior time to tumour progression and improvements in quality of life measures, leading to licensing of pemetrexed.

Carboplatin is a more tolerable platinum analogue than cisplatin. It produces considerably less emesis, nephrotoxicity and neurotoxicity, although it is more myelosuppressive. The role of carboplatin plus pemetrexed was evaluated in the International Pemetrexed Expanded Access Program [4] in which 3,142 patients with pleural MM were treated with cisplatin plus pemetrexed ($n=745$), carboplatin plus pemetrexed ($n=752$), or pemetrexed alone. The 26.3% response rate observed for cisplatin plus pemetrexed was very similar to 21.7% reported for carboplatin plus pemetrexed; disease control rates were also similar. For time-to-event endpoints, time-to-progressive disease (7 vs. 6.9 months) as well as one-year survival rate (63.1% vs. 64%) were similar in both cisplatin- and carboplatin-treated patients, respectively. Thus, carboplatin is an alternative to cisplatin if required.

Having established platinum plus pemetrexed regimes as standard systemic therapy, many current ongoing clinical trials are evaluating new therapies and strategies to improve MM survival, most of them based on novel insights into biology and drug delivery.

Targeting Mesothelioma Molecular Aberrations

Major advances in understanding the biology of non-small cell lung cancer have resulted in personalized therapy guided by the tumour molecular profile as the standard of care [5]. Will the same be observed in MM? Over recent years, two major molecular aberrations in MM have been characterized. The first is NF2 inactivation (neurofibromatosis type 2

gene) [6]. Around 40% of MM tumours harbour mutations in NF2 that inactivate its protein, Merlin (Moesin-ezrin-radixin-like protein). Loss of Merlin function has been proposed to lead to abnormal MM cell signalling through a number of pathways, including mTOR activation (mechanistic Target of Rapamycin). This rationale underpins trials of mTOR inhibitors such as everolimus alone [7] or in combination with PIK3CA inhibitors. The PIK3CA inhibitor, GDC0980, has been reported to obtain responses in vitro and in 25% of MM [8, 9].

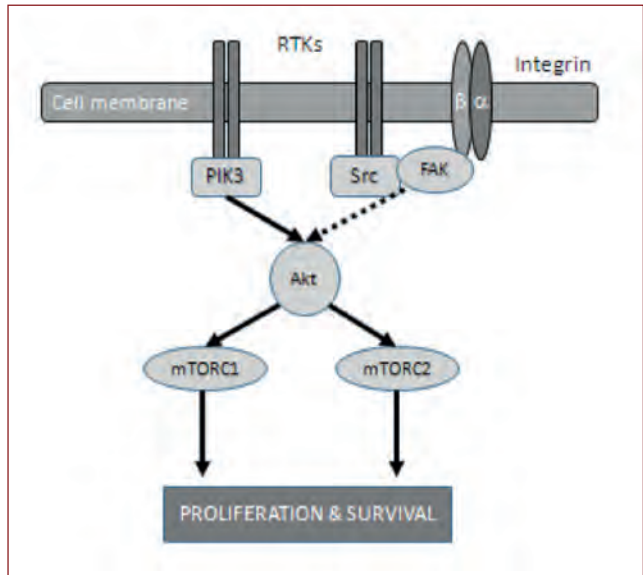


Fig 1: Schematic demonstrating cell membrane based receptor tyrosine kinase (RTK) signalling through FAK via integrins to activate Akt and mTOR resulting in cell proliferation and signalling.

NF2 loss may also potentially promote carcinogenesis by deregulating the YAP protein, and by activation of carcinogenic pathways such as Hippo, ERK and FAK signalling. FAK is a potent stem-cell factor signal and represents a potentially major therapeutic MM target (Figure 1). The FAK inhibitor, defactinib, is currently being investigated in the COMMAND Trial as maintenance therapy for non-progressive pleural MM after platinum-pemetrexed induction (NCT01870609).

The second major molecular aberration characterized in MM is at the BAP1 gene. Here, inherited germline BAP1 mutations have been shown to cause ocular melanoma, atypical melanocytic naevi and some familial cases of MM, inherited in an autosomal dominant manner. Such MM families have an increased risk of ocular and cutaneous melanoma [10, 11]. Whilst a number of other malignancies such as breast, lung, ovarian or renal cancers have been identified in these families, it is not known if they are causally related or not. Clinical correlates of germline BAP1 mutant MM are currently being evaluated. An epidemiological analysis of 10,556 MM from the Surveillance, Epidemiology and End Results (SEER) database reported a seven-fold higher overall survival in patients with germline BAP1-mutant MM in comparison with the whole series (five-year overall survival 47% vs. 6.7%, respectively) [11].

Whilst the number of MMs attributable to germline BAP1 inactivation is low (around 5%), somatic BAP1 inactivation is frequently observed in 40-60% of tumours with a recent comprehensive analysis indicating that BAP1 is dysregulated through a number of different mechanisms at a rate of around 65% [12]. Nevertheless, BAP1 inactivation in MM has not been associated with any obvious drug target and further work in this area is continuing.

A metabolic approach currently under evaluation is through targeting amino acid utilization in MM. Around 60% of pleural MM have either lost or have very low arginosuccinate synthase expression, rendering the cells sensitive to arginine depletion through arginine

deletion therapy such as pegylated arginine deaminase (ADI-PEG) [13]. This has been demonstrated in a proof-of-principle study of ADI-PEG in arginosuccinate synthase negative pleural MM, with tumour responses observed (NCT01279967) [14, 15]. This drug is now being evaluated in combination with chemotherapy in the TRAP Study (NCT02029690).

Another approach being taken to target abnormal MM proteins is by inhibiting the cellular chaperone HSP90 (heat shock protein 90). The HSP90 inhibitor, ganetespib, is being evaluated in combination with cisplatin-pemetrexed in the MESO 2 Trial (NCT01590160).

Targeting Tumour Surface Proteins Directly

Another therapeutic approach taken is to target proteins specifically expressed on MM. The tumour differentiation protein, mesothelin, is expressed on most normal mesothelial surfaces and in the epithelioid sub-type of MM. Advances in immunoconjugate drug therapy have allowed the development of an anti-mesothelin immunotoxin called SS1P. This therapy combines a murine anti-mesothelin variable region antibody fragment linked to *Pseudomonas* exotoxin A [16]. In a phase 1 study, SS1P was administered with pentostatin and cyclophosphamide in order to deplete B and T cells and to reduce the production of anti-SS1P neutralizing antibodies. Durable partial remissions were observed in 3 of 10 chemo-refractory patients with pleural MM [17] and this drug is now being developed further in combination with chemotherapy. In combination with cisplatin plus pemetrexed, responses were observed in 12 out of 20 evaluable patients (60%) [18].

Another anti-mesothelin conjugate is anetumab ravtansine (BAY 94-9343), a fully human anti-mesothelin antibody coupled to a microtubule targeting toxophore (DM4) [19]. A single agent dose escalation phase 1 study has been completed reporting tumour responses and the full results are eagerly awaited [20].

MM expresses high levels of VEGF-A and targeting angiogenesis, a well-recognized therapeutic modality, has been investigated for the treatment of the disease. Bevacizumab is a recombinant humanized monoclonal antibody that blocks angiogenesis by inhibiting vascular endothelial growth factor A (VEGF-A). The initial randomized phase 2 trial of bevacizumab in conjunction with cisplatin plus gemcitabine reported no benefit



in response rate (24.5% vs. 21.7%, $p=0.74$), progression-free survival (6.9 months vs. 6 months, $p=0.88$) and overall survival (15.6 months vs. 14.7 months, $p=0.91$) by adding bevacizumab to chemotherapy [21]. Whether this is a true reflection that targeting angiogenesis is not a viable therapeutic strategy for MM or simply reflects that the optimal partner chemotherapy combination with bevacizumab is not gemcitabine, awaits further clarification. At the American Society of Clinical Oncology meeting 2015, results from the highly anticipated IFCT-GFPC-0701 MAPS phase III randomized trial of cisplatin plus pemetrexed with or without bevacizumab were presented. In this, patients were randomized to receive either standard cisplatin-pemetrexed chemotherapy for 6 cycles or the same with bevacizumab, and then maintenance bevacizumab until progression. A significant and clinically meaningful benefit for the addition of bevacizumab was observed (median 2.75 months benefit, $p=0.01$), and quality of life maintained. This important trial is the first major drug breakthrough in mesothelioma for 12 years, potentially representing a new standard of care, and has validated a new drug target. Trials of other angiogenesis inhibitors including nintedanib and cediranib are ongoing, with results also eagerly awaited.

Role of Immunotherapy in Mesothelioma

Immunotherapy with immune checkpoint inhibitors represents a novel anti-cancer therapy and has been identified by the journal *Science* as “Breakthrough of the Year 2013” [21]. These agents, such as the CTLA4 inhibitors (ipilimumab and tremelimumab), the PD1 inhibitors (pembrolizumab, nivolumab), and the PDL1 inhibitors (MPDL3280A, MEDI4736), can overcome tumour-associated immune tolerance resulting in immune-mediated tumour cell death.

Due to their novel mechanism of action, the pattern and nature of anti-tumour activity of the immune checkpoint inhibitors observed thus far in other tumour types distinguishes them from conventional therapies. The efficacy of traditional cytotoxic chemotherapy and kinase inhibitors is typified by an increase in median survival, but resistance ultimately occurs resulting in little difference in the long-term survival rates. Unlike this, the immune checkpoint inhibitors do not tend to markedly increase median survival but tend to increase the long-term survival rate, as these drugs result in very durable responses in patients sensitive to this therapeutic modality, but they are not active in all patients [23]. This has been observed in melanoma where ipilimumab is licensed, resulting in almost doubling of the five-year survival rate from 8.8% to 18.2% with minor improvement in the median overall survival [24].

Thus far, limited evidence of activity of the immune checkpoint inhibitors in MM has been observed. In a small single-arm phase 2 trial of tremelimumab administered every 90 days to 29 patients with relapsed MM, two (7%) durable responses were observed with a two-year survival rate of 40% [25], indicating a potentially large benefit when compared with the previously reported 15% two-year survival rate obtained from vinorelbine [26].

Tumour or stromal PDL1 expression currently seems to be a biomarker that might discriminate for responses to PD1 and PDL1 inhibitors in some tumour types. Both a North American and a Spanish study have reported that PDL1 expression is associated with poorer survival in pleural MM [27, 28]. Preliminary data on the activity of pembrolizumab in 25 patients with PDL1-expressing tumours reported an unprecedented 28% response rate and a durable 76% disease control rate at the 2015 American Association for Cancer Research meeting [29].

Conclusions

Whilst current oncological options for MM are limited to platinum plus pemetrexed chemotherapy, a number of new drugs are in development with preliminary proof-of-principle data demonstrating promising activity. Coupled with advances in better understanding the molecular architecture of MM, current oncological options for MM will undoubtedly change markedly over the next 5-10 years.

Acknowledgements

SP is a consultant to Astra-Zeneca, BMS, Boehringer Ingelheim, Lilly, Pfizer, Roche, MSD, and has received travel expenses from Boehringer Ingelheim, Pfizer, and research funding from Boehringer Ingelheim, Otsuka, Pierre Fabre. SP acknowledges NHS funding to the RMH/ICR NIHR Biomedical Research Centre.

DM has participated in scientific events and advisories promoted by Astra-Zeneca, BMS, Boehringer Ingelheim, Lilly, Pfizer, Roche, MSD, Boehringer Ingelheim, Pierre-Fabre, and

Pfizer. His collaboration with the Royal Marsden Hospital Lung Unit was supported by a grant from the Spanish Society of Medical Oncology.

References

1. Fennell DA, Gaudino G, O'Byrne KJ, *et al.* Advances in the systemic therapy of malignant pleural mesothelioma. *Nat Clin Pract Oncol.* 2008; 5 (3): 136-47.
2. O'Brien ME, Watkins D, Ryan C, *et al.* Randomised trial in malignant mesothelioma (M) of early (E) versus delayed (D) chemotherapy in symptomatically stable patients: the MED trial. *Ann Oncol.* 2006; 17 (2): 270-5.
3. Vogelzang NJ, Rusthoven JJ, Symanowski J, *et al.* Phase III study of pemetrexed in combination with cisplatin versus cisplatin alone in patients with malignant pleural mesothelioma. *J Clin Oncol.* 2003; 21 (14): 2636-44.
4. Santoro A, O'Brien ME, Stahel RA, *et al.* Pemetrexed plus cisplatin or pemetrexed plus carboplatin for chemo-naïve patients with malignant pleural mesothelioma: results of the International Expanded Access Program. *J Thorac Oncol.* 2008; 3 (7): 756-63.
5. Mitsudomi T, Suda K, Yatabe Y. Surgery for NSCLC in the era of personalized medicine. *Rev Clin Oncol.* 2013; 10 (4): 235-44.
6. Ladanyi M, Zauderer MG, Krug LM, *et al.* New strategies in pleural mesothelioma: BAP1 and NF2 as novel targets for therapeutic development and risk assessment. *Clin Cancer Res.* 2012; 18 (17): 4485-90.
7. Ou SH, Moon J, Garland LL, *et al.* SWOG S0722: phase II study of mTOR inhibitor everolimus (RAD001) in advanced malignant pleural mesothelioma (MPM). *J Thorac Oncol.* 2015; 10 (2): 387-91.
8. Zhou S, Liu L, Li H, *et al.* Multipoint targeting of the PI3K/mTOR pathway in mesothelioma. *Br J Cancer.* 2014; 110 (10): 2479-88.
9. Varghese S, Chen Z, Bartlett DL, *et al.* Activation of the phosphoinositide-3-kinase and mammalian target of rapamycin signalling pathways are associated with shortened survival in patients with malignant peritoneal mesothelioma. *Cancer.* 2011; 117 (2): 361-71.
10. Carbone M, Yang H, Pass HI, *et al.* BAP1 and cancer. *Nat Rev Cancer.* 2013; 13 (3): 153-9.
11. Baumann F, Flores E, Napolitano A, *et al.* Mesothelioma patients with germline BAP1 mutations have 7-fold improved long-term survival. *Carcinogenesis.* 2015; 36 (1): 76-81.
12. Nasu M, Emi M, Pastorino S, *et al.* High Incidence of Somatic BAP1 Alterations in Sporadic Malignant Mesothelioma. *J Thorac Oncol.* 2015; 10 (4): 565-76.
13. Szlosarek PW, Klabatsa A, Pallaska A, *et al.* In vivo loss of expression of argininosuccinate synthetase in malignant pleural mesothelioma is a biomarker for susceptibility to arginine depletion. *Clin Cancer Res.* 2006; 12 (23): 7126-31.
14. Szlosarek PW, Luong P, Phillips MM, *et al.* Metabolic response to pegylated arginine deiminase in mesothelioma with promoter methylation of argininosuccinate synthetase. *J Clin Oncol.* 2013; 31 (7): e111-3.
15. Szlosarek PW, Steele J, Sheaff T, *et al.* A randomized phase II trial of pegylated arginine deiminase in patients with malignant pleural mesothelioma. 15th World Conference on Lung Cancer. Sydney. 2013 Oct 27-30; Abstr. MO09.02.
16. Weldon JE, Xiang L, Zhang J, *et al.* A recombinant immunotoxin against the tumor-associated antigen mesothelin reengineered for high activity, low off-target toxicity, and reduced antigenicity. *Mol Cancer Ther.* 2013; 12 (1): 48-57.

17. Hassan R, Miller AC, Sharon E, *et al.* Major cancer regressions in mesothelioma after treatment with an anti-mesothelin immunotoxin and immune suppression. *Sci Transl Med.* 2013; 5 (208): 208ra147.
18. Hassan R, Sharon E, Thomas A, *et al.* Phase 1 study of the antimesothelin immunotoxin SS1P in combination with pemetrexed and cisplatin for front-line therapy of pleural mesothelioma and correlation of tumor response with serum mesothelin, megakaryocyte potentiating factor, and cancer antigen 125. *Cancer.* 2014; 120 (21): 3311-9.
19. Golfier S, Kopitz C, Kahnert A, *et al.* Anetumab ravtansine: a novel mesothelin-targeting antibody-drug conjugate cures tumours with heterogeneous target expression favoured by bystander effect. *Mol Cancer Ther.* 2014; 13 (6): 1537-48.
20. Bendell J, Blumenschein G, Zinner R, *et al.* First-in-human phase I dose escalation study of a novel anti-mesothelin antibody drug conjugate (ADC), BAY 94-9343, in patients with advanced solid tumors. In: Proceedings of the 104th Annual Meeting of the American Association for Cancer Research; 2013 Apr 6-10; Washington, DC. Philadelphia (PA): AACR; 2013. Abstr. LB-291.
21. Kindler HL, Karrison TG, Gandara DR, *et al.* Multicenter, double-blind, placebo-controlled, randomized phase II trial of gemcitabine/cisplatin plus bevacizumab or placebo in patients with malignant mesothelioma. *J Clin Oncol.* 2012; 30 (20): 2509-15.
22. Couzin-Frankel J. Breakthrough of the year 2013. Cancer immunotherapy. *Science.* 2013; 342 (6165): 1432-3.
23. Ribas A, Hersey P, Middleton MR, *et al.* New challenges in endpoints for drug development in advanced melanoma. *Clin Cancer Res.* 2012; 18 (2): 336-41.
24. Maio M, Grob JJ, Aamdal S, *et al.* Five-Year Survival Rates for Treatment-Naive Patients With Advanced Melanoma Who Received Ipilimumab Plus Dacarbazine in a Phase III Trial. *J Clin Oncol.* 2015; 33 (10): 1191-6.
25. Calabrò L, Morra A, Fonsatti E, *et al.* Tremelimumab for patients with chemotherapy-resistant advanced malignant mesothelioma: an open-label, single-arm, phase 2 trial. *Lancet Oncol.* 2013; 14 (11): 1104-11.
26. Stebbing J, Powles T, McPherson K, *et al.* The efficacy and safety of weekly vinorelbine in relapsed malignant pleural mesothelioma. *Lung Cancer.* 2009; 63 (1): 94-7.
27. Mansfield AS, Roden AC, Peikert T, *et al.* B7-H1 expression in malignant pleural mesothelioma is associated with sarcomatoid histology and poor prognosis. *J Thorac Oncol.* 2014; 9 (7): 1036-40.
28. Cedrés S, Ponce-Aix S, Zugazagoitia J, *et al.* Analysis of expression of programmed cell death 1 ligand 1 (PD-L1) in malignant pleural mesothelioma (MPM). *PLoS One.* 2015; 10 (3): e0121071.
29. Alley EW, Molife LR, Santoro A, *et al.* Clinical safety and efficacy of pembrolizumab (MK-3475) in patients with malignant pleural mesothelioma: Preliminary results from KEYNOTE-028. In: Proceedings of the 106th Annual Meeting of the American Association for Cancer Research; 2015 Apr 18-22; Philadelphia, PA. Philadelphia (PA): AACR; 2015. Abstr. CT103.

Chapter 14

Extended Pleurectomy Decortication: The New Standard of Care for Malignant Pleural Mesothelioma

Apostolos Nakas

Chance does nothing that has not been prepared beforehand

Introduction

Malignant mesothelioma is a form of cancer that principally affects the pleura, the peritoneum, the pericardium as well as other serosal membranes (tunica vaginalis). Many cases are diagnosed at an advanced stage as symptoms are non-specific and appear late in the development of the disease. It is almost always fatal with most of those affected usually dying within twelve months of diagnosis. Mesothelioma has a strong association with exposure to asbestos and current estimates suggest that around 85% of all male mesotheliomas are attributable to occupational exposure [1]. Most deaths occurring now are a consequence of the long latency period (i.e. the time between initial exposure to asbestos and the manifestation of the disease) which is typically between 30 and 40 years and are a legacy of past occupational exposures to asbestos when it was widely used in the building industry [1,2].

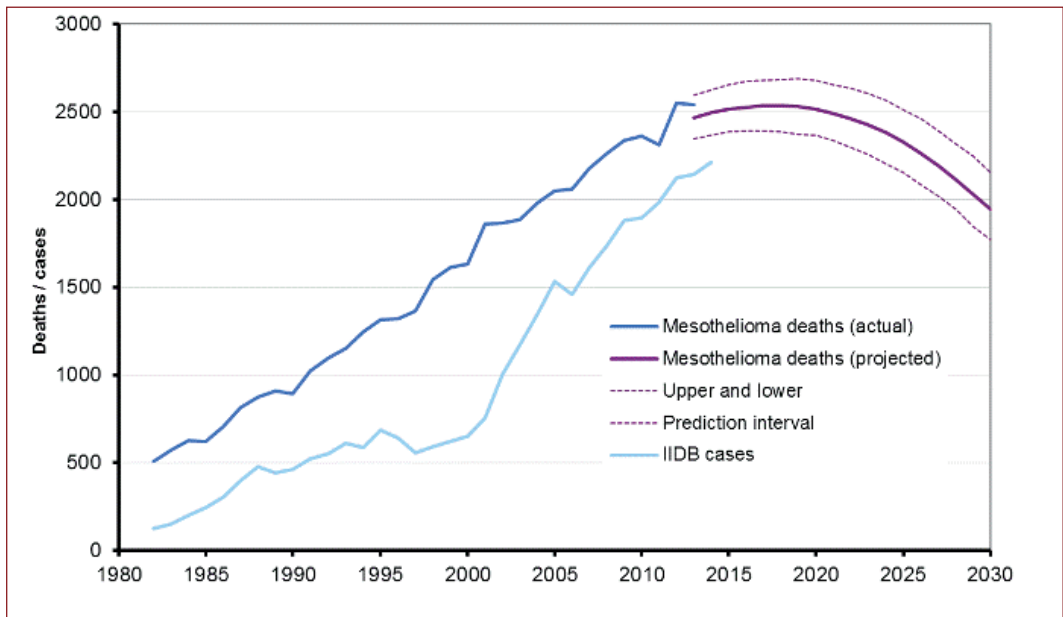


Fig1: Annual mortality for mesothelioma in Great Britain (Source: HSE 2014)

The latest (2015) information from the Health and Safety Executive shows that the number of mesothelioma deaths increased to 2,535 in 2012 from 2,311 in 2011 (Figure 1). This was largely due to an increase in male deaths aged 65 years or older. In 2012 there were 2,126 male deaths and 409 female deaths. The number of new cases of mesothelioma assessed for Industrial Injuries Disablement Benefit has increased from 2,125 in 2012 to 2,145 new cases in 2013. Men who worked in the building industry when asbestos was used extensively are now among those most at risk of mesothelioma [1, 2].

The widely accepted treatment options for malignant pleural mesothelioma include:

1. active symptom control,
2. indwelling pleural catheter to control pleural effusions,
3. pleurodesis,

4. systemic chemotherapy,
5. surgery: for diagnosis, staging and therapeutic purposes,
6. radiotherapy: port site, whole hemithorax or palliative at areas of symptomatic local invasion,
7. other:
 - a. photodynamic treatment (PDT), as an adjuvant to surgery.
 - b. intracavitary chemotherapy, as an adjuvant to surgery.
 - c. immunotherapy.

Radical Surgery in Malignant Pleural Mesothelioma

Radical surgical procedures were developed on the back of single modality approaches failing to extend survival. Surgery as part of a multimodality approach aims to achieve macroscopic clearance with some form of additional therapy by either local (intrapleural chemotherapy, hemithoracic irradiation, intraoperative PDT) or systemic (chemotherapy, immunotherapy) means to prevent local recurrence by addressing microscopic residual disease [3]. However, not everybody subscribes to the concept of Macroscopic Complete Resection (MCR) and this has led to controversy and a number of heated arguments amongst clinicians in the international scientific forums.

Non-Radical Surgery in Malignant Pleural Mesothelioma

Surgery with non-radical intent can be broadly divided in to surgery for diagnostic and staging purposes, and surgery with a therapeutic intention. With the exception of cervical mediastinoscopy and staging laparoscopy, all other procedures have a therapeutic intention to control pleural effusions, re-expand collapsed lung and control dyspnoea. Over the years, a number of retrospective studies have suggested that non-radical procedures could be used for palliation of certain symptoms (pain) and to improve quality of life [4, 5]. Some of these claims have been refuted by the results of other studies and trials [6].

Perhaps the most important question that remains to be answered is whether surgery for mesothelioma conveys a survival benefit compared to alternative treatment options or to no treatment at all. If this is the case, does surgery need to be radical with all the implications associated with extensive surgery or will patients survive just as long with a good quality of life with a lesser procedure?

Table 1: Surgical procedures for mesothelioma

VATS Pleural Biopsy and Talc Pleurodesis
VATS Pleurectomy Decortication (VAT Partial Pleurectomy or VAT PD)
Open Pleurectomy Decortication or Partial PD
Extended (radical) pleurectomy decortication (EPD)
Extrapleural pneumonectomy (EPP) or Pleuropneumonectomy

Therapeutic Procedures for MPM

It was previously considered that there were five surgical procedures for MPM (Table 1). However, in the last decade, a number of cohort studies as well as randomized trials have reported outcomes of these procedures thus significantly influencing the clinician's choice. The important question is whether all these procedures remain relevant in the modern era. It is of note that the National Lung Cancer Audit report for MPM in the UK between 2008-2012 groups all types of surgery together making extraction of survival figures for the different types of surgery impossible [2].

The five procedures in detail are:

VATS Pleural Biopsy and Talc Pleurodesis

This is the first procedure that a patient will have usually as part of the diagnostic process. It is short, straightforward and usually combined with talc pleurodesis. It is performed under local ('medical thoracoscopy') or general ('surgical thoracoscopy') anaesthesia and aims to get targeted biopsies for diagnosis and achieve effusion control in one procedure.

The advantage is that it can be tolerated by most patients and, besides active symptom control, may be the only treatment that a patient receives. It also facilitates subsequent radical surgery as the talc effect on the visceral pleura makes the visceral decortication of early stage disease technically easier. The single port can be irradiated as part of a trial (PIT Trial).

The disadvantages are that medical thoracoscopy requires at least a moderate amount of fluid whilst not all the patients will be fit enough for a general anaesthetic. If the lung is trapped, VATS pleurodesis is not a therapeutic option and the clinician will either have to accept a trapped lung and consider inserting an indwelling pleural catheter (IPC), or consider proceeding to a decortication.

VATS Pleurectomy Decortication (P/D)

Usually performed through 2-3 ports, the aim of this procedure is to re-expand the lung thus achieving effusion control and dyspnoea improvement. In cases of malignant pleural empyema, it might be utilized as an attempt to sterilize the space, to be followed

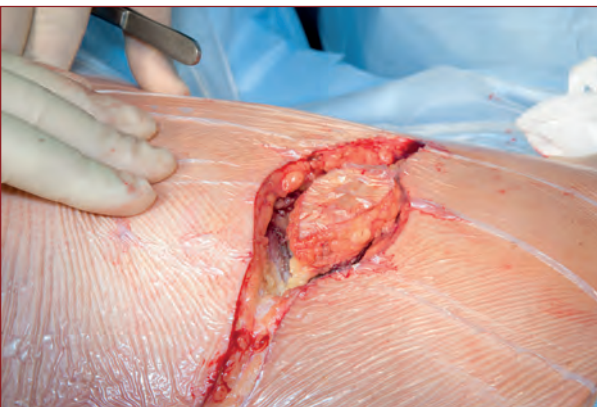

Fig2: Posterolateral thoracotomy for extended pleurectomy decortication with excision of previous VATS biopsy site

by more treatment (surgery or chemotherapy). Although the insult to the chest wall is minimal the internal pleurectomy/decortication is still associated with significant bleeding and air leak resulting in increased morbidity, mortality and length of stay compared to VATS pleurodesis [6]. Not particularly useful in bulky disease, debulking of the mediastinum or the diaphragm is virtually impossible with the VATS approach. As with the VATS pleurodesis, if lung expansion is impossible by VATS P/D, one might have to consider open decortication.

For a number of years, some clinicians felt that effusion control and lung re-expansion would be associated with improvement in quality of life and survival benefit. The results of the MesoVATS trial demonstrated that these beliefs were very optimistic, leaving the VATS P/D procedure without a clearly defined role [6].

Open (Non-Radical, Simple) Pleurectomy Decortication (P/D)

This is the procedure that most surgeons perform when they say that they have performed a P/D for mesothelioma. It is performed through a standard thoracotomy and usually consists of a partial pleurectomy and variable degree of decortication. It is more difficult, if not impossible, to achieve complete macroscopic clearance without resection of the diaphragm and/ or pericardium. It is technically easier to achieve good lung expansion than with video-assisted P/D but it adds a thoracotomy to the surgical insult and does not convey the potential benefits of radical resection [7]. In the opinion of the author, it can be used as a fall-back when the intention was to achieve complete resection but the tumour is found to be unresectable or in cases with completely trapped lung and no confirmed diagnosis of mesothelioma. In all other cases, the surgeon should consider either a purely palliative approach or an Indwelling Pleural Catheter (IPC).

Extended (Radical) Pleurectomy Decortication (EPD)

Also referred to as “Lung-Sparing Pleurectomy Decortication”, this is the operation that removes all macroscopic disease aiming to achieve R1 resection. It requires an extended thoracotomy curving towards the neck for access to the apex and the abdomen for access to the diaphragm, with excision of the previous biopsy scar and tract (Figure 2).

Some surgeons prefer a two level thoracotomy (4th and 6th or 7th intercostal space), however a single level thoracotomy at the 6th intercostal space on the right and 5th on the left is usually adequate for most cases. Although we have used a sternotomy in a few cases in the past, we have found no advantage to this approach with the possible exception of better photographic views and have therefore abandoned it.

The pleurectomy extends to remove pericardium and diaphragm when infiltrated with disease and reconstruct both with synthetic material (Figure 3). The visceral decortication extends into the fissures removing all disease and may require extensive sharp sub-adventitial dissection and skeletonization of the PA.

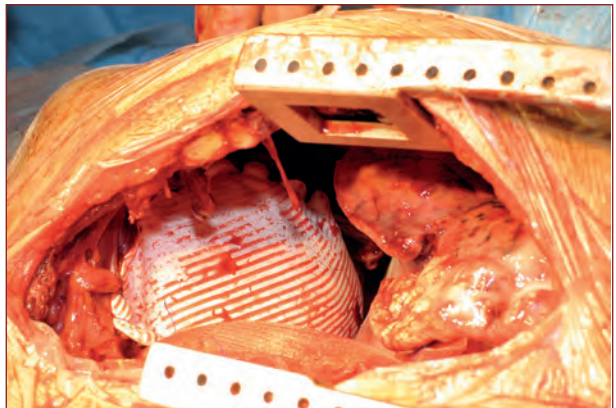


Fig 3: Extended pleurectomy decortication with pericardium reconstructed with Prolene mesh and diaphragm reconstructed with Gore-Tex Dual Mesh (viewed via median sternotomy).

Extended pleurectomy decortication is technically more challenging than all the other procedures. It is suitable for patients that cannot tolerate a pneumonectomy and has allowed the extension of radical surgery to older age groups and, in experienced hands,

has significantly less impact on quality of life and fewer complications than extrapleural pneumonectomy (EPP) [5].

It still has significant blood loss (probably more than EPP because of the preservation of the lung) and the air leak predisposes to pleural space infection. The presence of the lung does not allow for whole hemithorax irradiation and some surgeons feel that in the presence of bulky disease, an EPP is the only option. The author disagrees with this opinion as even the bulkiest disease can be decorticated except

in cases with gross invasion of the PA in the fissure - these cases are likely to be unresectable because of chest wall/ mediastinal invasion therefore EPD is feasible in practically most if not all the resectable cases (Figures 4 and 5) [8].

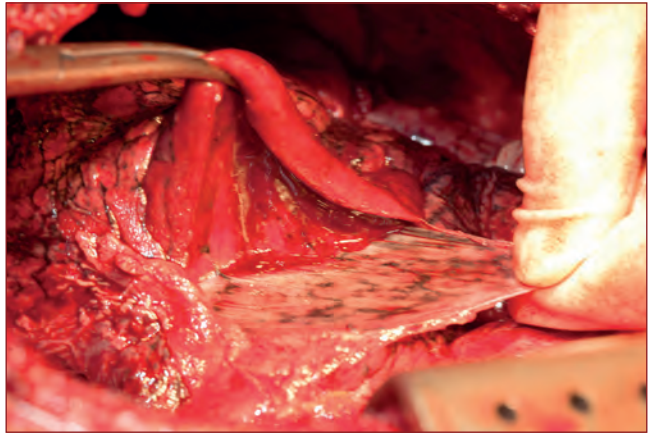


Fig 4: Extended pleurectomy decortication: visceral decortication

Extrapleural Pneumonectomy (EPP, Pleuropneumonectomy)

This was a procedure initially developed for tuberculosis surgery and later applied to mesothelioma as a means to attempt complete tumour resection (Figure 6) [9]. It is probably easier to achieve R1 resection (the reported cases of R0 are open to interpretation of what margin constitutes R0) and is definitely an easier operation than EPD. The empty hemithorax can be treated with high-dose radiotherapy, which is impossible in EPD, and obviously air leaks are not a problem.

Unfortunately, this operation adds the insult of pneumonectomy to the impact of an extended pleurectomy for malignant disease. The rate of complications remains consistently high (40-60%) in most of the reported series [5] and this has led most of the high volume centers worldwide to switch to EPD. Rapid space filling with haemodynamic compromise, pleural sepsis and bronchopleural fistulas are complications that are associated with significant mortality (6-7%) and unfavourable outcomes [5, 8, 12].

Thus, in the opinion of the author, only two procedures for MPM should be offered: VATS pleural biopsy and EPD. The evidence for this is summarized in the next sections

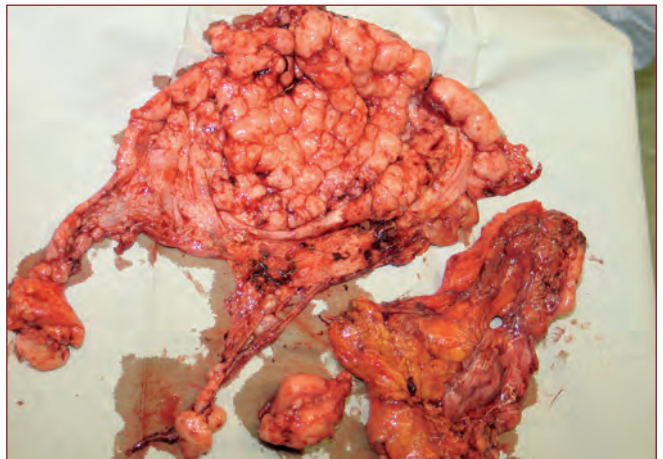


Fig 5: Extended pleurectomy decortication: surgical specimen

MARS Feasibility Trial (reported 2011)

The Mesothelioma and Radical Surgery (MARS) Trial opened as a feasibility study in October 2005 and completed recruitment in November 2008. Its aim was to assess the feasibility of a larger randomized control trial (RCT) that would compare EPP and chemotherapy versus chemotherapy alone in the treatment of mesothelioma.

The aim of the feasibility study was to recruit 50 patients in one year. The power of the main trial required to demonstrate the effect of the proposed intervention (EPP) was estimated to be 670 patients. Patients would receive 3 cycles of platinum-based chemotherapy and were then randomized to EPP + hemithorax irradiation or no EPP.

Twelve centres in the UK took part with 50 patients recruited over 3 years, of which 24 were randomised to have EPP. However only 16 actually had EPP as, in some patients, the disease had progressed to

being unresectable and some were found to be unresectable during the operation. Of these 16, only 8 patients completed trimodality treatment with hemithoracic irradiation.

Survival was significantly worse in the EPP arm (median survival of 14.4 months compared to 19.5 months for no EPP) with a hazard ratio (HR) for EPP of 2.75 (1.21-6.26, $p=0.016$) [10]. The 30-day mortality following EPP was 10.5%. The authors concluded that “EPP within trimodality therapy offers no benefit and potentially harms patients”.

This report has led to a reaction from many prominent mesothelioma experts who argued that the MARS study did not show the feasibility of doing a trial comparing chemotherapy with EPP and radiotherapy. The author believes the interpretation of the study that “radical surgery in the form of EPP within trimodal therapy offers no benefit and possibly harms patients” is inappropriate, could move clinical research for mesothelioma in the wrong direction, and might be harmful to patients seeking advice [11]. Criticisms of the trial have focused on the small number of patients, the exclusion of 58% of the screened patients and the fact that it took 3 years instead of 1 year to randomize the patients. Arguments aside, the landscape was changing. When the main trial for Mesothelioma and Radical Surgery was planned, the radical procedure on test would be EPD and not EPP. In the meantime, another large UK randomised controlled trial (MesoVATS) had reported.

MesoVATS Trial (reported 2014)

MesoVATS was a randomised controlled trial that aimed to compare VATS partial pleurectomy (VAT-PP) to talc pleurodesis [6]. Outcomes were survival, presence of effusion,

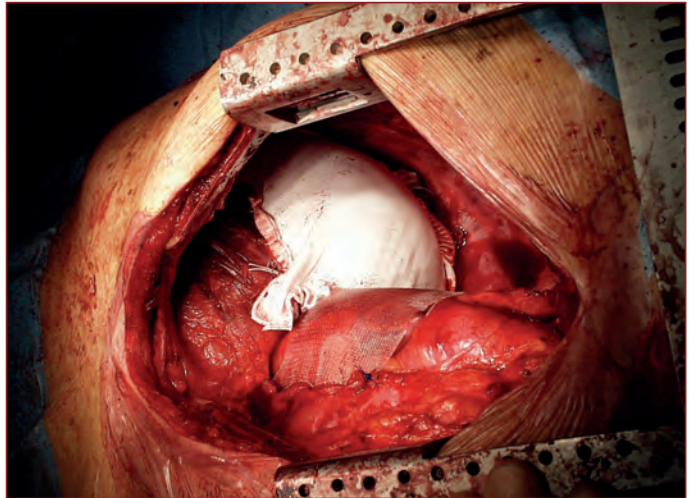


Fig 6: Empty hemithorax with reconstruction of pericardium and diaphragm following a right extrapleural pneumonectomy (median sternotomy).

quality of life, lung function, exercise tolerance, complications and cost. Twelve surgical centres from the UK recruited 196 patients between October 2003 and January 2012 and, of these, 11% in the VAT-PP arm and 10% in the pleurodesis arm did not have malignant pleural mesothelioma, leaving 87 and 88 patients respectively in the trial. Median survival at 12 months was 13.1 months in the VAT-PP group versus 13.5 months in the pleurodesis group (HR 1.04, 95% CI 0.76-1.42, $p=0.81$) with survival of 52% for VAT-PP versus 57% for pleurodesis.

Secondary outcomes were effusion control, improvement in FEV1, length of hospital stay and cost. The significant differences between the groups were that VAT-PP was associated with more complications, longer length of stay and higher costs.

The investigators concluded that VAT-PP had no effect on overall survival, resulted in more complications, longer hospital stay and was more expensive than talc pleurodesis in patients with pleural effusion due to malignant pleural mesothelioma. However, a significant improvement in the EQ-5D score at 6 and 12 months in the VAT-PP group suggested that this treatment might have a role in patients expected to survive at least 6 months. Subgroup analysis suggested that patients in the EORTC low-risk prognostic group might benefit most from VAT-PP and further work in this subgroup may be appropriate [6].

In summary, MesoVATS demonstrated that VAT-PP does not alter the biological course of the disease. The improvement in only one quality of life score makes the benefit of the procedure in improving quality of life questionable.

Taking into account the high mortality of EPP and the unfavourable results of non-radical resections, there are thus two operations that should be offered, as mentioned above: VATS pleurodesis and EPD. A simple, non-radical decortication can be used in selected cases with trapped lung and without a confirmed diagnosis, or as a fall back procedure in cases found to be unresectable intraoperatively. Although there are still advocates of EPP, the author would hesitate to consider it a viable option nowadays. It is associated with increased mortality and morbidity without demonstrating significant benefits over EPD or even over no surgery [12].

Why EPD should be tested as the new standard of care for MPM

A number of retrospective case series and systematic reviews [4, 5, 8, 12] have identified two key facts: EPP was associated with increased morbidity and impact on quality of life, and EPD was not associated with inferior oncological outcomes. The indications for EPD are listed in Table 2. The key question remains whether any form of surgery can be beneficial for patients with MPM.

In all these (as well as numerous other) case series, the 1-year survival after radical surgery ranges from 50% to 70%, whilst for all malignant pleural mesothelioma cases, the 1-year survival according to the National Lung Cancer Audit report for the years 2008-2012 is 40% on average [2]. The difference in favour of surgery is not clear at all.

When we add chemotherapy to radical surgery, according to our own subgroup analysis, the 1-year survival is 81% for surgery + chemotherapy versus 51% for the surgery only group ($p<0.001$) [12]. Thus, the combination of radical surgery and chemotherapy appears to be associated with better results than surgery alone. The need for a properly conducted RCT is obvious. MARS (Mesothelioma and Radical Surgery) 2 should be the trial that will help us to assess the efficacy or non-efficacy of surgery in the management of mesothelioma.

Table 2: Selection Criteria for EPD

	Criteria	Notes
Inclusion Criteria	IMIG Stage cT3N2M0 or better	True T4 might be impossible to determine on imaging studies
	Performance Status (PS) 1 or better	Assess PS after effusion control
	Normal Cardiac Function	
	Adequate respiratory function (FEV1 and TLCO >20%)	Assess FEV1 and TLCO after effusion control
		Sterile Pleural Space
Exclusion Criteria	Unresectable disease	Multifocal chest wall invasion, M1 disease
	Kidney Failure requiring dialysis	
	Liver Failure	
	Infected pleural space	
	Clotting disorder	
Relative Contraindications	Sarcomatoid disease	Not excluded in MARS 2
	Progression of disease on chemotherapy	Not excluded in MARS 2

This trial will evaluate EPD+chemotherapy versus chemotherapy alone. The feasibility part aims to recruit 50 patients in 2 years and the full study to recruit 285 patients more (total 335) in 5 years.

Conclusions

Overall the management algorithm the author would suggest broadly consists of:

1. biopsy and talc pleurodesis for most cases,
2. indwelling pleural catheter for trapped lung if the patient is not fit for radical surgery,
3. active symptom control is an appropriate form of treatment in a large proportion of patients,
4. adjuvant / palliative chemotherapy,
5. radical surgery in the form of EPD in the context of the MARS 2 Trial.

The biggest problem of EPD remains the 35-45% one-year mortality from disease progression [12]. There remain questions about the role of EPP, VATS PD or even partial PD. These procedures should only be used in a few selected cases and the majority of cases should be entered into MARS 2 if they are suitable for trial entry. Whilst retrospective studies suggest that complete cytoreduction in the form of Macroscopic Complete Resection achieved by EPD influences the course of the disease and might prolong survival, especially when combined with chemotherapy, with MARS 2 we will be able to confirm if this is true.

References

1. Mesothelioma in Great Britain, Health and Safety Executive, 2014.
2. National Lung Cancer Audit Report 2014 Mesothelioma, Report for the period 2008-2012, Health and Social Care Information Centre, 2014.
3. Sugarbaker DJ. Multimodality management of malignant pleural mesothelioma: introduction. *Semin Thorac Cardiovasc Surg.* 2009 Summer; 21(2):95-6.
4. Cao C, Tian D, Pataky K, *et al.* Systematic review of pleurectomy in the treatment of malignant pleural Mesothelioma. *Lung Cancer* 81 (2013) 319-327.
5. Cao C., Tian D, Park J, *et al.* A systematic review and meta-analysis of surgical treatments for malignant pleural mesothelioma. *Lung Cancer* 83 (2014) 240-245.
6. Rintoul RC, Ritchie AJ, Edwards JG, *et al.* Efficacy and cost of video-assisted thoracoscopic partial pleurectomy versus talc pleurodesis in patients with malignant pleural mesothelioma (MesoVATS): an open-label, randomised, controlled trial. *Lancet* 2014; 384: 1118-27.
7. Nakas A, Trousse DS, Martin-Ucar AE, *et al.* Open lung-sparing surgery for malignant pleural mesothelioma: the benefits of a radical approach within multimodality therapy. *Eur J Cardiothorac Surg.* 2008 Oct; 34(4):886-91.
8. Nakas A, von Meyenfeldt E, Lau K, *et al.* Long-term survival after lung-sparing total pleurectomy for locally advanced (International Mesothelioma Interest Group Stage T3-T4) non-sarcomatoid malignant pleural mesothelioma. *Eur J Cardiothorac Surg.* 2012 May; 41(5):1031-6.
9. Butchart EG, Ashcroft T, Barnsley WC, *et al.* Pleuropneumonectomy in the management of diffuse malignant mesothelioma of the pleura. Experience with 29 patients. *Thorax.* 1976 Feb; 31(1):15-24.
10. Treasure T, Lang-Ladzunski L, Waller, *et al.* Extra-pleural pneumonectomy versus no extra-pleural pneumonectomy for patients with malignant pleural mesothelioma: clinical outcomes of the Mesothelioma and Radical Surgery (MARS) randomised feasibility study. *Lancet Oncol* 2011; 12: 763-72.
11. Weder W, Stahel RA, Baas P, *et al.* The MARS feasibility trial: conclusions not supported by data. *Lancet Oncol.* 2011 Nov; 12(12):1093-4; author reply 1094-5.
12. Nakas A, Waller D. Predictors of long-term survival following radical surgery for malignant pleural mesothelioma. *Eur J Cardiothorac Surg.* 2014 Sep; 46(3):380-5.

Chapter 15

Extrapleural Pneumonectomy for Mesothelioma

Mobammed F Chowdhry and Paul Van Schil

To break a ray of light, a droplet of dew or a crystal of ice may suffice.

Introduction

Malignant mesothelioma of the pleura is managed with various surgical strategies. According to the IASLC/IMIG Consensus report of 2011 [1], extrapleural pneumonectomy (EPP) is an en bloc resection of parietal and visceral pleura together with the ipsilateral lung and, if necessary, the pericardium and the diaphragm (Figure 1).

Extended pleurectomy / decortication involves resection of the parietal and visceral pleura and, if necessary, the diaphragm and/or the pericardium with appropriate reconstruction (Figure 2). The term 'radical' is not used anymore because although all macroscopic tumour is excised, microscopic disease remains. A pleurectomy /decortication is the resection of parietal and visceral pleura without the diaphragm or pericardium with excision of all gross tumour. Partial pleurectomy is the partial removal of parietal and/or visceral pleura for diagnostic or palliative purposes, for example to control pleural effusion [2].

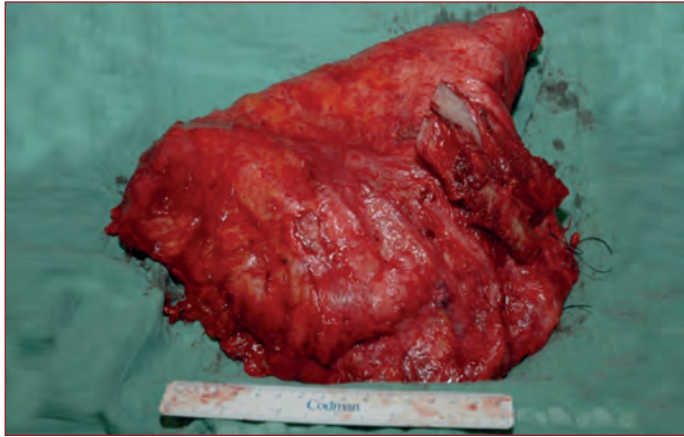


Fig 1: Specimen of EPP with partial chest wall resection

The advantages of EPP are that it is a maximal debulking procedure where good macroscopic clearance is achieved. For this reason, an increased radiation dose can be given after surgery as there is an empty pleural cavity and good palliation can be obtained. The disadvantages are that it is a major procedure with high mortality and morbidity and there remains the question of a survival advantage with EPP.

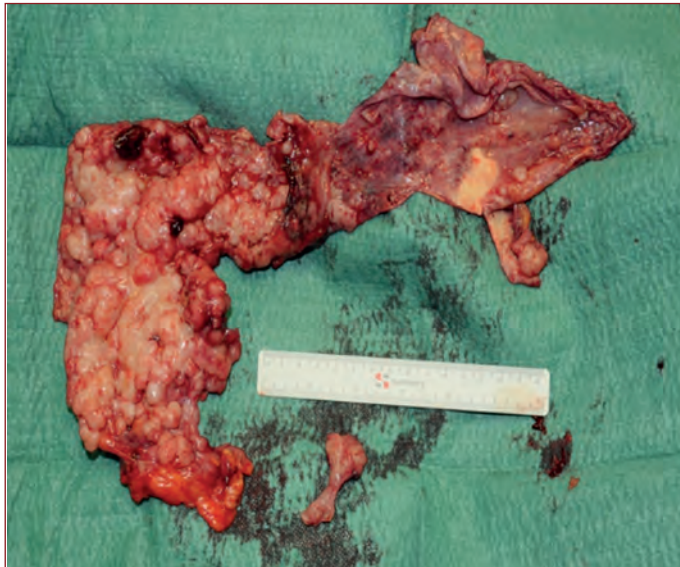


Fig 2: Specimen of pleurectomy and decortication

The main advantage of pleurectomy/decortication is the preservation of lung parenchyma. The mortality and morbidity is relatively lower while achieving good palliation and subsequent therapy (e.g. adjuvant chemoradiotherapy) is rapidly possible. The disadvantages are a reduced radiation dose due to the presence of remaining lung. Moreover, it can only be considered radical for early stage Ia mesothelioma [3].

Table 1: Comparison of outcomes in prospective phase II trials of extrapleural pneumonectomy after induction therapy.

Variable	SAKK 17/00-trial [6]	US phase II trial [7]	EORTC 08031 [2]
N patients / N institutions	61/6	77/9	59/11
Induction regimen	Cis-gem x 3	Cis-pem x 4	Cis-pem x 3
Compliance to induction chemotherapy	95%	83%	93%
EPP	45 (74%)	54 (70%)	42 (74%)
Operative mortality	2.2%	7%	6.5%
pCR rate	2.2%	5%	4.8%
PORT completed	36 (59%)	40 (52%)	37 (65%)
Median OS [ITT] (95% CI)	19.8 m (14.6-24.5)	16.8 m (13.6-23.2)	18.4 m (15.6-32.9)
Median OS [PP] (95% CI)	23.0 m (16.6-32.9)	21.9 m (16.8-29.1)	21.5 m (17.6- NR)
Local relapse (% PP)	NS	11 (28%)	6 (16%)
Median PFS [ITT] (95% CI)	13.5 m (10.2-18.8)	10.1 m (8.6-15.0)	13.9 m (10.9-17.2)
Median overall treatment time (range)	NS	NS	193 days (162-220)

CI: Confidence Interval; Cis-gem: cisplatin-gemcitabin; Cis-pem: cisplatin-pemetrexed; EORTC: European Organisation for Research and Treatment of Cancer; EPP: extrapleural pneumonectomy; ITT: intention to treat; m: months; N/n: number; NR: not reached; NS: not stated; OS: overall survival; pCR: pathological complete response; PFS: progression-free survival; PORT: post-operative radiotherapy; PP: per protocol; SAKK: Swiss Group for Clinical Cancer Research; US: United States.

Reproduced with permission of the European Respiratory Society ©: European Respiratory Journal Sep 2014, 44 (3) 754-764; DOI: 10.1183/09031936.00207213

Boston Experience

Sugarbaker [4] has probably the largest experience in performing EPP. In his series of almost five hundred patients who had EPP, the mortality was only 3.4% with a morbidity rate of 60%. The most frequent complications included atrial fibrillation (44.2%), prolonged intubation (7.9%), vocal cord paralysis (6.7%), deep vein thrombosis (6.4%) and technical complications related to patch dehiscence, haemorrhage or both.

European Organisation for Research and Treatment of Cancer (EORTC; protocol 08031) phase II trial

This trial investigated the feasibility of trimodality therapy consisting of induction chemotherapy followed by extrapleural pneumonectomy and post-operative radiotherapy in patients with malignant pleural mesothelioma (with stage cT3N1M0 or less) [5]. Induction chemotherapy consisted of three courses of cisplatin 75mg/m² and pemetrexed 500mg/m². Non-progressing patients underwent extrapleural pneumonectomy followed

by post-operative radiotherapy (54 Gy, 30 fractions). The primary end-point was “success of treatment” and the secondary end-points were toxicity and overall / progression-free survival.

Fifty-nine patients were registered, of which one was ineligible. Their median age was 57 years with TNM scores as follows: cT1 (n=36), T2 (n=16) and T3 (n=6); cN0 (n=57) and N1 (n=1). Fifty-five patients (93%) received three cycles of chemotherapy with only mild toxicity. Forty-six patients (79%) received surgery and 42 (74%) had extrapleural pneumonectomy with a 90-day mortality of 6.5%. Post-operative radiotherapy was completed in 37 (65%) patients. Grade 3–4 toxicity persisted after 90 days in three (5.3%) patients. Median overall survival time was 18.4 months (95% CI 15.6–32.9) and median progression-free survival was 13.9 months (95% CI 10.9–17.2). Only 24 (42%) patients met the definition of success (one-sided 90% CI 0.36–1.00). Therefore, although feasible, trimodality therapy in patients with mesothelioma was not completed within the strictly defined timelines of this protocol.

Similarly, the Swiss Group for Clinical Cancer Research (SAKK 17/00) aimed to prospectively evaluate neoadjuvant chemotherapy followed by EPP with or without radiotherapy in a multicentre setting in Switzerland [6]. The outcome of this trial, a similar US phase-2 trial and the EORTC trial are highlighted in Table 1 [5-7]. In the recently published SAKK 17/04 randomised phase 2 trial, the impact of high-dose hemithoracic radiotherapy after neoadjuvant chemotherapy and EPP was evaluated [8]. A total of 113 patients underwent EPP and 54 patients were randomised between postoperative radiotherapy or no radiotherapy. Median locoregional relapse-free survival from surgery was 7.6 months in the group who didn't have radiotherapy and 9.4 months in the radiotherapy group. The study concluded that the routine use of hemithoracic radiotherapy after neoadjuvant chemotherapy and EPP is not supported [8].

Mesothelioma and Radical Surgery (MARS) trial

Patients in this pilot study had 3 cycles of induction chemotherapy followed by repeat staging with eligibility reviewed by the MARS multidisciplinary team [9]. Randomization was carried out between EPP and no EPP with a scheduled target population of 670 patients with stage T1-3, N0-1 and M0 mesothelioma. The primary endpoint was survival; the secondary endpoint was quality of life. The MARS investigators started off with a randomised pilot study, which aimed to include 50 patients to assess whether randomisation between surgery and no surgery was possible as part of a multicentre trial. Eleven centers participated with 112 patients having induction therapy but only 50 patients (45%) could be randomised. This pilot trial showed that it was possible to randomise between surgical and non-surgical treatment.

Twenty-four patients were randomly assigned to EPP (with radical radiotherapy) but only 16 completed EPP surgery and only 8 received radical radiotherapy. It took 3 years to randomise 50 patients to EPP or no EPP. The problem with this trial was that the mortality of EPP was 18.8% (n=3). This was a small group of patients and this was not really the primary endpoint of this feasibility study. The median survival after EPP was 14 months compared to 19 months for the non-EPP group, and the one-year survival after EPP was 52% compared to 73% with no EPP (adjusted hazard ratio, HR 2.75, p=0.016).



The conclusion was that in view of the high morbidity associated with EPP in this trial (and in other non-randomized studies), a larger study was not feasible. This data, although limited, suggested that radical surgery in the form of EPP within trimodality therapy offered no benefit and possibly harmed patients and that EPP could no longer be recommended as an option for patients with mesothelioma.

Evidence from Systematic Reviews

The systematic review, published in 2010 before the results of the MARS 1 trial, included 34 studies from 26 institutions and demonstrated an overall mortality ranging from 0% to 11.8%, morbidity ranging from 22% to 82%, a median survival time of 9.4 months to 27.5 months and a 5-year survival of 0% to 24% [10]. This review concluded that selected patients might benefit from EPP, especially when combined with induction or adjuvant therapy.

A recent study by three institutions over a 10-year period in which 251 patients completed EPP after induction chemotherapy reported a 30-day and 90-day mortality of 5% and 8% respectively, with 30% major morbidity [11]. This was higher after a right EPP compared to left. This study concluded that EPP was feasible with acceptable mortality and morbidity in well-selected patients treated at high-volume centres.

Finally, a retrospective analysis was performed from the IASLC database involving 3101 patients with 15 centers participating across 4 continents [12]. The median age was 63 years with 79% male and 62.3% with epithelioid mesothelioma. The TNM stages were a combination of clinical and pathological staging when available: stage I (11%), stage II (21%), stage III (48%) and stage IV (20%). A total of 64.5% of patients (n=1494) had surgery with a curative intent. The survival data showed that patients who had EPP at an early stage of their disease showed the best survival.

The Australian guidelines recommend that only patients with favourable prognostic features involving histology and staging should be referred for radical treatment involving extensive cytoreductive surgery [13]. Cytoreductive surgery should only be used as part of multimodality treatment and restricted to experienced high volume institutions.

An editorial in the Journal of Thoracic Oncology titled “Is it time to consider pleurectomy and decortication as the ONLY surgical treatment for malignant pleural mesothelioma?” highlighted the result of the MARS trial [14]. However, looking at the rest of the evidence presented here, it is the opinion of the authors that it is too early to completely abandon EPP altogether.

In conclusion, one can perform an extended pleurectomy/decortication or EPP for complete macroscopic resection of mesothelioma. When there is extensive disease with invasion of the fissure, it is difficult to perform a pleurectomy/decortication and it is in these cases that EPP may be a more suitable alternative to obtain macroscopic tumour clearance which remains the major goal of these interventions.


References

1. Rice D, Rusch V, Pass H, *et al.* International Association for the Study of Lung Cancer International Staging Committee and the International Mesothelioma Interest Group. Recommendations for uniform definitions of surgical techniques for malignant pleural mesothelioma: a consensus report of the International Association for the Study of Lung Cancer International Staging Committee and the International Mesothelioma Interest Group. *J Thorac Oncol* 2011; 6:1304–1312.
2. Van Schil P, Opitz I, Weder W, *et al.* Multimodal management of malignant pleural mesothelioma: where are we today? *Eur Resp J* 2014; 44: 754-64.
3. Maggi G, Casadio C, Cianci R, *et al.* Trimodality management of malignant pleural mesothelioma. *Eur J Cardiothorac Surg* 2001; 19:346-50.
4. Sugarbaker DJ, Jaklitsch MT, Bueno R, *et al.* Prevention, early detection, and management of complications after 328 consecutive extrapleural pneumonectomies. *J Thorac Cardiovasc Surg.* 2004; 128:138-46.
5. Van Schil PE, Baas P, Gaafar R, *et al.* On behalf of the European Organisation for Research and Treatment of Cancer (EORTC) Lung Cancer Group. Trimodality therapy for malignant pleural mesothelioma: results from an EORTC phase 2 multicentre trial. *Eur Resp J* 2010; 36: 1362-9
6. Weder W, Stahel RA, Bernhard J, *et al.*; Swiss Group for Clinical Cancer Research. Multicenter trial of neo-adjuvant chemotherapy followed by extrapleural pneumonectomy in malignant pleural mesothelioma. *Ann Oncol* 2007; 18:1196-202.
7. Krug LM, Pass HI, Rusch VW, *et al.* Multicenter phase II trial of neoadjuvant pemetrexed plus cisplatin followed by extrapleural pneumonectomy and radiation for malignant pleural mesothelioma. *J Clin Oncol.* 2009; 27:3007-13.
8. Stahel RA, Riesterer O, Xyrafas A, *et al.* Neoadjuvant chemotherapy and extrapleural pneumonectomy of malignant pleural mesothelioma with or without hemithoracic radiotherapy (SAKK 17/04): a randomised, international, multicentre phase 2 trial. *Lancet Oncol.* 2015; 16:1651-8.
9. Treasure T, Waller D, Tan C, *et al.* The Mesothelioma and Radical surgery randomized controlled trial: the Mars feasibility study. *J Thorac Oncol.* 2009; 4:1254-8.
10. Cao CQ, Yan TD, Bannon PG, *et al.* A systematic review of extrapleural pneumonectomy for malignant pleural mesothelioma. *J Thorac Oncol.* 2010; 5:1692-703.
11. Lauk O, Hoda MA, de Perrot M, *et al.* Extrapleural pneumonectomy after induction chemotherapy: perioperative outcome in 251 mesothelioma patients from three high-volume institutions. *Ann Thorac Surg.* 2014; 98:1748-54.
12. Rusch VW, Giroux D, Kennedy C, *et al.* IASLC Staging Committee. Initial analysis of the international association for the study of lung cancer mesothelioma database. *J Thorac Oncol.* 2012; 7:1631-9.
13. www.clinicalguidelines.gov.au/guideline/ID/226311.
14. Weyant MJ. Is it time to consider pleurectomy and decortication as the only surgical treatment for malignant pleural mesothelioma? *J Thorac Oncol.* 2012; 7:629-30.

Postscriptum

“Never let success hide its emptiness from you, achievement its nothingness, toil its desolation and so keep alive the incentive to push on further that pain in the soul which drives us beyond ourselves”

Dag Hammarskjold (1905-1961)



The Society for Cardiothoracic Surgery in Great Britain and Ireland decided to publish the scientific articles presented at the annual SCTS University meetings. This volume is the first of a series which will be published each year following the meeting and it continues Mr Paul Modi's editing of the Pericardial Heart Valve Volume.

This initiative will certainly prove to be useful to all members of our profession and especially to those who were unable to attend the University. In addition, being printed in the old Johannes Gutenberg manner, it will be more present on the surgeon's desk and readily accessible when compared with a web search. Our Roman ancestors rightly said: *Scripta manent* – ‘and so it will’. The name of Julius Caesar would have not remained in the memory of men if his pen had not joined his sword.

As you all remember, the evolution of open-heart surgery progressed, since its beginnings in the early 1950s, through repeated periods of intense bursts of creative activity followed by periods of quiet consolidation. Such cycles repeated themselves several times and indeed not only in surgery but in almost all major fields of human endeavour.

Over the past several years it became evident that a period of intense scientific activity is progressively and successfully taking place in these islands. This reality is shown by the number, the high quality and the originality of the presentations at the SCTS University and printed in this book.

The authors of the chapters in this book are all eminent surgeons, experts in their own domain. They gave of their unique experience and precious time, to help make this publication possible. All chapters on cardiac and thoracic surgery are clearly presented and amply documented. Almost all of them addressed the most advanced aspects of modern cardiothoracic surgery. The high quality and diversity of the subjects presented and the depth and originality of the questions raised, is evidence that the scientific research in cardiothoracic surgery in these islands is robust. One could expect that the future of these specialities will advance with even more élan.

Mr Paul Modi, in addition to participating as a distinguished specialist author in his field, diligently brought together this exceptional group of scientists and very efficiently dealt with the editing of this volume.

Stimulated and excited by the publication of this first volume of the University series, I take the liberty to look towards the FUTURE, that future time which is so precious because it is the price of eternity, the future of young surgeons who may contemplate their future participation in the future of scientific activities. For this, I would humbly suggest to them to emulate the simple but magnificent advice of Winston S Churchill: “Always aim for the moon, even if you miss you will land among the stars”.

And remember: the song of the sea does not end at the shore but in the minds of those prepared to listen to it.



Marian Ion Ionescu

Monaco, November 2015



Society for Cardiothoracic Surgery in Great Britain and Ireland