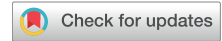

# Total Artificial Heart Implantation: How I Teach It



Matthew L. Goodwin, MD, and Nahush A. Mokadam, MD

Division of Cardiac Surgery, The Ohio State University Wexner Medical Center, Columbus, Ohio

The SynCardia temporary Total Artificial Heart (TAH-t) (SynCardia Systems LLC, Tucson, AZ) is a pneumatically driven, pulsatile, biventricular circulatory support system used for orthotopic replacement of the native ventricles. The TAH-t evolved from the Jarvik-7 TAH, which was first implanted 1982. The device consists of 2 polyurethane ventricle chambers each containing 2 tilting disc valves. The TAH-t offers 2 ventricular chamber sizes, 70 mL and 50 mL, capable of generating cardiac outputs of up to 9.5 L/m and 7.5 L/min, respectively. The pneumatically activated diaphragm system automatically balances output between the left and right ventricles and responds to increases in venous return with increased outputs.<sup>1</sup> Each chamber is activated by a separate drive-line connected to the external driver.

The 70 mL TAH-t received United States Food and Drug Administration approval in 2004 as bridge to transplantation (BTT) therapy<sup>2</sup> and is currently undergoing an investigational device exemption clinical trial for destination therapy. In addition, smaller adults and pediatric patients are being enrolled in an investigational device exemption and in humanitarian device exemption clinical trials investigating the 50 mL TAH-t as BTT. To date, more than 1700 TAH-t implantations have been performed in the United States and abroad at select centers.

The keys to successful device implantation remain patient selection and operative techniques aimed to facilitate orthotopic heart transplantation. The paucity of data on the TAH-t, fewer implantations, and specialization of the device to certified centers, relative to such mechanical circulatory support systems as left ventricular assist devices (LVADs), impacts surgeon and trainee exposure and knowledge toward the device. Our aim is to review the patient selection criteria and emphasize operative implantation techniques that enable successful device implantation and ease orthotopic heart transplantation. In doing so, we will focus on specific teaching strategies, decision points, and pitfalls of the TAH-t implantation.

## Preparation

Patient selection is paramount to successful TAH-t implantation. The surgeon is encouraged to obtain a thorough history and physical examination on all patients

being considered for advanced therapies, including TAH-t. The patient review focuses on the etiology of heart failure, left and right ventricular size and function, concomitant structural heart defects and cardiac pathology, patient size, end-organ function, and transplant eligibility. Pertinent preoperative studies include chest roentgenogram, electrocardiogram, echocardiogram, left- and right heart catheterization, chest computed tomography (CT), cardiopulmonary exercise testing, and pulmonary function testing. Any perturbations in end-organ function must be investigated. Availability of the preoperative work-up may depend on the patient's clinical status and need for vasopressor/inotropic support and temporary circulatory support. A detailed psychosocial evaluation is completed. Transplant eligibility is determined concurrently with evaluation for TAH-t, and destination therapy TAH-t may be considered in select patients under clinical trial oversight. Understanding the evaluation process before embarking on TAH-t implantation is crucial.

Patient size is of particular interest for TAH-t implantation for which a chest CT remains imperative. The 70-mL TAH-t displaces 400 mL, and recipients should have a body surface area (BSA) of 1.7 m<sup>2</sup> or larger. The thoracic diameter, anteroposterior dimension measured from the posterior sternum to the anterior 10th vertebral body, should be greater than 10 cm (Figure 1). The 50-mL TAH-t may be considered in patients with smaller body habitus or a BSA of 1.85 m<sup>2</sup> or less when under a clinical trial setting. Three-dimensional imaging can be useful in assessment of the chest cavity in borderline patients. Alternatively, the device may be displaced into the left chest with increased risks of left pulmonary vein or bronchus compression.<sup>3</sup> The size implications of TAH-t implantation and chest CT are reviewed preoperatively in addition to the other preoperative studies.

New implanters should understand that assessment of right ventricular function is essential in identifying patients who may benefit from TAH-t support because these patients almost universally have biventricular failure. Recognizing right ventricular failure or marginal right heart function is based on the patient's history and physical examination, laboratory data, including hepatic and renal function, right heart catheterization, and hemodynamic data, and echocardiogram. A number of risk

Address correspondence to Dr Mokadam, Division of Cardiac Surgery, Ohio State University, N-825 Doan Hall, 410 W 10th Ave, Columbus, OH 43210; email: [nahush.mokadam@osumc.edu](mailto:nahush.mokadam@osumc.edu).

Dr Mokadam discloses a financial relationship with SynCardia, Medtronic, Abbott, and Carmat.

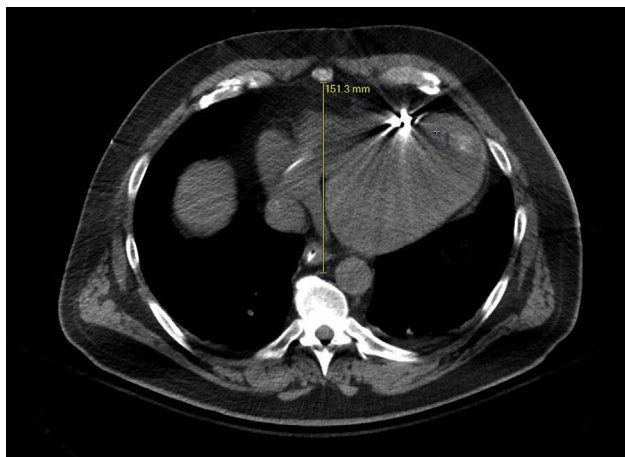


Figure 1. Thoracic diameter: The anteroposterior dimension on an axial computed tomographic image, measured from the posterior sternum to the anterior 10th vertebral body, should be >10 cm.

assessment tools have been developed to identify patients with right heart dysfunction who will benefit from biventricular support.<sup>4</sup>

Differentiating patients in need of biventricular support with TAH-t or biventricular assist devices (BiVAD) as opposed to LVAD support remains challenging. Occurrence of right heart failure in patients supported with LVADs leads to worse outcomes compared with patients without right ventricular failure.<sup>5</sup> Although no randomized, prospective data exist, short-term and midterm survival is improved with TAH-t compared with BiVAD.<sup>6,7</sup> The decision-making process for offering TAH-t support in lieu of BiVAD, LVAD, or palliation in a select subset of patients is made in a multidisciplinary team approach. Notably, durable BiVAD therapy as a BTT, when conducted, is performed off label and may encounter reimbursement challenges for the implant and health system.

When offering TAH-t support to patients, the surgeon must have a firm grasp on the indications for TAH-t implantation. Consideration for TAH-t is appropriate for the following (but not limited to) scenarios:

- Irreversible biventricular failure
- Cardiogenic shock
- Postcardiotomy failure
- Malignant arrhythmias
- Restrictive, infiltrative, or hypertrophic cardiomyopathies
- Massive myocardial infarction
- Mechanical complications of myocardial infarction, including ventricular septal defect
- Ventricular thrombosis
- Allograft failure, rejection, or posttransplant vasculopathy
- LVAD thrombosis/failure
- Right ventricular failure with LVAD support
- Congenital heart disease
- Cardiac malignancy

- Selected patients with unreconstructable endocarditis
- Multiple mechanical valves

Involvement in the preoperative evaluation of the patient and decision-making process for TAH-t implantation is indispensable to the learning process. These patients are critically ill and possess unique challenges for the surgeon that must be fully understood before the operating room. Knowledge regarding orthotopic heart transplantation is key to understanding the technical pearls of TAH-t implantation, because the successful transplant operation actually begins during the TAH-t implant.

### How I Teach It

The decision to perform an implant should be made before proceeding to the operating room. This is essential to ensure that the patient and family are fully engaged in possible outcomes. In addition, it is valuable to the surgical and medical team for full investment and preparation.

#### Preparation and Cannulation

The patient is placed supine on the operating room table. General anesthesia is induced, and a single-lumen endotracheal tube is placed by the anesthesia team. Intraoperative monitoring consists of an arterial catheter and multilumen central venous access. Cerebral oximetry is monitored throughout the case. The patient is prepared in the standard fashion from the chin to the knees. The groins are accessible should additional venous access or arterial monitoring become necessary.

The TAH-t system is prepared on the back table according to manufacturer standards. The application of a biological sealant to the outflow graft is necessary to provide hemostasis. Notably, the grafts should be fully elongated such that the sealant is able to reach the entire surface area of the graft. Once this is completed, all implantable components are wrapped in antibiotic soaked sponges while awaiting implantation.

After a standard sternotomy incision, a pericardiotomy is performed and a wide pericardial well created. The pericardium and diaphragm are divided laterally toward the apex of the heart to facilitate device and driveline placement. The patient is systemically heparinized. The pericardial reflection is dissected free from the proximal aortic arch, and additional stay sutures are placed as needed for exposure. A tonsil clamp is used to retract the aorta inferiorly, and the aorta is cannulated in the distal ascending aorta or proximal arch such that this cannulation site will no longer be visible at the time of transplant. It is important to circumferentially mobilize the ascending aorta.

Bicaval venous cannulation is required for TAH-t implantation. It is important not to disturb the pericardial reflections of the superior vena cava (SVC) and inferior vena cava (IVC), because this will facilitate transplant. In addition, the cannulation site can be at the caval-atrial

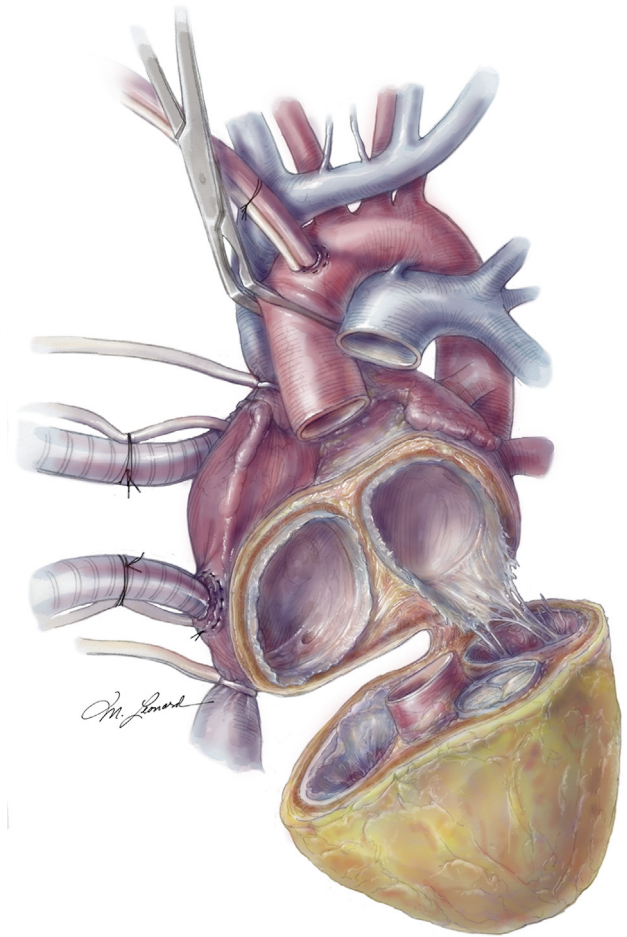
junction for the superior cannula so as to not disturb the more proximal SVC for transplant because the conduction system becomes irrelevant after implant. Similarly, the IVC cannula can be in the right atrium and inferiorly directed into the IVC. Caval tapes are needed, and the circumferential dissection of the SVC and IVC should be limited to the transverse sinus and oblique sinus, again to preserve tissue planes. The patient is initiated on cardiopulmonary bypass.

### Ventriculectomy

The aorta is cross-clamped without delivery of cardioplegia and is divided at the sinotubular junction to allow for venting. The pulmonary artery is divided through the pulmonary valve, and the right ventricular outflow is identified. A retractor is used to visualize the tricuspid valve. Resection of the ventricle is initiated in the atrioventricular groove by dividing the right coronary cusp of the aorta. Ideally, the right coronary artery is preserved with the atrium to provide tissue strength. The resection is continued toward the tricuspid annulus, and 3 to 5 mm of ventricular tissue is preserved around the tricuspid annulus. The fat pad is left intact with the right coronary artery until the posterior ventricular septum is encountered. Excessive ventricular tissue will interfere with the quick-connects, and serial resections can predispose to tissue embolization. Therefore, it is ideal to accomplish this task with one clean cut.

Next, the left ventricle is entered through the aortic root to visualize the septum, which is resected with 5 mm of tissue above the tricuspid annulus and connecting to the right ventricular resection. Now, the left ventricle is resected in an analogous fashion. The coronary sinus is preserved if possible, and the posterior mitral annulus is visualized. With 3 to 5 mm of ventricular tissue left on the mitral annulus, the ventricle is resected. Taking care to preserve the left atrial appendage, this is carried around to the anterior mitral annulus. From the aortic root, the aortomitral curtain is divided and connected to the annular resection. The tricuspid and mitral valve leaflets are excised 2 to 4 mm from the annuli. At this point, the ventricles should be handed off the field ([Figure 2](#)).

The coronary sinus ostium in the right atrium is oversewn. Even if the coronary sinus was able to be preserved during ventriculectomy, tributary veins from the ventricular resection would result in exsanguination. Examination for patent foramen ovale is conducted, and if found, oversewn. If there are implantable cardioverter defibrillator leads entering from the SVC, they are pulled down and sharply divided. Notably, use of felt reinforcement for all anastomoses is avoided. The quick-connect attachments are inverted and sewn to the tricuspid and mitral valve annuli, incorporating epicardium and pericardial adipose tissue using a running 4-0 Prolene (Ethicon, Somerville, NJ; [Figure 3](#)) suture. Both atrial quick connects are everted, and a second, hemostatic 4-0 Prolene suture is placed circumferentially.

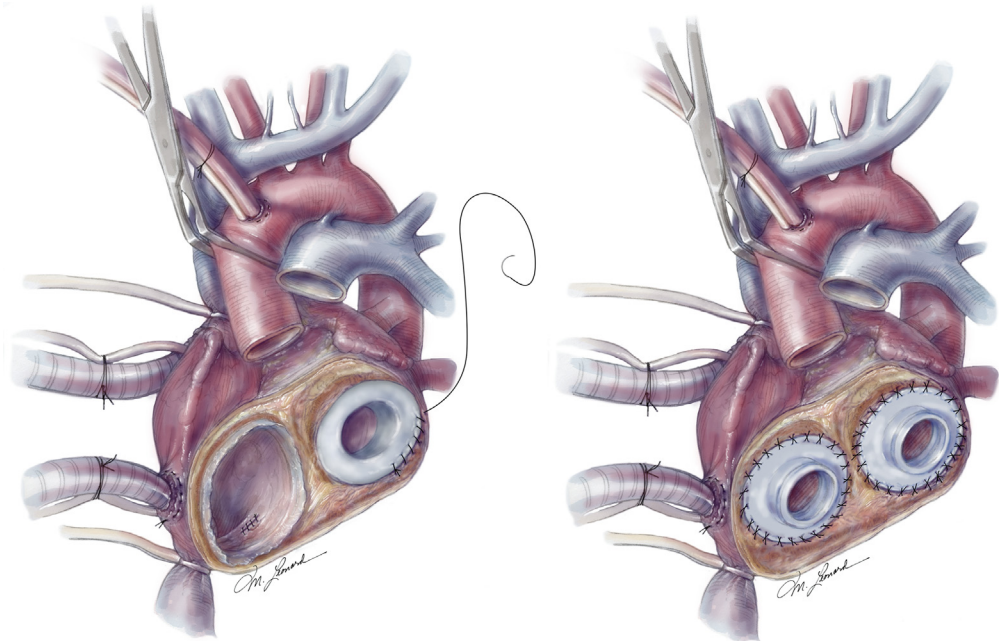


*Figure 2. Ventriculectomy: The proximal arch of distal aorta is cannulated. Bicaval venous cannulation is through the right atrium. Preservation of the conduction system is irrelevant, and the caval tissue planes are left intact. The ventricular incision is distal to the atrioventricular groove, and the left atrial appendage is preserved. (Reproduced with permission from SynCardia Systems, LLC.)*

The pulmonary artery and aortic quick-connect grafts are addressed next. The pulmonary artery graft is typically trimmed to 4.5 cm and sewn to the pulmonary artery using a single, running 4-0 Prolene suture. Excessive length in this graft can result in kinking or compression from the overlying sternum. The aortic graft is typically trimmed to 3 cm and secured with a double suture line. The high  $dP/dt$  of this device can result in delayed bleeding without appropriate reinforcement.<sup>8</sup> At this time, in preparation for transplant, a large 15- × 20-cm Gore-Tex pericardial membrane (0.01 mm; W. L. Gore & Associates, Flagstaff, AZ) is attached under the IVC and left pulmonary artery along the left atrium ([Figure 4](#)).

The left ventricle is attached first using the mitral and aortic quick connects. The ventricle is de-aired by filling it with saline. The driveline is tunneled as laterally as possible and pulled taught to avoid any loop within the pericardium or preperitoneal pocket ([Figure 5](#)). The right ventricle is attached next in similar fashion. The driveline

*Figure 3. (Left) The coronary sinus is oversewn, and the fossa ovalis is inspected for a patent foramen ovale. The quick-connect attachments are first inverted and sutured to the tricuspid and mitral valve annuli, incorporating the epicardium and pericardial adipose tissue. (Right) Both atrial quick connects are everted and oversewn with a second, hemostatic suture line. (Reproduced with permission from SynCardia Systems, LLC.)*

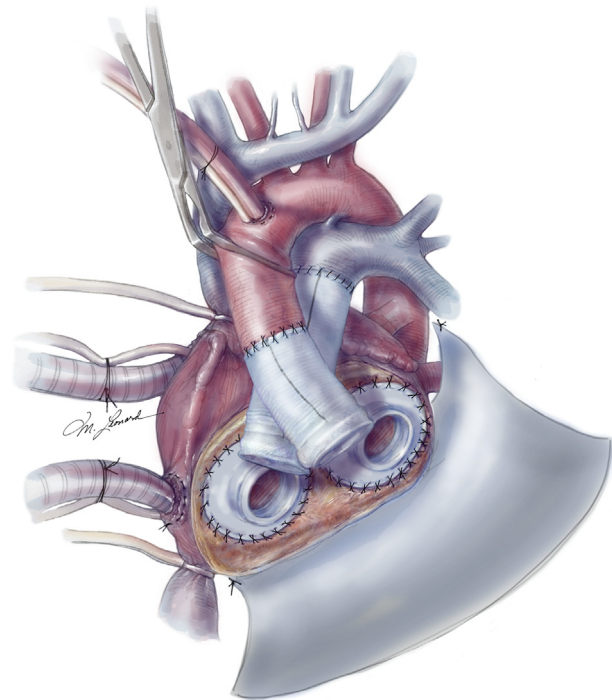


is tunneled as lateral as possible to the left ventricle and pulled taught. Both de-airing nipples are ligated (Figure 6). Driveline exit sites should be at least 5 cm apart to prevent skin necrosis between them.

#### *De-airing and Weaning Cardiopulmonary Bypass*

A de-airing needle is placed near the distal aortic anastomosis, and the patient is placed in Trendelenburg. With the aortic cross-clamp in place, the caval tapes are brought up, the heart allowed to fill, and the lungs are ventilated. The TAH-t controller is allowed to “gallop” several times at 40 beats/min while agitating the ventricles. Once complete, the cross-clamp is removed on a low flow state. The patient is weaned from cardiopulmonary bypass relatively quickly while increasing TAH-t speed. In general, as the fill volumes remain steady over 35 mL, the rate is increased by 20 beats/min. Ideally, once off cardiopulmonary bypass, the TAH-t will be near 120 beats/min with fill volumes above 40 mL.

The surgical sites are meticulously examined for hemostasis. Importantly, the caval tapes are released but left surrounding the cavae at this point. The following steps are undertaken to ease the subsequent reoperation and orthotopic heart transplantation because an intense inflammatory reaction develops to the surface of the TAH-t ventricles. A Gore-Tex pericardial membrane is sutured laterally from the SVC to the IVC. Another 8- × 16-cm Gore-Tex pericardial membrane is cut into 4- × 16-cm strips and used to wrap the SVC and IVC. The caval tapes are used to loop the Gore-Tex membrane around the cava, and the membranes are sutured anteriorly. Then, a 15- × 20-cm Gore-Tex membrane is cut into 7- × 15-cm and 13- × 15-cm strips. The larger piece is used to wrap the entire aorta and aortic graft. The 7- × 15-cm



*Figure 4. The pulmonary artery and aortic quick-connect grafts are trimmed to size, 4.5 cm and 3 cm, respectively. The pulmonary artery anastomosis is completed with a single, running 4-0 Prolene (Ethicon, Somerville, NJ) suture. The aortic anastomosis is double layered using 4-0 Prolene. A 15- × 20-cm Gore-Tex pericardial membrane (W. L. Gore & Associates, Flagstaff, AZ) is secured beneath the inferior vena cava and the left pulmonary vein along the left atrium. (Reproduced with permission from SynCardia Systems, LLC.)*

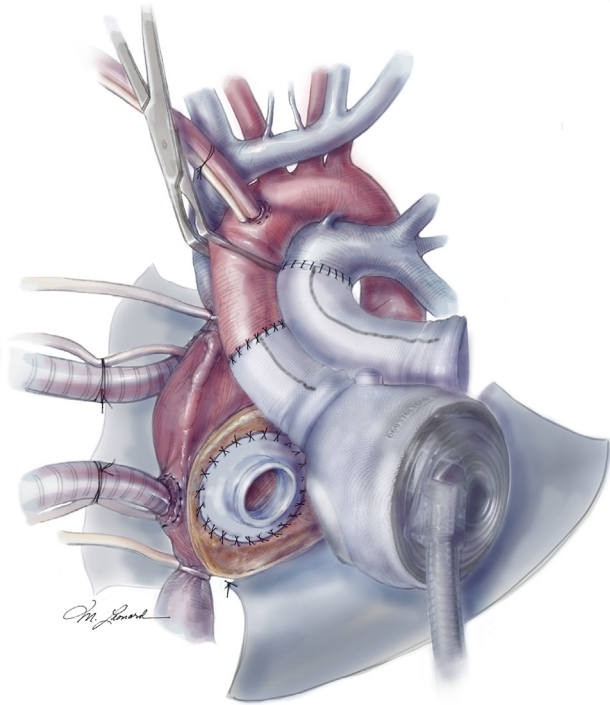


Figure 5. The left ventricle is attached first using the quick-connect attachments. The ventricle is de-aired with saline. The driveline is tunneled laterally and pulled taut. (Reproduced with permission from SynCardia Systems, LLC.)

membrane is wrapped around the pulmonary artery anastomosis. Both pieces of membrane are sutured together anteriorly to aid in removal and attached to prevent migration of the membranes (Figure 7). Lastly, the inferior 15- × 20-cm and lateral 15- × 20-cm Gore-Tex pericardial membranes are loosely sutured in the midline to wrap the TAH-t.

Mediastinal drainage is accomplished with an angled chest tube along the diaphragm, a straight mediastinal chest tube outside of the Gore-Tex beneath the sternum, and a Blake drain near the apex. Drainage tubes and the drivelines are secured with heavy suture.

The sternum is closed in a standard fashion. Negative pressure vacuum on the TAH-t console is started after closure of the fascia. Finally, the implantable cardioverter defibrillator, if present, is removed. It is important to do this with the chest open in the event that the SVC or innominate vein is lacerated during removal.

#### Orthotopic Heart Transplant

The transplant operation is significantly facilitated by the TAH-t implant technique. Because there is a contiguous sheet of pericardial membrane in the retrosternal plane, after incision and removal of sternal wires, a Yankauer suction tip can easily be passed from the xyphoid to the sternal notch. Once complete, a standard reciprocating saw can be used for the sternotomy. Mediastinal adhesiolysis can be extensive; however, the entire aorta is

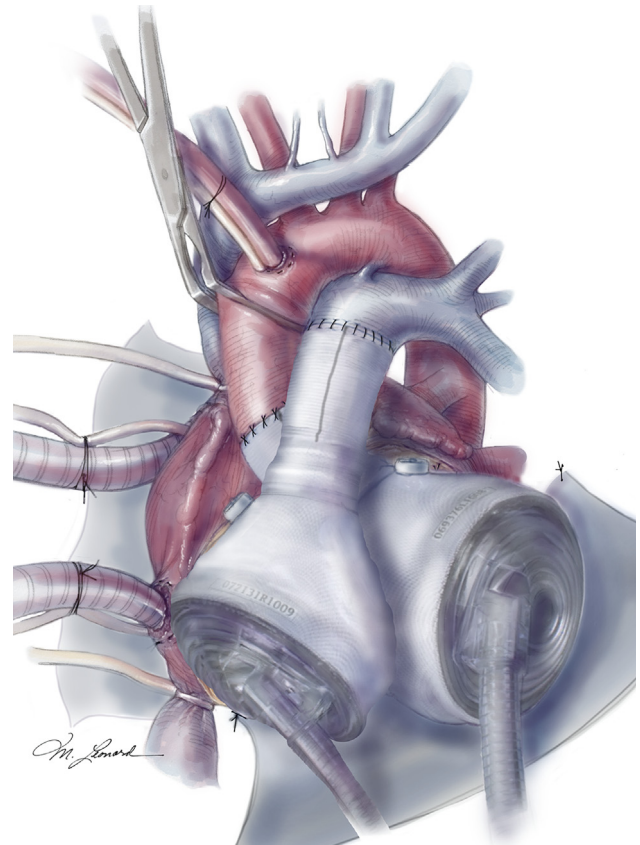


Figure 6. The right ventricle is attached last. The driveline is tunneled medial to the left ventricle. Both de-airing nipples on the ventricles are ligated. (Reproduced with permission from SynCardia Systems, LLC.)

rapidly mobilized due to the membrane surrounding it. Similarly, the membrane around the pulmonary artery can be removed. Typically, the main pulmonary artery will retract but should be able to be easily mobilized for anastomosis. In rare circumstances, a short portion of the graft can be left in situ for the anastomosis. Further, the membranes surrounding the cavae can be located and sewn to a new caval tape. Therefore, rapid isolation of the great vessels can be accomplished without peripheral cannulation and before systemic heparinization. The drivelines, pulled taut, can also be rapidly mobilized.

Once cannulated and on cardiopulmonary bypass, the ascending aorta can be clamped, caval tapes can be snared, and all quick connects disconnected. Drivelines should be divided and soaked with Betadine (Purdue Pharma LP, Stamford, CT) because they are not sterile internally. With the ventricles of the TAH-t removed, the right atrium can be preserved for a biatrial transplant or resected for a bicaval transplant. The left atrium, aortic, and pulmonary artery connections are standard. The drivelines, including their velour coverings, should be fully removed. In most cases, using this technique and preparation, the patient can be ready to accept a donor heart within 1 hour of incision.

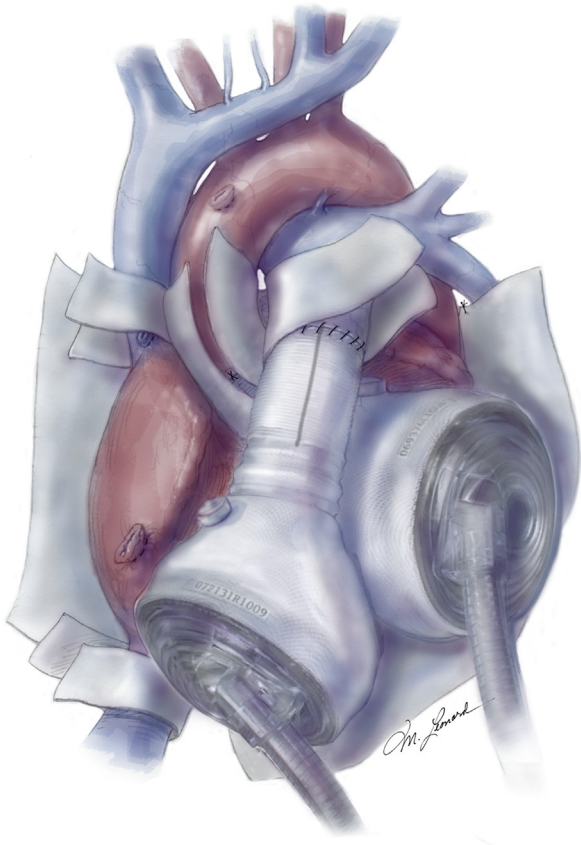


Figure 7. Gore-Tex pericardial membrane (W. L. Gore & Associates, Flagstaff, AZ) is used to limit the inflammatory reaction to the temporary total artificial heart and aid in reoperation and heart transplantation. (Reproduced with permission from SynCardia Systems, LLC.)

## Comment

The SynCardia TAH-t is a durable, biventricular circulatory system that offers excellent support in the right patient. The decision to implant the device is made after a thorough review process, as described, that must be fully understood by the patient and providers and is imperative to successful outcomes. The teaching points reviewed here emphasize the technical aspects of TAH-t implantation that can facilitate orthotopic heart transplantation. Technical pearls of implant and explant are keys to a rapid and safe approach to a variety of patients.

## References

1. Copeland JG. SynCardia Total Artificial Heart: update and future. *Tex Heart Inst J*. 2013;40:587-588.
2. Copeland JG, Smith RG, Arabia FA, et al. Cardiac replacement with a total artificial heart as a bridge to transplantation. *N Engl J Med*. 2004;351:859-867.
3. Tang DG, Shah KB, Hess ML, Kasirajan V. Implantation of the SynCardia total artificial heart. *J Vis Exp*. 2014;89:50377.
4. Lampert BC, Teuteberg JJ. Right ventricular failure after left ventricular assist devices. *J Heart Lung Transplant*. 2015;34:1123-1130.
5. Kormos RL, Teuteberg JJ, Pagani FD, et al. Right ventricular failure in patients with the HeartMate II continuous-flow left ventricular assist device: incidence, risk factors, and effect on outcomes. *J Thorac Cardiovasc Surg*. 2010;139:1316-1324.
6. Kirklin JK, Naftel DC, Pagani FD, et al. Seventh INTERMACS annual report: 15,000 patients and counting. *J Heart Lung Transplant*. 2015;34:1495-1504.
7. Kirsch M, Mazzucotelli JP, Roussel JC, et al. Survival after biventricular mechanical circulatory support: does the type of device matter? *J Heart Lung Transplant*. 2012;31:501-508.
8. Hermsen JL, Smith JW, Pal JD, et al. Late surgical bleeding following total artificial heart implantation. *J Card Surg*. 2015;30:771-774.